

Experimental Study on Ostrich Acellular Dermal Matrix in Repair of Full-Thickness Wounds of Guinea Pig

Fereshteh KHOMEJANI FARAHANI ¹ Hamidreza FATTAHIAN ¹ 
Abdol-Mohammad KAJBAFZADE ²

¹ Department of Clinical Science, Faculty of Specialized Veterinary Science, Science and Research Branch, Islamic Azad University, Tehran - IRAN

² Department of Pediatric Urology, Children's Hospital, Tehran University of Medical Sciences, Tehran - IRAN

KVFD-2015-13212 Received: 22.02.2015 Accepted: 30.03.2015 Published Online: 02.04.2015

Abstract

ADM (Acellular dermal matrix) can be a standard treatment for full-thickness wound defects. The aim of the present study was to achieve a decellularized matrix of the ostrich as a biomedical application and assess the evaluation of wound healing, which were implanted with ADM. Eighteen (n=18) guinea pigs were conducted and they received a full- thickness 2x2 cm flank skin wounds, nine experiment were implanted with acellular ostrich dermal matrix as experimental group and nine experiment as control group, which implanted with normal ostrich skin. At days of 3, 7 and 26 were evaluated for epithelialization and the other histological characteristics (Kruskal-wallis and Mann Whitney U tests), and the wounds were assessed for wound contracture at 26 days after surgery (ANOVA and Tukey test). Each dermal substitute decreased wound contracture and show no significant different at the endpoint of study (P>0.05). Between groups, increasing infiltration of fibroblast and new blood vessels under collagen scaffold showed no significant different (P=0.06). Histological evaluation of wound epithelialization and neo-dermis which was produced by ADM, was thicker neo-dermis at the end of study in experimental group. The study revealed that ostrich acellular dermal matrix can be used as a temporary substitute with acceptable result in healing of full-thickness wounds.

Keywords: Wound, Acellular dermal matrix, Guinea pig

Kobaylarda Tüm-Deri Katmanlarını İçeren Yaralarda Devekuşu Asellüler Dermal Matriksin Etkisinin Araştırıldığı Deneysel Bir Çalışma

Özet

ADM (Asellüler dermal matriks) tüm katmanları kapsayan yaralarda standart bir tedavi şekli olabilir. Bu çalışmanın amacı biyomedikal bir uygulama olarak devekuşu desellüler matriksin oluşturulması ve yara iyileşmesinde ADM uygulamasının başarısının değerlendirilmesidir. On sekiz (n=18) kobay çalışmada kullanıldı ve bu hayvanların yan taraflarında 2X2 cm boyutlarında deri yaraları oluşturuldu. Deneme grubu olarak 9 hayvana asellüler devekuşu dermal matriksi uygulanırken diğer 9 hayvan kontrol grubu olarak kullanıldı ve normal devekuşu derisi uygulandı. Epitelizasyon ve diğer histolojik bulgular 3., 7. ve 26. günlerde değerlendirildi (Kruskal-wallis ve Mann Whitney U testi) ve operasyondan 26 gün sonra yara durumuna bakıldı (ANOVA ve Tukey testi). Her iki uygulama yara kontraktürünü azaltırken çalışma sonunda anlamlı bir fark tespit edilmedi (P>0.05). Gruplar arasında fibroblast infiltrasyonu ve kolajen çatı altında damarlaşma açısından bir fark belirlenmedi (P=0.06). ADM uygulanan grupta yara epitelizasyonunun ve neoderminin histolojik değerlendirmesinde çalışma süreci sonunda daha kalın neodermis oluşumu gözlemlendi. Çalışma sonunda elde edilen bulgular yara iyileşmesinde asellüler dermal matriksin geçici olarak kullanılabileceğini göstermektedir.

Anahtar sözcükler: Yara, Asellüler dermal matriks, Kobay

INTRODUCTION

Skin suffers from different injuries and losses. When tissue loss is extensive, the healing process may not be enough to cure, and treatment with flaps and grafts should

be considered. Skin grafts, may be classified as autologous, homologous or xenogenic, such as those of porcine or bovine origins. Different procedures for tissue replacement have been introduced with the purpose of reducing scar formation and speeding up healing time ^[1,2]. Different



İletişim (Correspondence)



+98 212 2357598



Hamidrezafattahian@yahoo.com

methods of wound closure are in use, and each has its own advantages and disadvantages. The use of xenogenic skin as a source of ADM (Acellular dermal matrix) might alleviate some problems and make ADM more readily available for use in reconstructive surgery [2]. Due to excellent success in a variety of different biomedical applications, the performance of ADM, derived from full-thickness skin treated and removing of cells and cellular components, recently has drawn the attention of researchers in many fields [3]. Acellular dermal matrices are used as a suitable tissue for covering and also treatment of extensive burns [1]. In the wound-healing process, dermal substitutes play a guiding and supporting role during the cell and blood vessel recovery process [4]. Dermal substitutes serve as a scaffold into which cells can migrate and repair the injury [5]. Acellular dermal tissues are obtained by removing cellular components that are present in the tissue, since the cells are responsible for the activation of the immunological response. The absence of cellular structures result in little inflammation, and prevents rejection of the transplanted tissue [2]. As a dermal regeneration template, they also promote the guided regeneration function of the tissue, reduce scar hyperplasia and improve the quality of wound-healing [4]. The usefulness of ADM, which is derived from full-thickness skin following of removing the cells and cellular components concentrated in skin defect and cosmetic improvements. Because of absence cell particles of skin and diminishing of its antigenicity, it has been one of the most ideal substrate for a microenvironment for the cell movement and proliferation with no rejection. This experimental study deliberate to research of the effect of ostrich ADM in healing of full-thickness wounds of guinea pig.

MATERIAL and METHODS

Eighteen (n=18) adult male guinea pigs (230±17 g) were conducted. They were housed in cages with appropriate same food, humidity, light and bedding. Animals were fasted for 6 hours before surgery. All animals were administered subcutaneously by saline-dextrose solution (15 ml/kg) one hour before surgery for supporting energetic deficient of guinea pigs during surgery. All surgical processes were performed using aseptic technique. Anesthesia consisted of combination of acepromazine (1 mg/kg) and ketamine HCL 10% (40 mg/kg) administrated intramuscularly to maintain deep anesthesia.

Left flanks of the animals were shaved and prepared aseptically. By placing the surgical drape, surgical site was exposed. Skin excision was made as 2×2cm surgical wounds in both groups by 15 no scalpel blade. ADM and normal skin were placed on the wounds and grafts sutured by simple interrupted pattern using a 4-0 nylon suture. The wounds were dressed with cotton gauze and fine cover bandage. Enrofloxacin 0.1 mg/kg, sc. and meloxicam 0.2

mg/kg orally were administrated as antibiotic and NSAID to all animals for 3 days after surgery, respectively.

Preparation of ADM

Fresh ostrich skin was obtained from the cadaver. After complete cleaning and excision of subdermal fat tissues, the skin was used for preparation of ADM. The preparation of ADM was consisted of washing the ostrich skin with PBS (Phosphate-buffered saline) then the skin was kept in DW (Distilled Water) for 24 h and then in Triton X-100 at 4°C temperature for 24 h. After that the proceed skins were washed with DW and then skins were kept in SDS (Sodium Dodecyl Sulfate) for 15 h and then the skins were washed with DW and then were kept in SDS for 10 h. Finally the skins were washed with PBS. The cocktail of antibiotic was used after acellular protocol to preclude microbial growth.

Scanning Electron Microscopy (SEM)

Normal and ADM samples were treated with routine protocols for preparing SEM examinations and samples were loaded on to aluminum studs and coated with gold. Collagen morphologies were examined under a scanning electron microscope (Philips XL30, Netherlands). Samples were scanned, and the micrographs were recorded. Comparisons were made of morphological changes to collagen fibers before and after ADM protocols.

Biochemical Assessment of Normal and ADM Samples

Collagen and sGAG content of the tissues were quantified using the Sircol and Blyscan assay kits, respectively. Total collagen and sGAG of all tissues were quantified and expressed as µg/mg wet skin tissue.

Gross and Histologic Measurement and Assessment

Wound characteristics were measured grossly on day 26 after surgery. Direct measurements of wounds area and wound contractions were determined from photographs taken intermittently. All healed wound in each group on day 3, 7 and 26 post surgery were biopsied and then dehydrated with an increasing series of alcohol concentration and after completing the process, embedded in the paraffin finally. Paraffin-embedded samples were sectioned at a thickness of 6 µm. After H&E staining, samples were examined by light microscopy. A blinded pathologist evaluated all samples histologically for epithelization, fibroblast infiltration and degree of inflammatory cell infiltration, collagen generation and new vessels production. The DNA in samples were assessed by 4',6-diamidino-2-phenylindole (DAPI) staining, and then observed under light microscope.

Data Analysis and Statistics

Data were analyzed statistically by ANOVA and Tukey test, the Kruskal-wallis and Mann Whitney U tests. All

analysis was performed using SPSS software (Version 18.0). P value was considered for statistically significance.

The present study has been approved by the Animal Ethics Committee of the Iranian Laboratory animal ethic frameworks under the reference code IAEC 3-12/03.

RESULTS

There is not clinical difference in appearance of ADM and normal skin such as color, texture and size.

Histologic Observation of Normal and ADM Samples

Unprepared sample showed presence of epidermal layer in H&E and massive nucleus in ECM in DAPI staining. Decellularized sample showed no epidermal layer in H&E and few positive staining of residual nuclear materials in DAPI staining (Fig. 1).

Scanning Electron Microscopy (SEM) Evaluation

The histologic evaluation using SEM examination of

normal samples structure showed a dense and integral matrix. After decellularization and underwent a period of processing with Triton, PBS and SDS, the structural pattern of collagen fiber still remained without microscopic changes (Fig. 2).

Biochemical Assessment of Normal and ADM Samples

The decrease of collagen content per wet weight of decellularized skin ($42.11 \pm 2.5 \mu\text{g}/\text{mg}$) was significant ($P < 0.05$) in compare with native tissue ($57.86 \pm 4.7 \mu\text{g}/\text{mg}$), as well as in compare with native ($1.8 \pm 0.22 \mu\text{g}/\text{mg}$), sGAG content of decellular skin ($1.03 \pm 0.05 \mu\text{g}/\text{mg}$) was significantly decrease (Table 1).

Gross Evaluation of Wound Contracture

Dimensions of the implanted graft and contracture show at day 26 after surgery for each group (Table 2). Decreased wound contraction assessed by original wound area. Graft contraction in both groups manifested no statistical difference macroscopically at the end point of study ($P > 0.05$).

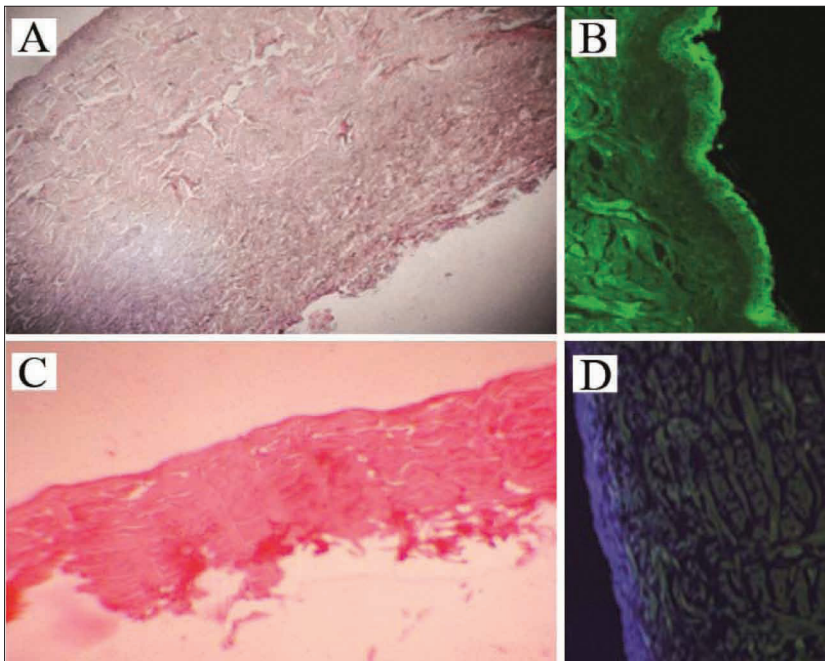


Fig 1. A- Normal skin, H&E (4x); B- Normal skin, DAPI ($\times 10$); C- Acellular skin, H&E (4x); D- Acellular skin, DAPI (40x)

Şekil 1. A- Normal deri, H&E (4x); B- Normal deri, DAPI ($\times 10$); C- Asellüler deri, H&E (4x); D- Asellüler deri, DAPI (40x)

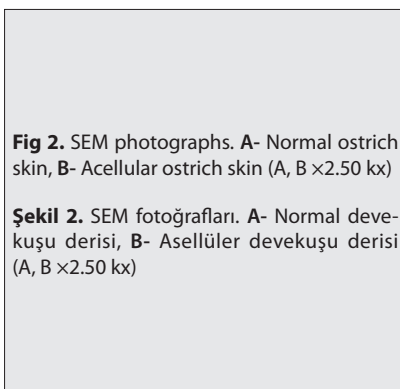


Fig 2. SEM photographs. A- Normal ostrich skin, B- Acellular ostrich skin (A, B $\times 2.50 \text{ kx}$)

Şekil 2. SEM fotoğrafları. A- Normal devekuşu derisi, B- Asellüler devekuşu derisi (A, B $\times 2.50 \text{ kx}$)

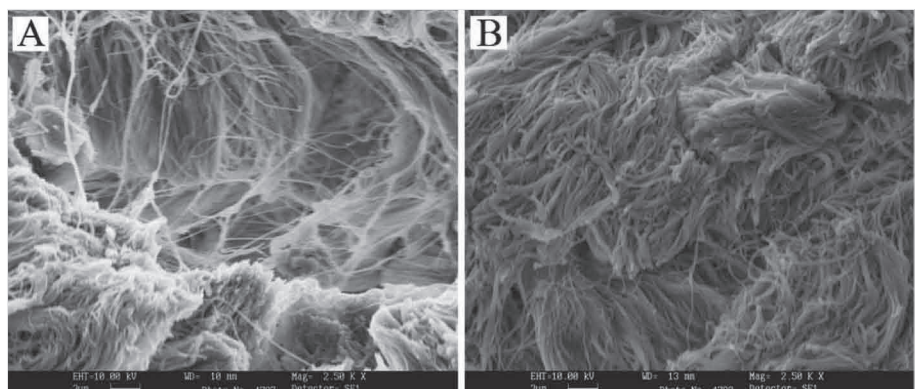


Table 1. Quantification of the total collagen content and sGAG in the tissues (means \pm SD)**Tablo 1.** Dokulardaki total kolajen miktarı ve sGAG'nın kantitatif hesabı

Grafted Tissue	Total Weight	
	Total Collagen ($\mu\text{g}/\text{mg}$ wet tissue)	Total sGAG Content ($\mu\text{g}/\text{mg}$ wet tissue)
Normal ostrich skin	57.86 \pm 4.7 ^a	1.8 \pm 0.22 ^b
Acellular ostrich skin	42.11 \pm 2.5 ^a	1.03 \pm 0.05 ^b

Different signs (a,b) show signification

Table 2. Area of grafts at day 26. Results are expressed as mean \pm SD**Tablo 2.** 26. günde greftlerin alanı. Sonuçlar ortalama SS olarak \pm verilmiştir

Area (cm ²)	Group 1	Group 2
		1.38 \pm 0.18 ^a

(a) sign shows not significant

Histologic Evaluation of Wound in Days of Sampling

Both wounds in groups had infiltration of with fibroblast and vascularized by 3 days after surgery. Increasing in infiltration of fibroblast and neovascularization were evident in wound bed under collagen scaffold. No significant difference was shown by day 7 after surgery in infiltration of fibroblast between groups ($P=0.06$).

Table 3. Evaluation of histologic factors in days 3, 7 and 26. Results are expressed as mean \pm SD**Tablo 3.** 3., 7. ve 26. günde histolojik faktörlerin değerlendirilmesi. Sonuçlar ortalama SS olarak \pm verilmiştir

Factor	Day	Group 1	Group 2
Epithelization	3	0 ^a	0 ^a
	7	1.3 \pm 0.57 ^a	1.6 \pm 0.57 ^a
	26	1.6 \pm 0.57 ^a	4 ^b
Inflammation	3	1.3 \pm 0.57 ^a	3.3 \pm 1.15 ^a
	7	2.6 \pm 1 ^a	3.6 \pm 0.57 ^a
	26	3 \pm 0.57 ^a	3.6 \pm 1.15 ^a
Fibroblast	3	1 ^a	0.6 \pm 0.57 ^a
	7	2.3 \pm 0.57 ^a	3.6 \pm 0.57 ^a
	26	4 ^a	4 ^b
Vascular	3	1 ^a	1.6 \pm 0.57 ^a
	7	3 ^a	3.3 \pm 1.15 ^a
	26	3.3 \pm 1.15 ^a	3.6 \pm 0.57 ^a
Collagen	3	1 ^a	1 ^a
	7	1.3 \pm 0.57 ^a	2.3 \pm 0.57 ^a
	26	2.6 \pm 0.57 ^a	4 ^a

Different signs (a,b) show signification

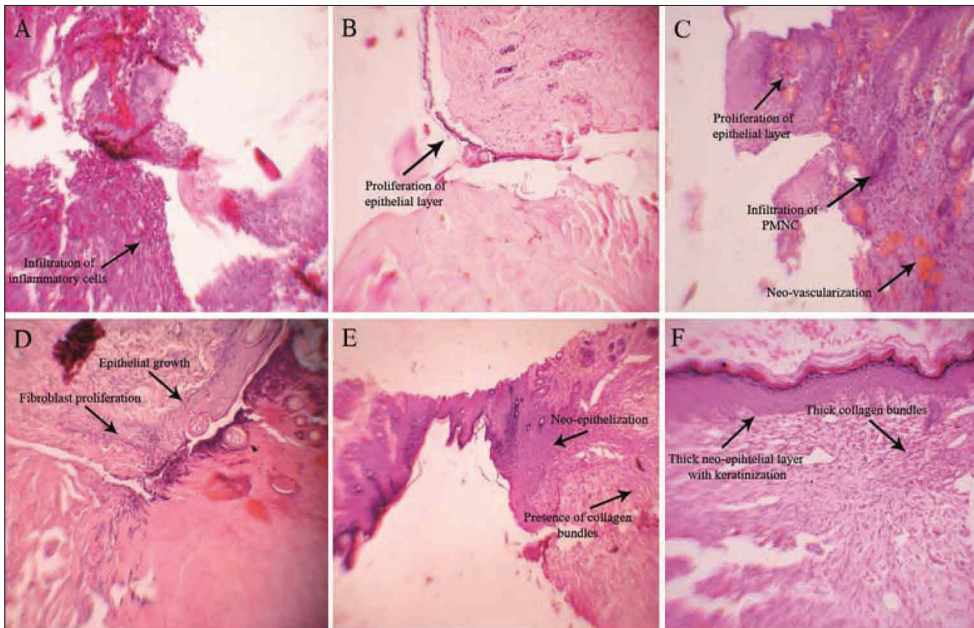


Fig 3. H&E staining of normal and ADM of ostrich skin samples. Representative histology from harvested in days 3, 7 and 26 after surgery. A- Day 3, control group, B- Day 3, experimental group, C- Day 7, control group, D- Day 7, experimental group, E- Day 26, control group, F- Day 26, experimental group (A-F \times 10)

Şekil 3. Devekuşu deri örneklerinin normal ve ADM'lerinin H&E boyanmış örnekleri. Operasyondan 3, 6 ve 26 gün sonraki örnek histolojik görüntüleri. A- 3. gün, Kontrol grubu, B- 3. gün, deneme grubu, C- 7. gün, Kontrol grubu, D- 7. gün, deneme grubu, E- 26. gün, Kontrol grubu, F- 26. gün, deneme grubu (A-F \times 10)

Histologically, inflammation was seen in the wound samples of both groups. Comparing ADM and normal implanted skin show no significant difference between the groups ($P=0.031$). However extensive inflammation involving the entire biopsy specimen was observed in wound implanted with ADM and normal samples at endpoint of study. Histologic epithelialization in both groups was seen but the quantification of neo-dermis of ADM samples was thicker than normal graft (Fig. 3). There is a significant difference ($P<0.034$)

between groups in collagen bundles at endpoint of study (Table 3).

DISCUSSION

In extensive deep burns and the other full-thickness skin wounds, permanent replacement of lost skin remains a major challenge. The different methods of wound closure are in use, and each has its own advantages and disadvantages. Porcine skin and preserved cadaver skin are

used for temporary wound coverage, but 1 week to 2 weeks after grafting, these tissues undergone immune-mediate rejection. Permanent wound coverage is usually accomplished using meshed split-thickness autograft harvested from undamaged regions of skin. The extensively burned patients have limited donor source, so thin split-thickness autografts are harvested repeatedly from the same sites. This results in substantial donor-site problems resulting from pain, infection, scarring and some keloid formation. Very thin meshed autografts can be used, but the lack of sufficient dermal bed often results in extensive wound contraction at the recipient site. Therefore, deepidermized xenograft porcine or human skin which cell components have been extracted and removed, as dermal substitute (Acellular Dermal Matrix) has been used with the least immuno-antigenicity and alleviate some of these problems and make ADM available for use in surgical procedure [2].

Human cadaver is expensive, limited and have economic problems, hence, available tissue are restricted as allograft. Also in islamic countries porcine products are forbidden so its skin is not used currently as xenograft. Nowadays ostrich farms spread and its products such as meat and leather are used widely in most countries. Therefore the use of xenogenic skin of ostrich as a new and wide source of ADM by alleviating of the problems make it more readily available for use in surgical procedure in skin deficit. Several previous studies have suggested using different materials for producing acellular dermal matrix of porcine or human skin. As Livesey et al. [6] extracted most or all cellular component from porcine, Srivasta et al. [2] used Dispase and Triton to produce acellular porcine skin. Mizuno et al. [7] used human skin for producing acellular matrix by using SDS (Sodium dodecyl sulfate) and hypertonic NaCl. Troung et al. [5] produced acellular human skin by using Dispase and Triton. In recent years Zuo et al. [8] in an experimental study, used EDTA-Na (Ethylenediaminetetraacetic acid), Triton and Trypsin for decellularizing rat skin. In this study, we prepared xenogenic ostrich ADM from fresh ostrich skin using SDS (Sodium dodecyl sulfate), PBS (Phosphate buffered saline) and Triton, used as xenograft in guinea pigs.

As previously mentioned, at the end point of study, wound contracture did not show significant different in two groups, that the findings agreed with Srivaste et al. [2] and Heo et al. [9] studies, which observed no significant contracture in wounds implanted with grafts. Also Walden et al. [10] study showed the dermal grafting was prevented contracture of wound. This data was confirmed our results. Absence of prepared dermal matrix causes the fibroblast initially synthesizes an immature matrix and subsequently remodeled to form a hypertrophic scar or scar contracture [9]. Although decellularizing removes most or all of cellular components, leaves structural and functional molecules such as collagen and sulfated glycos-

aminoglycan (sGAG), which facilitate the communication of the adjacent cells and with external environment. GAG in ECM have special impact on delaying wound contraction and inducing regeneration [8].

Srivasta et al. [2] and Hoyama et al. [1] were observed infiltration of inflammatory cells around grafts. Srivasta et al. [2] expressed the cause of infiltration of inflammatory cells was the presence of type IV collagen, laminin, some fibronectin, and glycosaminoglycans remains in ADM, albeit in reduced amounts compared with normal skin, it seems unlikely the source of antigenicity. Histological results of presence of inflammatory cells in our study agreed with Srivasta et al. [2] and Hoyama et al. [1] studies.

Troung et al. [5] by using human acellular matrix as xenograft in rat evaluated epithelization in wound bed, also Heo et al. [9] with the aim of evaluating healing potential of different shape of ADM and comparing of the epithelialization, defined that although all full-thickness wounds implanted with/without acellular dermal matrix produced epithelialized healed wound by day 28 after surgery that the quantity of wound healing was different between the groups. Our study showed significant difference in epithelization formation between two groups. Early research with acellular dermal tissues was based on theory that if in presence of an appropriate matrix, normal cells of normal adjacent tissue would migrate towards the matrix and performing their functions as if they were in normal tissues. The other studies revealed these expectations, showing the presence of normal fibroblast, collagen and elastin with normal maturity and orientation [1]. Livessey et al. by using porcine acellular dermal matrix found that ADM attached well with the wound bed and promote the ingrowth of fibroblast on the surrounding normal tissue, also after 1 week new blood vessels were formed as a permanent dermal replacement [6]. We found that proliferation of fibroblast and formation new vessels are migrated under ostrich acellular matrix.

In conclusion, epithelization on wound bed of group implanted with acellular ostrich skin demonstrate that ostrich acellular dermal matrix as a temporary substitute may have optimal results in reconstruction of epithelial on wound bed under acellular scaffold.

ACKNOWLEDGEMENT

The authors thank to Dr. P. Mortazavi, M. Tehrani and M. Abedi for contributions.

REFERENCES

1. Hoyama E, Schellini SA, Pellizon HC, Marques EAM, Padovani CR, Rossa R: Porcine acellular dermal graft with and without impermeable dressing to treat extensive wounds. *An Bras Dermatol*, 80, 369-374, 2005. DOI: 10.1590/S0365-05962005000400007
2. Srivastava A, DeSagun EZ, Jennings LJ, Sethi S, Phuangsab A,

-
- Hanumadass M, Rwyes HM, Walter R:** Use of porcine acellular dermal matrix as a dermal substitute in rats. *Ann Surg*, 233 (3): 400-408, 2001. DOI: 10.1097/00007890-199507150-00001
- 3. Chen RN, Ho H, Tsai Y, Sheu M:** Process development of an acellular dermal matrix (ADM) for biomedical applications. *Biomaterials*, 25, 2679-2686, 2003. DOI: 10.1016/j.biomaterials.2003.09.070
- 4. Chen X, Feng X, Xie J, Ruan SH, Lin Y, Lin Z, Shen Z:** Application of acellular dermal xenografts in full-thickness skin burns. *Exp Ther Med*, 6, 194-198, 2013. DOI: 10.3892/etm.2013.1114
- 5. Truong AN, Kowal-Vern A, Latenser BA, Wiley DE, Walter RJ:** Comparison of dermal substitutes in wound healing utilizing a nude mouse model. *J Burns Wound*, 4, 72-82, 2005.
- 6. Livesey SA, Herndon DN, Hollyoak MA, Atikson YH, Nag A:** Transplanted acellular allograft dermal matrix. Potential as a template for the reconstruction of viable dermis. *Transplantation*, 60, 1-9, 1995.
- 7. Mizuno H, Takeda A, Uchinoma E:** Creation of an acellular dermal matrix from frozen skin. *Aesthetic Plast Surg*, 23 (5): 316-322, 1999.
- 8. Zuo H, Peng D, Zheng B, Liu X, Wang Y, Wang L, Zhou X, Liu J:** Regeneration of mature dermis by transplanted particulate acellular dermal matrix in a rat model of skin defect wound. *J Master Sci: Master Med*, 23, 2933-2944, 2012. DOI: 10.1007/s10856-012-4745-9
- 9. Heo Ch, Chang H, Minn K, Kim B:** Comparison of the acellular dermal matrix (ADM) and micronized particulate ADM in wound healing utilizing a nude mouse model. *TERM*, 8 (5): 433-438, 2011.
- 10. Walden JL, Garcia H, Hawkins H, Crouchet JR, Traber L, Gore DC:** Both dermal matrix and epidermis contribute to an inhibition of wound contraction. *Ann Plast Surg*, 45, 162-166, 2000. DOI: 10.1097/0000637-200045020-00011