

Comparison of Rectal, Eye and Ear Temperatures in Kangal Breed Dogs ^[1]

Latif Emrah YANMAZ ¹  Elif DOĞAN ¹ Zafer OKUMUŞ ¹
Mümin Gökhan ŞENOCAK ¹ Fatih YILDIRIM ²

^[1] This study was supported by Ataturk University Scientific Research Projects (Project No: BAP 2013/033)

¹ Department of Surgery, Veterinary Faculty, Ataturk University, TR-25240 Erzurum - TURKEY

² Department of Zootechny, Veterinary Faculty, Ataturk University, TR-25240 Erzurum - TURKEY

Article Code: KVFD-2015-13037 Received: 23.01.2014 Accepted: 12.03.2015 Published Online: 18.03.2015

Abstract

The aim of this research was to compare rectal, eye and ear temperature of 30 healthy *Kangal* dogs. Rectal temperature was measured by use of standard rectal digital thermometer. Right and left eye temperatures were detected by infrared thermal camera from the *caracula lacrimalis* region. Tympanic thermometer was used to determine right and left ear temperatures. Data were analyzed by Pearson correlation test. The comparative analysis showed no significant differences between the measurement methods. Measuring of ear and eye temperature could be an alternative method to obtain body temperature in *Kangal* dogs.

Keywords: Body temperature, Rectal temperature, Eye, Ear, Kangal dog

Kangal Irkı Köpeklerde Kulak, Göz ve Rektal Isıların Karşılaştırılması

Özet

Bu çalışmanın amacı 30 sağlıklı kangal köpeğinin kulak, göz ve rektal ısılarını karşılaştırmaktır. Rektal ısı standart digital rektal termometre kullanılarak ölçüldü. Sağ ve sol göz ısı *caracula lacrimalis* bölgesinden kızılötesi termal kamera ile belirlendi. Timpanik termometre sağ ve sol kulak ısı değerlerini belirlemede kullanıldı. Veriler Pearson korelasyon testi ile analiz edildi. Karşılaştırmalı analizler tüm metodlar arasında önemli bir farklılık olmadığını gösterdi. Kangal köpeklerinde kulak ve göz ısısının ölçülmesi, vücut ısısının belirlenmesi için alternatif bir yöntem olabilir.

Anahtar sözcükler: Beden ısı, Rektal ısı, Göz, Kulak, Kangal köpeği

INTRODUCTION

Measuring of the body temperature is the crucial part of the canine physical examination. Digital rectal thermometer is the most commonly used tool to detect body temperature in dogs. However, it has some disadvantages such as time consuming, difficult to achieve in aggressive dogs, which could result with rectal injury, and impossibility in cases of atresia ani ^[1]. Alternative methods to detect body temperature are useful both patients and clinicians. Thermal microchips and infrared thermometers are used to measure body core temperature in dogs. However, the major disadvantage of microchip thermometry is necessity of equipment ^[2].

Infrared thermography is a noninvasive technique that detects temperature differences in a region. It has been pointed that eye temperature can reflect the core body

temperature. Moreover infrared thermography can be used to detect body temperature without touching or disturbing the animal ^[3].

Measuring of the ear temperature in veterinary medicine is a new, rapid and also economic technique. It has superiority on rectal temperature (RT) in some instances such as fractious dogs or those with recto-anal disease. However, the major limitations include ear diseases or inflammation and some dogs refuse placement of the probe ^[4].

Even though numerous researches have been conducted on *Kangal* dogs ^[5,6], to the authors' knowledge, there is no scientific data about measurement results of their eye and ear temperatures. Therefore, the aim of this study was to determine the difference between rectal, eye and ear temperatures in *Kangal* dogs.



İletişim (Correspondence)



+90 442 2315559



latifemrahyanmaz@gmail.com

MATERIAL and METHODS

Animals

Thirty male Kangal dogs (6-12 months old, mean body weight 40±9 kg) were enrolled in the study, which were brought to veterinary clinics at Ataturk University for various purposes; including routine physical examination, vaccinations and neutering. Each dog was healthy based on the physical examination. Measurements were collected at time between 9 am and 3 pm.

Measurements

Temperature measurements were obtained in a room, which had 25.3±1.1°C mean temperature, 58.0±8.0% relative air humidity and no direct sunshine. Before measurements, each dog was acclimatized in this room for 20 min.

Three different sources were used to determine dog temperature: rectal, eye and ear. Rectal temperatures were collected with a conventional digital thermometer from the dogs restrained by their owners. Digital rectal thermometer was inserted about 2 cm into the rectum, and it remained until the audible beep was heard.

Eye temperatures were obtained with infrared thermal camera (IR FlexCam S, Infrared Solutions Inc., Plymouth, MN, USA). Measurements were recorded when the infrared thermal camera was placed at a 1 meter distance from each dog. The dog was restrained by owners for 2 seconds to

measure the eye temperature, and then eye temperature was obtained focusing on *caracula lacrimalis* region by thermal camera.

Ear temperatures were obtained by infrared tympanic thermometer (Genius 2 Tympanic Thermometer, Covidien llc, Mansfield, USA) when the animal was restrained by owner. To measure the tympanic temperature of each ear, tympanic thermometer was inserted in the ear canal descending to the eardrum. After pressing the activation button, auricular temperature was appeared within 2 seconds.

Statistical Analysis

All data were analyzed using the SPSS 19 (IBM Company, Version 19.0, SPSS Inc, USA, 2010) statistical package. Data were presented as the average of the right tympanic temperature (RTT), left tympanic temperature (LTT), right caracula lacrimalis temperature (RCT), left caracula lacrimalis temperature (LCT) and RT. Differences among RTT, LTT, RCT, LCT and RT were analyzed by Pearson correlation test.

RESULTS

The consistency of RTT, LTT, RCT and LCT measurements versus to rectal temperatures are given in Fig. 1. The comparative statistical analysis results are shown in Table 1, which is indicated not significantly different results of

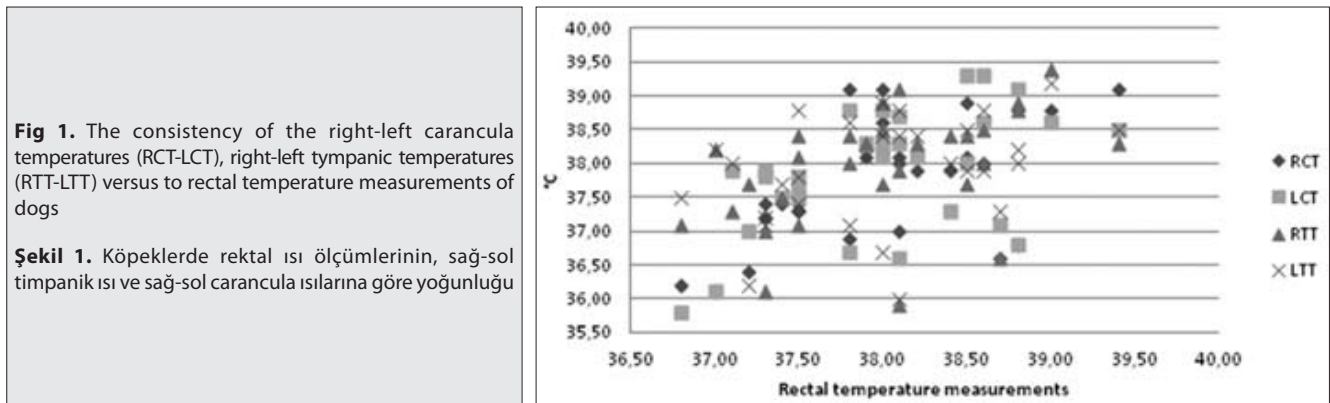


Fig 1. The consistency of the right-left caracula temperatures (RCT-LCT), right-left tympanic temperatures (RTT-LTT) versus to rectal temperature measurements of dogs

Şekil 1. Köpeklerde rektal ısı ölçümlerinin, sağ-sol timpanik ısı ve sağ-sol caracula ısılarına göre yoğunluğu

Table 1. Means, standard errors (SE), correlations and level of significance (P) of the right tympanic temperature (RTT), left tympanic temperature (LTT), right caracula temperature (RC), left caracula temperature (LCT) and rectal temperature (RT) in dogs

Tablo 1. Köpeklerde rektal, sol caracula, sağ caracula, sol timpanik ve sağ timpanik ısıların ortalamaları, standart hataları, korelasyonları ve önem seviyesi

Variable	Mean± SE (°C)	95% CI		RCT	LCT	RTT	LTT	RT
		Lower Bound (°C)	Upper Bound (°C)					
RCT	37.682±0.149	37.354	38.011	-	0.906**	0.485**	0.490**	0.569**
LCT	37.750±0.179	37.357	38.143		-	0.409*	0.459*	0.506**
RTT	37.940±0.168	37.570	38.311			-	0.739**	0.431*
LTT	37.920±0.191	37.499	38.341				-	0.368*
RT	37.997±0.119	37.754	38.239					-

** P<0.001, * P<0.005

RTT, LTT, RCT, LCT and RT. *Fig. 1* and *Table 1* observe high positive correlations between RTT, LTT, RCT, LCT and RT.

DISCUSSION

Measuring of the RT is a conventional method to reveal the body temperature in dogs. It has emphasized that measurement of RT may not be possible in 1.9% dogs due to intolerance [4]. This ratio may be higher if there is a rectal or perianal disease. It was reported that tympanic temperature measurement (TTM) was well tolerated than RT in dogs [2,4]; moreover it has also been reported that several dogs displeased the aural probe more than the rectal probe [7]. In the current study all measurement methods were well tolerated by all dogs. The prior study [8] has revealed that, similar to our results, TMMs' is easy to collect and rapid compared with RT.

Infrared thermography has been gaining popularity instead of surface temperature, and it does not need to direct contact with the patient [9]. Eye temperature is a more accurate and useful indicator of core body temperature [10]. It has been stated that direct sunlight could result in increased eye temperature [11]. We performed all thermographic measurements in a room without sunlight. As reported previously mean eye temperatures of horses was 32.6°C [11]; however, another study reported this ratio as 38.2°C, which was normal limit for horse' temperature [3]. This diversity is due to measurements of different parts of the eye. Central corneal temperatures of dogs were ranged between 34.4°C and 35.2°C [9]. Moreover it has been pointed out that temperature of nasal limbus tends to be higher than other regions of eye because of increased blood flow [10]. In this study, we also noticed lower central cornea temperature than nasal limbus, but we did not collect the temperature from the central cornea which had lower temperatures than body core temperature [12]. Our temperature results obtained from caruncula lacrimalis region correspond with rectal and tympanic temperatures.

In this study right and left tympanic temperature values showed strong similarity with RT. It has been reported that auricular temperature can be used to detect core body temperature in dogs [13]. On the other hand, a study on different breed dogs identified auricular temperatures have lower values than RT [14], which is disagreement with our findings. This discrepancy can probably due to breed differences and/or ear anatomy. Breed differences in body temperature have been reported in dogs [4,14]. It has been stated that sex do not affect the ear temperature [15], the current study was carried on only male dogs to prevent possible effects of temperature alterations.

Although current study did not focus on the selection of an advantageous method for obtaining body temperature, it was obvious that restriction of the dog by an assistant required in all methods. Measuring of eye temperature from the nasal limbus (caruncula lacrimalis region) seems

to more comfortable and safer than RT and TMM because it can be achieved without touching the animal. Moreover, TMM is easier than RT due to rapid detection of body temperature.

Measuring ear and eye temperature could be an alternative method to detect body temperature in Kangal dogs. It can be pointed out that further studies about body temperature techniques should be planned on other breeds and species.

REFERENCES

- Piccione G, Fazio F, Giudice E, Refinetti R:** Body size and the daily rhythm of body temperature in dogs. *J Therm Biol*, 34, 171-175, 2009. DOI: 10.1016/j.jtherbio.2009.01.004
- Sousa MG, Carareto R, Pereira-Junior VA, Aquino MCC:** Comparison between auricular and standard rectal thermometers for the measurement of body temperature in dogs. *Can Vet J*, 52, 403-406, 2011.
- Johnson SR, Rao S, Hussey SB, Morley PS and Traub-Dargatz J:** Thermographic eye temperature as an index to body temperature in ponies. *J Equine Vet Sci*, 31, 63-66, 2011. DOI: 10.1016/j.jevs.2010.12.004
- Lamb V, McBrearty AR:** Comparison of rectal, tympanic membrane and axillary temperature measurement methods in dogs. *Vet Rec*, 173, 524, 2013. DOI: 10.1136/vr.101806
- Yayla S, Ozturk S, Aksoy O, Kilic E, Yildiz S:** Normal ultrasonographic anatomy of the prostate in Kars shepherd dogs. *Kafkas Univ Vet Fak Derg*, 18, 27-30, 2012. DOI: 10.9775/kvfd.2011.4528
- Cilek S, Kavak G:** Some morphological characteristics of kangal shepherd dogs (Karabas) raised at villages by farmers in Kirikkale province. *Asian J Anim Vet Adv*, 7, 403-411, 2012. DOI: 10.3923/ajava.2012.403.411
- Greer RJ, Cohn LA, Dodam JR, Wagner-Mann CC, Mann FA:** Comparison of three methods of temperature measurement in hypothermic, euthermic, and hyperthermic dogs. *J Am Vet Med Assoc*, 230, 1841-1848, 2007. DOI: 10.2460/javma.230.12.1841
- Kunkle GA, Nicklin CF, Sullivan-Tamboe DL:** Comparison of body temperature in cats using a veterinary infrared thermometer and a digital rectal thermometer. *J Am Anim Hosp Assoc*, 40, 42-46, 2004. DOI: 10.5326/0400042
- Biondi F, Dornbusch PT, Sampaio M, Montiani-Ferreira F:** Infrared ocular thermography in dogs with and without keratoconjunctivitis sicca. *Vet Ophthalmol*, 18, 28-34, 2015. DOI: 10.1111/vop.12086
- Gloster J, Ebert K, Gubbins S, Bashiruddin J, Paton DJ:** Normal variation in thermal radiated temperature in cattle implications for foot-and-mouth disease detection. *BMC Vet Res*, 7, 73, 2011. DOI: 10.1186/1746-6148-7-73
- Yanmaz LE, Okumus Z:** Using infrared thermography to detect corneal and extremity temperatures of healthy horses. *Isr J Vet Med*, 69, 20-23, 2014.
- Klamann MK, Maier AK, Gonnermann J, Klein JP, Bertelmann E, Pleyer U:** Ocular surface temperature gradient is increased in eyes with bacterial corneal ulcers. *Ophthalmic Res*, 49, 52-56, 2013. DOI: 10.1159/000343774
- Southward ES, Mann FA, Dodam J, Wagner-Mann CC:** A comparison of auricular, rectal and pulmonary artery temperature in dogs with anaesthesia induced hypothermia. *J Vet Emerg Crit Car*, 16, 172-175, 2006. DOI: 10.1111/j.1476-4431.2005.00158.x
- Piccione G, Giannetto C, Fazio F, Giudice E:** Accuracy of auricular temperature determination as body temperature index and its daily rhythmicity in healthy dog. *Biol Rhythm Res*, 42, 437-443, 2011. DOI: 10.1080/09291016.2010.526425
- Huang HP, Huang HM:** Effects of ear type, sex, age, body weight, and climate on temperatures in the external acoustic meatus of dogs. *Am J Vet Res*, 60, 1173-1176, 1999.