

An Anthrax Outbreak in Wild Felidae Kept in a Local Zoo ^[1]

Rahşan YILMAZ ¹  Nihat YUMUŞAK ¹

^[1] Presented at VII. Veterinary Pathology Congress 08th-10th September 2014, Kars, Turkey

¹ Harran University, Veterinary Faculty, Pathology Department, Eyyübiye Campus, TR-63200 Şanlıurfa - TURKEY

KVFD-2014-12607 Received: 14.11.2014 Accepted: 06.01.2015 Published Online: 11.01.2015

Abstract

This report presents cases of anthrax infection in the leopard (*Panthera pardus*), tiger (*Panthera tigris*) and lion (*Panthera leo*). Of wild Felidae kept in the same zoo, 7 animals (2 lions, 1 tiger, 2 leopards, 1 jaguar, and 1 puma) died within 2 days with clinical manifestations including swelling of the tongue and lips, bleeding from the mouth and nose, listlessness. Of the animals, 2 sick lions were examined cytologically from the haemorrhagic exudate in the mouth and nose. Macroscopic examination revealed the presence of anthrax carbuncles in the skin and lesion in the spleen of the dead leopards. The microscopic examination of the skin lesions demonstrated haemorrhage, oedema and the infiltration of neutrophils and mononuclear cells in the dermis and hypodermis. Microscopically, the splenic lesions consisted of widespread haemorrhagic areas, the atrophy of the white pulp and multifocal necrosis in the red pulp. *Bacillus anthracis* spores were observed in the cytological examination of the skin and spleen lesions and the haemorrhagic nasal exudate. *Bacillus anthracis* spores were observed in smears of the haemorrhagic mouth and nasal exudates, in histological sections of the skin and spleen. Based on clinical, macroscopical, microscopic and cytological examinations, infection of the animals was diagnosed as an anthrax infection.

Keywords: Anthrax, Cytology, Histopathology, Wild felidae

Yerel bir Hayvanat Bahçesindeki Yabani Kedigillerde Antraks Salgını

Özet

Bu raporda, Leopar (*Panthera pardus*), kaplan (*Panthera tigris*) ve aslanda (*Panthera leo*) antraks enfeksiyonu sunulmaktadır. Aynı hayvanat bahçesinde dilde ve dudaklarda şişkinlik, ağız ve burundan kan gelmesi, halsizlik ve 2 gün içerisinde ölüm şeklinde klinik bulgulara sahip 7 hayvan (2 aslan, 1 kaplan, 2 leopar, 1 jaguar ve 1 puma) ölmüştür. Hasta 2 aslanın ağız ve burundan gelen kanlı eksudat sitolojik yönden incelendi. Ölen leoparların makroskopik muayenesinde deride antraks karbunkellerine ve dalakta lezyona rastlandı. Deri lezyonunun mikroskopik muayenesinde dermis ve hipodermiste kanama, ödem ile nötrofil ve mononükleer hücre infiltrasyonları görüldü. Dalağın mikroskopik muayenesinde yaygın kanama alanları, beyaz pulpada atrofi ve kırmızı pulpada multifokal nekroz odakları gözlemlendi. Deri ve dalağın histolojik kesitlerinde, ağız ve burundaki kanlı eksudat frotilerinde *Bacillus anthracis* sporlarına rastlandı. Yapılan makroskopik, mikroskopik ve sitolojik muayeneler sonucunda leopar, kaplan ve aslanda antraks enfeksiyonu tanımlanmıştır.

Anahtar sözcükler: Antraks, Sitoloji, Histopatoloji, Yabani Kedigil

INTRODUCTION

Anthrax is a zoonotic disease caused by *B. anthracis* ^[1]. *Bacillus anthracis* can persist as a dormant spore in soil for many years, there is little evidence to suggest that it can multiply outside an infected animal. In natural environments it is thought that healthy animals acquire the disease by grazing on the land contaminated with spores from infected animals ^[2]. Though the principal mode of transmission is ingestion of infective microorganisms, biting flies have been reported to transmit the disease from one animal to another ^[3]. In animals, the disease progresses rapidly, causes a high rate of mortality and generally courses with septicaemia. The principal lesions are those of

oedema, haemorrhage and necrosis ^[4]. Illness is observed for one or two days, but it may last five days; symptoms are preceded by fever, with a period of excitement in which the animal may charge anyone nearby ^[5]. All herbivorous animals are particularly susceptible to this pathogen. Humans, suids and carnivores are considered incidental hosts ^[4]. Susceptibility and high fatality has been reported in cattle, sheep, goats, horses, donkeys, pigs, and many warm-blooded domestic animals. Although avian species are naturally immune to the disease owing to their body temperature, literature reports indicate that the ostrich, crow and duck can be experimentally infected by faecal contamination. Humans may become infected by handling contaminated hides or wool or by examining infected



İletişim (Correspondence)



+90 414 3183926, Fax: +90 414 3183922



rahsany@harran.edu.tr

carcasses [5]. Wildlife with high rates of disease include antelope, bison, gazelles, impalas, elephants, hippopotami [6-8], red deer [9] black jackal [10]. Wild carnivores can also become infected through the consumption of dead animals infected with anthrax [7,8]. In this report, anthrax infection in the leopard (*Panthera pardus*), tiger (*Panthera tigris*) and lion (*Panthera leo*) were described with clinic-pathological findings.

CASE HISTORY

Two dead leopards, 1 dead tiger and 2 sick lions kept in the same zoo constituted the study material. Once all the necessary measures were taken to prevent the risk of contamination, smear samples were taken of all of the dead and live animals (Fig. 1-A). For cytological examination were carried out from the skin and spleen lesions of the dead

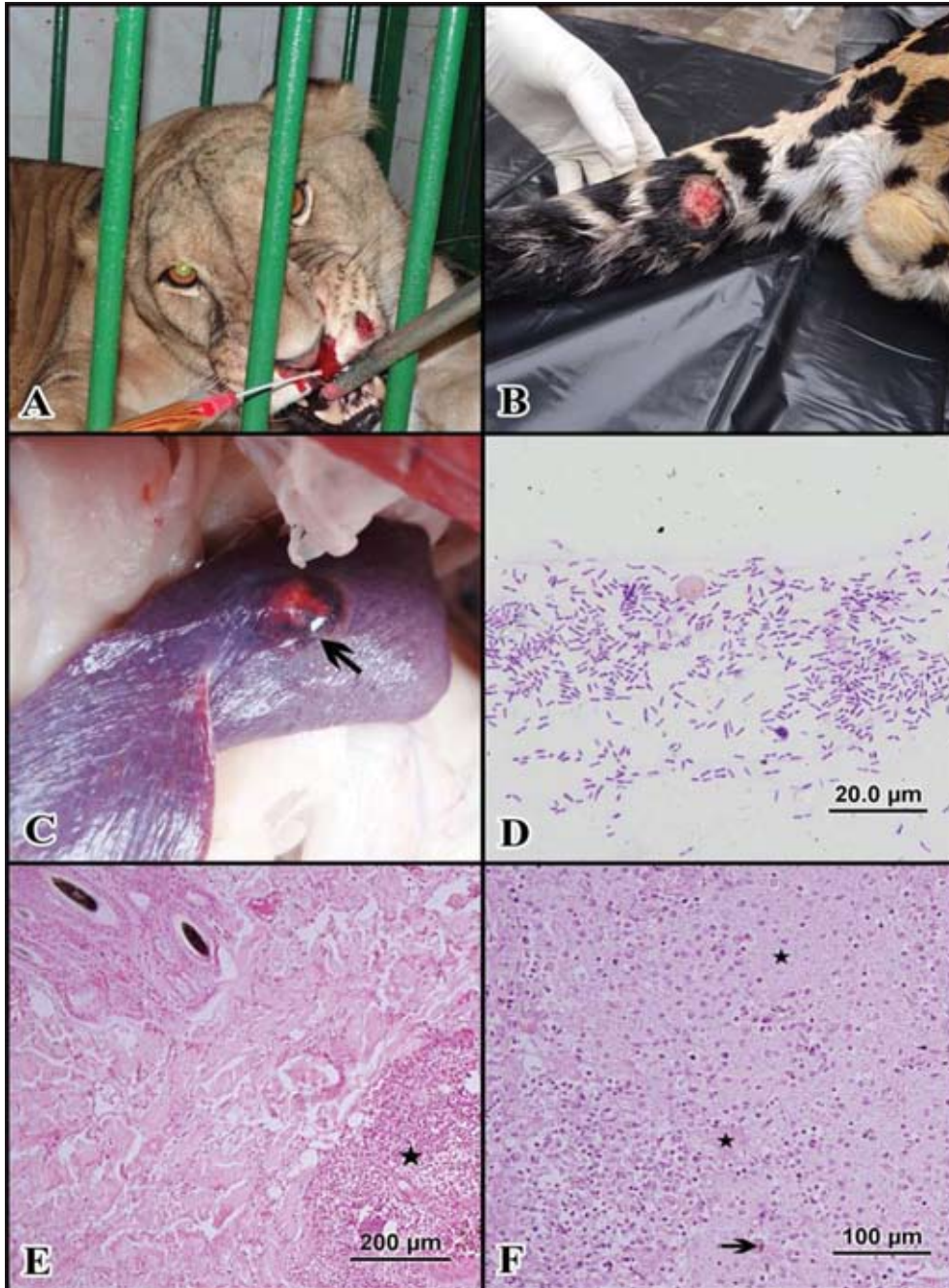


Fig 1. A- Bloody discharge the nose; B- Anthrax carbuncle on the tail; C- Lesion on the spleen; D- Spores of *Bacillus anthracis*, May Grünwald-Giemsa stain, x100; E- neutrophil infiltration in the dermis (star), Haematoxylin&Eosin stain, x10, F- Spleen necrosis (stars) and siderosis (arrow), Haematoxylin&Eosin stain, x20
Şekil 1. A- Burundaki kanlı eksudat; B- Kuyruktaki Anthrax karbunkeli; C- Dalaktaki lezyon; D- *Bacillus anthracis* sporları, May Grünwald-Giemsa boyması, x100; E- Dermiste nötrofil infiltrasyonu (yıldız), Hematoksilen&Eozin boyama, x10; F- Dalakta nekroz (yıldızlar) ve siderosit (ok), Hematoksilen&Eozin boyama, x20

animals. The smears were stained with May Grünwald-Giemsa solution. Specimens taken from the ulcerous focus (2x3 cm) in the skin of the tail of one of the dead leopards (Fig. 1-B) and the 2 convex lesions, measuring 3x3 cm and of light cream colour in the centre and dark red colour in the periphery, in the dorsal and ventral surfaces of the spleen of the other dead leopard (Fig. 1-C). The sections were fixed in neutral-buffered formalin and processed routinely. All sections were stained with Haematoxylin-Eosin (H&E). Because of there is no facility to bacteriological culture microbiological evaluation could be added.

The microscopic examination of the smears revealed the presence of short chains of dark blue coloured rod-shaped bacteria, surrounded by a purplish-red capsule (Fig. 1-D). The histopathological examination of the skin demonstrated widespread haemorrhage and oedema in the epidermis and dermis. The epidermis and dermis also presented with widespread and intense infiltration foci of normal, degenerated and necrotic neutrophils as well as with mononuclear cell infiltrations (Fig. 1-E). The histopathological examination of the demonstrated widespread haemorrhagic areas beneath the splenic capsule. Light brown colored siderocytes containing the hemosiderin pigment were dense in the haemorrhagic areas splenic tissue. The white pulp was observed to be atrophic. Disseminated multifocal necrosis was observed in the form of small foci in the red pulp (Fig. 1-F).

DISCUSSION

All domestic and wild animal species susceptible to the disease are infected either by the consumption of soil, feed, milk and water contaminated with *B. anthracis* spores, the biting of blood sucking flies carrying the pathogen, or the direct contact of open wounds with the spores [3,8,11,12]. According to the information given by the staff of the zoo, the wild Felidae were fed mainly the meat of horses and donkeys obtained from the region where the zoo was located. It was declared that the horses and donkeys were isolated in a separate unit in the zoo for 2 weeks, observed for signs of disease, and slaughtered only in the absence of any such sign. Due to the entire horse and donkey meat stock having been consumed, it could not be confirmed whether the infection of the wild Felidae was caused by the consumption of contaminated meat. In order to prevent any further risk of anthrax infection, the remaining live horses and donkeys were killed under the necessary precautions, and were not slaughtered for being fed to the wild Felidae. Once having entered the body, *B. anthracis* spores are phagocyted by macrophages and transported to the local lymph nodes. Here the endospores germinate, outgrow into vegetative bacilli, and cause septicaemia after being released into the blood circulation. Inside the macrophage, the vegetative form of the causative agent produces 3 exotoxins, namely, the protective antigen, lethal factor and oedema factor. These toxins cause various

clinical symptoms and lesions, including haemorrhage, oedema and necrosis [13,14]. Anthrax can be diagnosed on the basis of the identification of the causative agent by the examination of smears prepared from local lesions and blood, which are stained with the Gram, May-Grünwald Giemsa and methylene blue stains [15,16]. The direct or indirect contact of the pathogen with scratches and wounds in the skin, results in the formation of anthrax carbuncles. Skin lesions are observed as haemorrhagic pustules with a necrotic centre and surrounded by oedema, which may ulcerate with the course of the disease [1]. The internal organs affected by the disease vary with the transmission route of the pathogen [17]. As not performing a post-mortem examination of animals known or suspected to have died from anthrax prevents contamination [18], the animals included in the present study were not considered for necropsy. However, prior to the visit of the zoo for the on-the-spot examination of the animals, one of the dead leopards had been skinned and the abdominal cavity of the animal had been opened. The microscopic findings obtained for the spleen in the present study were in agreement with those reported in previous studies with in the experimentally infected [19]. In the present study, following an outbreak, anthrax infection was detected in wild Felidae kept in a zoo, on the basis of macroscopic, cytological and histopathological examinations. It was concluded that, food of animal origin provided to wild animals must be controlled for possible contamination with the anthrax pathogen in order to prevent the transmission of the infection.

REFERENCES

1. **Fasanella A, Palazzo L, Petrella A, Quaranta V, Romanelli B, Garofolo G:** Anthrax in red deer (*Cervus elaphus*), Italy. *Emerg Infect Dis*, 13, 1118-1119, 2007. DOI: 10.3201/eid1307.061465
2. **Centers for Disease Control and Prevention (CDC):** Human anthrax associated with an epizootic among livestock-North Dakota. *MMWR Morb Mortal Wkly Rep*, 50 (32): 677-680, 2001.
3. **Titball RW, Turnbull PC, Hutson RA:** The monitoring and detection of *Bacillus anthracis* in the environment. *Soc Appl Bacteriol Symp Ser*, 20, 9-18, 1991.
4. **Koch R, Gaffky G, Loeffler F:** The virulence of cultivated anthrax virus. Experimental studies on the artificial attenuation of the infectious properties of the bacillus of anthrax by means of cultivation. *Science*, 4, 276-277, 1884. DOI: 10.1126/science.ns-4.85.276
5. **Dragon DC, Rennie RP:** The ecology of anthrax spores: Tough but not invincible. *Can Vet J*, 36, 295-301, 1995.
6. **Stoltenow CL:** Anthrax. *J Equine Vet Sci*, 21 (4): 165-166, 2001. DOI: 10.1016/S0737-0806(01)70128-1
7. **Dixon TC, Meselson M, Guillemin J, Hanna PC:** Anthrax. *N Engl J Med*, 341, 815-826, 1999. DOI: 10.1056/NEJM199909093411107
8. **Dragon DC, Bader DE, Mitchell J, Wollen N:** Natural dissemination of *Bacillus anthracis* spores in northern Canada. *Appl Environ Microbiol*, 71, 1610-1615, 2005. DOI: 10.1128/AEM.71.3.1610-1615.2005
9. **Hanna PC, Ireland JA:** Understanding *Bacillus anthracis* pathogenesis. *Trends Microbiol*, 7, 180-182, 1999.
10. **Hugh-Jones ME, de Vos V:** Anthrax and wildlife. *Rev Sci Tec*, 21, 359-383, 2002.
11. **Peek SE, Sellon DC:** Miscellaneous Bacterial Infections. Section 3:

Bacterial and Rickettsial Diseases. In, Sellon DC, Long MT (Eds): Equine Infectious Disease. 383-384, Saunders, 2007.

12. Baillie LWJ: *Bacillus anthracis*. In, Batt CA, Robinson RK, Patel PD (Eds): Encyclopaedia of Food Microbiology. Vol. 1, 129-135, Academic Press, London, 2000.

13. Lindeque PM, Turnbull PC: Ecology and epidemiology of anthrax in Etosha National Park, Namibia. *Onderstepoort J Vet Res*, 61, 71-83, 1994.

14. Turell MJ, Knudson GB: Mechanical transmission of *Bacillus anthracis* by stable flies [*Stomoxys calcitrans*] and mosquitoes (*Aedes aegypti* and *Aedes taeniorhynchus*). *Infect Immun*, 55, 1859-1861, 1987.

15. Duong S, Chiaraviglio L, Kirby JE: Histopathology in a murine

model of anthrax. *Int J Exp Path*, 87, 131-137, 2006. DOI: 10.1111/j.0959-9673.2006.00473.x

16. Hazıroğlu R, Milli ÜH: Veteriner Patoloji. Cilt 2. 345-348, Medipres, Ankara, 2001.

17. Food and Agriculture Organization of the United Nations: Agriculture and Consumer Protection Department. Anthrax in animals. <http://www.fao.org/ag/magazine/0112sp.htm>, Accessed: 13 August 2014.

18. Godyn JJ, Reyes L, Siderits R, Hazra A: Cutaneous anthrax: Conservative or surgical treatment? *Adv Skin Wound Care*, 18 (3): 146-150, 2005.

19. Guarner J, Zaki SR: Histopathology and immunohistochemistry in the diagnosis of bioterrorism agents. *J Histochem Cytochem*, 54, 3-11, 2006. DOI: 10.1369/jhc.5R6756.2005