


## Alterations in Hip Angles Following of Juvenile Pubic Symphysiodesis in Ten Dogs with Hip Dysplasia

Gül ÖZDEMİR \* Hasan BİLGİLİ \* 

\* Ankara University, Faculty of Veterinary Medicine, Department of Surgery, TR-06110 Ankara - TURKEY

Makale Kodu (Article Code): KVFD-2010-3620

### Summary

The purpose of this study is to evaluate of pre- and postoperative clinical and radiological outcomes of 3-5 month-old, 10 dogs with hip dysplasia after juvenile pubic symphysiodesis. Pain scoring of hip extension test, Ortolani signs and Bardens palpations were performed pre- and postoperatively, on 1st, 3rd, and 6th months by clinical examinations. Norberg-Olsson angles on standard ventrodorsal on extended radiological views and distraction index on distracted hip radiological views were evaluated by radiological examinations. Juvenile pubic symphysiodesis was applied every 2.0 to 3.0 mm among to the entire length of the growth plate of the pubis via unipolar needle electrocautery (40 W, for 12 to 30 seconds). Acetabular full coverage on the femoral head was provided as a result of ventrolateral rotation of the acetabulum following juvenile pubic symphysiodesis procedure. The hip extension test, Ortolani signs and Bardens palpations were turned from positive to negative. In conclusion, juvenile pubic symphysiodesis is a successful and safe procedure which can be easily applied for prophylaxis and/or treatment of hip dysplasia (HD) in 3-5-month-old, large-breed puppies, which are predisposed to hip dysplasia or showing the initial clinical signs of hip dysplasia.

**Keywords:** Hip, Hip dysplasia, Juvenile pubic symphysiodesis, Dog

## Kalça Displazili On Köpekte Juvenil Pubik Simfiziodezis Operasyonunu Takiben Kalça Eklem Açılarında Şekillenen Değişiklikler

### Özet

Bu çalışmanın amacı; kalça displazisi bulunan 3-5 aylık yaştaki 10 köpeğin juvenil pubik simfiziodezis operasyonu sonrasında pre- ve postoperatif klinik ve radyolojik sonuçlarını değerlendirmektir. Pre- ve postoperatif 1, 3 ve 6. aylardaki kalça ekstensiyon testindeki ağrı skorlaması, Ortolani bulguları ve Barden palpasyon testi gibi klinik değerlendirmelerin sonuçları alındı. Standart ventrodorsal pozisyondaki Norberg-Olsson açıları ve distraksiyondaki kalça eklemine distraksiyon indeksi radyolojik olarak değerlendirildi. Juvenil pubik simfiziodezis, simfizis pubisin büyüme plağı boyunca 2-3 mm aralıklarla (40 W, 12-30 sn), unipolar iğne elektrotlu koter ünitesi yardımıyla uygulandı. Juvenil pubik simfiziodezis prosedürü ile asetabulumun ventrolateral rotasyonu şekillenerek kaput femorisin asetabulum tarafından tam olarak örtülmesi sağlandı. Olgularda kalçanın ekstensiyon testi, Ortolani ve Barden palpasyon testi sonuçları pozitiften negatife dönüştü. Sonuç olarak; juvenil pubik simfiziodezis, kalça displazisi gelişimine predispoze olan veya hastalığın ilk belirtilerini gösteren 3-5 aylık yaştaki büyük ırk yavru köpeklerde kalça displazisine karşı profilaksi ve/veya tedavi sağlamak amacıyla kolay uygulanabilen, güvenli ve başarılı bir prosedür olarak değerlendirildi.

**Anahtar sözcükler:** Kalça, Kalça displazisi, Juvenil pubik simfiziodezis, Köpek

### INTRODUCTION

Hip dysplasia (HD) is a biomechanical disease<sup>1,2</sup> occurring due to improper weight bearing between enlarged femoral head and acetabulum<sup>3,4</sup>. Such condition affects the growth and formation of the joints leading to an abnormal joint

structure and the degenerative joint disease (DJD) or osteoarthritis (OA)<sup>1,2,5,6</sup>.

Hip dysplasia is one of most frequently encountered



İletişim (Correspondence)



+90.312.3170315



hbilgilitr@yahoo.com

orthopedic disorders in large breed cases <sup>1,2,4,5,7,8</sup>. The latest studies were attempted towards reducing the incidence of this disease and encompasses to approaches associated with underlying aetiopathogenesis in the laxity of hip joints <sup>2,6,9-12</sup> and early diagnosis of the disorder <sup>3,5,12-17</sup>.

Several methods have been described treatment of HD in cases <sup>1,7,17-20,21</sup>. In addition, some new prophylactic treatment techniques have been developed for cases that are under the risk of HD. Juvenile Pubic Symphysiodesis (JPS) <sup>1,22-24</sup> is one of the new surgical techniques developed for the prophylaxis and treatment of HD in cases being under the risk of HD or in immature cases showing the early signs of HD <sup>4,16,19,25,26-28</sup>.

The purpose of this study is to evaluate of pre- and postoperative clinical and radiological outcomes of 3-5 month-old, 10 dogs with hip dysplasia after juvenile pubic symphysiodesis.

## MATERIAL and METHODS

In this study, 10 cases with HD in various age (3-5 months), breed and sex which were submitted to the Department of Surgery, Orthopedics and Traumatology Clinic, Faculty of Veterinary Medicine, University of Ankara were included in the study.

The cases were underwent a clinical examination for the diagnosis of orthopedic problems consider for HD. The puppies which are included in the study that have not completed the skeletal growth and these are consider under the risk of HD.

The hip joints were examined by Ortolani palpation test and Barden palpation test, and the hips were examined by radiography. For all cases, the hips of the puppies were checked by radiologically. For these procedures standard ventrodorsal (V/D) extended hindlimb views and distraction views to evaluate in the distraction position were performed. The evaluation for HD was based on the following criteria: gait analysis and routine orthopaedic examinations, pain scoring, Ortolani and Barden palpation tests, Norberg-Olsson (NO) angles on standard V/D radiological views and distraction index (DI) on distracted hip joints' radiological views. All angles were measured by Bs200Pro Software (BsCelik, BAB Digital Imaging System 2007, Ankara, Türkiye) on computer imaging. The risk of DJD formation was evaluated. Upon the consent of the owners, JPS operation was performed on cases with HD.

### Operation Technique

In male cases, skin incision was performed parallel to the penis from the scrotum to the point 3 cm cranial to the pubis under general anesthesia. Subcutaneous fascia on the pubic symphysis was incised by taking care of the prepubic tendon. Penis was retracted behind the median

zone following the ligation of pudental artery and venous collateral branches. In female cases, the same approach was applied in the ventralmidline <sup>29</sup>. Subperiosteal elevation of gracilis, adductor and external adductor muscles was performed by protecting the cranial ligament of the rectus abdominis. By reaching the pubic symphysis, an elevator was placed into pelvic canal to prevent intraabdominal organs (urethra and rectum) from thermal and iatrogenic injury and contamination. For an efficient cauterization, point cauterization along the pubic symphysis was performed at a dose of 40 W (at 2-3 mm interval) by using a unipolar standard cauter unit with needle electrode until the darkening of symphyseal tissue was observed (12-30 sec). The cauterization area was washed with physiologic saline solution following each cauterization. All subcutaneous connective tissue were closed with routine suture techniques.

### Post-operative Follow-up

No bandage was applied on the operation area. Carprofen (Rimadyl tablet, 20 mg, Pfizer, Istanbul, Turkey) at 3 mg/kg dose b.i.d. via PO route was recommended as postoperative pain reliever. For postoperative systemic antibiotic treatment, trimetoprim at 0.1 mg/kg dose via SC route or sulfametoksazol 400 mg, combined with trimetoprim 80 mg (Bactrim tablet, 15 mg/kg Roche, Istanbul, Turkey) via P.O. route once a day for 5 days was prescribed. In addition, terramycin spray application on the area was recommended for 10 days. While no limited exercise was recommended, the owners were advised to have short walks on a short leash to allow soft tissue amelioration. The patients were followed up on postoperative 1<sup>st</sup>, 3<sup>rd</sup> and 6<sup>th</sup> months. In follow-up period, Ortolani and Barden palpation tests were applied to the cases under general anesthesia. Standard V/D extended hindlimb views and distraction views to evaluate the distraction position were taken from the hips and above mentioned measurements were taken.

## RESULTS

In this study, 5 male and 5 female cases at the age of 3-5 months were included. The breeds of the cases were as follows: 4 Golden Retriever, 3 Labrador cross-breed, 2 German Shepherd and 1 English Bulldog (*Table 1*). Pre- and postoperative period of JPS procedure, pain scoring during hip extension was as follows: Light: +1, Mild: +2, Moderate: +3, Severe: + 4. According to this scale, 3 cases were scored as light to moderate, and the other 7 cases were scored as moderate to severe. At the postoperative 1<sup>st</sup> month follow up, while no pain was observed in 2 cases, the other 8 cases had reduced pain scores, ranging from mild to moderate. At the postoperative 3<sup>rd</sup> month follow up, 5 cases had light pain on one side of the hip, while the other 5 cases had no pain. In the postoperative 6<sup>th</sup> month, none of the cases experienced pain (*Table 2*).

Findings of Ortolani palpation test in pre- and post-operative orthopedic examinations were scored as Light: +1, Mild: +2, Moderate: +3, Severe: +4. According to the scoring system, Ortolani palpation test was positive in all cases and ranged from moderate to severe. In the postoperative 1st month, scores of Ortolani test ranged from light to moderate in all cases. In the postoperative 3<sup>rd</sup>

month, while 3 cases had light Ortolani finding, Ortolani findings in 7 cases was negative. In postoperative 6<sup>th</sup> month, findings of Ortolani palpation test in all cases were found to be negative (Table 3).

Findings of Barden test in pre- and post-operative orthopedic examinations were scored as Normal: +1, Borderline: +2, Dysplastic: +3, Dysplasia in advanced stage: +4. According to the Barden scoring system, preoperative findings of all cases were scored from dysplastic to dysplasia in advanced stage. In the postoperative 1<sup>st</sup> month, Barden scores were normal in 1 case and borderline or dysplastic in 9 cases. In the post-operative 3<sup>rd</sup> month, only 3 cases had score of normal in one side of hip, and other 7 cases were negative. In the postoperative 6<sup>th</sup> month, all cases were negative in terms of Barden palpation test (Table 4).

Pre- and postoperative radiological examinations of JPS applied cases, values of NO angles measured on standard V/D extended hindlimb radiographies were found to be normal (equal to 105 degrees or higher) and increased hip joint laxity (<105°). Preoperative NO measurements in all cases were smaller than 105 degrees indicating that all cases had increased hip joint laxity (Fig. 1a).

**Table 1.** Breed, age and sex of cases (F Female, M Male)

**Tablo 1.** Olguların ırk, yaş ve cinsiyetleri (F Dişi, M Erkek)

Case No	Breed	Age (month)	Sex
1	Labrador retriever	4.5	F
2	Labrador retriever	4.5	F
3	Labrador retriever	4.5	M
4	Golden retriever	4.5	M
5	English bulldog	5	M
6	Golden retriever	4	M
7	Golden retriever	4	F
8	German shepherd	3	F
9	German shepherd	3.5	M
10	Golden retriever	4	F

**Table 2.** Pre- and postoperative pain outcomes of cases (L Left, R Right)

**Tablo 2.** Olguların pre- ve postoperatif ağrı sonuçları (L Sol, R Sağ)

Case No	Preoperative		Postoperative 1st Month		Postoperative 3rd Month		Postoperative 6th Month	
	R	L	R	L	R	L	R	L
1	+3 R	+3 L	+1 R	+1 L	+1 R	0 L	0 R	0 L
2	+4 R	+3 L	+2 R	+1 L	+1 R	0 L	0 R	0 L
3	+4 R	+4 L	+2 R	+2 L	0 R	+1 L	0 R	0 L
4	+3 R	+3 L	+1 R	+1 L	0 R	+1 L	0 R	0 L
5	+4 R	+4 L	+2 R	+1 L	0 R	+1 L	0 R	0 L
6	+3 R	+4 L	+1 R	+2 L	0 R	0 L	0 R	0 L
7	+3 R	+2 L	+1 R	+1 L	0 R	0 L	0 R	0 L
8	+1 R	+1 L	0 R	0 L	0 R	0 L	0 R	0 L
9	+2 R	+1 L	0 R	0 L	0 R	0 L	0 R	0 L
10	+1 R	+2 L	0 R	+1 L	0 R	0 L	0 R	0 L

**Table 3.** Pre- and postoperative Ortolani sign outcomes of cases (L Left, R Right)

**Tablo 3.** Olguların pre ve postoperatif Ortolani testi sonuçları (L Sol, R Sağ)

Case No	Preoperative		Postoperative 1st Month		Postoperative 3rd Month		Postoperative 6th Month	
	R	L	R	L	R	L	R	L
1	+3 R	+3 L	+2 R	+2 L	0 R	0 L	0 R	0 L
2	+4 R	+3 L	+3 R	+2 L	+1 R	0 L	0 R	0 L
3	+4 R	+4 L	+2 R	+2 L	0 R	+1 L	0 R	0 L
4	+3 R	+3 L	+2 R	+2 L	0 R	0 L	0 R	0 L
5	+4 R	+3 L	+3 R	+2 L	+1 R	0 L	0 R	0 L
6	+4 R	+4 L	+2 R	+2 L	0 R	0 L	0 R	0 L
7	+3 R	+3 L	+2 R	+2 L	0 R	0 L	0 R	0 L
8	+3 R	+3 L	+2 R	+2 L	0 R	0 L	0 R	0 L
9	+4 R	+4 L	+2 R	+2 L	0 R	0 L	0 R	0 L
10	+3 R	+3 L	+1 R	+1 L	0 R	0 L	0 R	0 L

Postoperative 1<sup>st</sup> (Fig. 1b) and 3rd month (Fig. 1c) examinations, values of NO angles in all cases were found to be increased; i.e. the hip joint laxity of the cases was decreased. In the postoperative 6<sup>th</sup> month (Fig. 1d), values of NO angles in all cases continued to increase, and these values were found to range from 104 to 108 degrees. The hip joint accommodation of the cases turned out to normal (Table 5).

Pre- (Fig. 2a) and postoperative radiological examinations of the cases, values of DI measured on distracted pelvic radiographs were as follows: Normal (smaller than 0.30), light laxity (0.30-0.49), moderate laxity (0.50-0.69) and severe laxity (higher than 0.70). According to this scale, pre-operative DI values of all cases were higher than 0.30 indicating that increased hip laxity with DJD formation risk. The risk was higher for cases 2, 3, 4 and 5 which had moderate laxity in the hip joint. In the postoperative 1<sup>st</sup> (Fig. 2b), 3<sup>rd</sup> (Fig. 2c) and 6<sup>th</sup> months (Fig. 2d), the measured DI values were found to be gradually decreased. In the final examination, DI values in 5 cases were found to be below 0.30. Following JPS intervention, HD of these cases was absent, and they were negative in terms of HD with normal hip structure.

Four cases had DI values of 0.32 to 0.45. In spite of having a minimal DJD risk, these cases had light hip joint laxity. However, case # 5 was preoperatively in borderline severity in terms of hip laxity. Even though the severity of hip laxity was reduced following the JPS intervention, case # 5 had higher DJD risk compared to the other cases (Table 6).

During the JPS surgery, the abdominal organs such as rectum and urethra were protected to prevent any thermal or iatrogenic damage. In the postoperative follow-ups, no complication was encountered in urination and defecation, and there was no lameness and pain in the cases. Following JPS intervention, no morbidity was observed in urinary, intestinal and hip functions. In addition, no complication was observed in the operational area of the cases, and the incision scar was healed as expected on the 10<sup>th</sup> day of postoperative period.

There were some gait abnormalities, abnormal reactions to pain stimulation in hip range of motion in the pre-operative findings of the cases. In the follow up examinations following JPS procedure, the gait

**Table 4.** Pre- and postoperative Barden sign outcomes of cases (L Left, R Right)

**Tablo 4.** Olguların pre ve postoperatif Barden testi sonuçları (L Sol, R Sağ)

Case No	Preoperative		Postoperative 1st Month		Postoperative 3rd Month		Postoperative 6th Month	
	R	L	R	L	R	L	R	L
1	+3 R	+3 L	+2 R	+2 L	0 R	0 L	0 R	0 L
2	+4 R	+3 L	+3 R	+2 L	+1 R	0 L	0 R	0 L
3	+4 R	+4 L	+2 R	+2 L	0 R	+1 L	0 R	0 L
4	+3 R	+3 L	+2 R	+2 L	0 R	0 L	0 R	0 L
5	+4 R	+3 L	+3 R	+2 L	+1 R	0 L	0 R	0 L
6	+4 R	+4 L	+2 R	+2 L	0 R	0 L	0 R	0 L
7	+3 R	+3 L	+2 R	+2 L	0 R	0 L	0 R	0 L
8	+3 R	+3 L	+2 R	+2 L	0 R	0 L	0 R	0 L
9	+4 R	+4 L	+2 R	+2 L	0 R	0 L	0 R	0 L
10	+3 R	+3 L	+1 R	+1 L	0 R	0 L	0 R	0 L

**Table 5.** Pre- and postoperative Norberg Olsson (NO) Angles outcomes of cases (L Left, R Right)

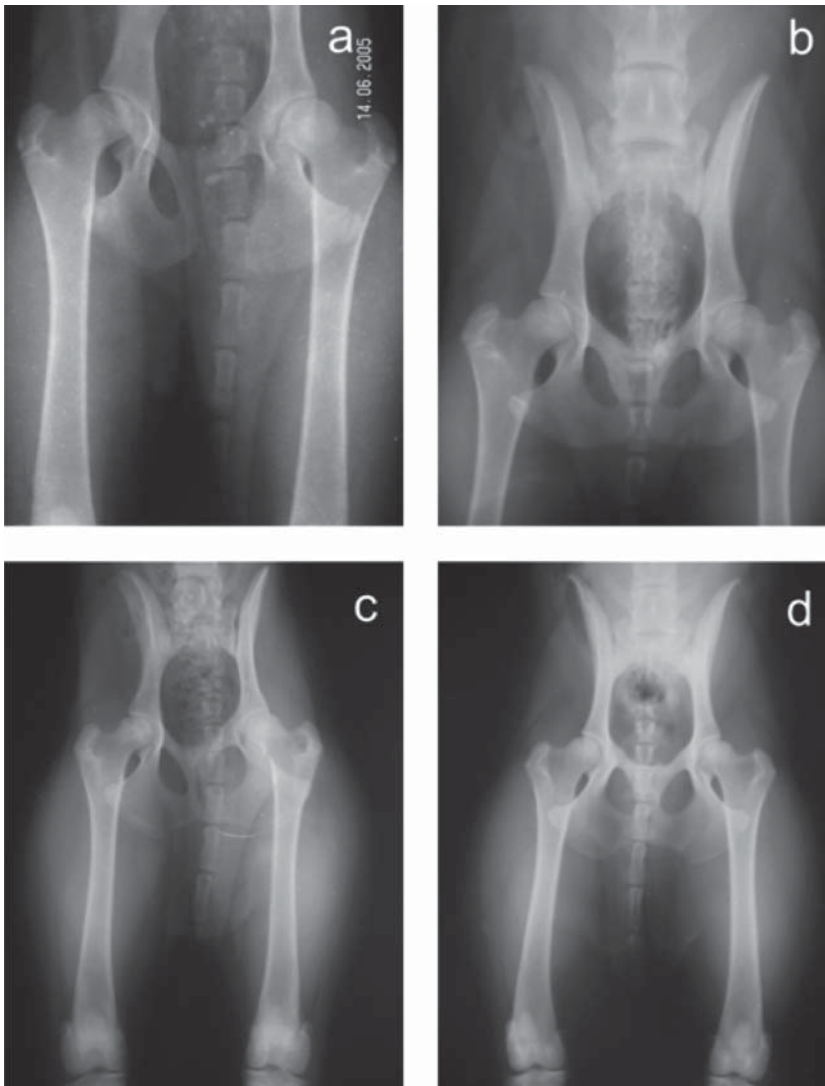
**Tablo 5.** Olguların pre ve postoperatif Norberg Olsson (NO) açısı sonuçları (L Sol, R Sağ)

Case No	Preoperative NO Angle		Postoperative NO Angle (1st Month)		Postoperatif NO Angle (3rd Month)		Postoperative NO Angle (6th Month)	
	R	L	R	L	R	L	R	L
1	100° R	98° L	102° R	100° L	106° R	104° L	106° R	104° L
2	98° R	98° L	100° R	100° L	104° R	104° L	104° R	104° L
3	96° R	100° L	100° R	102° L	106° R	105° L	106° R	105° L
4	98° R	100° L	100° R	102° L	105° R	105° L	105° R	105° L
5	100° R	100° L	102° R	102° L	104° R	104° L	98° R	100° L
6	102° R	98° L	102° R	100° L	106° R	106° L	106° R	106° L
7	96° R	94° L	98° R	96° L	106° R	106° L	106° R	106° L
8	93° R	95° L	96° R	98° L	100° R	103° L	105° R	108° L
9	90° R	93° L	96° R	98° L	104° R	105° L	105° R	106° L
10	92° R	93° L	100° R	100° L	102° R	105° L	105° R	108° L

**Table 6.** Pre- and postoperative Distraction Index (DI) outcomes of cases (L Left, R Right)

**Tablo 6.** Olguların pre ve postoperatif Distraksiyon İndeksi (DI) sonuçları (L Sol, R Sağ)

Case No	Pre-operative DI		Postoperative DI (1st Month)		Postoperative DI (3rd Month)		Postoperative DI (6th Month)	
	R	L	R	L	R	L	R	L
1	0.45 R	0.50 L	0.42 R	0.46 L	0.37 R	0.38 L	0.32 R	0.33 L
2	0.50 R	0.50 L	0.44 R	0.42 L	0.35 R	0.38 L	0.32 R	0.35 L
3	0.55 R	0.57 L	0.49 R	0.49 L	0.45 R	0.40 L	0.37 R	0.35 L
4	0.65 R	0.60 L	0.60 R	0.55 L	0.50 R	0.50 L	0.48 R	0.45 L
5	0.64 R	0.63 L	0.58 R	0.55 L	0.52 R	0.46 L	0.50 R	0.34 L
6	0.45 R	0.45 L	0.38 R	0.38 L	0.29 R	0.32 L	0.25 R	0.28 L
7	0.45 R	0.42 L	0.35 R	0.37 L	0.25 R	0.28 L	0.22 R	0.24 L
8	0.45 R	0.36 L	0.49 R	0.22 L	0.44 R	0.17 L	0.07 R	0.05 L
9	0.34 R	0.34 L	0.30 R	0.30 L	0.26 R	0.28 L	0.20 R	0.20 L
10	0.38 R	0.32 L	0.33 R	0.30 L	0.26 R	0.28 L	0.23 R	0.20 L



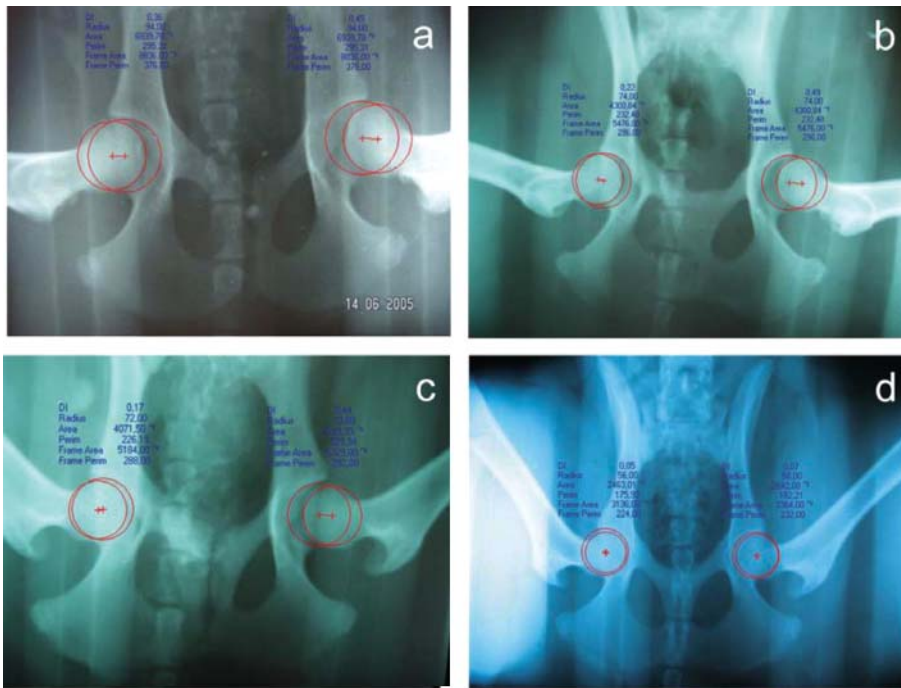
**Fig 1.** Pre- and postoperative ventrodorsal extended radiological views of case no: 8 (a: preoperative, b: postoperative 1<sup>st</sup> month, c: postoperative 3<sup>rd</sup> month, d: postoperative 6<sup>th</sup> month).

**Şekil 1.** Olgu no: 8'e ait pre- ve postoperatif ekstensiyonda ventrodorsal radyografik görünüm (a: preoperative, b: postoperatif 1. ay, c: postoperatif 3. ay, d: postoperatif 6. ay)

characteristics ameliorated and showed normal reactions to range of motions. During the hip extension tests, the joint capsule of the femoral neck was stretched out that gives a positive response if dorsal joint capsule is healed

by fibrosis. By this means, pain scoring can be performed. While all cases gave a positive response to pain before the surgery, no pain was observed in the cases in postoperative 6<sup>th</sup> month examination.





**Fig 2.** Pre- and postoperative distracted radiological views of case no: 8 (a: preoperative, b: postoperative 1<sup>st</sup> month, c: postoperative 3<sup>rd</sup> month, d: postoperative 6<sup>th</sup> month).

**Şekil 2.** Olgu no: 8'e ait pre- ve postoperatif distraksiyon radyografik görünümü (a: preoperative, b: postoperatif 1. ay, c: postoperatif 3. ay, d: postoperatif 6. ay)

The outcome of hip extension test indicates that JPS procedure relieved the hip joint movement and removed the pain. A positive Ortolani test shows that hip joint capsule is stretched out indicating the hip joint laxity which is secondary to HD. While preoperative Ortolani palpation test was negative in all cases, the findings from Ortolani palpation test returned to negative in the postoperative 6<sup>th</sup> month examination. The Barden palpation test which is used to evaluate HD was negative in all cases in the preoperative period, but the findings of Barden palpation test were found to be negative in the postoperative 6<sup>th</sup> month.

Due to the reduced hip joint laxity which allowed the hip joint accommodation, the cases had a normal hip structure following the JPS procedure. Norberg Olsson angles were measured on standard V/D pelvis radiographs to evaluate accommodation between caput femoris and acetabulum as well as to find out presence of hip joint laxity. Decreased NO angles measured preoperatively were an indicator of hip joint laxity. Values of angles in the postoperative 6<sup>th</sup> month were increased in all cases indicating the reduced hip joint laxity as a result of coxofemoral conformity following JPS operation. Distraction index measured on the distracted pelvic views is a good indicator of passive hip joint laxity and predictor of DJD risk. High DI values in all cases before the surgery imply the risk of hip joint laxity and DJD. Postoperative DI values were found to be decreased on the 6<sup>th</sup> month. Since DI values of 5 cases were close to the normal values, the success rate was high. Following JPS surgery, DI values in these 5 cases were reduced to below 0.30, and risk of hip joint laxity and DJD was removed. For the remaining 5 cases, since no sufficient improvement was provided following JPS procedure, risk of DJD were still present in spite of reduced hip laxity.

## DISCUSSION

The epiphyseal growth plate of the pubic symphysis is normally closed at 9-10 months of age. Early closing of epiphyseal growth plate of the pubic symphysis in immature 3-6 month-old cases which are potentially predisposed to HD is important for pelvic and acetabular development <sup>4,27</sup>. In this study, JPS application was performed on 10 cases (aged between 3-5 months old) with signs of HD. Following the outcomes, and previous researches that JPS is a successful technique in the treatment of HD which affects the development of the pelvis and acetabulum.

The epiphysial growth plates of the pubic symphysis play an important role in the development of pelvis and help in the formation of acetabular position. Electrocauter applied during JPS caused thermal necrosis in the germinal chondrocytes of epiphysial growth plates of the pubic symphysis. Hence, the epiphysial growth plate is early closed and the bones weld each other whereby growth of the pubic symphysis is prevented. While the growth of pelvis continues in dorsolateral direction, the pelvis becomes narrow and short in ventromedial direction <sup>2,4,11,14,25</sup>. In this study, JPS was applied using electrocauter in minimal dose and duration (40W, 12-30 sec.) as described <sup>26</sup> where in this dose and duration electrocauter was able to provide thermal necrosis in germinal chondrocytes of epiphysial growth plates of symphysis pubis in cases. Due to early closing of epiphysial growth plate, growth of the pubic symphysis was prevented, and the caudal side of pelvis was made narrow. This situation was demonstrated on radiographs taken from standard V/D distracted pelvic views during the postoperative examinations.

Factors affecting joint stabilization play important roles in the pathogenesis of HD, whereas the pathogenesis of OA depends on abnormal biomechanical forces resulting from disorders in joint stabilization. Factors affecting hip joint stability include bone fusions due to variable source of ossification, soft tissues supporting the joint (round ligament, joint capsule, synovia, gracilis muscle, pectineus muscle and pelvic muscles including adductor and obturator muscles) and biomechanical forces affecting the joint (such as body weight etc.). These biomechanical forces cause the femoral head to be pushed towards acetabular cavity<sup>1,4,24</sup>. By altering the biomechanics of the hip joint and increasing the tension in periarticular soft tissues, JPS creates a pulling force which causes ventro-lateral axial rotation of the dorsal rim of acetabulum. The increased DI due to passive hip joint laxity is reduced. Decreased DI results in an increase in acetabular ventroversion angle. Acetabulum rotates ventrolaterally on the caput femoris and turns to outside where caudal pelvis becomes narrow. Acetabulum fully covers the femoral head which provides a contact leading to a reduction in hip joint reaction force. By increasing the hip joint stabilization, development of HD is prevented. The reduction in the hip joint laxity prevents femoral head from excessive movement within the acetabulum. In addition, secondary OA formation could be also prevented since the structures associated with the joint are protected, and hip joint accommodation is improved. JPS has also some beneficiary effects on the orientation of acetabulum. By increasing the acetabular filling and reducing the shallowness, covering of caput femoris by acetabulum is increased<sup>1,2,4,11,12,14,22,24,25</sup>.

In this study, preoperative DI values of all cases were high; thus all cases had passive hip joint laxity which is a good predictor of HD development. Following JPS procedure, acetabulum underwent outward rotation and better holds the femoral head in the cases. Consequently, hip joint laxity was decreased, and DI values of the cases were decreased allowing the amelioration of hip joint accommodation.

A negative result was obtained from the Ortolani palpation test following JPS. This finding indicates that tension of joint capsule and hip joint laxity were reduced without luxation in the femoral head<sup>1,2,4,11,12,14,22,24,25</sup>. In this study, while the preoperative results of Ortolani palpation test were positive in all cases, the results were observed to be negative following JPS at 6<sup>th</sup> month follow-up. In addition, preoperative Barden palpation test, which is a diagnostic test for HD, was positive in all cases, the results of the test were found to be negative at postoperative 6<sup>th</sup> month control.

The increase in NO angle measurements following JPS shows a reduction in hip joint laxity and indicates the correction in accommodation between the femoral head and acetabulum<sup>1,2,4,11,12,14,22,24,25</sup>. The preoperative measurements of NO angles were low, but there was an

increase in each case and within the normal limits after JPS procedure at the 6<sup>th</sup> month follow-up.

Pain, mobility difficulties, muscle atrophy as well as signs of lameness due to DJD were decreased following JPS which prevents the development of HD and allows the hip joint accommodation<sup>1,4,11,12,14,22,24,25</sup>. In this study, preoperatively observed signs of DJD resulting from HD (pain and lameness) disappeared in all cases following JPS. Although the positive effects of JPS were hindered in some of cases which had severe passive hip joint laxity preoperatively, the laxity observed in these cases was significantly reduced. On the other hand, risk of DJD in these cases could not be removed.

The optimal dose and duration of electrocauter for the cauterization of the pubic symphysis was studied<sup>26</sup> in JPS applied cases. The authors reported that as a complication, there was a collection of serosity which leads to the formation of "seroma" in the operational area in all cases. However, the seroma disappeared within 3-5 days. In addition, intraabdominal organs such as urethra and rectum can be injured, and this type of iatrogenic damage should be taken into consideration during JPS surgery<sup>4,11,16,19,22-25,27</sup>. In the current study, intraabdominal organs were protected from thermal or iatrogenic injury, and no complication was observed following JPS. In addition, other complications such as infection, serosity or edema were not encountered postoperatively.

Although there might be an important and continued decrease in the diameter of pelvis due to shortness and narrowness in the caudal pelvis, no postoperative morbidity risk was reported following JPS. Although reduction in pelvic entrance due to reduction in pelvic diameter is desired for JPS, the reduction could result in constipation, tenesmus and stranguria. However, these types of complications were not reported in related studies. In addition, the reduction in pelvic entrance could make female cases predisposed to difficult delivery. Due to risk of difficult delivery and hereditary nature of HD, sterilization of these cases is recommended<sup>4,11,16,19,22-25,27,28</sup>. No complication was observed due to reduction in pelvic entrance in our cases. All cases had normal urination and defecation functions. The owners of the cases were informed for risk of difficult delivery and hereditary nature of HD. Only one dog was sterilized upon the consent of the owner.

Based on findings of this study, it could be concluded that JPS can be successfully performed in young dogs (at 3-4 months of age) who did not complete the skeletal growth and having the symptoms of HD or predisposed to HD. Using specific diagnostic methods, JPS could be applied for prophylaxis and treatment of HD. In this way, increased post-operative complications, high risk of morbidity seen in other costly surgical methods can be avoided by JPS.

## REFERENCES

1. **Bilgili H:** Developmental canine hip and elbow dysplasia course and Workshop, pp. 7-39, Ankara, 23rd-25th May, 2003.
2. **Captug O, Bilgili H:** Current approaches of canine hip dysplasia. Part I: Etiology and pathogenesis of canine hip dysplasia. *J Fac Vet Med Univ Erciyes*, 3, 123-128, 2006.
3. **Captug O, Bilgili H:** Current approaches of canine hip dysplasia. Part II: Clinical diagnosis of canine hip dysplasia. *J Fac Vet Med Univ Erciyes*, 4, 35-42, 2007.
4. **Ozdemir G, Captug O, Bilgili H:** Juvenile pubic symphysiodesis technique in hip dysplastic puppies. *Turk J Vet Surg*, 12, 73-80, 2006.
5. **Captug O, Bilgili H:** Can early diagnosis of canine hip dysplasia be possible? *J Turk Vet Med Assoc*, 77, 22-25, 2006.
6. **Lust G:** An overview of the pathogenesis of canine hip dysplasia. *J Am Vet Med Assoc*, 210, 1443-1445, 1997.
7. **Popovitch CA, Smith GK, Gregor TP, Shofer FS:** Comparison of susceptibility for hip dysplasia between rottweilers and german shepherd cases. *J Am Vet Med Assoc*, 206, 648-650, 1995.
8. **Todhunter RJ, Lust G:** Hip dysplasia in cases, pathogenesis. In: Slatter DH (Ed): Textbook of Small Animal Surgery. 2009-2017, Saunders Co, Philadelphia, 2002.
9. **Kealy RD, Olsson SE, Monti KL, Lawler DF, Biery DN, Helms RW, Lust G, Smith GK:** Effects of limited food consumption on incidence of hip dysplasia in growing cases. *J Am Vet Med Assoc*, 201, 857-863, 1992.
10. **Leighton EA:** Genetics of canine hip dysplasia. *J Am Vet Med Assoc*, 210, 1474-1479, 1997.
11. **Madsen JS:** The joint capsule and joint laxity in cases with hip dysplasia. *J Am Vet Med Assoc*, 210, 1463-1465, 1997.
12. **Smith GK:** Advances in diagnosing canine hip dysplasia. *J Am Vet Med Assoc*, 210, 1451-1457, 1997.
13. **Adams WM:** Radiographic diagnosis of hip dysplasia in the young dog. *J Small Anim Pract*, 30, 267-279, 2000.
14. **Fries CL, Remedios AM:** Pathogenesis and diagnosis of canine hip dysplasia: A review. *Can Vet J*, 36, 494-502, 1995.
15. **Fluckiger MA, Friedrich GA, Binder H:** A radiographic stress technique for evaluation of coxofemoral joint laxity in cases. *Vet Surg*, 28, 1-9, 1999.
16. **Patricelli AJ, Dueland RT, Adams WM, Fialkowski JP, Nordheim EV:** Juvenile pubic symphysiodesis on dysplastic puppies at 15 and 20 weeks of age. *Vet Surg*, 31, 435-444, 2002.
17. **Saunders JH, Godefroid T, Snaps FR, Francois A, Farnir F, Balligand M:** Comparison of ventrodorsal and dorsoventral radiographic projections for hip dysplasia diagnosis. *Vet Rec*, 45, 109-110, 1999.
18. **Prieur WD:** Intertrochanteric osteotomy. In, Bojrab MJ (Ed): Current Techniques in Small Animal Surgery. pp. 1165-1168, Williams and Wilkins, Baltimore, 1997.
19. **Schulz KS, Dejardin LM:** Intertrochanteric osteotomy In, Slatter DH (Ed): Textbook of Small Animal Surgery. pp. 2033-2056, Saunders Co, Philadelphia, 2002.
20. **Slocum B, Slocum TD:** Hip. In, Bojrab MJ (Ed): Current Techniques in Small Animal Surgery. pp. 1127-1153, Williams and Wilkins, Baltimore, 1997.
21. **Vasseur PB:** Femoral head and neck osteotomy. In, Bojrab MJ (Ed): Current Techniques in Small Animal Surgery. pp. 1170-1173, Williams and Wilkins, Baltimore, 1997.
22. **Dueland RT, Mathews KG, Adams WM:** Effect of Age-Sequenced Pubic Symphysiodesis in Dysplastic Puppies. *8<sup>th</sup> Annual ACVS Veterinary Symposium*, p. 3, Chicago, 08<sup>th</sup>-11<sup>th</sup> October, 1998.
23. **Dueland RT, Adams WM, Fialkowski JP, Patricelli AJ, Mathews KG, Norheim EV:** Effect of pubic symphysiodesis in dysplastic puppies. *Vet Surg*, 30, 201-217, 2001.
24. **Dueland RT, Patricelli AJ, Adams WM, Hayashi K:** Juvenile pubic symphysiodesis in dysplastic puppies. *1<sup>st</sup> World Orthopaedic Veterinary Congress*, pp. 101-102, Munich, 05<sup>th</sup>-08<sup>th</sup> September, 2002.
25. **Mathews KG, Stover SM, Kass PH:** Effect of pubic symphysiodesis on acetabular rotation and pelvic development in guinea pigs. *Am J Vet Res*, 57, 1427-1433, 1996.
26. **Patricelli AJ, Dueland RT, Lu Y, Fialkowski JP, Mathews KG:** Canine pubic symphysiodesis, investigation of electrocouter dose response by histologic examination and temperature measurement. *Vet Surg*, 30, 261-268, 2001.
27. **Swainson SW, Conzemius MG, Riedsel EA, Smith GK, Riley CB:** Effect of pubic symphysiodesis on pelvic development in the skeletally immature Greyhound. *Vet Surg*, 29, 178-190, 2000.
28. **Vezzoni A, Magni G, De Lorenzi M, Pisani G:** Pubic Symphysiodesis Clinical Experiences. *1<sup>st</sup> World Orthopaedic Veterinary Congress*, pp. 204-207, Munich, 05<sup>th</sup>-08<sup>th</sup> September, 2002.
29. **Piermattei DL, Johnson KA:** Atlas of Surgical Approaches to The Bones of The Dog and Cat. pp. 322-325, Saunders Co, Philadelphia, 2004.