

Vaginal Leiomyosarcoma in A Holstein Cow

Sinem Özlem ENGİNLER * 
Adem ŞENÜNVER *

Mehmet Can GÜNDÜZ *
Funda YILDIZ **

Ahmet SABUNCU *
Serdar Seçkin ARUN **

* İstanbul Üniversitesi Veteriner Fakültesi, Doğum ve Jinekoloji Anabilim Dalı, TR-34320 Avcılar, İstanbul - TÜRKİYE
** İstanbul Üniversitesi Veteriner Fakültesi, Patoloji Anabilim Dalı, TR-34320 Avcılar, İstanbul - TÜRKİYE

Makale Kodu (Article Code): KVFD-2010-2918

Summary

Vaginal leiomyosarcoma was clinically, histopathologically and immunohisto-chemically detected in a 4 year old Holstein cow in this case. The mass was extirpated and no recurrence was observed in the vagina at 12 months follow up. The cow was artificially inseminated and became pregnant after the surgery.

Keywords: *Leiomyosarcoma, Immunohistochemistry, Vagina, Cow*

Holstein Irkı Bir İnekte Vaginal Leiomyosarkoma Olgusu

Özet

Bu makalede 4 yaşlı Holstein ırkı bir inekte rastlanılan vaginal leiomyosarkoma olgusu klinik, histopatolojik ve immunohistokimyasal olarak değerlendirilmiştir. Kitle cerrahi olarak uzaklaştırılmıştır ve 12 aylık takipte nüks gözlenmemiştir. Cerrahi girişimin ardından ineğe sun'i tohumlama uygulanmış ve gebelik elde edilmiştir.

Anahtar sözcükler: *Leiomyosarkoma, İmmunohistokimya, Vagina, İnek*

INTRODUCTION

Leiomyosarcomas are quite rare among genital system tumors ¹. Also, genital system tumors are seldom observed in cows. It was established that 10-50% of such tumors originated from smooth muscles and, among them, approximately 10% were considered malignant. Leiomyosarcomas exhibit low malignancy with slow invasion and rare metastasis in cows ². Leiomyomas must be discerned from leiomyosarcomas from a histological viewpoint ³. Genital leiomyosarcomas were previously detected in vagina of pregnant women and pregnant dairy cattle, uterus and cervix of goats, uterus of sheep, vagina and vulva of bitches, vulva of cats ^{1,2,4-7}. The incidence of tumors over a 10-year period in Israel in dairy cattle (n=1100) is reported as squamous cell carcinoma in the vulva (10 cases), leiomyoma (1 case), fibroma (3 cases), haemangioma (1 case), fibropapilloma (1 case), melanoma (1 case) and leiomyosarcoma (1 case). However, the same incidence is reported in beef cattle (n = 1300) as squamous cell carcinoma in the vulva (5 cases),

melanoma (1 case) and fibroma (1 case) in the vagina ³. In a retrospective search, bovine genital neoplasms were observed during a total of 17.896 bovine accessions, 5 cases (0.03% incidence) were found originated from smooth muscle. Among them, one was diagnosed as leiomyosarcoma and the incidence was 0.006% ⁷.

CASE HISTORY

A 4 year old Holstein cow was presented at the Faculty of Veterinary Medicine Department of Obstetrics and Gynaecology in Istanbul University. Although she experienced dystocia during her initial parturition, no abnormalities were encountered during the artificial insemination performed two months postpartum. The cow underwent dystocia once again during her second parturition and the mass was identified this time by the owner. The general condition of the cow was found to be



İletişim (Correspondence)



+90 212 4737070/17322



soapaydin@hotmail.com

normal at the clinical examination. There was no distinct lesion at the vulva. The mass was found to measure 5.2x8.3 cm at the vaginal examination (Fig. 1A and 1B). The mass was projecting with a short stalk from the dorsal of the vagina and was a vivid, dark pink color and amorphous. There was no ulcerative region and hemorrhage on the surface of the mass, and also it was solid, rough, and firm with a white color at the cross-section (Fig. 1C). After the ligation of large vessels, the mass was excised under epidural anesthesia by using electro cauterization.

Amoxicillin and clavulanic acid (Synulox®, Pfizer, Italy) and B complex vitamine (Berovit B₁₂ flc®; Roche, Sweden) were administered intramuscularly to the cow for 7 days as postoperative care.

The tissue was placed in 10% neutral buffered formalin and submitted for histopathology and immunohistochemistry. The specimen that was presented to the Department of Pathology was initially fixed in 10% formalin solution, routinely processed and then stained with hematoxylin and eosin (H&E) and evaluated under

light microscopy. Immunohistochemistry (IHC) was performed on paraffin sections according to the avidin-biotin-peroxidase complex method using antibodies smooth muscle actin, Ab-1 (1A4) mouse MAb (Neomarkers, Fremont, CA) and pancytokeratin Ab-1 (AE1+AE3) mouse MAb (Neomarkers, Fremont, CA). Avidin-biotin-peroxidase staining kit was used for labeling and the reaction product was visualized with 3,3'-diaminobenzidine chromagen (Histostain-Kit, Invitrogen, Camarillo, CA) and the sections were counter-stained with 0.1% hematoxylin (Labvision Corporation, Fremont, CA), dehydrated and mounted.

Histologically, the mass was encapsulated and poorly demarcated at the surgical border, with variable cellularity ranging from densely packed spindle cells arranged in interwoven short fascicles to loosely spaced spindle cells separated by amorphous matrix (Fig. 2). Cells displayed eosinophilic cytoplasm with occasional small clear cytoplasmic vacuoles and a moderately large central cigar-shaped nucleus containing finely stippled chromatin

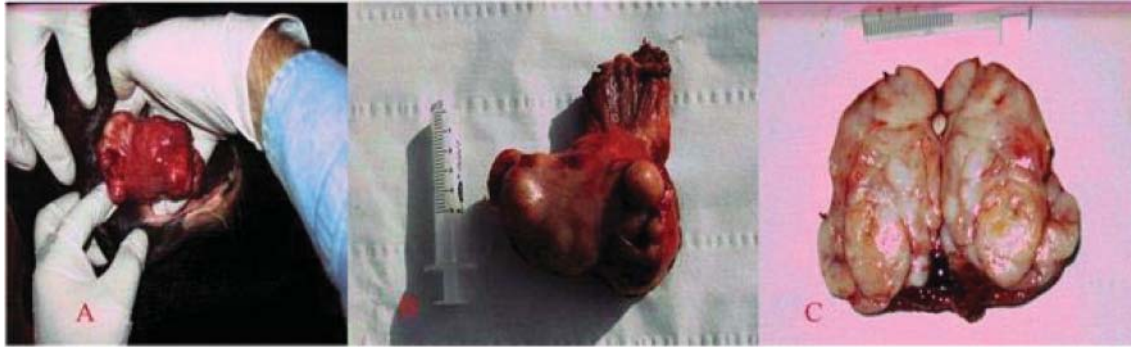


Fig 1. Vaginal mass before surgery (A), The extirpated mass (B) and The cut surface of the mass (C)
Şekil 1. Cerrahi girişim öncesi vaginal kitle (A), Ekstirpe edilmiş kitle (B) ve Kitlenin kesit yüzeyi (C)

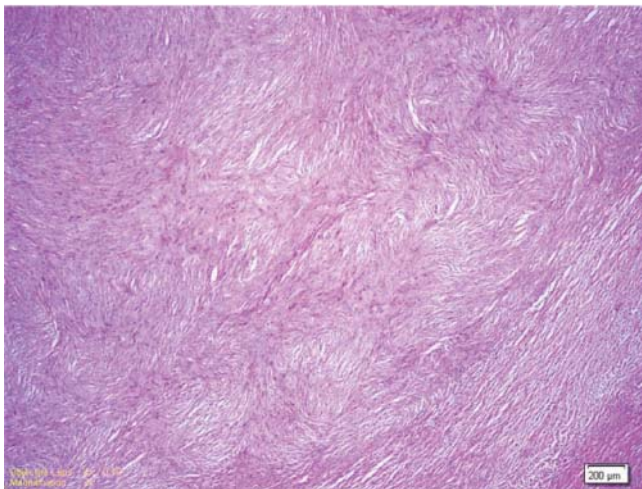


Fig 2. Spindle cells arranged in interwoven short fascicles, H&E, 200 µm

Şekil 2. Birbirleri ile kesişen kas fasikülleri şeklinde organize olmuş mekiksi çekirdekli hücreler, H&E, 200 µm

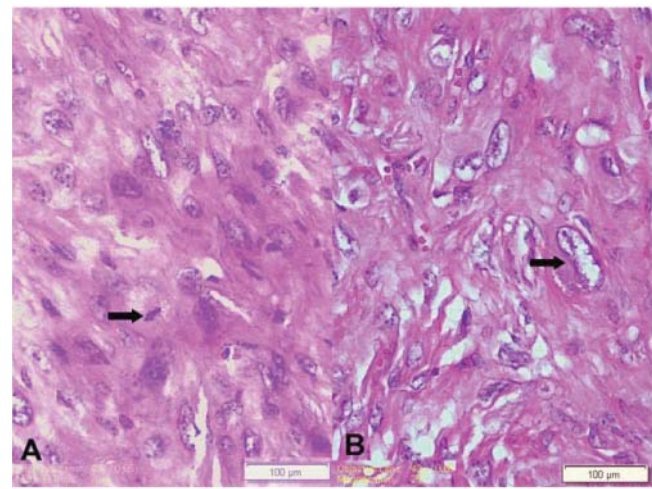


Fig 3. Atypical spindle cells, mitotic figure (arrow) H&E, 100 µm (A), Nuclear atypia, karyomegaly (arrow), H&E, 100 µm (B)

Şekil 3. Atipik mekik hücreler, mitotik figür (ok) H&E, 100 µm (A), Nükleer atipi, karyomegali (ok), H&E, 100 µm (B)

(Fig 3A, 3B). There was moderate to marked nuclear atypia present, with frequent karyomegaly (Fig. 3B). The mitotic index ranged from 1 to 5 per high power field, with an average of 1-2 per 400 high power field (HPF) (Fig. 3A). It was histopathologically concluded that the entity is a leiomyosarcoma. As the neoplastic cells were positive for a-smooth muscle actin (Fig. 4) and negative for negative control of actin (Fig. 5A) and pancytokeratin (Fig. 5B), it was confirmed as leiomyosarcoma also from an immunohistochemical viewpoint.

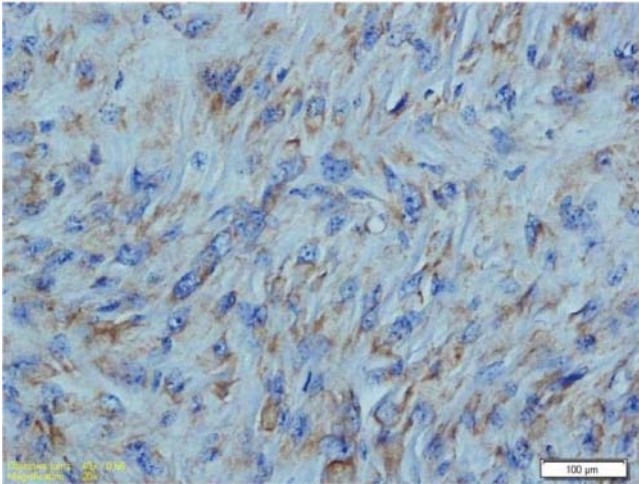


Fig 4. Positive staining with actin antibody, IHC, 100 µm

Şekil 4. Aktin antikoru ile pozitif boyama, IHC, 100 µm

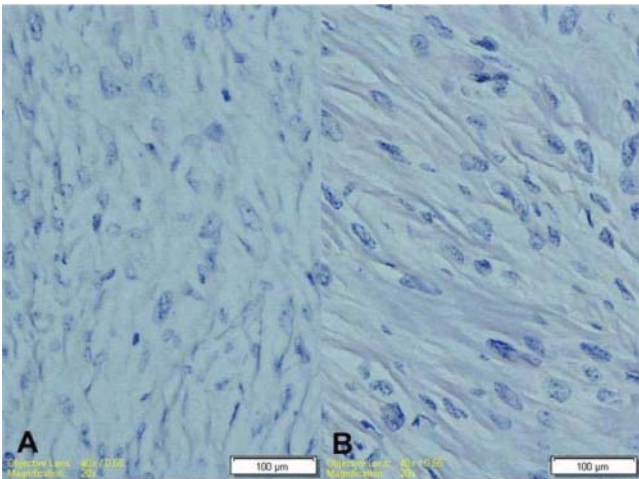


Fig 5. Negative control tissue for actin antibody, IHC, 100 µm (A), Negative staining for pancytokeratin antibody, IHC, 100 µm (B)

Şekil 5. Aktin antikoru için negatif kontrol dokusu, IHC, 100 µm (A), Pansitokeratin antikoru için negative boyama, IHC, 100 µm (B)

DISCUSSION

Anderson and Sandison⁸ reported as a result of a one-year survey that none of the studied 302 cows with neoplasia was diagnosed with vaginal leiomyosarcoma. Only two leiomyosarcomas in the uterus that were metastasized to lung, lymph node and liver was reported by the same researchers in the cattle.

Genital leiomyosarcoma is most common in dogs and there is no evident breed predisposition. Spleen metastasis was reported in a dog. Also genital smooth muscle tumors are reported commonly in goats and especially in Saanen goats¹.

Yeruham et al.³ reported only one vaginal leiomyosarcoma from 1.100 dairy and 1.300 beef cattle in Israel over a 10-year period. They also reported that vaginal leiomyosarcomas are seen infrequently in cows. In previous reports it is reported that stalk tumors can cause dystocia⁹. Dystocia was observed in both parturitions and the reason of the second dystocia was thought to be due to the mass.

In conclusion at the end of the twelve months follow up there was no recurrence in the vagina and no symptoms associated to metastasis in this case were observed. The cow was artificially inseminated and became pregnant after the surgery.

REFERENCES

1. Cooper BJ, Valentine BA: Tumours of Muscle. In, Meuten DJ (Ed): Tumours in Domestic Animals. 4th ed., pp. 319-363, Iowa State Press, A Blackwell Publishing Company, 2121 State Avenue, Ames, IA 50014, USA, 2002.
2. Hossein N, Iraj K, Bonyadian, M: Vaginal leiomyosarcoma in a pregnant dairy cow. *ESVP/ECVP Proceedings*, 141 (4): 301, 2009.
3. Yeruham I, Perl S, Orgad U, Yakobson, B: Tumours of the vulva and vagina in cattle- A 10-year survey. *TVJ*, 158, 237-239, 1999.
4. Behzatoğlu K, Bahadır B, İnhan G, Altuğ, M: Primary vaginal leiomyosarcoma in pregnancy. *Gynecologic Oncology*, 91, 627-629, 2003.
5. Firat I, Haktanir-Yatkin D, Sontas BH, Ekici H: Vulvar leiomyosarcoma in a cat. *J Feline Med Surg*, 9, 435-438, 2007.
6. Vemireddi V, Langohr IM, Thacker HL: Polypoid uterine leiomyosarcomas in a sheep. *J Vet Diag Invest*, 19, 309-312, 2007.
7. Whitney KM, Valentine BA, Schlafer DH: Caprine genital leiomyosarcoma. *Vet Pathol*, 37, 89-94, 2000.
8. Anderson LJ, Sandison AT: Tumours of the female genitalia in cattle, sheep and pigs found in a British Abbottoir survey. *J Comp Path*, 79, 53-63, 1969.
9. Çolak A, Sağlam YS, Kamiloğlu A, Karaman M: Bir inekte rastladığımız vaginal tümör olgusu. *Kafkas Univ Vet Fak Derg*, 3 (1): 93-96, 1997.