

Electroretinographic Evaluation of Photoreceptor Cells in Turkish Shepherd Dogs ^[1]

Murat ŞAROĞLU *  Aslı BAŞOĞULLARI EKİCİ *

[1] *This study is supported by TUBITAK (Turkish Scientific Research Institution) -TOVAG (Project no: 107 O 919*
* İstanbul Üniversitesi Veteriner Fakültesi, Cerrahi Anabilim Dalı, TR-34320 Avcılar, İstanbul - TÜRKİYE

Makale Kodu (Article Code): KVFD-2010-2101

Summary

In this study, the electroretinography (ERG) results which are obtained from a total of 40 eyes in 20 Turkish shepherd dogs (TSDs) which meet the standards of ISCEV were evaluated. Accordingly, amplitude of the a-wave 1.298 ± 0.208 microvolt, amplitude of the b-wave 7.670 ± 0.846 microvolt, implicit time of the a-wave 70.268 ± 11.840 milisecond, implicit time of the b-wave 97.072 ± 12.696 milisecond were determined. There is no clinical, fundusoscopic or ERG evidence of a genetic retina disorder in TSDs. The fundusoscopic and ERG datas which obtained from 10 patient in different breed which have single-or double sidedblindness revealed that the results of our study can be used as a reference value in further studies about retina in TSDs.

Keywords: *Electroretinography, Turkish Shepherd Dog, Retina, Photoreceptor cells*

Türk Çoban Köpeklerinde Retina Fotoresptör Hücrelerinin Elektoretinografik Olarak Değerlendirilmesi

Özet

Bu çalışmada 20 Türk Çoban köpeğinin (TÇK) toplam 40 gözünde, ISCEV standartlarını uygulayarak elde ettiğimiz ERG sonuçları değerlendirilmiştir. Buna göre a dalga boyu 1.298 ± 0.208 mikrovolt, b dalga boyu 7.670 ± 0.846 mikrovolt, a dalgası için implisit zamanı 70.268 ± 11.840 milisaniye, b dalgası için implisit zamanı 97.072 ± 12.696 milisaniye olarak belirlendi. TÇK'inde genetik bir retina hastalığına ilişkin, klinik, funduskopik ya da ERG'de bir belirti gözlenmemiştir. Çalışma içerisinde, tek ya da çift taraflı körlük bulunan 10 farklı ırktan klinik olgunun, funduskopik ve ERG verileri de, TÇK'inde elde ettiğimiz değerlerin, bu ırkta yapılacak retina çalışmalarında, referans değerler olarak kullanılabilceğini göstermiştir.

Anahtar sözcükler: *Elektoretinografi, Türk Çoban Köpeği, Retina, Fotoresptör hücreleri*

INTRODUCTION

The existence of hereditary retinopathy in many dog breeds has been determined up to now. Irish Setter ^{1,2}, Collie ³, miniature Schnauzer ⁴ and Alaska Malamute ^{5,6} are some of them. Retinopathies, which are seen in many other dog breeds and have clinical symptoms in different age groups, do not have a treatment method. For that reason, it is important that patients with retinopathy that have genetic transfer characteristic be excluded from production. Progressive retina atrophy (PRA) starts with night blindness and causes loss of sight during day when it develops. Ophthalmoscopic symptoms

of this disease are thinning in retinal vessels, tapetal reflex increase, and atrophy at optic nerve end in later periods. It is an undesired situation that these dogs reach to puberty and mated before these symptoms appear. Before clinical or ophthalmoscopic symptoms appear, in order to define early functional loss in the photoreceptor cells, it is important to apply ERG technique. In this way, function loss related to retinopathy in rod and con cells can be defined during the first few months and patients are excluded from the production ⁷⁻¹¹.



İletişim (Correspondence)



+90 212 4737070/17299



saroglum@istanbul.edu.tr

Parallel to the technological developments, electrodiagnostic methods that are widely used, as in the human medicine, takes its place in veterinary ophthalmology. Flash electroretinography (FERG) is the most common of these methods in veterinary ophthalmology ^{7,10-12}. In FERG technique, changes developed in electrical potential of retina can be recorded during light stimulants. This electrical potential is shaped by transcellular movement of ions such as sodium and potassium in extracellular interval ^{7,11,13-15}.

ERG is the massive answer of retina. For that reason, in local lesions that include a small area of retina, there may not be clear change in ERG answer. However, it gives important information on many diseases that cause function deformities ranging from photoreceptor cells of retina to bipolar cells ^{7,11,12,14,16}. For that reason, it is mostly used for the diagnosis of neurosensoric retinal diseases ¹².

Progressive retinal atrophy (PRA) that can develop in many dog breeds is a genetic disease, has no treatment and the development of the disease can not be stopped. The only way to decrease the incidence of the disease is that to exclude the patients with PRA from the gene pool ^{8,15}. For example, typical ophthalmoscopic clinical symptoms of the disease in Poodles can be seen between the ages of 3 and 5. Before this disease is diagnosed it strengthens the possibility of puppy production. Whereas, when they are 8-9 months old, with ERG, increase in implicit time and abnormal darkness adaptation line can be defined and this proves that there is malfunction in rod cells. This case provides opportunity for early diagnose and extraction of patients with PRA from the process in ideal time ¹⁷. From this point of view, ERG technique plays an important role in the diagnosis of hereditary generalized PRA ^{1,2,7,10,15,17-22}.

ERG also provides important information on the diagnosis of sudden acquired retinal degeneration in dogs. Clinical symptoms of this disease are acute blindness and the fact that dilated pupil do not react to light. The image of retina in ophthalmoscopic examination is normal ⁸. Along with this, in some situations that the eye ground can not be examined such as cataract, hypohema and cornea edema, ERG is the only objective method to understand whether retina is functional or not ^{7,10,11,14,15,22}.

In traces obtained with FERG, negative diversion called as *a* current in the beginning, and after that positive diversion current called *b* is observed. Normally, many small waves appeared on the arms of *b* wave are called as oscillatory potential. In addition to these, there are early receptor potential *c* and *d* waves that are only obtained

under lab conditions ^{10,11,14,16,23}. Oscillatory potentials are best defined in dark adaptations ²³. They take root form inner retina. In order to comment on the waves obtained from ERG trace, they are compared to criteria called latency and amplitude. Latency is the period that starts from the time the waves is given till to the peak of the wave. The unit of latency is millisecond (ms). Amplitude is, for *a* wave, the value between isoelectric line and peak point of the wave. For *b* wave, the value between peak point of wave *a* and that of wave *b*. The unit of amplitude is microvolt (mV) ^{10,14}.

In order to have an ideal ERG trace in veterinary practice, it is chemically necessary to calm down the patient ^{1,7,8,10,16,21,22,24}. By this way it is possible to avoid the sounds from environment and the artifacts that can develop due to the patient's movement. In addition, patient's stress is prevented. Need for assistance by the doctor applying the technique is minimized ^{10,21,22}. For this purpose there are some studies on the effects of some anesthetic and sedative medication on ERG traces. Kommonen et al.²⁴ have stated that propofol largely used in veterinary practice today increased *b* wave with dosage increase. Yanese and Ogawa ²⁵ have stated that halothane and sevofourine anesthesia moderately decreased *b* wave amplitude, pressed scotopic edge answer clearly. Norman et al.²² have stated that medetomidine extended implicit time clearly and decreased amplitudes of *a* and *b* waves. They also stated that the changes were minimal and medetomidines can be used when needed. Kommonen and Raitta ²⁶ have stated that, ketamine-xylazine anesthesia had no clear effect on *a* and *b* waves amplitudes in normal dogs.

In a previous study carried on TSDs, fundusoscopic normal variations were examined and genetically screening in terms of retinal diseases during this study was performed ²⁷. According to the result of this study multifocal retinal dysplasia that does not lead to sight loss in TSD has been defined, however, no proof on the existence of progressive retinal atrophy has been found.

Within the time of millisecond, in electrophysiologic researches that small electrical potential records like microvolt are made, different results may be seen due to patients, situations, equipments and application differences. For that reason, it is important for every electrophysiological lab to define its normal values ^{10,28}. Our purpose within this Project is to standardize our ERG technique according to the standards of ISCEV, electroretinographically evaluate normal photoreceptor cell functions of TSDs, obtain reference numbers and meanwhile scan in terms of progressive retinal atrophy.

MATERIAL and METHODS

The material of this study consists totally 30 dogs, 20 TSD of which had no eye disorder or sight loss, 10 of which had uni or bilateral blindness. Age and sex distribution of normal TSDs were given at [Table 1](#). At [Table 2](#), breed, age, sex distributions and name of the disease that caused sight loss were given.

Information about the TSD that formed the study group was gathered on digestion and respiratory system as well as appetite, general condition, flexibility from the owners of the dogs by anamnesis questions. In order to assess sight cotton ball test, manece response and walking in cluttered area tests followed by direct and indirect routine eye examination with ophthalmoscope. During this examination, cornea, humor aqueous, pupillary cavity, lenses, corpus vitreous were evaluated in terms of transparency. Pupillary reflex was evaluated for both eyes and no abnormality was defined in eye ground examination optic nerve head, retinal vessels and tapetal and nontapetal area. After these examination techniques, normal dogs with no sight loss and eye disease were included into the study. In order to compare the results of the study, 8 unilateral and 2 bilateral blindness from different breeds were include into the study. These 10 dogs that formed the control group underwent routine sight and eye examination.

Each subject has 30 min darkness adaptation before general anesthesia was administrated. The purpose of this action is that it shortened anesthesia time and there was no need for extra anesthesia. All the dogs that were taken into dark room for darkness adaptation were given tropicamide (Tropamid®, Bilim, Turkey) for mydriasis. This was repeated twice in ten min intervals. The patients that will have ERG were administrated 0.5 mg/kg Xylazin HCl (Rompun®, Bayer, Turkey) intra-

venously as preanesthetic, in order to provide anesthesia induction Ketamin HCl (Ketalar®, Eczacıbaşı, Turkey) 5 mg/kg was given intravenously. A standard anesthesia protocol was applied to all patients. During the imaging no complication about anesthesia was encountered.

ERG was used for all patients in the eye examination room that can be darkened. After midriatic eye drop application and general anesthesia, positive needle electrode was placed to the lower eyelid from ectoderm

Table 1. Age and Sex Distribution of Turkish Shepherd Dogs (TSDs)

Tablo 1. Türk Çoban Köpeklerinin yaş ve cinsiyet dağılımı

Case Number	Age (Months)	Sex
1	72	female
2	48	male
3	4	male
4	24	male
5	6	male
6	6	female
7	84	male
8	10	male
9	60	male
10	42	male
11	4	female
12	4	male
13	42	female
14	42	male
15	4	female
16	4	male
17	24	male
18	10	female
19	10	female
20	60	male

Table 2. Breed, age, sex and diagnose distribution of cases with uni or bilateral blindness

Tablo 2. Tek ya da çift taraflı körlük bulunan klinik olguların, ırk, yaş, cinsiyet ve tanı dağılımı

Case Number	Breeds	Age/Months	Sex	Diagnose	Right/Left
1	German Shepherd	72	male	Retinal degeneration	left
2	Mix	12	female	Gun shot wound	left
3	Mix	24	male	Chronic ocular perforation	right
4	Terrier	96	female	chronic glaucoma	right
5	Mix	84	male	Retina detachment	left
6	Terrier	168	male	Retinal atrophy	right
7	Labrador Retriever	48	female	PRA	right and left
8	Mix	6	male	Corneal erosion	left
9	Terrier	144	female	Temporal bone fracture	left
10	Golden Retriever	156	male	PRA	Right and left

in order to touch conjunctiva. Negative needle electrode was placed 1 cm away from lateral eye angle towards eyeball. Earth needle electrode fixed to the head of the patient in the same distance to each electrode (Fig. 1). Google that was used as light source was placed on eyes taking right and left eyes into consideration (Fig. 2). Due to the advanced process program of our equipment, it was confirmed whether needle probes were in the correct location and active or not. Artifact existence that could develop upon other electronic equipments or noise is controlled by opening another window on the program. After these processes, light flash interval 10 sec, Standard flash 3 log U (3 cdsm-2) stimulation was applied in order to get answer to maximal combine. We obtained ERG images on the computer screen via our equipment that we adjusted according to standards of Bandpass amplifier 03-300 Hz, Impetans 10-100 Hz, stimulation frequency 5 Hz ISCEV (international Society for Clinical Electrophysiology of Vision) (Fig. 3-4). Data for each subject was recorded to the patient record program so as to assess later. Wavelength on ERG trace and numerical values of implicit times were obtained numerically thanks to the processing program of the equipment.



Fig 1. Localizations of needle electrodes
Şekil 1. İğne elektrotların lokalizasyonu



Fig 2. Google replacement for light stimuli
Şekil 2. Işık uyarımı için google yerleştirilmesi

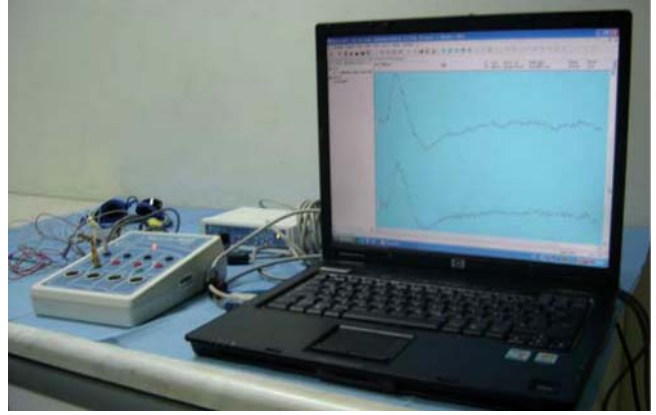
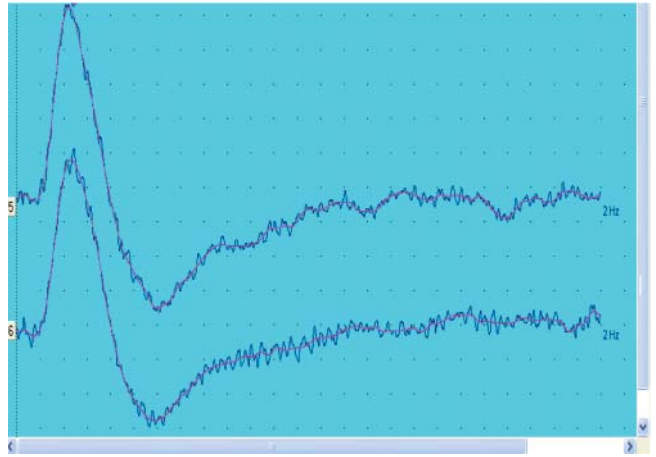


Fig 3. Image of whole ERG system
Şekil 3. Tüm ERG sistemimizin görüntüsü



RESULTS

Seven of the TSDs that were included into study were female and 13 were male. Mean age of this group, healthy in terms of eye and sight, was 28 months. No complication about applied anesthesia protocol was encountered. *a* and *b* wavelengths of the subjects on their right eyes and implicit time of *a* and *b* waves were given at Table 3. Findings on left eye about the same criteria were given at Table 4.

The same anesthesia procedure was applied to the patients with uni and bilateral sight loss in order to perform ERG and no complication was encountered. Four of these patients were female and 6 were male. The mean age for this group was 81 months. Four of this 10 cases were Terrier, 4 were cross bred, 1 German shepherd dog and one was Golden Retriever. Eight of these patients had unilateral blindness and 2 had bilateral blindness according to the result of ophthalmoscopic examination. ERG trace was obtained only from the healthy eyes of these 8 cases that have unilateral

Table 3. Values obtained from right eyes of TSDs**Tablo 3.** Türk Çoban Köpeklerinin sağ gözlerinden elde edilen değerler

Case Number	a Wavelengths (Microvolt)	b Wavelengths (Microvolt)	a Implicit Time (Milisecond)	b Implicit Time (Milisecond)
1	2.100	2.350	64.000	29.300
2	1.190	20.900	51.300	17.300
3	3.910	15.000	17.300	38.700
4	0.820	5.280	21.300	95.000
5	4.210	10.300	201.000	240.000
6	6.510	8.310	183.000	217.000
7	0.540	6.350	152.000	185.000
8	2.630	9.720	307.000	346.000
9	0.100	5.430	16.000	48.000
10	1.440	7.660	14.000	44.700
11	0.710	6.010	16.700	48.000
12	0.910	7.220	38.220	42.130
13	0.170	2.710	23.300	8.130
14	0.920	1.590	44.000	72.700
15	0.380	3.920	13.300	75.300
16	0.420	4.290	32.700	73.300
17	0.830	4.040	16.000	41.300
18	0.810	5.150	65.300	101.000
19	1.250	6.340	36.000	45.000
20	2.100	5.330	72.200	51.000

Table 4. Values obtained from left eyes of TSDs**Tablo 4.** Türk Çoban Köpeklerinin sol gözlerinden elde edilen değerler

Case Number	a Wavelengths (Microvolt)	b Wavelengths (Microvolt)	a Implicit Time (Milisecond)	b Implicit Time (Milisecond)
1	0.980	6.710	41.300	16.700
2	0.320	11.900	46.000	10.700
3	1.110	21.300	12.000	50.700
4	1.050	6.780	21.300	70.300
5	2.150	13.700	181.000	217.000
6	0.220	24.800	40.700	121.000
7	0.520	6.350	160.000	186.000
8	1.120	7.640	309.000	333.000
9	0.760	11.100	15.300	49.300
10	0.440	6.260	34.700	69.300
11	0.200	4.170	52.700	99.300
12	3.890	4.750	81.300	105.000
13	0.750	1.410	72.200	98.000
14	0.510	12.700	18.000	64.000
15	1.640	1.790	96.000	140.000
16	0.220	2.220	71.300	108.000
17	0.680	9.030	18.000	48.700
18	0.500	4.730	83.300	112.000
19	1.200	5.230	30.000	80.000
20	1.700	6.330	42.000	85.000

blindness (Fig. 5). ERG trace could not be obtained from both eyes of the other two patients that have bilateral blindness. ERG trace obtained from the eyes of these cases is given at Table 5.

on veterinary ophthalmology all around the world especially for the last ten years. Thanks to this technique, diagnosis of many retinal diseases has been made. In sight loss especially those developed due to retinal

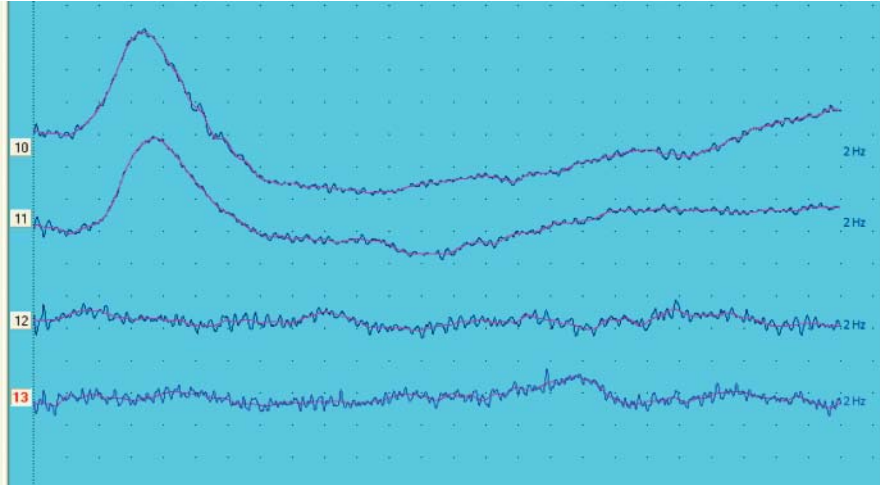


Fig 5. Right and left eye electroretinography of case 2, in our clinical cases, had pellet in left eye ground. Upper 2 trace normal eye that have sight (10,11), lower 2 trace ERG of left eye injured with pellet (12,13). It is observed that a and b waves do not exist on left eye that have no sight

Şekil 5. Klinik olgularımızdan sol göz dibine saçma tanesi gelmiş olan 2 numaralı hastanın sağ ve sol gözlerinin elektoretinografisi. Üst 2 trase görüş olan normal gözün (10,11), alt 2 trase ise saçma tanesi ile yaralanmış olan sol gözün ERG'si (12,13). Görüşün olmadığı sol gözün ERG'sinde a ve b dalgalarının oluşmadığı izlenmekte

Table 5. ERG traces values from the eyes of the cases that have sight

Tablo 5. Klinik olguların görüş bulunan gözlerinin ERG trase değerleri

Case Number	a Wavelengths (Microvolt)	b Wavelengths (Microvolt)	a Implicit Time (Milisecond)	b Implicit Time (Milisecond)
1	1.220	5.320	7.330	50.000
2	0.990	19.000	18.000	66.700
3	0.340	4.010	18.000	54.000
4	2.820	23.000	17.300	60.000
5	0.460	5.280	12.000	54.000
6	1.290	13.000	22.000	58.000
8	1.480	3.250	22.000	65.000
9	1.930	19.600	16.700	63.300
mean±	1.316±0.798	11.557±8.083	16.666±4.925	58.875±5.936

Table 6. Average Values and Standard Deviations of normal electroretinography traces of TSDs

Tablo 6. Türk Çoban Köpeklerinde elde edilen normal elektoretinografi traselerinin ortalama değer ve standart sapmaları

Wave Type	Wavelengths	Implicit Time
a Wave	1.298±0.208 (microvolt)	70.268±11.840 (milisecond)
b Wave	7.670±0.846 (microvolt)	97.072±12.696 (milisecond)

Totally 40 eyes of 20 TSDs, according to ERG results that we obtained applying ISCEV standards *a* wavelength was defined as 1.298±0.208 microvolt, *b* wavelength was 7.670±0.846 microvolt, implicit time for *a* wave was 70.268±11.840 millisecond, and 97.072±12.696 millisecond for *b* wave implicit time (Table 6).

DISCUSSION

ERG technique has been used in some centers

problems, it gives important information for prognosis determination and in order to observe the answer obtained for the applied therapy ^{5,7,10-12,29-31}. In some cases where it is not possible to have ophthalmoscopic examination of retina such as cornea edema, intraocular bleeding and cataract, FERG is an indispensable method to define the total answer of retina. In many veterinary ophthalmology clinics cataract operation is performed after defining that retina is functional using ERG. Cataract operation has been performed for the cases in which

there is no electrophysiologic answer in retina with ERG. By this way it is possible to avoid both unnecessary operations, postoperative expenses and unnecessary effort and suffer that the patient or relatives will have ^{7,10,11,14,15,22}. Park et al. ³² in their study have reported more common cataract in Miniature/toys Poodle, York Shire Terrier and Shih Tsu breeds than other small breed dogs. In our control group, case number 6, Terrier, there was a mature cataract in one eye and insipient cataract in the other. In the ERG, *a* and *b* waves were not seen in the right eye that had cataract for 1 year. Upon this, right eye operation was given up. Other clinic cases like this show the benefits of ERG in, as in the literature data, prognosis determination and diagnose.

One of the most important usages of ERG is to determine genetic retinal diseases that exist in many dog breeds. Especially, it is possible to diagnose before the clinical and ophthalmoscopic symptoms of genetic diseases such as PRA and the dogs that have these illness are excluded from the gene pool ^{1,3,6,7,10,15,18-21,28}. In our study cases 7 and 10 in the control group had clinically and funduscopy diagnose of high level PRA. *a* and *b* waves did not have shape in these patients in ERG. Therefore, it was defined that their retina was not functional. The owner of case 7 that is a young female was warned not to have puppies from the dog. None of the TSDs had clinic, funduscopy and ERG symptoms of PRA.

In ERG imaging, small electric potentials such as millivolt are recorded in short periods like millisecond. For that reason, in addition to the patient's situation environment, equipment and application differences may also change the obtained values. This makes it compulsory for each center to standardize the imaging technique, the environment that the imaging is carried out, the equipment and settings and take the obtained values as reference ^{10,17}. Due to this fact, the environment that the imaging performed and the technique were standardized and the same equipment and settings were used. We are in the opinion that the google apparatus that we used as light source, as in the literature information ¹⁰, is highly practical and useful. The usage of needle electrodes, which were adapted to our system, is very practical and during the application it clears away the need for an assistant. However, as it has been stated in the literature ¹⁰, with the use of electrodes that touch to cornea, it is possible to obtain higher wavelengths.

In veterinary practice, in order to obtain ideal ERG trace it is necessary to calm down the patient chemically ^{1,7,8,10,16,21,22,24}. By this way it is possible to avoid the sounds from environment and the artifacts that can develop due to the patient's movement. In addition, patient's stress is prevented. Need for assistance

by the doctor applying the technique is minimized ^{10,22,24}. Kommonen and Raitta ²⁶ have stated that ketamine-xylazine anesthesia did not have clear effect on *a* and *b* wave amplitudes in dogs. We also applied ketamine-xylazine combination in our study and we did not encounter any anesthetic complications and we prevented any artifacts that could be resulted from the patient's movements and eliminated there need for an assistant during the process.

In a study ²⁷ conducted on national dog breed TSDs in 2005 a funduscopy scanning was done for genetic retinal diseases. According to the results of this study, multifocal retinal dysplasia cases that do not lead to sight loss and blindness were reported. Besides this, normal funduscopy variations of TSDs were defined. According to the results of this study, there is need for further studies in TSD in terms of genetic retinal diseases. Grahn et al. ³³ in their report in 2008 had multifocal retinopathy diagnose in Coton de Tuleur breeds and evaluated these cases clinically, electroretinographically, ultrasonographically and angiographically and compared these cases with normal cases. Electroretinographically in scotopic and photopic whole field ERG findings, they defined slight decrease in *a* and *b* waves of patients with retinopathy. They defined slight serous in patients with retinopathy according to tomography and ultrasonography findings. According this, ERG became an indispensable method to define genetic retinal diseases. For that reason it is a mandatory stage to define normal ERG values in order to make comparison in TSDs that have normal eye and sight capacity. The ERG values that we obtained bear reference value. It is necessary for a center to have its own standards where ERG studies are carried out ²⁸.

Although the ISCEV standards that we formed is a homogenization model accepted all around the world, different numerical values may be obtained due to patient, situation, tool and equipment. This makes it more meaningful to compare and discuss the results of different studies that were carried out in the same center. Therefore, we are in the opinion that the values that we obtained in totally 40 eyes of 20 TSDs according to ERG results that we obtained applying ISCEV standards *a* wavelength was defined as 1.298 ± 0.208 microvolt, *b* wavelength was 7.670 ± 0.846 microvolt, implicit time for *a* wave was 70.268 ± 11.840 millisecond, and 97.072 ± 12.696 millisecond for *b* wave implicit time would be accepted as reliable references.

REFERENCES

1. Parry HB, Tansley K, Thomson LC: Electroretinogram of the dog. *J Physiol*, 120, 28-40, 1953.

2. **Aguirre GD, Rubin LF:** Rod-Cone Dysplasia (PRA) in the Irish Setter. *J Am Vet Med Assoc*, 166, 157-164, 1976.
3. **Wolf ED, Vainisi SJ, Santos-Anderson RM:** Rod-Cone Dysplasia in the Collie. *J Am Med Assoc*, 173, 1331-1333, 1978.
4. **Parshall C, Wyman M, Nitroy S:** Photoreceptor dysplasia: An inherited progressive retinal atrophy of Miniature Schnauser Dogs. *Prog Vet Com Ophthalmol*, 1, 187-203, 1991.
5. **Rubin LF, Bourns TKR, Lord LH:** Hemeralopia in dogs: Heredity of hemeralopia in Alaskan Malamutes. *Am J Vet Res*, 28, 355-357, 1967.
6. **Aguirre GD, Rubin LF:** The electroretinogram in dogs with inherited cone degeneration. *Invest Ophthalmol*, 14 (11): 840-847, 1975.
7. **Narfstrom K, Bjerkas E, Ekesten B:** Visual impairment. In, Peiffer RL, Petersen- Jones SM (Eds): *Small Animal Ophthalmology: A Problem- Oriented Approach*. pp. 85-165, WB Saunders Company, London, 1997.
8. **Ofri R:** Clinical electrophysiology in veterinary ophthalmology- Past, present and future. *Doc Ophthalmol*, 104, 5-16, 2002.
9. **Narfstrom KL, Nilsson SE, Anderson BE:** Progressive retinal atrophy in the Abyssinian Cat: Studies of the DC-Recorded electroretinogram and the standing potential of the eye. *Bri J Ophthalmol*, 69, 618-623, 2005.
10. **Ekesten B:** Electrodiagnostic evaluation of vision. In, Gelatt KN, (Eds): *Veterinary Ophthalmology*. USA, pp. 520-533, Blackwell P, 2007.
11. **Ekesten B:** Electrodiagnostic evaluation of vision. Chapter 1. In, Gelatt KN (Ed): *Essentials of Veterinary Ophthalmology*. USA Second ed., pp. 29-34, Wiley-Blackwell, 2008.
12. **Kamaromy AM, Brooks DE, Dawson WW, Kallberg ME, Olliver FJ, Ofri R:** Technical issues in electrodiagnostic recording. *Vet Ophthalmol*, 5 (2): 85-91, 2002.
13. **Yanase J, Ogawa H:** Effects of halothane and sevoflurane on the electroretinogram of dogs. *Am J Vet Res*, 58, 904-909, 1997.
14. **Öner AÖ:** Oküler klinik elektrofizyoloji. *Erciyes Univ Tıp Derg*, 26 (1): 33-38, 2004.
15. **Maehara S, Osawa A, Itoh N, Wakaiki S, Tsuzuki K, Seno T, Kushiro T, Yamashita K, Izumisawa Y, Kotani T:** Detection of cone dysfunction induced by digoxin in dogs by multicolor electroretinography. *Vet Ophthalmol*, 8 (6): 407-413, 2005.
16. **Shirao Y, Wajima R, Kaneko T, Nishimura A:** Neural retinal contribution to the slow negative potential of the canine electroretinogram. *Doc Ophthalmol*, 94, 293-306, 1998.
17. **Aguirre GD, Rubin LF:** Progressive retinal atrophy in the miniature poodle: An electrophysiologic study. *J Am Vet Med Assoc*, 160, 191-201, 1972.
18. **Gelatt KN:** Visual disturbance: Where do I look? *J Small Ani Pract*, 38, 328-335, 1997.
19. **Chaudieu G, Noblot SM:** Early retinopathy in the Bernese Mountain Dog in France: Preliminary observations. *Vet Ophthalmol*, 7 (3): 175-184, 2007.
20. **Ropstad EO, Bjerkas E, Narfström K:** Clinical findings in early onset cone-rod dystrophy in the Standard Wire- Haired Dachshund. *Vet Ophthalmol*, 10 (2): 69-75, 2007.
21. **Yu HA, Jeong MB, Park SA, Kim WT, Kim SE, Chae JM, Yi NY, Seo KM:** The determination of dark adaptation time using electroretinography in conscious Miniature Schnauser Dogs. *J Vet Sci*, 8 (4): 409-414, 2007.
22. **Norman JC, Narfström K, Barrett M:** The Effects of medetomidine hydrochloride on electroretinogram of normal dogs. *Vet Ophthalmol*, 11 (5): 299-305, 2008.
23. **Martin CL:** Anamnesis and the ophthalmic examination. In, Martin CL (Ed): *Ophthalmic Diseases in Veterinary Medicine*. pp. 11-40, Manson Publishing, London, 2005.
24. **Kommonen B, Hyvatti E, Dawson WW:** Propofol modulates inner retina function in Beagles. *Vet Ophthalmol*, 10 (2): 76-80, 2007.
25. **Yanase J, Ogawa H, Ohtsuka H:** Scotopic threshold response of the electroretinogram of dogs. *Am J Vet Res*, 57 (3): 361-366, 1996.
26. **Kommonen B, Raitta C:** Electroretinography in Labrador Retrievers given ketamine-xylazine anesthesia. *Am J Vet Res*, 48, 1325-1331, 1997.
27. **Saroglu M, Devecioglu Y, Altunatmaz K:** Fundoscopic normal variations of the retina in Turkish Sheepdogs and multifocal retinal dysplasia: A comparative study in Akbash and Kangal Breeds. *Turk J Vet Anim Sci*, 29, 551-556, 2005.
28. **Gündoğan FÇ, Erdem Ü, Hamurcu MŞ, Sobacı G, Bayraktar MZ:** Flaş elektroretinogram (FERG) normal değerlerimiz. *Gülhane Tıp Dergisi*, 48, 14-18, 2006.
29. **Narfstrom K, Wrigstad A:** Clinical, electrophysiological and morphological changes in a case of hereditary retinal degeneration in the Papillon Dog. *Vet Ophthalmol*, 2, 67-74, 1992.
30. **Hurn SD, Hardman C, Stanley RG:** Day-blindness in three dogs: Clinical and electroretinographic findings. *Vet Ophthalmol*, 6 (2): 127-130, 2003.
31. **Rosolen SG, Rigaudiere F, Le Gargasson JF, Chalier C, Rufiange M, Racine J, Joly S, Lachapelle P:** Comparing the photopic ERG I-Wave in different species. *Vet Ophthalmol*, 7 (3): 189-192, 2004.
32. **Park SA, Yi NY, Jeong MB, Kim WT, Kim SE, Chae JM, Seo KM:** Clinical manifestations of cataracts in small breed dogs. *Vet Ophthalmol*, 12 (4): 205-210, 2009.
33. **Grahn BH, Sandmeyer LL, Breaux C:** Retinopathy of Coton de Tulear Dogs: Clinical manifestations, electroretinographic, ultrasonographic, fluorescein and indocyanine green angiographic and optical coherence tomographic findings. *Vet Ophthalmol*, 11 (4): 242-249, 2008.