

Retrieval of A Retained Air Rifle Pellet in the Bursa Ovarica of A Bitch

Oktay YILMAZ * ✍

* Department of Obstetrics and Gynaecology, Faculty of Veterinary Medicine, Afyon Kocatepe University, 03200 Afyonkarahisar - TURKIYE

Makale Kodu (Article Code): KVFD-2010-2165

Dear Editor,

In the present case, air rifle pellet injury of bursa ovarica of a bitch was described to emphasize of the importance the presence of gunshot trauma menace to both human and animal health in public area.

Injuries caused by firearms have the same properties as penetrating wounds. The projectile, depends on its velocity and shape, causes damage in viscoelastic tissue as it expands along its path. When the bone tissue encounters with a projectile, fragmentation of both the bullet and bone occurs due to absorbing the energy by bone. If the fragments have a nature as secondary projectiles, additional soft tissue injuries can happen ¹. Modern air guns can have similiar effects and injuries as small caliber firearms ^{1,2}.

A three years old crossbreed bitch referred to the animal hospital, small animal clinic for ovario-hysterectomie. Median line was prepared for aseptic surgery. As abdominal cavity was opened it was seen that an air rifle pellet was present in the left bursa ovarica surrounded by a capsule (Fig 1). No other defects either on abdominal wall or abdominal organs were evident. It was suggested that the rifle was fired from a higher distance. Because air rifle gun pellet can have minimum 600 ft/sec velocity if the distance between target and gun muzzle is less than approximately 9 metres ². When it was decided there was no complication macroscopically, to the owner's permission, ovariohysterectomie was performed. After surgery, postoperative antibiotic therapy was continued and no complication was observed during the healing period.

It was concluded that air rifle in use in public area still have a danger for both human and animal health and it can cause more dangerous cases if it uses in effective distances. Thereby, the first case of air rifle injury of bursa ovarica in a bitch was reported.

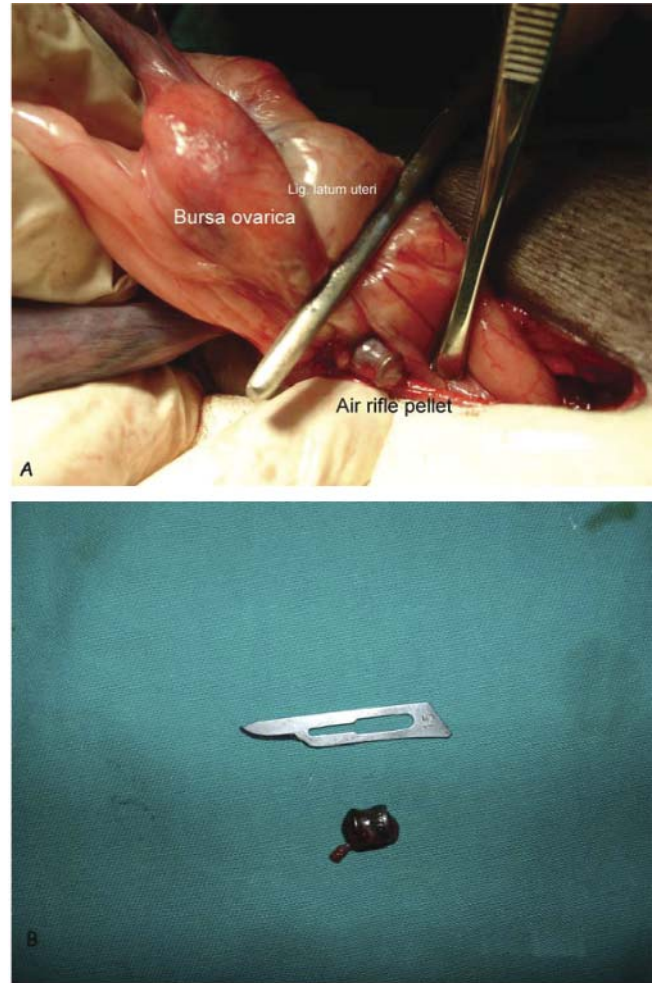


Fig 1 (A,B). Air rifle pellet detected in bursa ovarica

Şekil 1 (A,B). Bursa ovarikada tespit edilen havalı tüfek saçması

REFERENCES

1. Kolata RJ: Trauma: Epidemiology and mechanism. In, Slatter DH (Ed): Textbook of Small Animal Surgery. 3rd ed. 139-140, WB Saunders, Philadelphia, 2003.
2. Naude GP, Bongard FS: From deadly weapon to toy and back again: The danger of air rifles. *J Trauma*, 41, 1039-1043, 1996.

✍ İletişim (Correspondence)

☎ +90 272 2149309

✉ oktayyilmaz@aku.edu.tr