

Cutaneous Malignant Melanoma in a Cat

Mehmet Çağrı KARAKURUM *  Zeynep PEKCAN ** Özlem ÖZMEN ***

* Department of Internal Medicine, Faculty of Veterinary Medicine, Mehmet Akif Ersoy University, Burdur - TURKEY

** Department of Surgery, Faculty of Veterinary Medicine, Kırıkkale University, Kırıkkale - TURKEY

*** Department of Pathology, Faculty of Veterinary Medicine, Mehmet Akif Ersoy University, Burdur - TURKEY

Makale Kodu (Article Code): KVFD-2009-265

Summary

Melanomas are neoplasia of melanocytes and melanoblasts which may in benign or malign character. Malign melanoma is typically considered as a rare neoplasm in cats. In this case report, the clinical and histopathological findings of cutaneous malignant melanoma was reported in a sixteen year-old cat. At the same time, this is the first report of cutaneous malignant melanoma in a cat in Turkey.

Keywords: *Cat, Malignant melanoma*

Bir Kedide Kutanöz Malign Melanoma

Özet

Melanomlar melanosit ve melanoblastların benign veya malign tümörleridir. Malign melanom kedilerde oldukça nadir gözlenen bir tümördür. Bu vaka takdiminde 16 yaşlı bir kedide kutanöz malign melanoma'nın klinik ve histopatolojik bulguları bildirilmiştir. Bu, aynı zamanda, Türkiye'de bir kedide bildirilen ilk kutanöz malign melanoma vakasıdır.

Anahtar sözcükler: *Kedi, Malign melanoma*

INTRODUCTION

In cats, less than 1% of all feline oral neoplasms and approximately 0.5% of feline skin tumours are melanomas ¹. More than 150 cases of non-ocular malignant melanomas have been reported in the literature since 1961 ². Malignant melanoma can not be differentiated from melanocytoma on gross examination. The tumour may be highly pigmented or nonpigmented, and may invade the deeper tissues, into the subcutaneous tissue and along the fascial planes ³. Feline malignant melanomas are known to have an aggressive nature with a high metastatic rate, independent with primary site of origin ^{1,4,5}.

Aim of the study is to report a case of cutaneous malignant melanoma in a sixteen year-old, domestic short-hair cat.

CASE HISTORY

A sixteen-year-old, spayed, female, domestic short haired cat was admitted to our clinic for the evaluation of an ulcerated skin lesion that had been growing fastly for 3 months on the dorsum of the upper lip and lethargy for 4 days. The cat had been vaccinated regularly and roaming freely.

At physical examination, an ulcerative, crusting and oval shaped skin lesion with the dimensions of 2.5 x 2 x 1 cm was observed between the left nostril and the upper lip border (*Fig. 1*). At physical examination enlarged left mandibular lymph node and anemia was detected. No other abnormalities were detected by clinical examination. Results of CBC showed lymphopenia, and severe normocytic-hypochromic anemia (*Table 1*). Radiographic and ultrasonographic study did not



İletişim (Correspondence)



+90 248 2344500



mckarakurum@yahoo.com

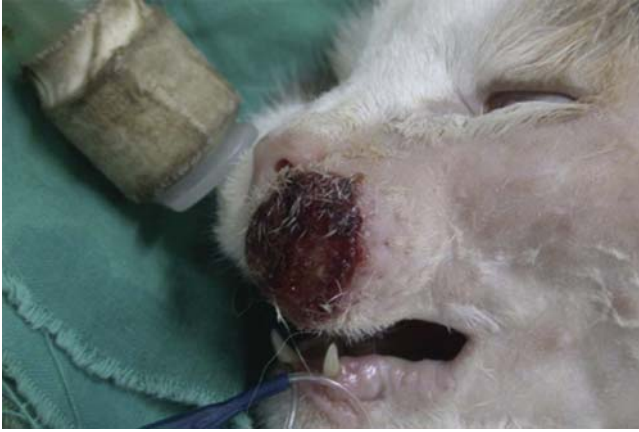

Fig 1. Appearance of tumour before surgery

Şekil 1. Tümörün cerrahi öncesi görünümü

Table I. Complete blood count results

Tablo I. Tam kan sayımı sonuçları

Complete Blood Count	Value
Hemoglobin	5.70 g/dL
Haematocrit	24.70%
Erythrocyte	3.90 M/mm ³
Leukocyte	14.59 K/mm ³
MCH	14.60 pl
MCV	63.30 fl
MCHC	23.10 g/dL
RDW	20.40%
Thrombocyte	213.00 K/mm ³
PCT	0.20%
Differential	
Eosinophils	0%
Basophils	1%
Neutrophils	82%
Lymphocytes	14%
Monocytes	3%
Erythrocytes	Normocytic
Hypochrom	+

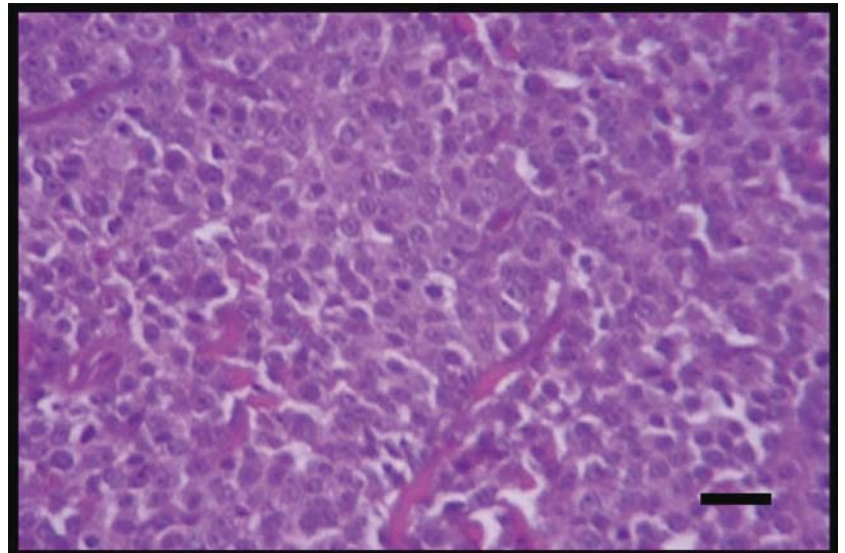
reveal any abnormality. Sera was tested by using Snap Combo kits (IDEXX, Portland, ME, USA) for the presence of FIV and FeLV and found to be FIV positive.

Skin biopsy was taken and transferred to the laboratory for histopathological examination. Biopsy result showed malignant melanoma. After the diagnosis, wide excision of the tumour was performed and the specimen was sent for the pathological assessment. At the time of surgery fine needle aspiration was obtained from mandibular lymph node. Following fixation in the 10% neutral formalin, the excised specimen was blocked in paraffin and cut into 5 μ thickness slices. Tissue sections were stained with Hematoxylin-Eosin (HE), and examined microscopically. Selected tumour sections were stained immunohistochemically in order to demonstrate Neuron Specific Enolase (NSE), S100 protein, smooth muscle actin (SMA), vimentin, Melan-A using a routine streptavidin-biotin peroxidase technique. Commercially obtained rabbit antisera were used as primary antibody.

At the histopathological examination epithelium was ulcerated. Tumour cells were epitheloid with prominent, round to oval shaped nuclei, non-pigmented and arranged in nests (Fig. 2). Anaplasia with cell pleomorphism and varying degrees of mitotic activity were observed (mitotic count was $>20/\text{mm}^2$ ($1 \text{ mm}^2 = 6.3$ high power fields)). Infiltration of tumour into the subcutaneous fat was detected. Surgical borders were intact. No tumour regression was seen. Immunohistochemistry showed that tumour is Melan-A, S100, vimentin and NSE positive (Fig. 3). Histopathological diagnosis was reported as nodular type malignant melanoma. Cytology of lymph node aspirates was unremarkable.

Fig 2. Tumour cells are polygonal with round to oval shaped hyperchromatic nucleus with evident nucleoli. H&E, Bar = 50 μ m

Şekil 2. Poligonal şekilli, yuvarlaktan ovale değişen hiperkromatik çekirdeklere sahip, belirgin çekirdekçikli tümör hücreleri. H&E, Bar = 50 μ m



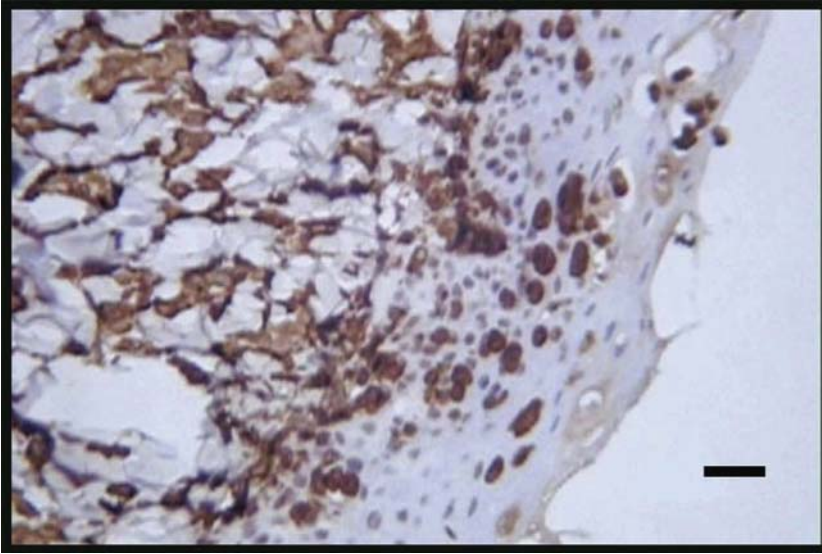


Fig 3. Melan - A positive immunoreaction of the tumour. Bar = 100 μ m

Şekil 3. Tümörün Melan-A pozitif immuno-reaksiyonu. Bar = 100 μ m

After surgery, chemotherapy could not be performed upon the owner's request. The cat had died 1 month after surgery. But owner did not give permission for necropsy.

DISCUSSION

Feline melanomas are very unusual neoplasms¹ and they can only be diagnosed by histopathology. Melanoma may be presented as different type of pigmentation, ranging from gray or brown to black, red, or even dark blue^{3,6}. Pigmentation is not a specific feature because the gross appearance of other neoplastic or nonneoplastic lesions can be similar. Most common localization sites are head, tail, distal extremities and lumbar area^{1,2,4,5} which are also common for other feline cutaneous neoplasms such as basal cell carcinoma and squamous cell carcinoma (SCC)⁷. SCC is a sunlight induced skin tumour with little or no pigment and has similar site localizations for melanomas. Extensive keratinization and formation of keratin pearls are characteristic for SCC. Basal cell tumours are neoplasia of the epidermis, sweat gland, hair follicles and sebaceous glands with a high incidence in cats. Basal cell tumours may be pigmented and this may lead a mistake in diagnosis. Since basal cell carcinomas are usually showing a benign character and have a good long term prognosis, it is important to make a differential diagnosis between melanoma and basal cell carcinoma². Thus histopathology is useful in differential diagnosis of above mentioned tumours and melanoma. In the present case in order to confirm the diagnosis of malignant melanoma an immunohistochemical study was performed and the

tumour found to be Melan-A, S100, vimentin and NSE positive. These staining results are in accordance with malignant melanoma as reported previously³.

In animal skin and eye melanocytic neoplasms, mitotic index is the most reliable histological feature for distinguishing malignant from benign. Three or more mitotic figures per 10 high-power fields show malignancy. Other valuable additional features favouring malignancy are the presence of neoplastic cells, individually or in nests, within the upper layers of the epidermis and tumour cell type³. In the present case high mitotic activity (mitotic count was $>20/\text{mm}^2$ [1 $\text{mm}^2 = 6.3$ high power fields]), and existence of tumour cells arranged in nests and epitheloid tumour type full-fill the criteria established for malignancy.

Metastatic rates for cutaneous melanomas in cats have been reported to range from 5 to 25%^{5,8}. The cat of this report had no confirmed metastasis by lymph node aspirate cytology, radiography and ultrasonography.

The most common cause of lymphopenia is endogenous (stress) and exogenous corticosteroids, some viral infections (e.g. Panleukopenia, FIV, FeLV), impaired lymphopoiesis, extravasation of lymph (lymphocyte-rich thoracic effusions, and lymphangiectasia)⁹. Lymphopenia in our case might not be directly related to presence of malign melanoma. Since, anemia and neutropenia and/or lymphopenia are common haematological abnormalities in FIV infected cats; the present authors established a direct cause effect between lymphopenia, anemia and concurrent FIV infection. Lymphopenia in FIV infected cats is usually a result of a decrease in CD4 + lymphocytes, CD4 +/CD8 + ratio and mitogen induced blastogenic

response of T cells ¹⁰.

The possibility of an increase of melanomas in combination with FIV- or FeLV-infections was reported ¹¹. In the present case the authors could not obtain a clear evidence of immunosuppression or any other possible FIV effect that lead a direct cause effect between FIV and development of malignant melanoma. In this clinical case, the association of malignant melanoma and FIV has not been clearly elucidated and also might have been coincidental.

REFERENCES

1. **Goldschmidt MH, Shofer FS:** Skin Tumors of the Dog and Cat. Butterworth Heinemann, Oxford, UK, pp. 142-151, 1992.
2. **Luna LD, Higginbotham ML, Henry CJ, Turnquist SE:** Feline non-ocular melanoma: A retrospective study of 23 cases (1991-1999). *J Feline Med Surg*, 2, 173-181, 2000.
3. **Smith SH, Goldschmidt MH, McManus PM:** A Comparative Review of Melanocytic Neoplasms. *Vet Pathol*, 39, 651-678, 2002.
4. **Day MJ, Lucke VM:** Melanocytic neoplasia in the cat. *J Small Anim Pract*, 36, 207-213, 1995.
5. **Patnaik AK, Mooney S:** Feline melanoma: A comparative study of ocular, oral, and dermal neoplasms. *Vet Pathol*, 105-112, 1988.
6. **Dixon PM, Head KW:** Equine nasal and paranasal sinus tumours. Part 2: A contribution of 28 case reports. *Vet J*, 157, 279-294, 1999.
7. **Vail DM, Withrow SJ:** Tumours of the skin and subcutaneous tissues. In, Withrow SJ, McEwen EG (Eds): *Small Animal Clinical Oncology*. 2nd ed. WB Saunders Company, Philadelphia, USA, pp. 183-185, 1996.
8. **Holzworth J:** Diseases of the Cat: Medicine and Surgery. WB Saunders Co, Philadelphia, 579-583, 1987.
9. **Cahn CM, Line S:** The Merck Veterinary Manual. 9th ed., Merck&Co., Inc, Whitehouse station, N.J., USA, 49, 2005.
10. **Jain NC:** Essentials of Veterinary Hematology. Lea & Febiger, Philadelphia, 375, 1993.
11. **Shiller, I, Spiess B, Pospischil A:** Malignant melanomas in two cats. *Schweiz Archiv Tierheilkd*, 137, 50-53, 1995.