

Immunohistochemical Distribution of Insulin-, Glucagon-, and Somatostatin-Containing Cells in the Pancreas of the Rat (*Wistar albino*)

Hakan KOCAMIS * 
Nurhayat GULMEZ *

Ebru KARADAG SARI *
Sahin ASLAN *

Mumtaz NAZLI *
Turgay DEPREM *

* Department of Histology and Embriology, Faculty of Veterinary Medicine, University of Kafkas, 36100 Kars - TURKEY

Makale Kodu (Article Code): 2009/086-A

Summary

The aim of the present study was to determine the regional distribution of the insulin-, glucagon-, and somatostatin-containing cells in the pancreas of rat. Tissue samples were obtained under deep ethyl ether anaesthesia from 10 adult rat (*Wistar albino*). Tissue sections were stained with Crossmon's connective tissue staining for general observations. Sections were further processed for standart immunohistochemical techniques using the avidin- biotin-complex method for the distribution of insulin-, glucagon-, and somatostatin-containing cells. It was monitored that insulin-containing B cells were located central regions of the islets of Langerhans whereas glucagon- containing A cells and somatostatin- containing D cells were located peripheral regions of the islets. Somatostatin- containing cells were rare in the islets of Langerhans. Our findings make additional contribution to those of pancreatic studies of rats which have been often used as an animal model in the studies dealing with diabetes or islet cell tumours.

Keywords: *Insulin, Glucagon, Somatostatin, Pancreas, Rat*

Rat (*Wistar albino*) Pankreasında İnsulin-, Glukagon- ve Somatostatin-İçeren Hücrelerin İmmunohistokimyasal Olarak Dağılımı

Özet

Bu çalışmanın amacı insülin-, glukagon-, ve somatostatin-içeren hücrelerin rat pankreasında bölgesel olarak dağılımının belirlenmesidir. Doku örnekleri, derin etil anestezisi altındaki 10 adet erişkin rattan alındı. Doku kesitleri genel görünüm için Crossmon'ın bağ doku boyasıyla boyandı. Kesitlere insülin-, glukagon-, ve somatostatin içeren hücrelerin dağılımının belirlenmesi için standart Avidin-biotin complex (ABC) metodu uygulandı. İnsülin içeren B hücrelerinin adacıkların merkezinde yerleştiği görüldü. Glukagon-içeren A hücreleri ve somatostatin-içeren D hücreleri adacıkların periferinde yerleşmişti. Somatostatin-içeren hücreler Langerhans adacıklarında az sayıdaydı. Sonuç olarak elde edilen bulgular sıklıkla diabet ya da adacık hücre tümörleri gibi hastalıklarda hayvan modeli olarak kullanılan ratların pankreasında yapılan çalışmalara katkıda bulunacaktır.

Anahtar sözcükler: *İnsülin, Glukagon, Somatostatin, Pankreas, Rat*

INTRODUCTION

Pancreas in the vertebrates is subdivided into two parts: One of them is exocrine part where digestive enzymes are released and the other one is endocrine part where regulatory hormones are released into blood circulation ¹. The endocrine part, formed by the islets of Langerhans, is multihormonal unit composed

of at least four types of cells; the insulin (B cells), the glucagon (A cells), the somatostatin (D cells), and the pancreatic polypeptide (PP cells) ².

Insulin is synthesized in the B cells of the pancreatic islets and regulates the blood glucose levels. Glucagon



İletişim (Correspondence)



+90 474 2426812



hkocamis@hotmail.com

is synthesized in the A cells of the pancreas and regulates blood glucose levels as well ³. Somatostatin is a polypeptid hormone ⁴ which is also known as a somatotropin release-inhibiting factor (SRIF) and secreted by pancreatic δ (D) cells ^{5,6}. Somatostatin is known to be a multifunctional hormone that inhibits the secretion of a large number of hormones including insulin, glucagon, gastrin and cholecystokinin ⁴.

The purpose of this study was to determine the regional distribution of the insulin-, glucagon-, and somatostatin-containing cells in the pancreas of the rat by immunohistochemistry using specific antisera against insulin, glucagon, and somatostatin.

MATERIAL and METHODS

In the present study, ten adult rats (*Wistar albino*) were used without any gender distinction. Tissue specimens were dissected and obtained under deep ethyl ether anaesthesia from the lobes of the pancreas. Samples from the pancreas were fixed in Bouin's solution for 12 h at 4°C. After paraffin embedding, serial tissue sections were cut at 5-6 μ m in thickness. Sections of each tissue were stained with Crossmon's connective tissue stain ⁷ for general observations.

Immunohistochemistry

Each section was deparaffinized, rehydrated and then immunostained with the avidin-biotin-complex (ABC) method ⁸. The endogeneous peroxidase and non-specific binding sites for antibodies were suppressed by treating sections with 0.5% hydrogen peroxide for 30 min and 10% normal rabbit serum for 10 min at room temperature, respectively. Furthermore, sections were processed for standart immunohistochemical techniques. The working dilutions and the sources of antibodies used are listed in the [Table 1](#). Peptide specific antibodies isolated from mammalian species were used. Negative controls were carried out by incubating sections with phosphate-buffered saline (PBS) instead of the primer antiserum. Negative controls were also conducted with tissue sections from the gastrointestinal tract of rabbits known to contain the hormones studied. The sections were incubated in primary antisera in PBS-containing bovine serum albumin (2.5%) and Triton X-100 (0.2%) for 1 h at room temperature. Subsequently, the binding of primary antisera was detected using rabbit-antimouse antisera and Strept ABC. Finally, the chromogen protocol was used to reveal the distribution of bound peroxidase activity ⁹.

Table 1. The primary and secondary antibodies and their dilutions

Tablo 1. Primer ve sekonder antikolar ve dilusyonları

Antisera	Working Dilutions	Sources
Insulin	1: 40	Signet
Glucagon	1: 40	Signet
Somatostatin	1: 100	Dako
Goat-anti-rabbit Ig G	1: 100	Zymed
Rabbit anti-mouse Ig G	1: 100	Dako
Strept ABC	1: 50	Dako

RESULTS

Rat pancreas was found (as expected) to be consisted of exocrine and endocrine (islets of Langerhans) parts. The endocrine parts of the pancreas were scattered singly or in small groups of islets of various shapes and size in the interstitium of the exocrine parts.

The islets of Langerhans were composed of two different regions, which were central and peripheral regions. Positive immunohistochemical reactions were observed in the pancreatic islets of rat against insulin-, glucagon-, and somatostatin containing cells. No specific staining was found in the exocrine part of pancreas.

Insulin-containing cells (B cells)

Insulin-containing cells were abundant in the whole islets of Langerhans. Those cells were located in the central regions of the islets. B cells were found to have round shape ([Fig 1](#)).

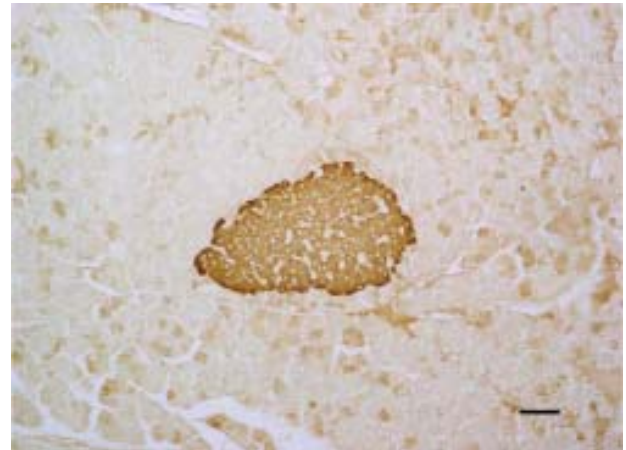


Fig 1. Insulin-containing cells (B cells) in islets of Langerhans. Bar: 100 μ m

Şekil 1. Langerhans adacıklarında insulin-içeren hücreler (B hücreleri). Bar: 100 μ m

Glucagon-containing cells (A cells)

Glucagon-containing cells were located in peripheral regions of the islets. They were surrounded by the B cells and had round shape ([Fig 2](#)).

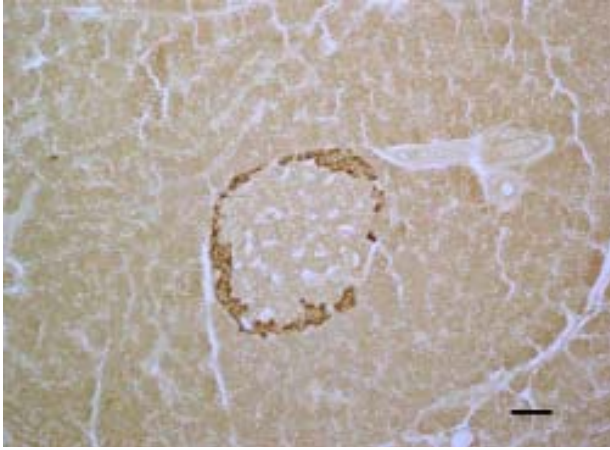


Fig 2. Glucagon-containing cells (A cells) in islets of Langerhans. Bar: 100 μ m

Şekil 2. Langerhans adacıklarında glukagon-içeren hücreler (A hücreleri). Bar: 100 μ m

Somatostatin-containing cells (D cells)

Somatostatin-containing cells were found rarely in the islets of Langerhans. D cells were localised especially in the peripheral regions of the islets. They were found to have irregular shape (*Fig 3*).

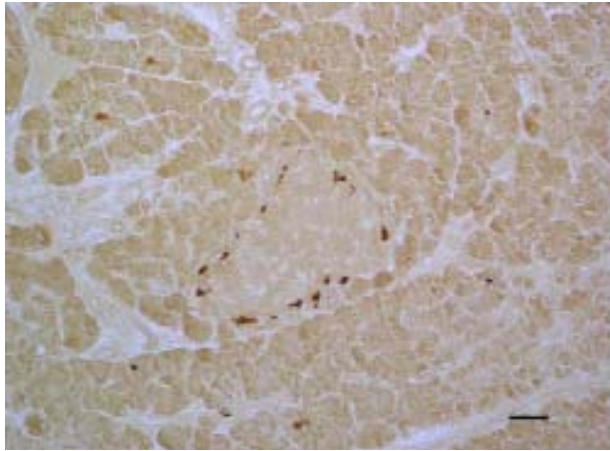


Fig 3. Somatostatin-containing cells (D cells) in islets of Langerhans. Bar: 100 μ m

Şekil 3. Langerhans adacıklarında somatostatin-içeren hücreler (D hücreleri). Bar: 100 μ m

DISCUSSION

The pancreas is composed of two secretory parts, which are the insular or endocrine part and the acinar or the exocrine part ². In this study, pancreas was found to be consisted of exocrine and endocrine (islets of Langerhans) parts, as explained in literature. It was reported that insulin-immunoreactive cells were arranged in the central region of pancreas islets

in wood mouse ¹⁰ and hamster ¹¹. However, it was described that insulin-immunoreactive B cells occupied the majority of the periphery regions of islets in monkey pancreas ¹². In the present study, insulin-containing cells were observed in the central regions of islets of Langerhans, as in agreement with previous studies ^{10,11,13}.

In monkey ¹² and equine ¹⁴, glucagon-immunoreactive cells were found in the central regions of pancreatic islets where insulin-immunoreactive cells were numerous located in most of the domestic animals. Glucagon-containing cells were seen peripheral regions of pancreatic islets in our study. Sujatha et al. ¹² and Helmstaedter et al. ¹⁴ reported that somatostatin-immunoreactive cells were found mostly with glucagon-immunoreactive cells in the center of pancreatic islets. However, somatostatin-containing cells were located peripheral regions of the islets of Langerhans in the current study as described in some of the studies ^{10,11,13}. Taken together, cellular pattern of islets has a species difference that may eventually give rise to functional significance.

There were several immunohistochemical and morphometric studies on the glucagon-, insulin-, and somatostatin-immunoreactive cells in the pancreas ¹⁵⁻²¹. It has been indicated that in diabetic state, pancreatic beta-cells showed a weak immunostaining for insulin, appears to suggest that induction of regenerative stimulus in diabetic state triggers pancreatic regenerative processes, thereby restoring functional activities of the pancreas ¹⁵. It was demonstrated that significantly less B-cell area and markedly larger A- and D- cell areas within the diabetic islets were found when compared with the non-diabetic and pre-diabetic islets ¹⁹. In another study, they have observed a direct relationship between total hormone area and hormone content, in islets from normal and hyperglycemic diabetic dogs ²⁰. This findings suggest that there are acute effects of insulin or of normalization of glycemia on the A- and D-cells, to reduce hormone content in diabetes. Badawoud ²¹ demonstrated that the B cell volume density was significantly lower in the diabetic group, while islet volume density, islet diameter, islet volume and absolute islet cell numbers were significantly greater in the diabetic group. The B cell nuclear diameter and volume were not significantly different in the diabetic group. This study indicated that maternal diabetes induced foetal islet hypertrophy and caused an increase in the total islet cell number ²¹.

In conclusion, it was monitored that insulin-containing B cells were located central regions of the islets whereas glucagon-containing A cells and somatostatin-containing D cells were located peripheral regions of the islets. Somatostatin-containing cells were rare in the islets of Langerhans. Therefore, the findings make additional contribution to those of pancreatic studies of rats which have been often used as an animal model in the studies dealing with diabetes or islet cell tumours.

REFERENCES

1. **Kobayashi K, Syed Ali S:** Cell types of the endocrine pancreas in the shark, *Scylliorhinus stellaris* as revealed by correlative light and electron microscopy. *Cell Tissue Res*, 215, 475-490, 1981.
2. **Bendayan M, Ito S:** Immunohistochemical localization of exocrine enzymes in normal rat pancreas. *J Histochem Cytochem*, 27, 1029-1034, 1979.
3. **Hsu SM, Raine L, Fanger H:** Use of avidin-biotin peroxidase complex (ABC) in immunoperoxidase techniques: A comparison between ABC and unlabeled antibody (PAP) procedures. *J Histochem Cytochem*, 29, 577-580, 1981.
4. **Reisine T, Bell GL:** Molecular properties of somatostatin receptors. *Neurosci*, 67, 777-790, 1995.
5. **Patel YC, Greenwood M, Panetta R, Hukovic N, Grigorakis S, Robertson LA, Srikant CB:** Molecular biology of somatostatin receptor subtypes. *Metabolism*, 45, 31-38, 1996.
6. **Reichlin S:** Somatostatin. *N Engl J Med*, 309, 1495-1501, 1983.
7. **Crossmon G:** A modification of Mallory's connective tissue stain with a discussion of the principles involved. *Anat Rec*, 69, 33-38, 1937.
8. **Hsu WH, Crump MH:** The Adrenal Gland. In, Mc Donald LE, Pineda MH (Eds): *Veterinary Endocrinology and Reproduction*. Philadelphia, Lea&Febiger, pp. 186-201, 1989.
9. **Shu S, Ju G, Fan L:** The glucose oxidase-DAB-nickel in peroxidase histochemistry of the nervous system. *Neurosci Lett*, 85, 169-171, 1988.
10. **Yukawa M, Takeuchi T, Watanabe T, Kitamura S:** Proportions of various endocrine cells in the pancreatic islets of wood mice (*Apodemus speciosus*). *Anat Histol Embryol*, 28, 13-16, 1999.
11. **Camihort G, Del Zotto H, Gomez-Dumm CL, Gagliardino JJ:** Quantitative ultrastructural changes induced by sucrose administration in the pancreatic B cells of normal hamsters. *Biocell*, 24, 31-37, 2000.
12. **Sujatha SR, Pulimood A, Gunasekaran S:** Comparative immunohistochemistry of isolated rat & monkey pancreatic islets cell types. *Indian J Med Res*, 119, 38-44, 2004.
13. **Wieczorec G, Pospischil A, Perentes EA:** Comparative immunohistochemical study of pancreatic islets in laboratory animals (rats, dogs, minipigs, nonhuman primates). *Exp Toxicol Pathol*, 50, 151-172, 1998.
14. **Helmstaedter V, Feurle GE, Forsmann WG:** Insulin-, glucagon-, and somatostatin-immunoreactive cells in the equine pancreas. *Cell Tissue Res*, 172, 447-454, 1976.
15. **Adewole SO, Ojewole JA:** Insulin-induced immunohistochemical and morphological changes in pancreatic beta-cells of streptozotocin-treated diabetic rats. *Methods Find Exp Clin Pharmacol*, 29, 447-55, 2007.
16. **Calvo RM, Forcen R, Obregon MJ, Escobar del Rey F, Morreale de Escobar G, Regadera J:** Immunohistochemical and morphometric studies of the fetal pancreas in diabetic pregnant rats. Effects of insulin administration. *Anat Rec*, 251, 173-80, 1998.
17. **Fu Q, Honda M, Ohgawara H, Igarashi N, Toyada C, Omori Y, Kobayashi M:** Morphological analysis of pancreatic endocrine cells in newborn animals delivered by experimental diabetic rats. *Diabetes Res Clin Pract*, 31, 57-62, 1996.
18. **Gulmez N, Kocamis H, Aslan S, Nazli M:** Immunohistochemical distribution of cells containing insulin, glucagon and somatostatin in the goose (*Anser anser*) pancreas. *Turk J Vet Anim Sci*, 28, 403-407, 2004.
19. **Iwashima Y, Watanabe K, Makino I:** Changes in the pancreatic A-, B- and D-cell populations during development of diabetes in spontaneously diabetic Chinese hamsters of the Asahikawa colony (CHAD). *Diabetes Res Clin Pract*, 8, 201-14, 1990.
20. **Rastogi KS, Brubaker PL, Kawasaki A, Efendic S, Vranic M:** Increase in somatostatin to glucagon ratio in islets of alloxan-diabetic dogs: Effect of insulin-induced euglycemia. *Can J Physiol Pharmacol*, 71, 512-7, 1993.
21. **Badawoud MH:** Immunohistochemical and morphometric study of the effect of maternal diabetes on rat foetal pancreatic islets. *Folia Morphol (Warsz)*, 62, 19-24, 2003.