

Ultrasonographic Evaluation of Mammary Tumors in Bitches

Ayhan BAŞTAN *  Erhan ÖZENÇ ** İlknur PİR YAĞCI *** Duygu BAKİ ACAR *

* Department of Obstetrics and Gynaecology, Faculty of Veterinary Medicine, University of Ankara, 06110, Ankara - TURKEY

** Department of Obstetrics and Gynaecology, Faculty of Veterinary Medicine, University of Afyon Kocatepe, 03200, Afyonkarahisar - TURKEY

*** Department of Obstetrics and Gynaecology, Faculty of Veterinary Medicine, University of Kırıkkale, 71450, Kırıkkale - TURKEY

Yayın Kodu (Article Code): 2008/79-A

Summary

The aim of this study was to characterize the ultrasonographic patterns of benign and malignant mammary tumors and to evaluate the efficacy of ultrasonographic imaging to distinguish benign and malignant tumors in dogs. Shape, margins, width-to-cranio-caudal (CC) dimension ratio, echotexture, echogenicity, presence of calcification, presence of pseudocapsule, size (the deepest and longest axis) and acoustic transmission of tumors were evaluated. The ultrasonography features and the tissue diagnosis of benign tumor were oval or round (80% of masses with this feature were benign), and circumscribed margins (95% were benign). The features most predictive of a malignant tumor diagnosis were spiculated or microlobulated margins (76% of masses with this feature were malignant), and irregular shape (78% were malignant). No differences between the benign and malignant groups for width-to-CC dimension ratio >1.4 were observed. The benign tumors were seen in different distribution of benign hypoechoic (30%), isoechoic (35%) or varied in echogenicity. It was concluded that, the ultrasonography could be an extremely useful tool for the preevaluation of canine mammary gland tumors, especially in relation to the evaluation of tumor size, shape, border irregularity, echotexture, internal echogenicity and acoustic transmission.

Keywords: *Bitch, Diagnosis, Mammary tumor, Ultrasonography*


Dişi Köpeklerdeki Meme Tümörlerinin Ultrasonografik Olarak Değerlendirilmesi

Özet

Bu çalışmada köpeklerde benign ve malign tümörlerin ultrasonografik görünüm özelliklerinin belirlenerek ayırıcı tanıda bu özelliklerin kullanılabilirliğinin belirlenmesi amaçlanmıştır. Tümörler şekil, çevre kenar özellikleri, en-boy uzunluk oranları, ekotekstur, ekojenite, kalsifikasyon ve yalancı kapsül varlığı, uzunluk ve akustik iletim yönünden değerlendirildi. Benign tümörlerin ultrasonografik özellikleri oval veya yuvarlak olması (benign tümörlerin %80'i bu özelliğe sahip) ve sınırlı bir kenar yapısına (benign tümörlerin %95'i bu özellik belirlendi) sahip olmasıydı. Malign tümörler ise düzensiz bir şekle (malign tümörlerin %78'sinde gözlemlendi) sahip olmakla birlikte, lobuler veya uzantılı bir kenar özelliği de (malign tümörlerin %76'inde belirlendi) gösterdiler. Benign ve malign tümörlerde en ve boy oranlarının 1.4 den büyük özellik göstermesi bakımından istatistiksel bir fark saptanmadı. Benign tümörlerde farklı oranlarda hipoeoik (%30), isoeoik (%35) ve karma ekoik görüntü (%35) saptandı. Sonuç olarak, köpeklerde meme tümörlerinin tiplendirilmesinden önce ultrasonografik görüntülerinin özellikle tümör boyutu, şekli, tümörün kenar özellikleri, iç ekojenite, ekotekstür yapısı ve akustik iletim yönünden ön değerlendirmesinin fayda sağlayabileceği belirlenmiştir.

Anahtar sözcükler: *Dişi köpek, Tanı, Meme tümörü, Ultrasonografi*

 İletişim (Correspondence)

 +90 312 317 03 15

 bastan@veterinary.ankara.edu.tr

INTRODUCTION

Mammary gland tumors are the most important types of neoplasms in the dog since the incidence is approximately 27.1 per cent (with a range of 8.4 to 52.0 per cent) of all tumors in female dogs¹ and the second most common tumors in dogs of both sexes².

As in humans, mammary tumors are common in dogs and it is important to distinguish the type and stage of the mammary tumors as they influence the treatment and the prognosis^{3,4}. Treatment options depend on tumor size, stage, type and histologic differentiation⁵⁻⁷. The treatment recommended in veterinary practice for any type of the mammary neoplasm is surgery, radiation therapy, chemotherapy, or a combination but strategies of surgery can change due to tumour type⁵. Early detection and rapid therapy are essential to prevent early local or distant dissemination⁵.

It has been reported in the previous studies that fine needle aspiration cytology is considered a fast and accurate method for the diagnosis of canine and human mammary gland tumors⁸. Use of less invasive methods of distinguishing malignant tumors from benign lesions would be of importance clinically to reduce the number of biopsies in the individual animal^{3,9}. Although numerous observations have been made, ultrasound criteria for avoiding biopsy of solid lesions have not been widely adopted^{10,11}. However, studies on mammary tumors have mostly focused on the ultrasonographic evaluation in humans. There is limited number of studies on the ultrasonographic characteristics of superficial canine tumors. In addition, there is still a need to investigate the correct differential parameters on ultrasonographic examinations of the canine mammary masses.

The aims of this study were to characterize the ultrasonographic patterns of benign and malignant mammary tumors and to evaluate whether ultrasound could help discriminate between benign and malignant tumors in dogs.

MATERIAL and METHODS

This study was conducted in 64 bitches from different age and breed having 78 mammary

masses which referred to the Clinic of Obstetrics and Gyneacology Department, Faculty of Veterinary Medicine, Ankara University, Ankara - Turkey between 2004 and 2007. The age range of the bitches was 5-15 years (mean 10.1 ± 3.7 years). The breeds of animals were Terrier (n=24), Cross breed (n=10), Setter (n=5), Boxer (n=6), Pincher (n=5), Rotweiller (n=4), Anatolian Shepherd Dog (n=7) and Doberman pinscher (n=3).

Age, breed, parturition, any drug or hormone administration, enlargement and localization of masses and metastasize were recorded. After anamnesis all mammary glands and lymph nodules on both sides were palpated carefully and results were recorded.

Using an veterinary ultrasound equipment (100 Falco Vet; Pie Medical Equipment B.V., Philipsweg 1, 6227 AJ, The Netherlands) combined with a 6-8 MHz linear array transducer, abdominal ultrasonographic examination was carried out. Ultrasonographic examinations of the mammary masses were evaluated according to following criteria from the literature^{3,12}: Shape (round, oval, lobulated, or irregular), margins (circumscribed, microlobulated, non-defined, or spiculated), width-to-cranio-caudal (CC) dimension ratio, echotexture (heterogenous or homogeneous), echogenicity (hypoechoic, isoechoic, or varied), acoustic transmission (presence or absence of distal acoustic enhancement and/or shadowing), presence of a pseudocapsule, and presence of calcification. The size of tumor was measured as its deepest and longest axis.

After clinical and ultrasonographic examination, the operation was decided. Before surgical intervention, complete blood cell count, serum biochemical profile and thoracic radiography (3 views) were performed. In dogs which had not been the evidence of metastasis, uni or bi lateral mastectomy was performed according to tumor localization. After mastectomy, the masses were sent to the laboratory for histopathological examination. Tissue samples were fixed in 10% buffered formaldehyde solution and embedded in paraffine wax. Sections of 5 μ m thickness were cut and stained with hematoxylin-eosin (HE).

Noninfiltrating carcinomas, complex carcinoma, simple carcinomas, special types of carcinomas, sarcomas, and malign mix tumor were defined as

malignant tumors. Simple adenoma, basaloid adenoma, complex adenoma, fibroadenomatous change, duct papilloma, benign mix tumor, duct adenoma was defined as a benign tumor ¹³.

Data was analyzed using SPSS (version 15). The Chi-square test was used to compare results between benign and malignant tumors. Comparisons were made between ultrasonographic images and histopathological sections. Multivariate statistics using discriminant analysis was considered to determine which parameters may be valuable tool to predict the status of the tumor.

RESULTS

There were 78 masses and 20 of them (26%) were classified as benign tumors, 58 of them (74%) were classified as malignant tumors by histopathologic examinations. Ultrasonographic characteristics of tumor groups were summarized in *Table 1*.

In benign tumors round-oval and irregular shape of tumors were 80% and 20%, whereas in malignant tumors these rates were 22% and 78%, respectively. Although tumors with a round-oval shape were likely to be benign ($P<0.01$), irregular tumor border gave an increased probability that the tumor malignant ($P<0.01$).

The ultrasonography features and the tissue diagnosis were circumscribed margins (95% were benign and 12% were malignant), microlobulated (57% were malignant), non-defined (5% were benign and 12% were malignant) and spiculated (19% were malignant). A circumscribed margin was very reliable as a predictor of benign tumors ($P<0.001$). However, non-defined margin was not reliable in differentiating between benign and malignant groups ($P>0.05$) (*Fig. 1-3*).

Width-to-CC dimension ratio was >1.4 in benign tumors (60%) and in malignant tumors (40%). Differences between the benign and malignant groups for width-to-CC dimension ratio were not seen ($P>0.05$).

Echogenicity was different between groups. In benign tumors hypoechogenicity was 30% and isoechogenicity was 35%. There was a difference between benign and malignant groups for iso-

echoic and hypoechoic features ($P<0.05$). Tumors with a varied echogenicity (heterogenous echotexture) are likely to be malignant ($P<0.001$).

Fifteen of 20 benign tumors (75%) had shadowing, whereas 3 of 58 malignant tumors (5%) had shadowing. This difference was statistically significant ($P<0.001$). 15 of 20 benign tumors (75%) had acoustic enhancement, whereas 30 of 58 (52%) malignant tumors had acoustic enhancement. No significant differences between benign and malignant tumors were observed in acoustic enhancement.

Whereas all benign tumors (100%) had pseudocapsule, 52 of 58 malignant tumors (90%) had pseudocapsule. The difference for this parameter was not statistically significant between the benign and malignant tumors ($P>0.05$).

Whereas 18 of 20 benign tumors (90%) had calcification, 42 of 58 malignant tumors (72%) had not calcification. Calcification was very reliable as a predictor of benign tumor ($P<0.001$). In addition, non calcification was more likely to be malignant ($P<0.01$).

The mean lengths of benign and malignant tumors were determined as 1.7 and 6.2 cm respectively (*Fig. 4*). A significant difference was seen between the benign and malignant tumors (the mean size being larger than benign) ($P<0.05$).

DISCUSSION

It had previously been declared that a significant difference was seen between the benign tumors and malignant tumors with regard to size of the tumors, with malignant tumors on average being larger than benign ³. In our study, we found that a larger tumor might indicate malignancy, but other ultrasonographic features were more reliable for this purpose as described by previous study ³.

In a study conducted in humans, it had previously been reported that ultrasonography features that most reliably characterize masses as benign were round or oval shape (94% were benign), circumscribed margins (91% were benign) ¹². In another study, conducted in female dogs, it was reported that, seven of the eight benign tumours had regular margins and were spherical or oval in shape ¹⁴. In our study, we concluded that this two

features could be strictly applied to predict a diagnosis of benignity. In addition to these results, Rahbar et al.¹² found that in humans, features that characterize masses as malignant included irregular shape (61% were malignant), microlobulated (67% were malignant) or spiculated (67% were malignant) margins, and width-to-CC dimension ratio of 1.4 or less (40% were malignant). In addition, Gonzales et al.¹⁴ were reported that, the ultrasonographic images of nine of the 11 malignant tumours had irregular margins and were polymorphous in shape. In our study, we concluded that features that have irregular shapes, micro-lobulated margins might indicate malignancy, but width-to-CC dimension ratio of 1.4 could not be applied to predict a diagnosis of tumor classification.

Nyman et al.³ indicated that there was a difference in echogenicity between the different groups of tumors. The benign tumors had equal distribution of being hypoechoic, isoechoic, or variable echogenicity and texture³. In this study, the benign tumors were seen different distribution of benign hypoechoic (30%), isoechoic (35%), or varied in echogenicity. Tumors with a varied echogenicity are more likely to be malignant.

It had previously been reported that distal acoustic enhancement and/or shadowing were observed in equal distribution between benign and malignant tumors³. In addition, tumors with shadowing were more likely to be benign³. In our study, we found that tumors with shadowing and/or enhancement are more likely to be benign which was similar to the previously mentioned study, which reported that 15 of 25 (60%) benign tumors had acoustic enhancement and shadowing, whereas 44 of 79 (55.7%) malignant tumors had acoustic enhancement and shadowing.

The results of this study indicated that, the ultrasonography was extremely useful for the evaluation of canine mammary gland tumors, especially in the determination of tumor size, shape, border irregularity, echotexture, internal echogenicity and acoustic transmission.

Acknowledgments

The authors would like to thank the staff of the Department of Pathology at the University of Ankara for their help in this work.

REFERENCES

1. **Johnston SD, Kustritz MVR, Olson PNS:** Disorders of mammary glands of the bitch. **In,** Johnston SD, Kustritz MVR, Olson PNS (Eds): *Canine and Feline Theriogenology*. 243-256, WB Saunders Company, Philadelphia, 2001.
2. **Moulton JE:** Tumors of mammary gland. **In,** Moulton JE (Ed): *Tumors in Domestic Animals*. 3th ed. 518-552, University of California Press, Los Angeles, CA, 1990.
3. **Nyman HT, Kristensen AT, Lee MH, Martinussen T, McEvoy FJ:** Characterization of canine superficial tumors using gray-scale B mode, color flow mapping, and spectral doppler ultrasonography-A multivariate study. *Vet Radiol Ultrasound*, 47, 192-198, 2006.
4. **Perez Alenza MD, Pena L, Del Castillo N, Nieto AI:** Factors influencing the incidence and prognosis of canine mammary tumours. *J Small Anim Pract*, 41, 287-291, 2000.
5. **Novosad CE:** Principles of treatment for mammary gland tumors. *Clin Tech Small Anim Pract*, 18, 107-109, 2003.
6. **Sorenmo K:** Canine mammary gland tumors. *Vet Clin North Am: Small Anim Pract*, 33, 573-596, 2003.
7. **Yamagami T, Kobayashi T, Takahashi K, Sugiyama M:** Prognosis for canine malignant mammary tumors based on TNM and histologic classification. *J Vet Med Sci*, 58, 1079-1083, 1996.
8. **Cassali GD, Gobbi H, Malm C, Schmitt FC:** Evaluation of accuracy of fine needle aspiration cytology for diagnosis of canine mammary tumours: Comparative features with human tumours. *Cytopathology*, 18, 191-196, 2007.
9. **Malik G, Waqar F, Buledi GQ:** Sonomammography for evaluation of solid breast masses in young patients. *J Ayub Med Coll Abbottabad*, 18, 34-37, 2006.
10. **Kamio T, Hamano K, Kameoka S, Kimura T:** Ultrasonographic diagnosis of breast cancer with intraductal spreading of cancer cells. *Nippon Geka Gakkai Zasshi*, 97, 338-42, 1996.
11. **Baker JA, Soo MS:** The evolving role of sonography in evaluating solid breast masses. *Semin Ultrasound CT MR*, 21, 286-296, 2000.
12. **Rahbar G, Sie AC, Hansen GC, Prince JS, Melany ML, Reynolds HE, Jackson VP, Sayre JW, Bassett LW:** Benign versus malignant solid breast masses: US differentiation. *Radiology*, 213, 889-894, 1999.
13. **Misdorp W:** Tumors of the mammary gland. **In,** Meuten DJ (Ed): *Tumors in Domestic Animals*. 575-605, Iowa: 2121, State Avenue, 2002.
14. **Gonzalez de BA, Garcia FP, Mayenco Aguirre AM, Sanchez de la MM:** Ultrasonographic imaging of canine mammary tumours. *Vet Rec*, 143, 687-689, 1998.

Table 1. Ultrasonographic characteristics of malign and benign tumors
Tablo 1. Malign ve benign tümörlerin ultrasonografik özellikleri

Parameters		Benign (n=20)	Malignant (n=58)	P
Shape	Round-oval	16 (80%)	13 (22%)	P<0.01
	Lobulations		12 (21%)	
	Irregular	4 (20%)	45 (78%)	P<0.01
Margins	Circumscribed	19 (95%)	7 (12%)	P<0.001
	Microlobulated		33 (57%)	
	Non-defined Spiculated	1 (5%)	7 (12%) 11 (19%)	P>0.05
Width-CC dimension ratio	>1.4	12 (60%)	23 (40%)	P>0.05
	≤1.4	8 (40%)	35 (60%)	P>0.05
Echotexture	Heterogenous	7 (35%)	49 (84%)	P<0.001
	Homogeneous	13 (65%)	9 (16%)	P<0.05
Internal echogenicity	Varied	7 (35%)	49 (84%)	P<0.001
	Isoechoic	7 (35%)	5 (9%)	P<0.05
	Hypoechoic	6 (30%)	4 (7%)	P<0.05
Acoustic transmission	Not present	5 (25%)	25 (43%)	P>0.05
	Enhancement	15 (75%)	30 (52%)	P>0.05
	Shadowing	15 (75%)	3 (5%)	P<0.001
Pseudocapsule	Present	20 (100%)	52 (90%)	P>0.05
	Absent		6 (10%)	
Calcification	Present	18 (90%)	16 (28%)	P<0.001
	Absent	2 (10%)	42 (72%)	P<0.01
Size, mean length (cm)		1.7	6.2	P<0.05

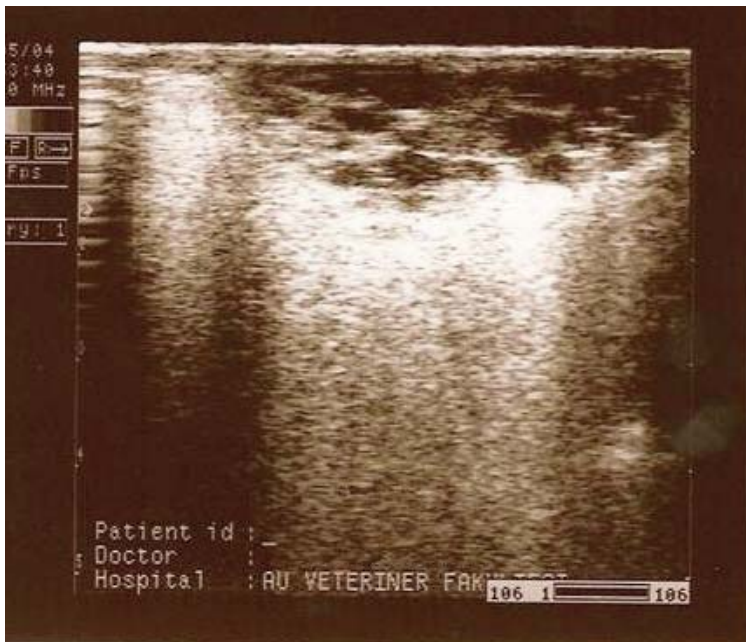

Fig 1. An USG image of a mammary malign mix tumor in an 11-years-old Terrier. Note the irregular shape, lobulations, acoustic transmission and invasiveness into the surrounding tissue

Şekil 1. 11 yaşlı Terrier ırkı bir köpeğin meme dokusundaki bulunan malign miks tümörün ultrasonografik görüntüsü. Tümör düzensiz şekil, lobulasyon, akustik iletim ve çevre dokulara doğru yayılan uzantılara sahip kenar özelliği göstermektedir

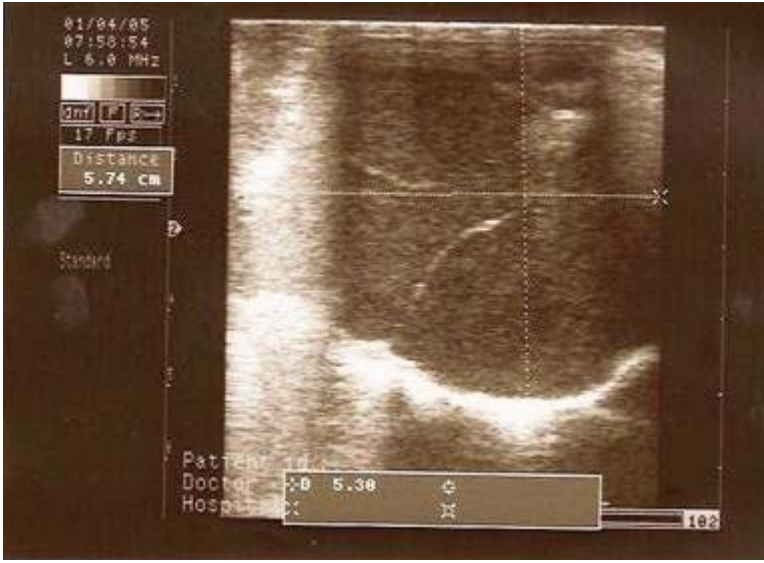

Fig 2. A gray-scale image of malign mix tumor in a 7-years-old Terrier. Note the heterogeneous echotexture, varied internal echogenicity

Şekil 2. 7 yaşlı Terrier ırkı köpeğin meme dokusundaki bulunan malign miks tümörün ultrasonografik görüntüsü. Tümör heterojen ekotekstür ve karma iç ekojenite özelliklerini göstermektedir

Fig 3. An USG image of a benign mix tumor in an 8-years-old Terrier. Note the round-oval shape, circumscribed margins, and pseudocapsule

Şekil 3. 8 yaşlı Terrier ırkı köpeğin meme dokusundaki bulunan benign miks tümörün ultrasonografik görüntüsü. Tümör yuvarlak-oval şekil, sınırlı bir kenar yapı ve yalancı kapsül özelliklerini göstermektedir

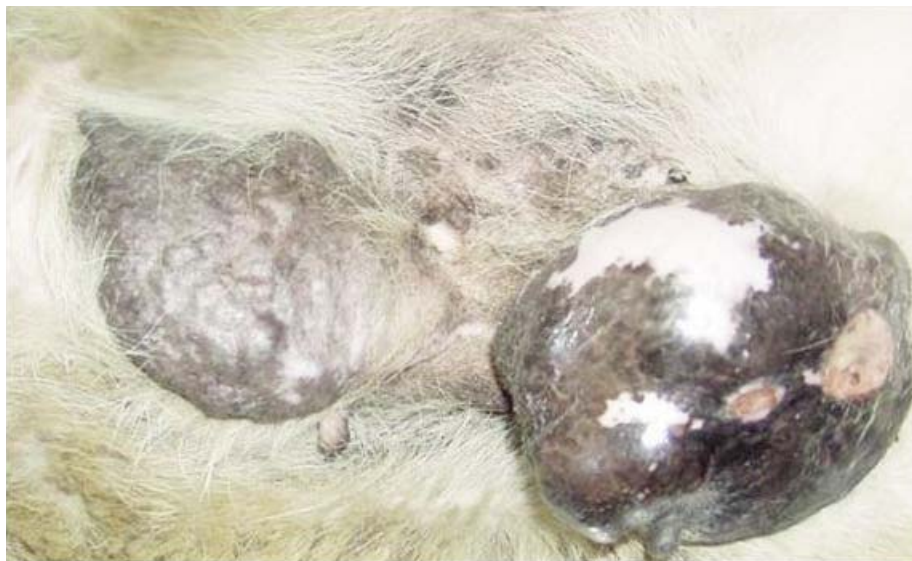
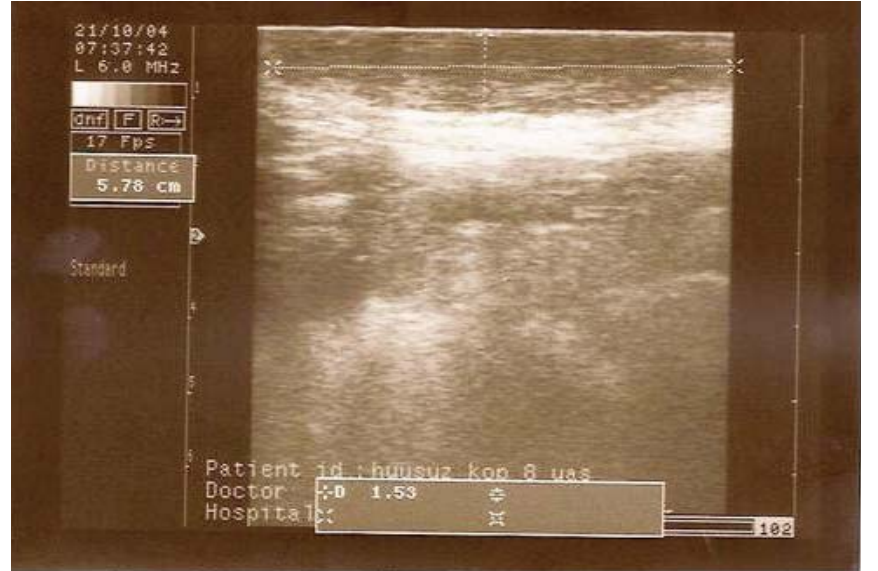
Fig 4. A macroscopic image of a complex carcinoma in a 10-years-old cross breed dog

Şekil 4. 10 yaşlı kırma ırklı bir köpeğin meme dokusunda bulunan kompleks karsinoma tanılı tümörün makroskopik görünümü