

## PARTIAL LACK OF THE LEFT RENAL DIVISIONS IN A DOMESTIC FOWL CASE REPORT

Şükrü Hakan ATALGIN\* Emine Ümran BOZKURT\*\* İbrahim KÜRTÜL \*\*\*

\* Abant İzzet baysal üniversitesi, Mudurnu süreyya astarcı meslek yüksekokulu, Mudurnu , Bolu- TÜRKİYE

\*\* Harran Üniversitesi Veteriner Fakültesi Anatomi Anabilim Dalı, Şanlıurfa –TÜRKİYE

\*\*\* Kafkas Üniversitesi Veteriner Fakültesi Anatomi Anabilim Dalı, Kars –TÜRKİYE

Yayın Kodu: 2007/09-G

### Summary

During the dissection process of a nother research, in a mature and sexually functioning fowl, none of the renal divisions in the left kidney was observed to fully develop, in spite of the fact that there was no sign of a nother pathologic condition. The renal divisions of the right kidney we re mature a nd fully developed.

**Key Words:** Abnormality, Domestic fowl, Left renal divisions

## Evcil Bir Tavukta Sol Böbrek Division'larının Kısmen Bulunmaması Olgusu

### Özet

Bir başka araştırmanın diseksiyon aşamasında, erişkin ve seksüel olak aktif bir tavukta, başka herhangi bir patolojik bir durum göz lenmeksizin, sol renal division'ların tam olarak gelişim göstermediği gözlemlendi. Sağ böbrek division'larının tamamen normal bir gelişim gösterdiği belirlendi.

**Anahtar Sözcükler:** Anomali, Evcil tavuk, Sol böbrek division'ları

---

### İletişim (Correspondence)

Phone: +90 374 4216233/4602

e-mail: atalgin\_s@ibu.edu.tr

## INTRODUCTION

Although kidney in avian species is a paired urinary organ as is the case in mammals <sup>1,2</sup>, it possesses several unique features in both anatomically and physiologically such as divisions <sup>3</sup>. Both kidneys in avian species are composed particularly of three renal divisions <sup>1,3,4,5</sup>. Occurrence of the anomalies in these divisions in domestic fowl is very rare and is encountered particularly as a part of severe congenital pathological conditions.

## CASE HISTORY

This is a report on the partial lack of the left renal division in a domestic fowl. The case was encountered during the dissection process of another research. The animal was mature, sexually functioning, and had no sign of another pathological condition. It was 6 weeks old, weighing 1620 gr, and were fed a ration which contained %38 corn, %15 wheat, %5 barley, %22 Soybean meal, %10 Full fat soybean, %3 fish meal, and %3.5 oil, with a metabolize energy of 3200 kcal/kg.

The animal was exsanguinated and put in 10% formalin solution for further preservation. It was dissected and photographed by a Datron digital camera.

Nomina Anatomica Avium <sup>6</sup> was used for the anatomical nomenclature.

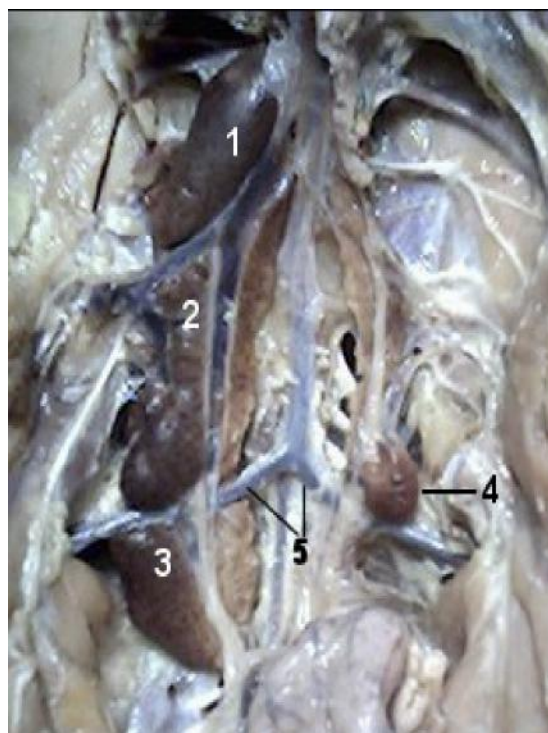
## RESULTS and DISCUSSION

The renal divisions of the right kidney were fully developed in their anatomic in situ topography as the cranial (lobus renalis cranialis), middle (lobus renalis medialis), and caudal (lobus renalis caudalis) renal divisions (Figs.1/1;1/2;1/3). On the other hand, none of the renal divisions in the left kidney was fully developed. In other words, there was no fully mature renal division in the left kidney. Caudal part of the middle renal division was present and seemed to be functioning. The others were immature, being only as a premature organ draft.

Studies <sup>7</sup> have indicated that number of the divisions in the kidney of the domestic fowl might occasionally be more than three. As far as we search,

there is only one report in the literature indicating an aplasia of the right kidney in two cases out of 13.483 necropsies in domestic fowl<sup>8</sup>. This report also indicates that a gross congenital anomaly case in relation particularly with the kidneys and related organs of the urinary system of any avian species is extremely rare even though studies reported renal changes occurred principally in tubule morphology at ultrastructural level <sup>9</sup>. Our case has documented the partial lack of the renal divisions of the left kidney in domestic fowl.

As far as clinical observation is concerned, the partial lack of the renal divisions of the left kidney in this study seems to have no effect on the function of the urinary system. This suggests the fact that the other potential renal divisions can clearly compensate the function of the immature divisions, as is the case in mammals <sup>10</sup>.



**Fig.1.** Partial lack of the renal divisions of the kidney in a domestic fowl.

**Şekil.1.** Evcil tavukta böbrek division'larının kısmen bulunmaması olgusu.

1. Lobus renalis cranialis dexter, 2. Lobus renalis medialis dexter, 3. Lobus renalis caudalis dexter, 4. Lobus renalis sinister 5. Arteria ischiadica.

## REFERENCES

1. **King AS, Mcllelland J:** Birds, their Structure and Function. Second Edition. Balliere Tindall. Philadelphia, 1984.
2. **Nickel R, Schummer A, Seiferle E :** Anatomy of Domestic Birds. Verlag Paul Parey. Berlin Hamburg, 1977.
3. **Dursun N:** Evcil Kuşların Anatomisi, Medisan Yayınevi, Ankara, 2002.
4. **Demirsoy A:** Yaşamın Temel Kuralları, Omurgalılar/Amniyota (Sürüngenler, Kuşlar, Memeliler) Cilt-III/ Kısım I I, Meteksan Ankara, 1992.
5. **Whitton G.C:** Sturkie's Avian Physiology, Fifty Edition, Academic Press, New York, 2000.
6. **Julian JB:** Nomina Anatomica Avium. Published by The Nuttall Ornithological Club. No:23, Cambridge, Massachusetts, 1993.
7. **Doğuer S, Ereçin Z:** Evcil Kuşların Komparatif Anatomisi. A.Ü. Veteriner Fakültesi, Ders Kitapları, Ankara Üniversitesi Basımevi, Ankara, 1964
8. **Grewal GS, Singh B, Sahota PS:** Congenital anomalies of domestic fowl: seven cases. *Avian Dis* 20 (3): 504-506, 1976.
9. **Maxwell MH, Mbuqua CW:** Ultrastructural abnormalities in seven day old broilers reared at high altitude. *Res Vet Sci*, 49 (2): 182-189, 1990.
10. **Jacobs C:** The case for a fair compensation policy of economic consequences incurred by living kidney donors. *Nephrol Dial Transplant*, 21 (7): 1764-1765, 2006.



- 1.
- 2.
- 3.
- 4.
- 5.
- 6.
- 7.
- 8.