

## CASE REPORT

## Progressive Ocular Histiocytosis in a Cat

Aynur DEMİR<sup>1(\*)</sup>  Zeynep Nilüfer AKÇASIZ<sup>1</sup>  Özge ERDOĞAN BAMAÇ<sup>2</sup> <sup>1</sup> Istanbul University-Cerrahpaşa, Faculty of Veterinary, Surgery Department, TR-34315 İstanbul - TÜRKİYE<sup>2</sup> Istanbul University-Cerrahpaşa, Faculty of Veterinary, Pathology Department, TR-34555 İstanbul - TÜRKİYE

ORCID: A.D. 0000-0002-5471-1655; Z.N.A. 0000-0003-4857-8891; Ö.E.B. 0000-0002-0352-4841

Article ID: KVFD-2023-29127 Received: 31.01.2023 Accepted: 31.03.2023 Published Online: 09.04.2023

**Abstract:** Feline progressive histiocytosis is a rare proliferative disorder manifested by solitary or multiple cutaneous nodules and papules with potential late distant metastasis. This case study presents clinical, diagnostic imaging, and histopathologic findings and therapeutic approach to progressive ocular histiocytosis detected in a 1.5-year-old male Domestic Shorthair cat with a complaint of a painless firm mass on the left lower eyelid. Magnetic resonance imaging (MRI) of the orbit revealed a tumoral lesion expanding from the left lower eyelid into the intraorbital space, translocating the bulbus from ventrolateral to dorsomedial. The computed tomography (CT) visualized a destructive lesion on the infraorbital edge, which was histopathologically confirmed to be progressive nodular histiocytosis.

**Keywords:** Cat, Eye, Computed tomography, Magnetic resonance imaging, Progressive histiocytosis

## Bir Kedide Progresif Oküler Histiyoitozis

**Öz:** Feline progresif histiyoitozis, olası geç dönem uzak metastazlı soliter veya çoklu kutanöz nodüller ve papüllerle kendini gösteren nadir bir proliferatif hastalıktır. Bu olgu sunumunda sol alt göz kapağında ağrısız sert kitle şikayeti ile başvuran 1.5 yaşında erkek evcil kısa tüylü bir kedide saptanan ilerleyici oküler histiyoitozun klinik, tanısal görüntüleme, histopatolojik bulgular ve tedavi yaklaşımı sunulmaktadır. Orbitanın manyetik rezonans görüntülemesinde (MRG), sol alt göz kapağından intraorbital boşluğa doğru genişleyen ve bulbusu ventrolateralden dorsomedial'e kaydıran tümöral bir lezyon görüldü. Bilgisayarlı tomografi (BT), infraorbital kenarda histopatolojik olarak progresif nodüler histiyoitoz olduğu doğrulanan yıkıcı bir lezyonu görüntüledi.

**Anahtar sözcükler:** Bilgisayarlı tomografi, Göz, Kedi, Manyetik rezonans görüntüleme, Progresif histiyoitozis

## INTRODUCTION

Feline progressive histiocytosis (FPH) is a rare disorder, with limited reports in horses, cattle, dogs, and humans<sup>[1,2]</sup>. The incidence of the disorder in cats is unknown due to the differential diagnostic challenge. Histiocytic neoplasms are classified as focal and self-restricting (cutaneous histiocytoma), locally aggressive (localized histiocytic sarcoma), and multisystemic lesions (disseminated histiocytic sarcoma)<sup>[1,2]</sup>. No breed, age, and gender predisposition has been noted<sup>[3]</sup>.

The lesions emerge as solitary or multifocal painless, alopecic, or ulcerated cutaneous nodules on the head, neck, and distal extremities and can be easily confused with other allergic, infectious, and neoplastic types of skin disorders<sup>[2-4]</sup>. Histiocytosis may show a spontaneous

regression in dog<sup>[5]</sup>, on the contrary, it can progress into a malignant histiocytic sarcoma-like neoplasm, with lymph node, liver, spleen, kidney, lung, and even bone marrow metastasis in cat<sup>[2,3,6]</sup>. It is usually a fatal disorder with the lack of efficient therapeutic options.

This report presents clinical, imaging, and histopathological findings and surgical treatment, and its postoperative outcome of an infrequently encountered diffuse progressive histiocytosis case in a male Domestic Shorthair cat expanding from the lower eyelid skin of the left eye into the soft tissues of the intraorbital cavity.

## CASE HISTORY

A veterinary practitioner submitted a 1.5-year-old neutered male Domestic Shorthair to the Istanbul University-

How to cite this article?

Demir A, Akçasız ZN, Erdoğan Bamaç Ö: Progressive ocular histiocytosis in a cat. Kafkas Univ Vet Fak Derg, 29 (3): 305-309, 2023.  
DOI: 10.9775/kvfd.2023.29127

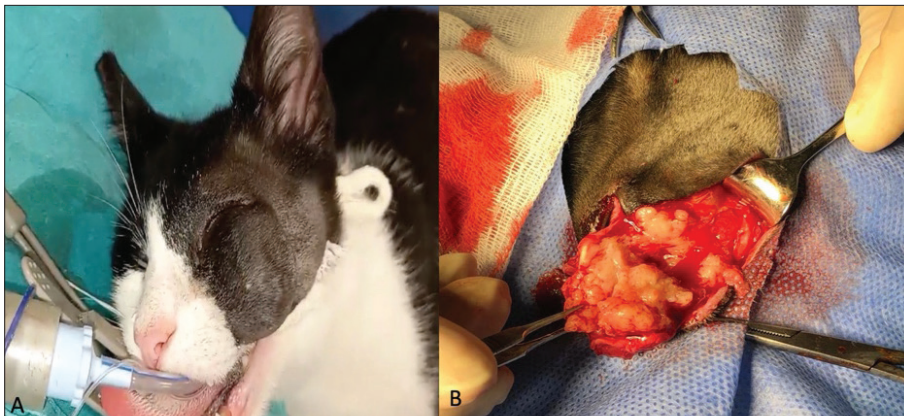
(\*) Corresponding author: Aynur DEMİR

Phone: +90 506 755 0873

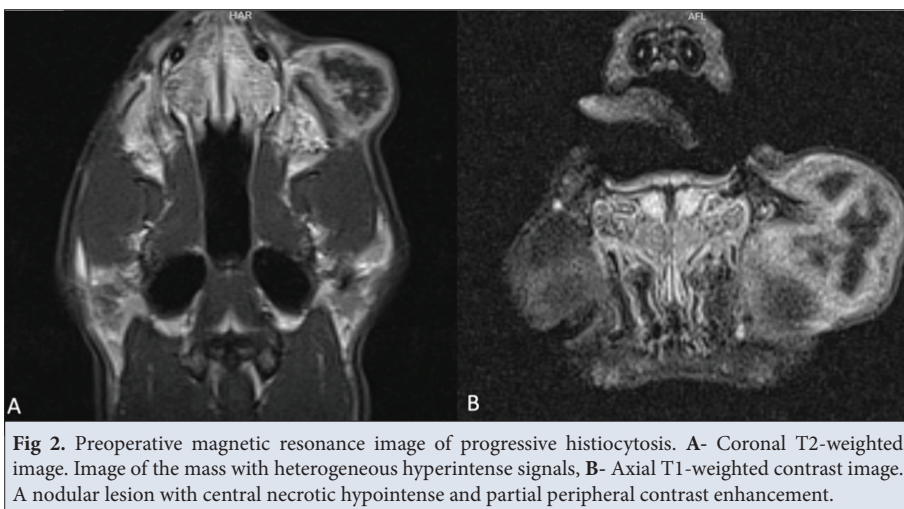
E-mail: aynur.demir@istanbul.edu.tr



This article is licensed under a Creative Commons Attribution-NonCommercial 4.0 International License (CC BY-NC 4.0)



**Fig 1.** A 1.5 years old Domestic Shorthair cat. A- with photophobia and retrobulbar swelling. B- This swelling appeared to be a large solid mass attached tightly to the bulbar surface of the left lower eyelid



**Fig 2.** Preoperative magnetic resonance image of progressive histiocytosis. A- Coronal T2-weighted image. Image of the mass with heterogeneous hyperintense signals, B- Axial T1-weighted contrast image. A nodular lesion with central necrotic hypointense and partial peripheral contrast enhancement.

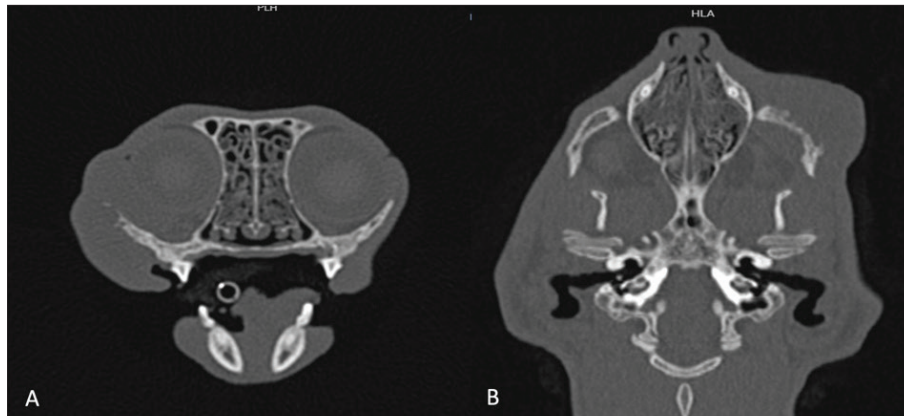
Cerrahpaşa, Veterinary Teaching and Research Hospital for further evaluation of a fast-growing mass on the left lower eyelid. In the relevant case, an “informed consent form” containing the entire process was obtained. The patient initially received for a week systemic antibiotics and anti-inflammatory drugs with no recovery.

Physical examination revealed no abnormality in the patient’s general health status. However, a round-shaped solid tumoral mass with an approximate diameter of 3 cm was detected on the lower eyelid of the left eye, attached firmly to the underlying zygomatic arch. Conjunctival congestion, hyperemia, and partial dorsomedial eyeball deviation were noted. The affected eye resisted retropulsion, and the protruding third eyelid could not be stretched onto the ocular surface (*Fig.1-A*). No intraocular lesion was detected. Menace response, pupillary light, and dazzle reflexes were normal. Right (15 mm/min) and left (7 mm/min) eyes Schirmer’s tear test and right (22 mmHg) and left (24 mmHg) intraocular pressure values were within reference range, of 11-23 mm/min and 15-25 mmHg, respectively. The left submandibular lymph node was mildly enlarged. Detailed blood testing exhibited no

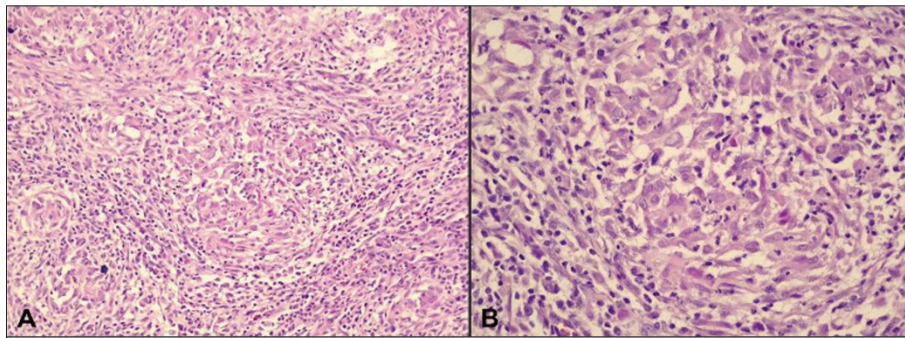
abnormal values, and thoracic and abdominal radiography revealed no evidence of metastasis.

Orbital magnetic resonance imaging (MRI) revealed an exophytic, infiltrative mass with heterogeneous contrast expanding from the subcutaneous space of the left lower eyelid into the intraorbital cavity with conjunctival and muscle involvement. Orbital computed tomography (CT) confirmed destructive lesions on the base of the orbit.

MRI of the brain and orbit was performed by a 1.5 T MRI unit. T1W FLAIR images were obtained after intravenous injection of gadopentetate dimeglumine (0.1 mmol/kg). Sequences of transverse, sagittal, and coronal planes revealed a maximum of 2.6x2.6x2.2cm-sized ventrolaterally located mass with a subcutaneous fatty content on the caudal aspect of the left eye. T2-weighted images showed a mass lesion with heterogeneous hyperintense signals, and T1-weighted contrast images revealed a centrally hypointense nodular lesion with partial peripheral contrast enhancement, particularly indicating a potential malignant mass of aggressive behavior with central necrosis. Fatty planes between the defined lesion and the orbit were undistinguished (*Fig. 2-A,B*).



**Fig 3.** Preoperative computed tomography images. **A-** Ventrolateral appearance of the mass in the axial plane, **B-** Partial destruction of the left orbital bone in the coronal plane



**Fig 4.** Histopathological findings. **A-** Subcutaneous densely cellular histiocytic nodule with inflammatory cells (H&E, original magnification x200), **B-** Atypical cells with round to polygonal cell borders, lightly eosinophilic cytoplasm and irregular vesicular nuclei with marginated chromatin. Moderate anisocytosis and anisokaryosis are remarkable (H&E, original magnification x400)

CT imaging was performed by the Siemens SOMATOM Scope VB30 (0.6 mm, 110 Kv, 28 mA with an exposure time of 14 sec). The scans demonstrated a mass of approximately 2.6x2.6x2.2 cm ventro-laterally located within the subcutaneous fat plane on the caudal aspect of the left eye, and partial destruction of the orbital bone was noted (*Fig. 3-A,B*).

Immediately after MR and CT imagines and while the patient was still under general anesthesia, the mass with extraocular soft tissue and bone involvements along with bulbus oculi were surgically removed. The tumoral lesion on the left lower eyelid was excised through a linear incision on the skin, and then orbital exenteration was performed (*Fig. 1-B*). Honeycomb-like lesions on the inferior wall of the bony orbit were removed by a 16 cm rongeur until macroscopically intact tissue was achieved, and the resected tissues were then submitted in 10% neutral buffered formalin for histopathology. After routine histopathological preparation and sectioning procedures, 4 µm thick sliced samples were stained with hematoxylin and eosin (H&E) and examined by a light microscope. The histologic examination of the tumor revealed multinodular histiocytic infiltrates composed of round to polygonal cells with a light eosinophilic cytoplasm and irregular

vesicular nuclei. Moderate anisocytosis and anisokaryosis were observed, and a reactive inflammatory response was prominent (*Fig. 4-A,B*). After ocular enucleation, a drain was placed in the medial canthus. Following full anesthetic recovery, the patient was discharged prescribing ceftriaxone (50 mg/kg SID IM), and meloxicam (0.01 mg/kg SID SC) for one week. An Elizabethan collar was recommended for two weeks. The drain and the sutures were removed on the fourth and twelfth postoperative day, respectively, and periodic follow-ups were scheduled to evaluate potential recurrence and infection. The owner declined postoperative radiotherapy and chemotherapy. During five months follow-up period no health complaint was noted.

## DISCUSSION

This is the first comprehensive case study to present clinical findings, including diagnostic imaging scans (MRI and CT), histopathological features, and a therapeutic approach to feline progressive ocular histiocytosis among few previously reported cases in cats<sup>[4,6]</sup>. This is also the first and only case in a cat where ocular tissues were affected, and advanced imaging techniques were utilized for clinical diagnosis. Therefore, this report is

considered to provide a better understanding of the lesion and contribute to the literature. A comparative evaluation of imaging scans of its human counterpart suggests the potential efficacy of these techniques in feline practice.

Progressive histiocytosis is usually encountered in young dogs<sup>[7]</sup>, whereas in cats it typically affects middle-aged to older cats (Age range=7-17)<sup>[2]</sup>. Despite the lack of known breed and gender predisposition, females are slightly more prone to develop the disorder<sup>[8]</sup>. In a study by Costa et al.<sup>[8]</sup>, 21 of 26 cases were represented by approximately 9.3-year-old Domestic Shorthair cats. FPH is initially manifested by well-circumscribed solitary skin nodules that may extend to 4 cm in diameter<sup>[9]</sup>. Nevertheless, it is usually smaller than 2 cm, showing progressive growth as multiple papules, nodules, and plaques<sup>[2]</sup>. Skin lesions are most likely to have developed in different species diagnosed with progressive histiocytosis; however, there are only few reported cases of FPH, particularly with ocular involvement<sup>[1]</sup>. Unlike the previously documented cases, progressive histiocytosis occurred in a young (1.5 years of age) male cat, developing as a primary ocular mass showing rapid growth in two months in the presented report. Moreover, the lower eyelid skin was affected, including the intraorbital soft tissues with inferior orbital wall involvement. The solid lesion was more extensive than the previously reported cases and showed exophytic growth, compressing the bulbus oculi on the orbit's caudal portion.

Clinical findings in FPH differ due to the affected organ systems. Yaygingül et al.<sup>[10]</sup> reported that unilateral exophthalmos, nictitating membrane protrusion, secondary conjunctival hyperemia, keratitis, strabismus, dysphagia, blindness, glaucoma, retinoschisis, circulatory alterations or edema, changes in pupillary light or corneal reflexes were detected in a calf due to progressive paraorbital histiocytosis. In our case restricted ocular and lower eyelid movements of the left eye due to the lesion's localization and tumoral infiltration of the extraocular muscles were determined. Decreased palpebral reflex resulting in lagophthalmos, exophthalmos, protruded nictitating membrane, conjunctival hyperemia, the eyeball's partial dorsomedial deviation, and partial ventral resistance to retropulsion were also noted.

Histological examinations of tumor masses often reveal proliferation of pleomorphic histiocytes with marked hemophagocytosis<sup>[2]</sup>. It is well known that FPH and feline histiocytic sarcoma (FHS) have common histologic features<sup>[2,7,8]</sup>. Especially, the morphological features of the advance form of FPH resemble those of FHS<sup>[2]</sup>. In our case, the round to polygonal cells that constituted the multinodular histiocytic infiltrates with moderate anisocytosis and anisokaryosis and the reactive inflammatory response was compatible with the histologic

findings of the previous reports of FPH<sup>[2,7]</sup>. Also, absence of high mitotic index and numerous multinucleated giant cells with bizarre mitotic figures differentiated the histologic findings of our case from those of FHS<sup>[8]</sup>.

Advanced imaging techniques (MRI and CT scan) are utilized to identify the depth and extent of the ocular and orbital lesions aiding in differential clinical diagnosis, which facilitates the most efficient therapeutic protocol, and also to monitor the prognosis of the defined disorder<sup>[9]</sup>. Despite the valuable diagnostic and surgical guidance of CT scan and MRI<sup>[11]</sup>, Park et al.<sup>[12]</sup> suggested that both imaging techniques might fail to make a specific radiological diagnosis in malignant fibrous histiocytoma (MFH) cases due to the poor or inconsistent signaling. In CT scans, MFH usually appeared to be a large multilobulated soft-tissue mass isoattenuating to muscle due to necrosis, hemorrhage, or myxoid material at the center, and calcification or ossification could be imaged with relatively poor preciseness like 5-20%. In MRI, MFH is typically visualized as isoattenuating mass to muscle tissue in T1-weighted scans and heterogenous hyperintense mass in T2-weighted sequences. Khan and Sepadhari<sup>[9]</sup> reported that a CT scan of the brain demonstrated osteolytic lesions in the right frontal and zygomatic bones in a patient with ocular histiocytosis, and MRI revealed a heterogenous exophytic infiltrative mass extending from the intraorbital cavity to the subcutaneous space. In the presented case, we obtained similar data concerning the radiographic imaging of the lesion. The closeness of the mass to the orbit necessitated MRI for clinical diagnosis. MRI of the patient's orbit and periocular areas revealed a left lower eyelid-originating mass near the left medial-inferior orbital wall, extending into the left orbital cavity and intraorbital soft tissues, pushing out the eye bulb from ventrolateral to dorsomedial. The indistinct moth-eaten appearance of the medial-inferior orbital wall suggestive of lytic areas was confirmed as the destruction of the orbital bone on CT scans.

While localized eyelid lesions are successfully treated by excisional biopsy, surgical management of FPH varies. Kim et al.<sup>[5]</sup> suggested that the primary therapeutic approach to canine cutaneous histiocytomas is surgical excision, and local recurrence or occurrence of a new lesion on the other body parts is highly unlikely. Coste et al.<sup>[8]</sup> showed that a wide local excision with clear surgical margins generated favorable outcomes in seven cats with FPH located on different body regions other than the orbit. On the contrary, in a study by Affolter and Moore<sup>[2]</sup>, local recurrence was noted in four out of 8 cats with a solitary mass or limited cutaneous lesions with a few nodules that underwent surgical excision and new tumoral lesions developed in other body parts in all surgically treated cats. The results of the presented case are

compatible with the outcomes of some of the previously mentioned therapeutic approaches. Our treatment protocol comprised exenteration of the affected eye and partial ostectomy of the orbital floor. Although the mean survival time for progressive ocular histiocytosis in cats documented only in few case studies is unknown, survival for FPH encountered in different body sites other than the orbit was shown to be 96 days (range=41-238 days). In another study, the mean survival time was reported to be 13.5 months<sup>[13]</sup>. Neither complications nor metastases were detected in the presented case study in which we evaluated an ocular form of FPH in a 5-month-follow up period. Therefore, a radical surgical removal in FPH with ocular involvement might be a good treatment choice like its human counterpart.

In conclusion, progressive histiocytosis, is very rare in cats, usually occurs as a skin lesion and sometimes self-limited and regressed, while it can become very aggressive and metastasize to internal organs. For this reason, early and differential diagnosis of the disease is very important for the prognosis of the patient. This case report showed that FPH can also occur in the paraorbital region and orbit. In addition, it is aimed to emphasize here the diagnostic value of cross-sectional imaging and the efficacy of surgical excision and curettage in the treatment of ocular lesion.

#### Availability of Data and Materials

The authors declare that the data supporting the study findings are also presented to the corresponding author (A. Demir).

#### Acknowledgements

The authors thank the owner of the animal and the surgical team who assisted in the conduct of this study.

#### Competing Interest

The authors declared no conflict of interest regarding this report.

#### Author's Contributions

The authors have equally contributed to the preparation of this

manuscript. AD and NA designed and supervised this study. AD, NA, and OEB collected and analyzed data. OEB wrote the pathological examination section, AD and NA wrote the first draft of the rest of the text. All authors contributed to the critical revision of the article and read and approved the final version.

## REFERENCES

- Hülskötter K, Pfankuche VM, Rocks A, Junginger J, Lei WKJ, Vries E, Kruppa J, Baumgartner W, Wohlsein P: Feline progressive histiocytosis - A case report with a review of the literature. *WTM*, 105 (1/2): 41-47, 2018.
- Affolter VK, Moore PF: Feline progressive histiocytosis. *Vet Pathol*, 43 (5): 646-655, 2006.
- Treggiari E, Ressel L, Polton GA, Benoit J, Desmas I, Blackwood L: Clinical outcome, PDGFR $\beta$  and KIT expression in feline histiocytic disorders: A multicentre study. *Vet Comp Oncol*, 15 (1): 65-77, 2017. DOI: 10.1111/vco.12142
- Trost ME, Ramos AT, Masuda EK, dos Anjos BL, Cunha MGMCM, Graça DL: Malignant histiocytosis in a cat. Case report. *Braz J Vet Pathol*, 1 (1): 32-35, 2008.
- Kim B, Lim J, Shim JH, Seo K, Kang S: Spontaneous regression of eyelid histiocytoma in a Maltese dog. *J Vet Clin*, 39 (3): 121-125, 2022. DOI: 10.17555/jvc.2022.39.3.121
- Scurrall E, Trott A, Rozmanec M, Belford CJ: Ocular histiocytic sarcoma in a cat. *Vet Ophthalmol*, 16, 173-176, 2013. DOI: 10.1111/vop.12052
- Moore PF: A review of histiocytic diseases of dogs and cats. *Vet Pathol*, 51 (1): 167-184, 2014. DOI: 10.1177/0300985813510413
- Coste M, Prata D, Castiglioni V, Minoli L, Etienne-Raffestin CL, Boulouha L, Lagadic M: Feline progressive histiocytosis: A retrospective investigation of 26 cases and preliminary study of Ki67 as a prognostic marker. *J Vet Diagn Invest*, 31 (6): 801-808, 2019. DOI: 10.1177/1040638719884950
- Khan SN, Sepahdari AR: Orbital masses: CT and MRI of common vascular lesions, benign tumors, and malignancies. *Saudi J Ophthalmol*, 26 (4): 373-383, 2012. DOI: 10.1016/j.sjopt.2012.08.001
- Yayingül R, Kiliç N, Epikmen ET, Akin İ, Avcı H: Paraorbital malignant histiocytosis in a Holstein calf. *Atatürk Üniv Vet Bil Derg*, 12 (1): 71-75, 2017. DOI: 10.17094/ataunivbd.309777
- Kanazawa T, Karatsu K, Kuramae T, Ishihara M: Langerhans cell histiocytosis in the frontal and zygomatic bones of an adolescent girl. *BMJ Case Rep*, 14 (9): e246367, 2021. DOI: 10.1136/bcr-2021-246367
- Park SW, Kim HJ, Lee JH, Ko YH: Malignant fibrous histiocytoma of the head and neck: CT and MR imaging findings. *AJNR*, 30 (1): 71-76, 2009. DOI: 10.3174/ajnr.A1317
- Borucki RB, Neskey DM, Lentsch EJ: Malignant fibrous histiocytoma: database review suggests a favorable prognosis in the head and neck. *The Laryngoscope*, 128 (4): 885-888, 2018. DOI: 10.1002/lary.26909

