

Efficacy and Toxicity of Doxorubicin and Cyclophosphamide for the Neoadjuvant Treatment of Locally Advanced Stage Canine Mammary Tumors

Fikriye Ecem KURUOĞLU ^{1,a} Musa Ozgur OZYIGIT ^{1,b} Deniz NAK ^{1,c} Zehra AVCI KUPELİ ^{1,d}
Zeynep Merve EKİCİ ^{1,e} Davut KOCA ^{1,f} Talha AVCILAR ^{1,g} Mustafa Eren SAHİN ^{1,h} Yavuz NAK ^{1,i}
Abid Hussain SHAHZAD ^{2,j}

¹Bursa Uludag University Veterinary Faculty, Department of Obstetrics and Gynecology, Gorukle, TR-16059 Bursa - TURKEY

²Theriogenology Department, University of Veterinary and Animal Sciences, Lahore, PAKISTAN

ORCID: ^a 0000-0002-6715-8529; ^b 0000-0003-0682-8127; ^c 0000-0001-8908-5052; ^d 0000-0003-1853-4679; ^e 0000-0002-6904-7275

^f 0000-0002-7962-6959; ^g 0000-0001-7034-9644; ^h 0000-0003-1985-2345; ⁱ 0000-0002-6734-8226; ^j 0000-0002-9442-0000

Article ID: KVFD-2020-24112 Received: 25.02.2020 Accepted: 27.08.2020 Published Online: 05.09.2020

How to Cite This Article

Kuruoglu FE, Ozyigit MO, Nak D, Avci Kupeli Z, Ekici ZM, Koca D, Avcilar T, Sahin ME, Nak Y, Shahzad AH: Efficacy and toxicity of doxorubicin and cyclophosphamide for the neoadjuvant treatment of locally advanced stage canine mammary tumors. *Kafkas Univ Vet Fak Derg*, 26 (6): 729-734, 2020. DOI: 10.9775/kvfd.2020.24112

Abstract

The aim of this study was to investigate the effect and toxicity of a doxorubicin cyclophosphamide combination for neoadjuvant use in dogs with locally advanced mammary tumors. A total of 16 dogs with locally advanced mammary tumors aged 8-14 years was used in this study. Samples were taken from all the dogs via Tru-Cut biopsy and fine needle aspiration biopsy of the lymph nodes prior to neoadjuvant chemotherapy. The samples were sent to the pathology laboratory for histopathological examination. Based on the histopathology results, mammary tumors were diagnosed as adenocarcinoma (n=13), tubulopapillary carcinoma (n=2) and malignant mixed tumors (n=1). For the neoadjuvant chemotherapy, doxorubicin (25-30 mg/m²) and cyclophosphamide (100 mg/m²) were administered via slow IV injection 4 times at 3-week intervals. Clinical findings such as fever, vomiting, anorexia, lethargy, weight loss, alopecia, enteritis, hematuria, and skin ulceration and laboratory findings such as a decrease in neutropenia and hematocrit values were observed. Based on the longest diameter of the tumors before and after four weeks of chemotherapy, a complete response was detected in 2 dogs (12.5%), a partial response was observed in 9 dogs (56.25%) and the disease was stable in 5 dogs (31.25%). According to results, the toxicity, and efficacy of a doxorubicin and cyclophosphamide combination for neoadjuvant chemotherapy in dogs with locally advanced mammary tumors is acceptable, and the treatment is promising.

Keywords: Dog, Locally advanced mammary tumor, Neoadjuvant chemotherapy, Doxorubicin, Cyclophosphamide

Lokal İleri Köpek Meme Tümörlerinde Neoadjuvan Tedavide Doksorubisin ve Siklofosfamidin Etkinliği ve Toksisitesi

Öz

Bu çalışmanın amacı, lokal ileri meme tümürlü köpeklerde neoadjuvan kullanımda doksorubisin ve siklofosfamidin etkinliğini ve toksisitesini araştırmaktır. Bu çalışmada lokal ileri meme tümürlü 8-14 yaş aralığında 16 köpek kullanılmıştır. Neoadjuvan kemoterapi öncesinde tüm köpeklerden Tru-Cut biyopsisi ve ilgili lenf nodundan ince iğne aspirasyon biyopsisi ile örnekler alınmıştır. Numuneler histopatolojik inceleme için patoloji laboratuvarına gönderilmiştir. Histopatoloji sonuçlarına göre, meme tümörlerine adenokarsinom (n=13), tubulopapiller karsinom (n=2) ve malign miks tümör (n=1) tanısı konmuştur. Neoadjuvan kemoterapi olarak, 3 haftalık aralıklarla 4 kez yavaş IV enjeksiyon ile doksorubisin (25-30 mg/m²) ve siklofosfamid (100 mg/m²) uygulanmıştır. Yan etki olarak; kusma, anoreksi, uyuşukluk, kilo kaybı, alopesi, enterit, hematüri ve deri ülseri gibi klinik bulgular, nötropeni ve hematokrit değerlerinde azalma gibi laboratuvar bulguları gözlenmiştir. Kemoterapiden önce ve tedavinin bitiminde 4 hafta sonra tümörlerin en uzun çapına dayanarak, 2 köpekte (%12.5) tam cevap, 9 köpekte (%56.25) kısmi cevap ve 5 köpekte (%31.25) stabil hastalık belirlenmiştir. Sonuç olarak, lokal ileri meme tümürlü köpeklerde neoadjuvan kemoterapi için doksorubisin ve siklofosfamid kombinasyonunun toksisitesi ve etkinliği kabul edilebilir ve tedavide umut verici olduğu görülmüştür.

Anahtar sözcükler: Köpek, Lokal ileri meme tümörü, Neoadjuvan kemoterapi, Doksorubisin, Siklofosfamid



Correspondence



+90 224 2940873



deniznak@gmail.com

INTRODUCTION

Canine mammary tumors (CMTs) are the most common neoplasms in intact female dogs. Although the prevalence of these tumors decreases in regions where preventive ovariectomy is performed, it remains an important disease entity in veterinary medicine [1]. In female dogs, the probability of mammary tumors is 50%, and half of these tumors have the ability to metastasize [2,3]. Dogs with malignant tumors have been shown to be older than dogs with benign tumors. Malignant tumors were found to be significantly larger than benign tumors [4,5].

The incidence of mammary tumors increases with age and it is most common in dogs over the age of 10-12 years. For mammary tumors, age, hormonal exposure (neutered status/exogenous hormone use), breed and genetic susceptibility and body weight (particularly during puberty) are important risk factors. At the same time, these risk factors may affect posttreatment survival. The entire mamma is exposed to growth factors and sex hormones, rendering it susceptible to carcinogenesis. This was proven to be mainly triggered by progesterone affecting on mammary stem cells from the first estrus cycle on. Consequently, most dogs develop tumors in multiple glands [5].

The therapeutic intent and goals of a given chemotherapeutic regimen are important factors to be considered when a drug is selected or investigated. Neoadjuvant treatment is a treatment performed before surgical removal of the primary tumor to prevent the development of possible postoperative micrometastases and to reduce the size of the tumor to make it suitable for operation. Furthermore, complete regression of the tumor stage and lymph node metastasis was observed after preoperative neoadjuvant chemotherapy. Adjuvant treatment is treatment with chemotherapeutic drugs following surgical removal of the primary tumor [6,7].

Irrespective of the stage of the disease, in studies [1,2,5] conducted to date, the first approach to CMTs is almost always surgically followed by adjuvant chemotherapy with cytotoxic drugs. Adjuvant chemotherapy is recommended particularly in dogs with mammary tumors that are thought to be at risk of metastasis and recurrence. To date, the following chemotherapeutic applications have been conducted in the treatment of CMTs: doxorubicin, docetaxel, paclitaxel, mitoxantrone, gemcitabine, and carboplatin, or combinations of various drug groups such as doxorubicin + cyclophosphamide, 5-fluorouracil + doxorubicin + cyclophosphamide, 5-fluorouracil + cyclophosphamide, mitoxantrone + vincristine + cyclophosphamide, gemcitabine + carboplatin and mitoxantrone + carboplatin [8].

In human medicine, preoperative neoadjuvant chemotherapy is preferred in advanced stage breast tumors and

has been accepted as a standard treatment [7,9]. In studies on neoadjuvant chemotherapy in human breast tumors, the complete pathological response rate (pCR) was found to be 13-13.7% as a result of drug administration in the form of a combination of doxorubicin and cyclophosphamide [10,11]. However, despite the advantages mentioned above, there are no studies on the use of neoadjuvant chemotherapy in CMTs. To date, there has been limited study related to the combination of doxorubicin and cyclophosphamide in adjuvant chemotherapy on CMTs. Therefore, this study was aimed at investigating the efficacy and toxicity of a doxorubicin cyclophosphamide combination for neoadjuvant use in dogs with locally advanced mammary tumors.

MATERIAL and METHODS

Patients

This study included 16 intact female dogs with locally advanced mammary tumors ($T_{1-3} N_{0-1} M_0$). The dogs' ages ranged from 8 to 14 years. The breeds of the dogs included poodle (3), terrier (5), golden retriever (2), Siberian husky (1), German shepherd (2), Rottweiler (1) and Doberman pinscher (2). Of the 16 dogs included in this study, while 4 had one tumor in single mammary tissue, 12 had multiple tumors in different mammary tissues. Mammary tumors were in the inguinal and abdominal mammary lobes in 93.75% of the dogs, while it contained the thoracic lobes in 6.25% in this study. All dogs were fed commercial dog food. Dog's body weights ranged from 5 kg to 48 kg. No dog had a history of pseudopregnancy or hormonal contraception. The approval for conduction of the experiment was obtained from the ethics committee of the Bursa Uludag University (2018-01/03).

Pretreatment Evaluation

All dogs received a general examination, gynecological examination (vaginocopy, vaginal cytology), complete blood count (CBC) (VetScan HM5, Veterinary Hematology Analyzer, Abaxis, USA), serum biochemistry (VetScan® VS2, Chemistry Analyzer, Abaxis, USA), thoracic radiographs, and intra-abdominal ultrasonography (Mindray, DC-N2, China). If necessary, echocardiography was added to the examination to determine heart pathology. Using the ultrasound guide technique, a 14-gauge core needle biopsy was obtained from the mammary tumors of all dogs. Needle biopsies were taken from the local lymph nodes with a 21 gauge needle. All of the biopsies were then sent to the pathology laboratory. Based on the pathological examination, dogs with malignant mammary tumors were included in the study. All dogs with malignant mammary tumors were evaluated according to the TNM system [5]. The mammary tumors of these dogs were stage II-III-IV ($T_{1-3} N_{0-1} M_0$) and were identified as locally advanced mammary tumors.

Histopathological Evaluation

The tumor biopsy samples were fixed in 10% buffered formalin and embedded in paraffin. Sections 4 µm thick were obtained from each sample and stained with H&E (hematoxylin and eosin) for histologic examination and were classified according to the World Health Organization criteria for canine mammary lesions [12]. All samples were evaluated with respect to tubule and mammary alveoli formation, pleomorphism, nuclear polymorphism, mitosis index, necrosis, inflammatory infiltration, adjacent tissue invasion, and lymph node metastasis.

Treatment

A combination of 25-30 mg/m² doxorubicin (Adriamycin, Saba, Tekirdag, Turkey) (<15 kg, 25 mg/m²; >15 kg, 30 mg/m²) and 100 mg/m² cyclophosphamide was administered slowly intravenously every three weeks for four cycles. The premedication was given intravenously (I.V) 30 min before each chemotherapy treatment. This premedication included dexamethasone (Dexacure 2 mg/kg IV, Alivir, Ankara, Turkey) and metoclopramide (Metpamid 0.5 mg/kg IV, Zero, Istanbul, Turkey). All dogs were operated 4 weeks later after the last chemotherapy protocol. General anesthesia was performed with xylazine HCl (2 mg/kg) (Alfazyne 2%, Alfasan International BV, Woerden, The Netherlands) injected intramuscularly for premedication. Induction was provided by ketamine HCl (5-10 mg/kg, IV) (Alfamine 10%, Alfasan International BV, Woerden, The Netherlands). An endotracheal tube was inserted and isoflurane (Forane Likid, Abbott, Kent, UK) was delivered in 100% oxygen at 2 L/min as recommended. At the time of anesthetic induction, amoxicillin/clavulanic acid (8.75 mg/kg, IM) (Synulox, Pfizer, Istanbul, Turkey) was administered for prophylaxis and was continued postoperative period for five days. Carprofen (Rimadyl; Pfizer Inc., Zaventem, Belgium) was injected (4 mg/kg, SC) 5 days for postoperative analgesia. All dogs underwent mastectomy.

Evaluation of Response and Toxicity

At the beginning of treatment, tumor volume was measured under ultrasound guidance before each cycle and at 4 weeks after the last chemotherapy. The largest diameter of single tumors and the baseline sum of diameters of 2 and more tumors were evaluated. Complete response, partial response, stable disease, and progressive disease were used to evaluate clinical improvement. Response evaluation criteria are presented in Table 1 [13].

The side effects observed during treatment as toxicity were classified according to Veterinary Cooperative Oncology parameters v1.1 [14].

RESULTS

The general examination, CBC and serum biochemistry were within normal limits in all dogs. No pathology was found in thoracic radiographs or intra-abdominal ultrasonographic examinations.

Based on the histopathology results, mammary tumors were diagnosed as adenocarcinoma (n=13), tubulopapillary carcinoma (n=2) or malignant mixed tumors (n=1). Whereas 14 dogs had no indication of lymph node metastasis, in two dogs, mammary epithelial tumor cells were noticed in the lymph node via lymph node fine needle aspiration.

The mammary tumors of all dogs were at a locally advanced stage according to TNM classification. Based on the TNM classification, the tumors were grade 2 in 14 dogs and grade 4 in 2 dogs. The two dogs with mammary tumors that showed a complete response were grade 4. Characteristics of dogs and neoadjuvant chemotherapy response rates was summarized in Table 2.

The clinical images before and after 4 weeks of treatment for dog with a partial response are shown in Fig. 1 and Fig. 2.

The ultrasound images before and after 4 weeks of treatment for dog with a partial response are shown in Fig. 3 and Fig. 4.

Although no side effects were observed during treatment, clinical findings such as fever, vomiting, anorexia, lethargy, weight loss, alopecia, enteritis, hematuria, and skin ulceration and laboratory findings such as a decrease in neutropenia and hematocrit values were observed after treatment. All of the adverse effects changed between 1 to 2 grades. Three dogs that exhibited alopecia were of the terrier breed. All of the adverse effects were seen after the second neoadjuvant chemotherapy cycle. Five dogs that exhibited vomiting, enteritis, hematuria, and neutropenia were treated symptomatically. These adverse effects were not observed on the third and fourth neoadjuvant chemotherapy cycles. The adverse effects are presented in Table 3.

Table 1. Response evaluation criteria for solid tumors in dogs (v1.0)(13)

Characterization of Response	
Complete response	Disappearance of all target lesions
Partial response	At least 30% reduction in the sum of diameters of target lesions, taking as reference the baseline sum
Stable disease	Less than 30% reduction (PR) or 20% increase (PD) in the sum of diameters of target lesions
Progressive disease	Either the appearance of one or more new lesions or at least a 20% increase in the sum of diameters of target lesions

Table 2. Neoadjuvant chemotherapy response rates and characteristics of dogs with locally advanced mammary tumors

No	Age	Breed	Castrated	Cycle Stage	Tumor No.	Tumor Type	Histologic Tumor Grade		Lymph Node	Tumor Size	Clinical Response
							Before Treatment	After Treatment			
1	10	Poodle	Not Castrated	Anestrus	>1	Adenocarcinoma	I	-	Negative	<3 cm	C.R
2	9	German Shepherd	Not Castrated	Anestrus	1	Adenocarcinoma	I	-	Negative	<3 cm	C.R
3	12	Doberman Pinscher	Not Castrated	Anestrus	>1	Adenocarcinoma	I	I	Negative	3-5 cm	P.R
4	12	Terrier	Not Castrated	Anestrus	1	Schrious adenocarcinoma	III	II	Positive	3-5 cm	P.R
5	13	Terrier	Not Castrated	Anestrus	>1	Tubulopapillary carcinoma	I	I	Negative	3-5 cm	P.R
6	9	Golden Retriever	Not Castrated	Estrus	>1	Schrious adenocarcinoma	II	II	Positive	3-5 cm	P.R
7	10	Terrier	Not Castrated	Anestrus	>1	Adenocarcinoma	II	I	Negative	3-5 cm	P.R
8	9	Rotweiler	Not Castrated	Anestrus	>1	Adenocarcinoma	I	I	Negative	3-5 cm	P.R
9	9	German Shepherd	Not Castrated	Anestrus	>1	Adenocarcinoma	II	I	Negative	3-5 cm	P.R
10	10	Terrier	Not Castrated	Anestrus	>1	Adenocarcinoma	II	I	Negative	3-5 cm	P.R
11	10	Poodle	Not Castrated	Anestrus	>1	Adenocarcinoma	II	I	Negative	3-5 cm	P.R
12	9	German Shepherd	Not Castrated	Anestrus	>1	Adenocarcinoma	II	II	Negative	3-5 cm	S.D
13	7	Terrier	Not Castrated	Anestrus	>1	Tubulopapillary carcinoma	I	I	Negative	3-5 cm	S.D
14	10	Poodle	Not Castrated	Anestrus	>1	Adenocarcinoma	I	I	Negative	3-5 cm	S.D
15	9	German Shepherd	Not Castrated	Anestrus	1	Malignant mixed tumors	I	I	Negative	3-5 cm	S.D
16	9	Siberian Husky	Not Castrated	Anestrus	1	Adenocarcinoma	I	I	Negative	>5 cm	S.D

C.R.: Complete Response; P.R.: Partial Response; S.D.: Stable Disease

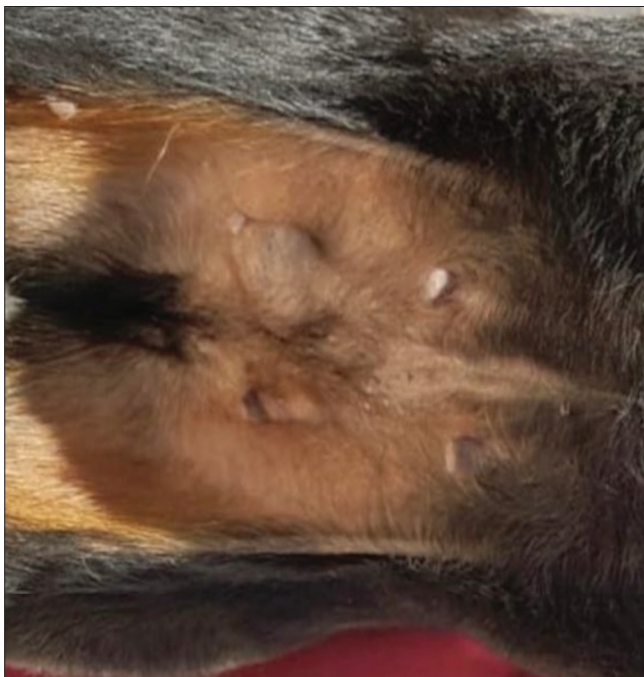


Fig 1. Clinical appearance of mammary tumor on right inguinal mammary gland before treatment

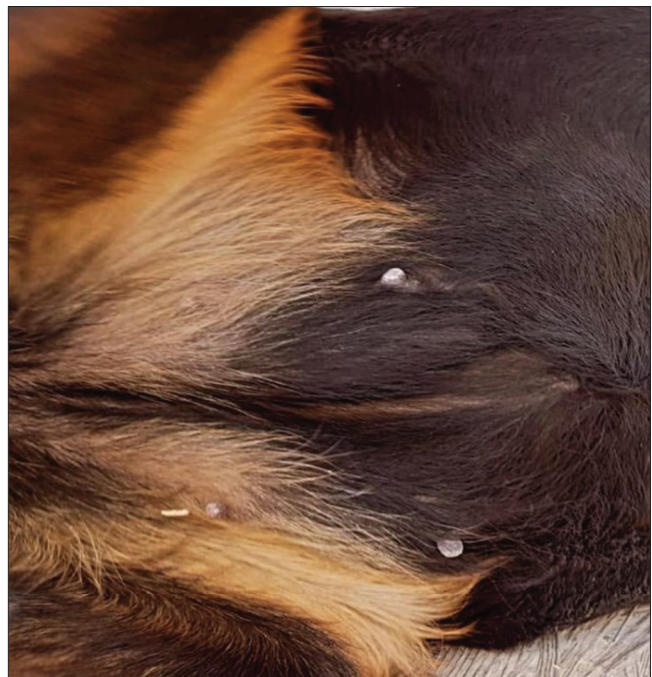

Fig 2. Clinical appearance of partial response in the tumor size after treatment

DISCUSSION

Treatment options for CMTs are limited compared with human breast cancers. However, treatment protocols for human breast tumors can be considered as treatment options for CMTs ^[1].

In adjuvant treatment, combination chemotherapy is used routinely due to widespread evidence that polychemotherapy offers a survival advantage compared with single-agent therapy. Multidrug regimens have generally resulted in higher overall complete response rates with improvement in response durations. When compared

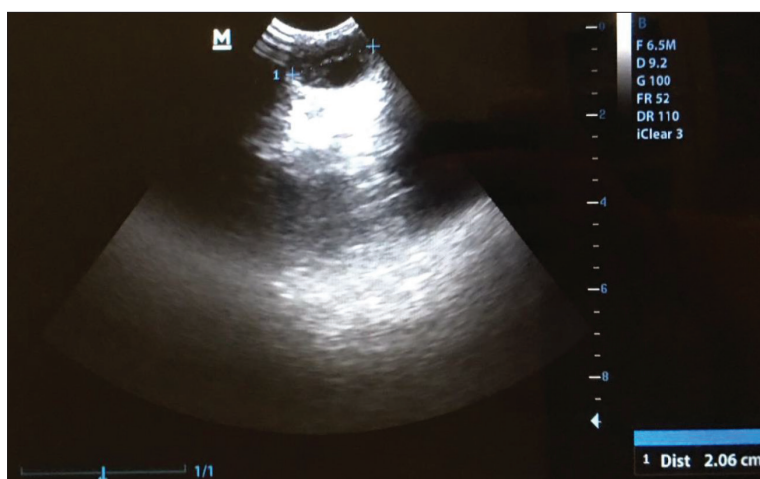


Fig 3. Ultrasound image of a dog before neoadjuvant chemotherapy that produced a partial response

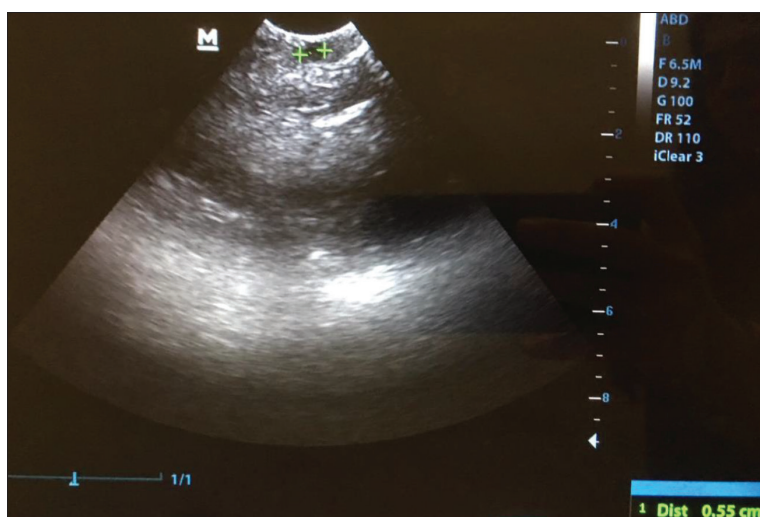

Fig 4. Ultrasound image of a dog after 4 weeks of neoadjuvant chemotherapy that produced a partial response

Table 3. Adverse effects observed after neoadjuvant chemotherapy in dogs with locally advanced mammary tumors

Adverse Effects	Number of Dogs	Stage
Clinical findings		
Fever	1/16	Grade 2
Vomiting	3/16	Grade 1
Anorexia	4/16	Grade 2
Lethargy	4/16	Grade 1
Weight loss	2/16	Grade 1
Alopecia	3/16	Grade 1
Enteritis	2/16	Grade 2
Haematuria	1/16	Grade 2
Skin ulceration	1/16	Grade 2
Laboratory findings		
Neutropenia	2/16	Grade 2 (1) Grade 1 (1)
Hematocrit value ⁻	2/16	Grade 1

with patients treated with non-anthracycline-containing regimens, patients treated with anthracycline-containing regimens had a statistically significant reduction in recurrence rates (12%) and mortality rates (11%) [15-17]. Anthracycline-containing regimens provided advantages in overall and recurrence-free survival rates over non-anthracycline-containing regimens. The most commonly used anthracycline-containing adjuvant chemotherapy regimen consists of four cycles of doxorubicin plus cyclophosphamide (AC) administered every 21 days [15,17]. Rastogi et al.^[10] conducted a study to determine whether four cycles of doxorubicin and cyclophosphamide (AC) administered preoperatively improved breast cancer disease-free survival (DFS) and overall survival (OS) compared with AC administered postoperatively in 751 patients. In the preoperative AC group, an objective clinical response occurred in 79% of the assessable patients with a clinical partial response (cPR) in 43% of patients and a clinical complete response rate (cCR) in 36% of patients. In another study, a cCR of 40.1% was found after four cycles of preoperative AC on women with operable breast cancer and a mean tumor size of 4.5 cm [11]. There have been two published studies in veterinary medicine that deal with a doxorubicin and cyclophosphamide combination used on CMTs. In one study, two dogs with inflammatory mammary carcinoma received 1 dose of doxorubicin (30 mg/m², IV) on day 1 (day of presentation) and 1 dose of cyclophosphamide (200 mg/m², PO) on day 4. Both had presented for re-evaluation on an emergency basis, one at 6 d and the other at 7 d after the initiation of chemotherapy, with

clinical signs including severe lethargy (n=2), pale mucous membranes (n=2), melena (n=2), hematemesis (n=1), abdominal hemorrhagic effusion (n=1), and inguinal hematomas (n=1). Additional diagnostic tests were not allowed by the owners and both dogs died on the day of representation. Both dogs were not already dead when re-evaluation was planned or performed [18]. The second study evaluated the effect and toxicity of doxorubicin and cyclophosphamide chemotherapy combined with operative treatment of malignant mammary tumors in 6 dogs. Ten days after the operation, doxorubicin was given intravenously at 20-30 mg/m² once weekly for 3 consecutive weeks and cyclophosphamide was given intravenously at 100 mg/m² 3 days after doxorubicin administration for 3 consecutive weeks. This study showed that doxorubicin and cyclophosphamide chemotherapy effectively suppressed the development of new neoplasms and metastases but was accompanied by general adverse reactions such as lethargy, anorexia, vomiting, hair loss, fever, hypochromic anemia, and strong immunosuppression [19]. The present

study found a complete response in 2/16 (12.5%), a partial response in 9/16 (56.25%), stable disease in 5/16 (31.25%), and progressive disease in 0/16 (0%) of cases after four cycles of neoadjuvant AC protocols on locally advanced CMTs. The mammary tumors size was <3 cm in the two dogs with a complete response. It has been determined that CMTs smaller than 3 cm can be treated with AC treatment and the treatment of small tumors is more successful. Compared with human studies, the complete response rate was lower than but the partial response rate was similar in our study. This difference may be due to species differences and dose differences. The clinical tumor stage is the most important indicator of the pathological complete response rate after neoadjuvant chemotherapy in breast cancer patients. Low clinical tumor stages have significantly higher pCR rates than high tumor stages [20]. In our study, the lymph nodes of the dogs that responded fully were negative (No.1-2 dogs). Liu et al. [21] determined that there a significant relationship between high tumor grade (grade III) and overall response rate. The present study detected that the overall response dogs had grade I-III (unlike the above -mentioned literature). In a study [18] using the high-dose AC protocol, the dogs died, and in another study [19] there were serious side effects. This study documented grade I-II manageable toxicity. The dose used in this study was evaluated as successful both in terms of clinical response and manageable toxicity.

This study presents the first data on response rates and neoadjuvant use of the AC protocol on CMTs. The neoadjuvant AC protocol leads to an improved clinical outcome in canine locally advanced mammary tumors. The AC treatment was well tolerated.

CONFLICT OF INTEREST

The authors declare that there are no conflicts of interest.

AUTHOR CONTRIBUTIONS

D. NAK, E. KURUOGLU and Y. NAK, planned and designed the research. Z. M. EKICI, D. KOCA, T. AVCILAR, M. E. SAHIN and A. H. SHAHZAD provided help in the clinic process. M. O. OZYIGIT and Z. AVCI KUPELI made histopathological examinations. All authors discussed the results and contributed to the final manuscript..

REFERENCES

- Sleekx N, Rooster HD, Veldhuis Kroeze EJB, Ginneken CV, Brantegem LV:** Canine mammary tumours, an overview. *Reprod Domest Anim*, 46, 1112-1131, 2011. DOI: 10.1111/j.1439-0531.2011.01816.x
- Von Euler H:** Tumors of the mammary glands. In: Dobson JM, Lascelles BDX (Eds): BSAVA Manual of Canine and Feline Oncology. 3rd ed., 237-247, Gloucester, UK: BSAVA, 2011. DOI: 10.22233/9781905319749.16
- Kivrak MB, Aydin I:** Treatment and prognosis of mammary tumors in bitches. *Inter J Vet Sci*, 6 (4): 178-186, 2017.
- Sorenmo KU, Kristiansen VM, Cofone MA, Shofer FS, Breen AM, Langeland M, Mongil CM, Grondahl AM, Teige J, Goldschmidt MH:** Canine mammary gland tumours: A histological continuum from benign to malignant: Clinical and histopathological evidence. *Vet Comp Oncol*, 7, 162-172, 2009. DOI: 10.1111/j.1476-5829.2009.00184.x
- Goldschmidt MH, Pena L, Zappuli V:** Tumors of Mammary Gland. In: Meuten DJ (Ed): Tumors in Domestic Animals. 5th ed., 723-725, Wiley Blackwell, USA, 2017. DOI: 10.1002/9781119181200
- Gustafson DL, Page RL:** Cancer chemotherapy. In: Withrow SJ, Vail DM, Page RL (Eds): Withrow & MacEwen's Small Animal Clinical Oncology. 5th ed., 157-179, Saint Louis, USA, Elsevier Saunders, 2013.
- Biller B, Berg J, Garrett L, Ruslander D, Wearing R, Abbott B, Patel M, Smith D, Bryan C:** 2016 AAHA oncology guidelines for dogs and cats. *J Am Anim Hosp Assoc*, 52 (4): 181-204, 2016. DOI: 10.5326/JAAHA-MS-6570
- Karayannopoulo M, Lafioniatis S:** Recent advances on canine mammary cancer chemotherapy: A review of studies from 2000 to date. *Rev Méd Vét*, 167 (7-8): 192-200, 2016.
- Specht J, Gralow JR:** Neoadjuvant chemotherapy for locally advanced breast cancer. *Semin Radiat Oncol*, 19 (4): 222-228, 2009. DOI: 10.1016/j.semradonc.2009.05.001
- Rastogi P, Anderson SJ, Bear HD, Geyer CE, Kahlenberg MS, Margolese RG, Hoehn JL, Vogel VG, Dakhil SR, Tamkus D, King KM, Pajon ER, Wright MJ, Robert J, Paik S, Mamounas EP, Wolmark N:** Preoperative chemotherapy: Updates of National Surgical Adjuvant Breast and Bowel Project Protocols B-18 and B-27. *J Clin Oncol*, 26 (5): 778-785, 2008. DOI: 10.1200/JCO.2007.15.0235
- Bear HD, Anderson S, Brown A, Smith R, Mamounas EP, Fisher B, Margolese R, Theoret H, Soran A, Wickerham DL, Wolmark N:** The effect on tumor response of adding sequential preoperative docetaxel to preoperative doxorubicin and cyclophosphamide: Preliminary results from National Surgical Adjuvant Breast and Bowel Project Protocol B-27. *J Clin Oncol*, 21 (22): 4165-4174, 2003. DOI: 10.1200/JCO.2003.12.005
- Goldschmidt M, Pena L, Rasotto R, Zappuli V:** Classification and grading of canine mammary tumors. *Vet Pathol*, 48 (1): 117-131, 2011. DOI: 10.1177/0300985810393258
- Nguyen SM, Thamm DH, Vail DM, London CA:** Response evaluation criteria for solid tumours in dogs (v1.0): A Veterinary Cooperative Oncology Group (VCOG) consensus document. *Vet Comp Oncol*, 13 (3): 176-183, 2015. DOI: 10.1111/vco.12032
- Veterinary Co-operative Oncology Group:** Common Terminology Criteria for Adverse Events (VCOG-CTCAE) following chemotherapy or biological antineoplastic therapy in dogs and cats v1.1. *Vet Comp Oncol*, 14 (4): 417-446, 2016. DOI: 10.1111/vco.283
- Miles D, Von Minckwitz G, Seidman AD:** Combination versus sequential single-agent therapy in metastatic breast cancer. *Oncologist*, 7 (Suppl.-6): 13-19, 2002. DOI: 10.1634/theoncologist.2002-0013
- Perez EA:** Paclitaxel in breast cancer. *Oncologist*, 3, 373-389, 1998.
- Mamounas EP, Bryant J, Lembersky B, Fehrenbacher L, Sedlacek SM, Fisher B, Wickerham DL, Yothers G, Soran A, Wolmark N:** Paclitaxel after doxorubicin plus cyclophosphamide as adjuvant chemotherapy for node- positive breast cancer: Result from NSABP B-28. *J Clin Oncol*, 23 (16): 3686-3696, 2005. DOI: 10.1200/JCO.2005.10.517
- De M Souza CH, Toledo-Piza E, Amorin R, Barboza A, Tobias KM:** Inflammatory mammary carcinoma in 12 dogs: Clinical features, cyclooxygenase-2 expression, and response to piroxicam treatment. *Can Vet J*, 50, 506-510, 2009.
- Todorova I, Simeonova G, Simeonov R, Dinev D:** Efficacy and toxicity of doxorubicin and cyclophosphamide chemotherapy in dogs with spontaneous mammary tumours. *Trakia J Sci*, 3 (5): 51-58, 2005.
- Goorts B, Van Nijnatten TJA, De Munck L, Moosdorff M, Heuts EM, De Boer M, Lobbes MBI, Smidt ML:** Clinical tumor stage is the most important predictor of pathological complete response rate after neoadjuvant chemotherapy in breast cancer patients. *Breast Cancer Res Treat*, 163, 83-91, 2017.
- Lin Q, Liu Y, Chen H, Liu Y, Tang Q, Liu J, Chen H:** Survivin, Ki-67 and tumor grade as predictors of response to docetaxel-based neoadjuvant chemotherapy in locally advanced breast cancer. *Mol Clin Oncol*, 1 (5): 839-844, 2013. DOI: 10.3892/mco.2013.138