

Effect of Pimobendan in The Treatment of Pulmonary Hypertension in a Cat with Giant Right Atrium

(Dev Sağ Atriyumlu Bir Kedide Pimobendan'ın Pulmoner Hipertansiyon Tedavisindeki Etkinliği)

Pınar LEVENT ^{1,a} Ahmet SARIL ^{1,b} Meriç KOCATÜRK ^{1,c} Ryou TANAKA ^{2,d} Zeki YILMAZ ^{1,e}

¹ Department of Internal Medicine, Faculty of Veterinary Medicine, Bursa Uludag University, TR-16059 Bursa - TURKEY

² Veterinary Surgery, Department of Veterinary Medicine, Faculty of Agriculture, Tokyo University of Agriculture and Technology, Tokyo, 183-8509, JAPAN

ORCID: ^a 0000-0001-9757-6716; ^b 0000-0003-1094-880X; ^c 0000-0002-2849-1222; ^d 0000-0001-9948-6490; ^e 0000-0001-9836-0749

Article Code: KVFD-2020-24524 Published Online: 23.06.2020

How to Cite This Article

Levent P, Saril A, Kocatürk M, Tanaka R, Yılmaz Z: Effect of pimobendan in the treatment of pulmonary hypertension in a cat with giant right atrium. *Kafkas Univ Vet Fak Derg*, 26 (5): 717-718, 2020. DOI: 10.9775/kvfd.2020.24524

Dear Editor,

Pulmonary hypertension (PH) is one of the most common health problem in human medicine, therefore many patients need anti-hypertensive medication to improve clinical signs and increase life quality and expectancy. In veterinary medicine, PH is associated with heartworm disease, pulmonary thromboembolism, chronic obstructive pulmonary disease, left-sided heart failure and large congenital cardiac shunts in dogs, but is rarely reported in cats ^[1-4]. Therefore, by this case presentation, we would like to share diagnostic algorithm and therapeutic approach of PH with veterinary academicians and practitioners to develop their skills on challenging disorders of feline cardiology.

The patient (Chinchilla, 3 years old, female, 4 kg) was referred from a private clinic to Veterinary Teaching Hospital with a history of lethargy, abdominal distention, exercise intolerance and abdominal breathing for a month. Patient with ascites and pleural effusion was already treated with furosemide and corticosteroid for 15 days. At admission, physical examination revealed 2/6-grade murmur from left and 4/6-grade at tricuspid valve puncta maxima. While heart (240 bpm) and respiratory rates (44 breath/min) increased, other clinical parameters were within normal range. Distended jugular vein was remarkable. Thoracic radiography revealed enlarged (right-sided) heart silhouette (VHS: 10.5), pulmonary artery (PA) bulging, dorsal deviation of trachea and caudal vena cava, decreased cardio-thoracic ratio in right side, and increased alveolar

pattern. Pleural effusion and alveolar edema were minimal due to ongoing furosemide administration till admission. ECG examination showed sinus tachycardia. Complete blood cell count (Fuji VH5R) and serum biochemistry (Comprehensive Panel, Fuji Dri-Chem NX500I) were non-specific.

Transthoracic echocardiography was performed using standard imaging techniques with a 7.5-10 mHz phase array cardiac transducer (Caris-Plus Esoate) ^[1,3]. Two-dimensional right parasternal long and short-axis view revealed right atrial (RA) dilatation (2.8 cm) (*Fig.1-a*), RA bulging into left atrium (LA), flattening of the interventricular septum (IVS) and right ventricular free wall (0.7 cm, ref.; 0.24±0.04 cm) and IVS thickness (0.94 cm, ref.; 0.5-0.9 cm) at diastole, suggestive for a giant RA and volume overload most probably due to PH and/pulmonary stenosis in this case. Since interatrial and IVS were intact and thicknesses and settlements of mitral and tricuspidal valves were normal, congenital defects that cause to RA dilation such as atrial and ventricular septal defects, Gerbode defect, endocardial cushion defect, and Ebstein's anomaly were excluded from the differential diagnosis list ^[1]. Geometric (LA:Ao ratio and left ventricle diameter and free wall thickness) and functional measurements such as fractional shortening were within reference limits, indicating that left-sided congestive heart failure was not a possible reason for increased volume overload in RA ^[2].

The main PA and its branches were dilated (*Fig.1-b*). PA color flow Doppler showed the laminar flow as it should



Correspondence



+90 224 2940817

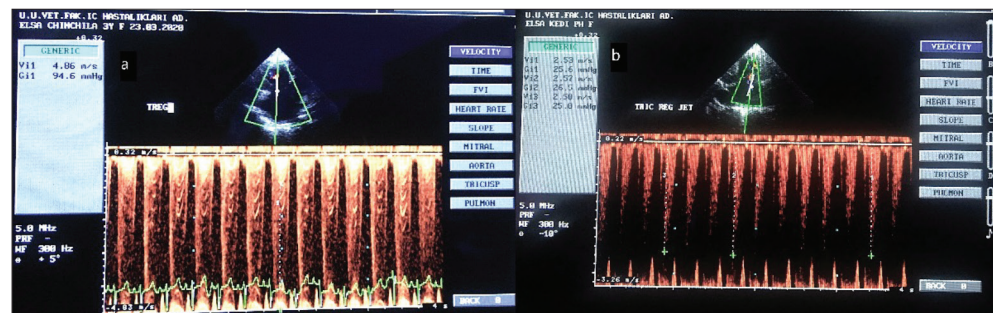


merick@uludag.edu.tr

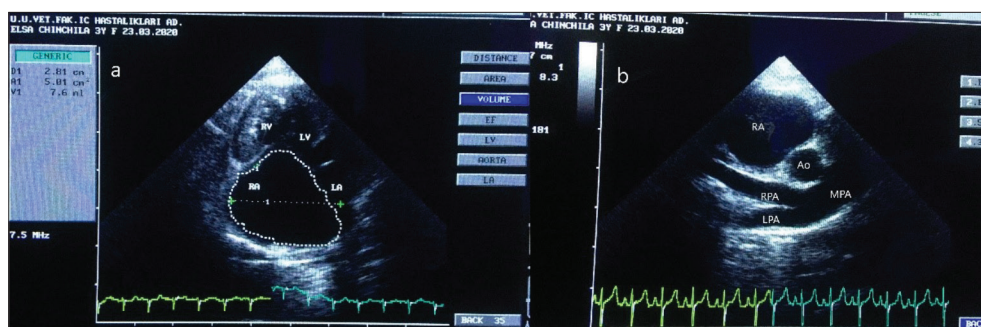

Fig 1. a) Enlarged right atrium (RA) in apical view (2.81 cm; 5.01 cm²; 7.6 mL); **b)** Dilated main pulmonary artery (MPA; 2.0 cm) and right (RPA) and left branches (LPA) and dilated RA in right parasternal short axis-Aort (Ao; 1.0 cm) level

Fig 2. a) Pulse wave Doppler echocardiographic measurement of the tricuspid regurgitant jet velocity and pressure gradient before (4.86 m/s and 94.6 mmHg) and **b)** after pimobendan treatment (2.53 m/s and 25.6 mmHg, respectively)



be, and its flow velocity and pressure gradient (PG) were within normal limits (0.9 m/s and 3.2 mmHg, respectively). Severe tricuspid regurgitation (TR) was observed without valvular pathology on apical 4-chamber view. Maximal TR jet velocity was 4.86 m/s and PG between right ventricle and RA was 94.6 mmHg (Fig. 2-a) according to Bernoulli equation [1,4]. That dogs with TR jet velocity >3.4 m/s have at least two echocardiographic signs of PH such as IVS flattening and RA and PA dilation (PA/Ao ratio: 2.0) increases the probability of PH [4]. PA systolic pressure (PASP) was 109.6 mmHg estimated by accepted formula ($PASP = 4v^2 + RA \text{ pressure}$) in compatible with severe idiopathic PH (type-I) in this case [2,3]. RA pressure was accepted as 15 mmHg for this case because RA diameter (2.8 cm) was greater than LA (0.9 cm) [1]. Other possible reasons for PH which is left-sided heart failure (Type-II), respiratory diseases (Type-III), pulmonary embolism (Type-IV), parasitic diseases (Type-V), and multifactorial (Type-VI) were not possible for our case based on comprehensive diagnostic approaches [4].

The patient had supportive treatment for RA volume overload and PH with ramipril and hydrochlorothiazide combination (0.5 mg/kg, q24h, PO), furosemide (1 mg/kg, q24h, PO), Aspirin (10 mg/kg, q72h, PO) and dietary salt restriction [1,2]. Two weeks later, although clinical findings were improved slightly, the severity of TR jet velocity and PASP remained unchanged. Among treatment choices of PH, although sildenafil is the first option, there are some disadvantages due to its short half-life, difficulty of oral dosage in cats, and an expensive option for patient owners [4]. Instead, pimobendan, a particularly preferred

drug in dogs, is a phosphodiesterase III inhibitor with calcium sensitizing effects thereby exerting positive inotropy and vasodilation. Pimobendan led to a short-term improvement in clinical signs and decreased TR in dogs [4], but there is not more information about this subject in feline practice. Considering the beneficial effects of pimobendan in dogs with PH [4], it was added to the standard treatment (0.25 mg/kg, q12h, PO). Three weeks after onset of pimobendan, TR jet was found to be lower (2.5 m/s) than previous one (4.8 m/s) (Fig. 2-a,b), resulting in the full clinical improvement.

In conclusion, this presentation suggests that cases with isolated giant RA should be examined whether PH is present or not by transthoracic echocardiography. PASP could be estimated non-invasively by Doppler echocardiography in cats. Pimobendan therapy may have long-term clinical benefits which brings future possibilities of PH treatment which has not sufficient literature in feline medicine.

REFERENCES

1. Smith FWK, Oyama MA, Tilley LP, Sleeper MM: Manuel of Canine and Feline Cardiology. 5th ed., Elsevier, 2016.
2. Vezzosi T, Schober KE: Doppler-derived echocardiographic evidence of pulmonary hypertension in cats with left-sided congestive heart failure. *J Vet Cardiol*, 23, 58-68, 2019. DOI: 10.1016/j.jvc.2019.01.007
3. Yilmaz Z, Kocaturk M, Levent P, Saril A, Salci H, Sag S: Utility of transesophageal echocardiography in the diagnosis of tetralogy of Fallot in a dog. *Kafkas Univ Vet Fak Derg*, 24 (6): 913-914, 2018. DOI: 10.9775/kvfd.2018.20756
4. Reinero C, Visser LC, Kellihan HB, Kellihan HB, Masseau I, Rozanski E, Clercx C, Williams K, Abbott J, Borgarelli M, Scansen BA: ACVIM consensus statement guidelines for the diagnosis, classification, treatment, and monitoring of pulmonary hypertension in dogs. *J Vet Intern Med*, 34 (2): 549-573, 2020. DOI: 10.1111/jvim.15725