

## The Effects of Calcium Aluminate and Calcium Silicate Cements Implantation on Haematological Profile in Rats

Muhamed KATICA <sup>1,a</sup> Ognjenka JANKOVIĆ <sup>2,b</sup> Faruk TANDIR <sup>3,c</sup> Nedžad GRADAŠČEVIĆ <sup>4,d</sup>  
Radoslav DEKIĆ <sup>5,e</sup> Maja MANOJLOVIĆ <sup>6,e</sup> Smiljana PARAŠ <sup>7,g</sup> Ljiljana TADIĆ- LATINOVIĆ <sup>8,9,h</sup>

<sup>1</sup> Department of Pathological Physiology of Domestic Animals, Veterinary Faculty, University of Sarajevo, Bosnia and Herzegovina; <sup>2</sup> Department of Restorative Dentistry and Endodontics, Faculty of Medicine, University of Banja Luka, Bosnia and Herzegovina; <sup>3</sup> Department of Anatomy and Embryology, Veterinary Faculty, University of Sarajevo, Bosnia and Herzegovina; <sup>4</sup> Department of Radiobiology with Radiation Hygiene, Biophysics & Environmental Protection, Veterinary Faculty, University of Sarajevo, Bosnia and Herzegovina; <sup>5</sup> Department of Zoology, Genetics and Evolution, Faculty of Natural Sciences and Mathematics, University of Banja Luka, Bosnia and Herzegovina; <sup>6</sup> Department of Ecology and Environmental Protection, Faculty of Natural Sciences and Mathematics, University of Banja Luka, Bosnia and Herzegovina; <sup>7</sup> Department of Zoology, Faculty of Science and Mathematics, University of Banja Luka, Bosnia and Herzegovina; <sup>8</sup> Institute of Pathology, Clinical Center, Banjaluka, University of Banja Luka, Bosnia and Herzegovina; <sup>9</sup> Department of Pathology, Faculty of Medicine, University of Banja Luka, Bosnia and Herzegovina  
<sup>a</sup> ORCID: 0000-0001-8184-0065; <sup>b</sup> ORCID: 0000-0002-9642-9674; <sup>c</sup> ORCID: 0000-0001-9184-592X; <sup>d</sup> ORCID: 0000-0003-4759-3192  
<sup>e</sup> ORCID: 0000-0001-5209-8431; <sup>f</sup> ORCID: 0000-0003-4587-2913; <sup>g</sup> ORCID: 0000-0001-8617-3583; <sup>h</sup> ORCID: 0000-0003-1424-819X

Article ID: KVFD-2019-23476 Received: 14.10.2019 Accepted: 27.02.2020 Published Online: 02.03.2020

### How to Cite This Article

Katica M, Janković O, Tandir F, Gradašević N, Dekić R, Manojlović M, Paraš S, Tadić- Latinović L: The effects of calcium aluminate and calcium silicate cements implantation on haematological profile in rats. *Kafkas Univ Vet Fak Derg*, 26 (3): 427-434, 2020. DOI: 10.9775/kvfd.2019.23476

### Abstract

The objective of this study was to evaluate potential unfavourable side effects, especially on the blood corpuscles, of experimental calcium aluminate and calcium silicate cements that are applied subdermally or directly to tooth pulp. In the study, fifty-four Wistar rats were separated into two study groups (n=27 in each group). The effects of the dental cements on haematological parameters were observed three times (after 7, 15 and 30 days): erythrocytes, haemoglobin, haematocrit, mean corpuscular volume, mean corpuscular haemoglobin, mean corpuscular haemoglobin concentration, leukocytes, leucogram and poikilocytic erythrocyte forms. There were no statistically significant differences in the total number of leukocytes and percentage results of lymphocytes, and neutrophils. The study recorded lower numbers of erythrocytes, with no connection with the type of material applied to the dental pulp (First study group). Significant differences in results for the second study group were recorded on days 7-15 and 15-30 of the experiment in relation to both types of implanted cements. In the second study group there were significant differences related to both types of implanted cements, in the same periods. Lower values of erythrocytes, haemoglobin and haematocrit indicated the existence of hypochromic anaemia caused by the damaging influence of calcium aluminate and calcium silicate. Research showed that in both study groups, normocytic hypochromic anaemia existed, along with modest to expressed distribution of anulocytes and stomatocytes. According to the results of the research, the negative impact of application of Ca-silicate was recorded and was related to the appearance of hypochromic anaemia with poikilocytic forms of erythrocytes.

**Keywords:** Calcium aluminate, Calcium silicate, Rat, Haematological parameters, Poikilocytic erythrocytes forms

## Kalsiyum Alüminat ve Kalsiyum Silikat Sement İmplantasyonunun Ratlarda Hematolojik Profil Üzerine Etkileri

### Öz

Bu çalışmanın amacı, deneysel olarak subdermal veya direkt olarak diş pulpasına uygulanan kalsiyum alüminat ve kalsiyum silikat sementlerin, özellikle kan kürecikleri üzerindeki potansiyel olumsuz yan etkilerini değerlendirmektir. Çalışmada, elli dört Wistar rat iki çalışma grubuna ayrıldı (her grupta n = 27). Dental sementlerin hematolojik parametreler üzerindeki etkileri eritrositler, hemoglobin, hematokrit, ortalama korpüsküler volüm, ortalama korpüsküler haemoglobin, ortalama korpüsküler hemoglobin konsantrasyonu, lökositler, lökogram ve poikilositik eritrosit formlarını içerecek şekilde üç kez (7, 15 ve 30 gün sonra) gözlemlendi. Total lökosit sayısı ile lenfosit ve nötrofillerin yüzde değerlerinde istatistiksel olarak anlamlı bir fark yoktu. Çalışma, eritrosit sayısında diş pulpalarına uygulanan materyal tipiyle hiçbir bağlantısı olmayan bir azalmayı ortaya koydu (Birinci çalışma grubu). İkinci çalışma grubu için elde edilen sonuçlarda, 7-15 ve 15-30. günlerde her iki sement implant tipiyle ilişkili olan anlamlı farklılıklar saptandı. İkinci çalışma grubunun aynı periyotlarında her iki sement implant türü ile ilgili önemli farklılıklar vardı. Düşük eritrosit, hemoglobin ve hematokrit değerleri, kalsiyum alüminat ve kalsiyum silikatın zararlı etkisinden kaynaklanan hipokromik aneminin varlığını gösterdi. Bu araştırma ile her iki çalışma grubunda da anüositlerin ve stomatitlerin orta dereceli ekspresyonunu gösteren normositik hipokromik anemi varlığı belirlendi. Araştırma sonuçlarına göre, Ca-silikat uygulamasının olumsuz etkisi saptandı ve bu durum eritrositlerin poikilositik formları ile birlikte görülen hipokromik anemi ile ilişkiliydi.

**Anahtar sözcükler:** Kalsiyum alüminat, Kalsiyum silikat, Sıçan, Hematolojik parametreler, Poikilositik eritrosit formları



### İletişim (Correspondence)



+387 33 729 155 Fax: +387 33 617 850



muhamed.katica@vfs.unsa.ba

## INTRODUCTION

Biomaterials are defined as materials designed to successfully replace the corresponding biological function in close contact with living tissue, after they have been implemented in the body of an animal or human. The biocompatibility of some biomaterials is evident. They show excellent characteristics for application in the field of surgery [1,2]. In contact with biomaterial, tissue should not exhibit cytotoxic, genotoxic, mutagenic or allergic reactions [3-5]. If changes occur on the surrounding tissue, they are in the form of inflammation, necrosis, infiltration, encapsulation or some other reaction by the tissue [6].

Some implanted biomaterials have a partially adverse impact on leukocytes in peripheral blood, in the form of the occurrence of toxic granules in the cytoplasm [7]. Many researchers have studied the biocompatibility of calcium silicate cements and, in the last decade, calcium aluminate cements [5,6,8,9]. There is a growing interest in nanomaterials since, among other things, they have the possibility to overcome the problems associated with solubility and stability, and to enable medicine to be released into the desired tissue [10].

Using nanotechnology, in combination with the hydrothermal sol-gel method and self-inflicting waves method, two new experimental biomaterials based on calcium aluminate and calcium silicate were synthesized. Expectations are that these biomaterials will overcome the existing disadvantages of popular calcium silicate cements such as MTA: long bonding time, and the granular consistency of the fused material.

In dental research, the most used animal for laboratory tests is rat [11-13]. A literature review revealed many studies where rats were used to follow the effects of different substances on specific tissues [12,14]. In contrast, not so many authors, in their evaluation of the toxicity or biocompatibility of implanted materials, have investigated their influence on haematological parameters [15,16].

It is evident that monitoring and analysis of haematological parameters is one in the series of important segments of every clinical examination of a sick animal. Haematological analysis contributes to determining potential disease risk, or exclusion of possible diseases, following the disease's progress and path, as well as therapy success and outcome of treatment [11,13]. On the other hand, using haematological parameters as a tool for evaluation of biomaterial toxicity would create the possibility of quick and efficient selection of appropriate implantation material.

The objective of this study was to evaluate the potential influence on blood corpuscles of experimental calcium aluminate and calcium silicate cements, applied subdermally or by direct coverage of the tooth pulp of rats. In order to attain the most accurate results, a number of

haematological parameters were analysed. New experimental biomaterials were used to establish their purposefulness for veterinary dentistry and medicine, as well as their unfavourable side effects on haematological profile.

## MATERIAL and METHODS

### *Ethics Committee Approval*

This study was approved by the Ethics Committee of the University Clinical Center in Banja Luka under registration number 01-9-192.2/15, Bosnia and Herzegovina.

### *Testing Materials*

The materials used for testing are calcium aluminate systems: a  $\text{CaO}\cdot\text{Al}_2\text{O}_3 + \text{CaCO}_3 + \text{Bi}_2\text{O}_3$ , mixture called ALBO-MCCA obtained by mixing  $\text{CaCO}_3$  and  $\text{Bi}_2\text{O}_3$ , and  $\text{BaSO}_4$  with calcium aluminate phase with a ratio of 2:2:1. Finally, water was added to the mixture in a 1:2 ratio, to create cement paste. The second material used was calcium silicate (CS): 60% of the total quantity was  $\beta$ -C2S and C3S phase, with added components: 20% calcium carbonate ( $\text{CaCO}_3$ ) and 20%  $\text{BaSO}_4$  (Merck, Germany) [5,6,17].

### *Animals*

A total of 54 rats, Wistar breed, aged 10-11 weeks, average weight 265-280 g, were used in this study. The rats had free access to food and water, and a 12-h light and darkness schedule. The air temperature was between 20 and 23°C, with 60%±10% air humidity.

### *General Experimental Procedure and Study Groups*

The tested animals (n=54) were separated into two study groups. The first study group consisted of 27 rats subjected to covering the dental pulp with dental cements: Ca-aluminate and Ca-silicate.

Within the first study group, and in its subgroup (A), nine rats had Ca-aluminate administered onto the dental pulp, whereby the pulp was covered directly.

In the subgroup (B), the nine rats had Ca-silicate administered onto the dental pulp whereby the pulp was covered directly.

The remaining 9 rats from the first experimental group represented the control group (A-B).

The other study group of rats also consisted of 27 rats that underwent implantation of sterile polyethylene tubes subdermally on each side of the spine. Polyethylene tubes were used with two types of different fillings: Ca-aluminate and Ca-silicate.

Within the second study group, in its subgroup (C), a sterile polyethylene tube was implanted subdermally on each side of the spine in nine rats, filled with Ca-aluminate.

In subgroup (F), a sterile polyethylene tube containing Ca-silicate was implanted subdermally on each side of the spine in nine rats.

The remaining 9 rats from the second experimental group represented the control group (C-F).

### **Surgical Procedures**

Before the surgical procedure of subdermal implementation of polyethylene tubes, general anaesthesia was performed using intra muscular ketamine, 90 mg/kg of body weight (Ketamine HCl Injection USP) Rotexmedica-Germany, in combination with Xylazin HCl 5 mg/kg of body weight (2% Xylazin, Cp Pharma, Bergdorf, Germany). The duration of anaesthesia was around one hour. Places where application was planned were prepared by removing animal hair and cleaning the area with antiseptic (10% betadine). The polyethylene tubes were inserted into the animals in subgroups C and F as described above.

During the dental procedure, sterile instruments were used including the plates where the material was prepared. The location of application was relatively dry due to the use of absorbent cotton and a saliva pump. Cavities in the first upper molar on the left and right sides of each experimental animal from subgroups A and B were prepared. Trepanation of the pulp cavum top and placement of the cement directly on the pulp was performed. Before application of the cement, the procedure of total anaesthesia was used identical to study subgroups C and F. Cavities were later restored using composite (Tetric Ceram, Ivoclar Vivadent, Schaan Lichtenstein).

### **Postoperative Treatment**

After surgical treatment, the animals were placed separately in cages, with one animal per cage in a strictly controlled environment, with a controlled diet and daily care. Rats from control group A-B were able to consume mashed feed mixture ad libitum, which regarding nutritive values completely responded to the feed consumed by the rats in experimental subgroups A and B. Rats in control groups A-B and C-F were from the same vivarium, hatch, breed and age as the rats in the study groups.

### **Hematological Procedure**

In all rats, the vena coccigea was punctuated at three time periods: 7, 15 and 30 days after surgical procedures. During punctuation, the principles of asepsis and antisepsis were regarded. Punctuated blood was deposited in hematological vacutainers with EDTA anticoagulants.

To estimate the haematological parameters of the peripheral blood, a haematological analyzer "Celltac MEK-6450" was used. The parameters that were analysed included: HGB (g/dL), HCT (%), MCV (fl), MCH (pg) i MCHC (g/dL), number of RBC ( $10^{12}/L$ ) PLT ( $10^9/L$ ) and WBC ( $10^9/L$ ).

### **Microscopic Examination of Peripheral Blood**

Blood smears were processed using standard technical laboratory procedures<sup>[18]</sup>. On every original coloured smear, 2000 RBC were counted and analysed using a binocular light microscope, Motic Type 102M, 1000x magnification. Poikilocytes were defined according to the standard methodology. Counting was limited to representative one-layer fields in which around half of the erythrocytes were in contact, without overlapping<sup>[18-21]</sup>. Most representative fields were electronically recorded using Motic Images Plus 2.0 software.

The number and type of poikilocytes was recorded as percentages of RBC. Poikilocytosis was classified semi-quantitatively according to similar research, following the criteria: non-existing (0%), rare (0.05-0.5%), mild (>0.5-3%), modest (>3-10%), or expressed (>10%)<sup>[18]</sup>.

Leukocytes cells were differentiated and numbers were presented in percentages after the analysis of 2000 of them in each animal in the experiment.

### **Statistical Data Analysis**

The mean and standard deviation of the data were determined, after which statistical analysis was performed using Minitab 19<sup>®</sup>[22]. ANOVA Two-way and post hoc Tukey test were used to detect whether there were significant differences between the groups and treatments.

## **RESULTS**

Lower values of RBC in the two observed groups (7<sup>th</sup> and 30<sup>th</sup> day) were recorded after covering of the pulp by calcium aluminate and calcium silicate compared with their controls (*Table 1*). Recorded values were below the physiological limits for rats<sup>[23]</sup>. No statistically significant differences between the average values of the experimental and control groups were recorded. The Post Hoc Tukey test showed the significant differences in RBC between the average values on the 7<sup>th</sup> and 15<sup>th</sup> days ( $P < 0.05$ ) and the 15<sup>th</sup> and 30<sup>th</sup> days ( $P < 0.05$ ), after subcutaneous implantation of calcium aluminate and calcium silicate. Also regarding HGB, the ANOVA results showed that there was a statistically significant difference related to the variable Day. However, that difference did not show after performing the Post Hoc Tukey test (*Table 2*).

After performing Post Hoc Tukey test we can see that there is significant difference between the means of control and subgroup A and control and subgroup B in the results for MCHC (*Table 1*). The Post Hoc Tukey test showed a significant difference in MCHC between the means of the control and subgroup C, and the control and subgroup F (*Table 2*).

The Post Hoc Tukey test showed a significant difference in HCT between the means of the 7<sup>th</sup> and 15<sup>th</sup> days ( $P < 0.05$ ) and the 15<sup>th</sup> and 30<sup>th</sup> days ( $P < 0.05$ ) (*Table 2*).

**Table 1.** First study group: mean and standard deviation of haematological parameters after direct coverage of pulp with calcium aluminate (A) and calcium silicate (B)

Subgroup	Day	RBC	HGB	MCV	MCHC	MCH	HCT	PLT	WBC
A	7	5.70±1.58	10.36±24.58	53.76±2.41	34.10±0.00	18.33±0.80	30±0.07	500.67±394.65	8.50±2.85
	15	9.10±1.67	14.83±21.38	49.26±2.97	33.50±1.00	16.50±0.98	44±0.06	545.67±317.97	9.26±1.88
	30	6.91±0.95	12.65±16.26	53.45±0.07	34.250±3.53	18.30±0.14	36±0.05	594.00±45.25	5.95±0.35
B	7	7.77±0.00	12.50±0.00	48.00±0.00	33.50±0.00	16.10±0.00	37±0.00	1171.00±0.00	9.80±0.00
	15	8.13±1.31	13.80±8.66	51.96±5.50	33.00±6.08	17.16±1.85	41±0.02	695.33±174.90	14.36±6.80
	30	6.48±2.28	11.46±36.11	52.96±4.16	33.70±6.08	17.80±1.05	34±0.10	427.67±121.02	7.80±3.67
Control A-B	7	8.28±0.54	14.83±13.87	51.4±2.15	310.0±17.32	18.33±0.81	0.43±0.01	670.67±100.32	9.84±1.36
	15	8.89±0.39	13.73±2.52	52.90±1.08	310.00±20.00	16.50±0.98	0.44±0.03	630.67±226.29	9.27±1.89
	30	9.18±0.83	13.26±5.03	52.97±2.84	323.33±25.17	17.20±0.89	0.43±0.01	832.33±238.12	7.11±0.88
Reference Ranges		7.34-8.85 [23]	14.7-17.3 [23]	46-57 [24]	31.3-34.4 [23]	18.6-20.7 [23]	44.9-51.7 [23]	804-1282 [24]	6.63-20.35 [23]
P	group	0.074	0.306	0.700	0.005**	0.525	0.083	0.233	0.334
	day	0.116	0.187	0.434	0.408	0.141	0.078	0.417	0.068
	day x group	0.283	0.200	0.375	0.955	0.297	0.318	0.122	0.736

**Subgroup A-** direct coverage of pulp with calcium aluminate in both teeth; **Subgroup B-** direct coverage of pulp with calcium silicate in both teeth

**Table 2.** Second study group: mean and standard deviation of haematological parameters after subdermal implementation of calcium aluminate (C) and calcium silicate (F) polyethylene tubes on both sides of spine

Subgroup	Day	RBC	HGB	MCV	MCHC	MCH	HCT	PLT	WBC
C	7	5.69±1.97	10.56±38.28	53.86±0.15	34.30±8.71	18.50±0.43	30±0.10	902.00±302.37	5.76±3.23
	15	9.84±0.74	17.30±18.19	51.43±1.55	34.13±7.63	17.56±0.56	50±0.05	548.33±161.86	9.06±3.69
	30	6.15±1.40	11.25±19.09	53.50±2.40	34.40±4.24	18.40±1.13	32±0.06	423.00±103.23	5.90±2.26
F	7	7.95±1.18	14.25±21.92	52.30±0.42	34.25±0.70	17.95±0.07	41±0.06	698.00±186.67	13.15±3.18
	15	9.25±1.22	16.53±18.00	52.96±1.30	33.86±1.15	17.90±0.36	48±0.05	402.00±46.93	6.95±5.34
	30	7.57±0.59	12.50±17.67	50.45±2.33	33.05±4.95	16.65±1.06	38±0.04	599.00±4.24	8.25±0.07
Control C-F	7	8.28±0.73	15.70±4.36	51.93±1.72	323.33±20.82	17.17±0.86	0.44±0.02	955.67±84.23	6.85±0.23
	15	8.13±0.84	13.87±8.98	52.52±0.98	309.83±0.29	16.94±1.23	0.43±0.01	636.97±30.81	8.60±1.67
	30	8.49±0.74	13.86±16.25	51.87±1.11	322.27±1.79	16.89±0.50	0.43±0.01	863.51±81.19	7.43±1.22
Reference Ranges		7.34-8.85 [23]	14.7-17.3 [23]	46-57 [24]	31.3-34.4 [23]	18.6-20.7 [23]	44.9-51.7 [23]	804-1282 [24]	6.63-20.35 [23]
P	group	0.141	0.299	0.353	0.000**	0.025*	0.128	0.008**	0.249
	day	0.010*	0.014*	0.604	0.370	0.369	0.004**	0.001**	0.570
	day x group	0.035*	0.030*	0.139	0.405	0.353	0.043*	0.214	0.147

**Subgroup C-** subdermal implementation of calcium aluminate polyethylene tubes on both sides of spine, half a tube; **Subgroup F-** subdermal implementation of calcium silicate polyethylene tubes on both sides of spine, half a tube

Regarding PLT, after performing Post Hoc Tuckey test, we saw that there is significant difference between the means of the control and subgroup F. The Post Hoc Tuckey test showed the significant difference in PLT between the means of the 7<sup>th</sup> and 15<sup>th</sup> days (P<0.01) and the 7<sup>th</sup> and 30<sup>th</sup> days (P<0.05) (Table 2).

There were no statistically significant differences in the total number of WBC (Table 1, Table 2) or the percentage results for lymphocytes, immature and mature neutrophils.

The Post Hoc Tukey test showed a significant difference related to the mean values of monocytes between the control and subgroup B (P<0.05). We see a significant difference related to the mean values of monocytes

between the control and subgroup C (P<0.05), and the control and subgroup F (P<0.01) (Table 3, Table 4).

The Post Hoc Tukey test showed a significant difference related to the mean values of basophil between the 7<sup>th</sup> and the 30<sup>th</sup> days (P<0.05) (Table 4).

**Results of Microscopic Examination of Peripheral Blood**

Analysis of peripheral blood smears in rats showed the significant presence of anulocytes (hypochromic RBC) with low haemoglobin content (Fig. 1-e, Fig. 2).

According to semi-quantitative classification of poikilocytes<sup>[18]</sup> there were moderate percentage values of stomatocytes present (>3-10%), as well as the same poikilocytic forms

**Table 3.** First study group leucogram (%) mean and standard deviation after direct coverage of the pulp with calcium aluminate and calcium silicate

Subgroup	Days	Mature Neutrophyl	Immature Neutrophyl	Basophils	Acidophils	Lymphocytes	Monocyte
A	7 (n=3)	22.00±12.16	2.20±1.05	2.00±0.34	0.66±0.57	70.03±13.19	0.66±0.57
	15 (n=3)	9.00±8.18	1.66±2.88	0.00±0.00	0.33±0.57	85.66±12.05	0.33±0.57
	30 (n=3)	10.00±2.00	1.33±1.15	0.00±0.00	1.00±1.00	82.00±2.00	2.00±0.00
B	7 (n=3)	32.66±3.21	0.66±0.57	0.33±0.57	0.66±0.57	61.33±6.11	0.33±0.57
	15 (n=3)	23.26±20.43	3.20±2.88	0.00±0.00	2.00±1.00	64.76±18.75	1.33±0.57
	30 (n=3)	12.33±5.13	1.33±0.57	0.00±0.00	0.33±0.57	82.66±6.50	1.00±0.00
Control	7 (n=3)	17.00±5.41	0.67±0.76	0.50±0.50	2.00±1.00	77.67±6.81	2.17±1.61
	15 (n=3)	14.5±7.05	1.00±0.00	0.23±0.25	0.50±0.50	79.07±12.57	2.00±1.00
	30 (n=3)	17.67±4.16	1.83±1.04	0.33±0.58	1.00±1.00	75.33±5.13	1.83±1.04
Reference Ranges		3.5-18.7% [23]	-	0.2-0.6% [23]	0.0-0.6% [23]	75.8-92.9% [23]	0.5-3.4% [23]
P	day	0.062	0.572	0.238	0.674	0.133	0.355
	group	0.130	0.673	0.197	0.409	0.146	0.018*
	day x group	0.362	0.367	0.992	0.032*	0.210	0.164

**Subgroup A** - direct coverage of pulp with calcium aluminate in both teeth; **Subgroup B** - direct coverage of pulp with calcium silicate in both teeth

**Table 4.** Second study group leucogram (%) mean and standard deviation after subdermal implementation of calcium aluminate and calcium silicate polyethylene tubes on both sides of spine

Subgroup	Days	Mature Neutrophyl	Immature Neutrophyl	Basophils	Acidophils	Lymphocytes	Monocyte
C	7 (n=3)	13.16±6.52	1.00±1.00	0.33±0.57	1.33±1.52	79.66±5.75	1.50±0.86
	15 (n=3)	15.33±5.85	1.00±1.00	0.00±0.00	1.66±1.52	78.66±7.57	0.33±0.57
	30 (n=3)	21.33±1.52	2.00±0.00	0.66±0.57	0.83±1.44	71.00±3.00	1.83±1.04
F	7 (n=3)	11.68±2.06	1.58±1.50	1.68±0.65	2.26±1.16	76.75±1.61	1.25±0.66
	15 (n=3)	16.66±10.40	0.76±0.40	0.86±0.23	0.00±0.00	78.80±10.92	0.76±0.40
	30 (n=3)	12.33±6.65	1.33±1.52	0.00±0.00	0.00±0.00	83.66±5.85	0.33±0.57
Control	7 (n=3)	20.00±2.65	1.50±0.50	0.67±0.58	0.50±0.50	74.50±1.32	2.17±0.76
	15 (n=3)	19.71±1.69	1.00±1.00	0.27±0.35	1.00±1.00	76.42±0.62	2.15±0.05
	30 (n=3)	20.03±1.91	0.68±0.79	0.17±0.29	1.00±0.00	75.88±2.13	2.24±1.25
Reference Ranges		3.5-18.7% [23]	-	0.2-0.6% [23]	0.0-0.6% [23]	75.8-92.9% [23]	0.5-3.4% [23]
P	day	0.475	0.613	0.016*	0.307	0.892	0.312
	group	0.061	0.628	0.036*	0.516	0.255	0.003**
	day x group	0.444	0.475	0.011*	0.109	0.173	0.239

**Subgroup C** - subdermal implementation of calcium aluminate polyethylene tubes on both sides of spine, half a tube; **Subgroup F** - subdermal implementation of calcium silicate polyethylene tubes on both sides of spine, half a tube


after thirty days' treatment with calcium aluminate.

Conical shaped RBC with a central dent, or a uniconical shape is called a stomatocyte. As mentioned before, their presence was shown (Fig. 1-a,c,d; Fig. 2).

On the 7<sup>th</sup> and 15<sup>th</sup> days, all experimental groups, in both tissues and those treated with both dental materials showed a "mild" appearance of stomatocytes (>0.5-3%) (Fig. 2). The presence of spherocytes is classified as "moderate" (>3-10%) (Fig. 2, Fig. 1-f). Very low values of schizocytes were found, that is, another poikilocytotic form of RBC. Their presence on blood smears was "rare" (0.05-0.5%) in all study groups and their subgroups (Fig. 2).

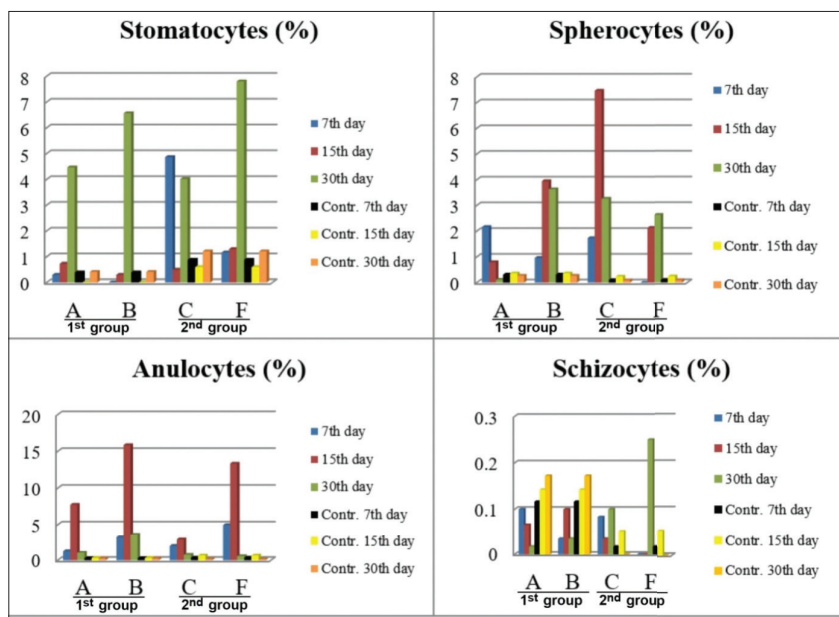
## DISCUSSION

It is widely known that the contact of bioactive materials with a tissue surface leads to specific biological response. Many authors [8-10] have determined that acute inflammation is not always present. Our research did not determine any acute form of inflammation, which may be explained by the fact that lymphocytes and neutrophils, and the total number of WBC in all the experimental and control groups were within the reference ranges. Likewise, the lack of inflammation processes may be related to the appropriate application of dental treatment on the pulp, as well as the suitable subcutaneous surgical procedures.



**Fig 1.** Poikilocytic forms of RBC, peripheral blood smear, magnification 1000x; a- Red arrow - stomatocytes, white arrow - RBC in the process of destruction; b- Healthy RBC; c- Red arrow - stomatocytes, white arrow - RBC in the process of destruction; d- Red arrow - stomatocytes; e- White arrow - anulocytes, red arrow - stomatocytes; f- White arrow - spherocytes

**Fig 2.** Percentage ratios of poikilocytic RBC forms



Rats are animals with a pronounced lymphocyte blood chart [11,13,23,24]. Our research recorded a trend of dominant percentage values of lymphocytes compared to other cells of the leukocyte type (Table 1). The significant differences

in the mean values of basophils, acidophils and monocytes could be explained by their low and narrow physiological benchmarks [11,23,24]. Thus, they may be ignored. Our results correspond to those in Leprince et al.[25].

The lower values of PLT and significant differences between the mean values of the control and on day 30 ( $P < 0.05$ ) could be explained by the loss of PLT caused by their role in stopping bleeding after surgery, anaesthetic application, or blood sampling due to haematological analysis.

Osan et al.<sup>[15]</sup> studied the biocompatibility of dental cements (Ivoclar D and DSM and Vitadur D and DSM) after subdermal implementation, using the bone marrow and blood corpuscles of the peripheral blood of experimental rats.

In our research, the target location of the first study group (subgroup A and subgroup B) was direct coverage of pulp. Dental pulp in rats is fairly innervated and vascularized, especially in peripheral areas, containing a odontoblastic and sub odontoblastic capillary plexus.

The study recorded lower numbers of RBC, which showed no connection with the type of implanted material, on the dental pulp (subgroup A and subgroup B). In the second study group (subgroups C and F) there were significant differences related to both types of implanted cement, between the 7<sup>th</sup> and 15<sup>th</sup> days, and the 15<sup>th</sup> and 30<sup>th</sup> days of the experiment.

The results indicate expressed oligocythemia caused by the application of calcium aluminate and calcium silicate, especially because the number of RBC in the control group was within the physiological limits. Likewise, lower values of haemoglobin indicate hypochromia<sup>[26]</sup>. The values of RBC, HGB and HCT indicate the existence of hypochromic anaemia caused by the damaging influence of calcium aluminate and calcium silicate. Since MCV was within the reference values, the anaemia present may be characterised as hypochromic anaemia of the normocytic type.

Some researchers determined the link between anaemia and the effects of aluminium *in vivo* and *in vitro*. Independent of the aluminium compound or application method, anaemia was confirmed in mice, rabbits and rats. Its toxic influence was confirmed in mature RBC in peripheral blood, as well as in progenitor cells in bone marrow<sup>[27,28]</sup>.

Likewise, hypochromic anaemia of the normocytic type was determined in animals treated with calcium silicate (subgroup B-pulp and subgroup F-subdermal tissue). The available literature does not reveal research studies showing a similar toxic effect of calcium silicate on RBC parameters.

Healthy RBC in rats have a biconcave disk shape, as in most mammals<sup>[29]</sup>. The appearance of poikilocytotic forms of erythrocytes is not rare, and is caused by biochemical or pathophysiological changes due to the influence of toxins or physical trauma to the RBC. They may directly support the occurrence of anaemia<sup>[19,26,30]</sup> independently of etiological factors. The type of abnormally shaped RBC with

a lighter central area and darker periphery that resembles a ring, is called an anulocyte. It occurs in iron deficiency or hypochromia<sup>[31]</sup>.

When we evaluated the effects of aluminium compounds on mature RBC *in vivo*, the results were similar to those obtained in the study by Vitori et al.<sup>[27]</sup> and Vitori et al.<sup>[28]</sup>. Research by Vittori et al.<sup>[28]</sup> proved the direct influence of aluminium citrate or aluminium chloride on mature human RBC and erythroprogenitor precursor cells in different species after 14 days of application. Their transformation into stomathocytes and acanthocytes was detected. They proved the hypothesis using an electronic microscope, which showed a significant amount of aluminium connected to the RBC membrane<sup>[28]</sup>. This undoubtedly indicated the effect of aluminium on RBC, reshaping them into stomathocytes, which finally leads to the appearance of anaemia. Microscopic examination of peripheral blood smears revealed a smaller number of RBC in the process of destruction, which represents haemolysis, meaning that the haemoglobin is leaving the RBC stroma.

Our research did not reveal the presence of acanthocytes, as recorded in other studies<sup>[28]</sup>, however, there was a smaller presence of some other poikilocytotic forms of RBC, such as schizocytes. Their presence was "rare" in our study, and associated with the following: mechanical trauma of the cell during the creation of blood smears, the influence of anticoagulants, or microscopy on the edges of the blood smear<sup>[19,29]</sup>. Significance was given to the presence of spherocytes, classified as "moderate" (>3-10%). In available literature, a higher presence of this type of cells is linked to different types of anaemia<sup>[19,29,32]</sup>.

The toxic influence of calcium silicate on RBC and the appearance of anaemia has not been completely explained. Our research showed that with application on to the pulp, subdermal hypochromic anaemia of the normocytic type exists, along with modest (>3-10%) to expressed (>15%) distribution of anulocytes and stomathocytes.

The effects of calcium silicate were more pronounced compared to those of calcium aluminate. There is not enough literature dealing with the effects of calcium silicate on haematological parameters in *in vitro* or *in vivo* experiments. Thus, it would be beneficial to determine the transformation of poikilocytotic RBC after treatment with calcium silicate using electronic microscopy. This is even more significant if we take into account the wide usage of calcium silicate in human and veterinary dentistry.

The influence of the tested dental cements on haematological parameters is unfavourable, leading to the appearance of hypochromic anaemia of the normocytic type. The study detected expressed anulocytosis in the groups treated with calcium silicate, and moderate stomatocytosis in the groups treated with calcium aluminate. Likewise, moderate spherocytosis was present following

the application of both cements implemented in both tissues. The aforementioned poikilocytotic forms are the vanguard of RBC destruction, in other words haemoglobin leaves the RBC stroma. The results imply the possibility of haematological disorders after cement is implanted in humans. Further studies are needed (in humans) to clarify the possible negative effects of these materials in human dentistry.

## CONFLICTS OF INTEREST

The authors declare no conflict of interest.

## REFERENCES

- Delibegovic S, Dizdarevic K, Cickusic E, Katica M, Obhodjas M, Ocus M:** Biocompatibility of plastic clip in neurocranium - Experimental study on dogs. *Turk Neurosurg*, 26 (6): 866-870, 2016. DOI: 10.5137/1019-5149.JTN.13979-15.1
- Delibegovic S, Katica M, Latic F, Jakic-Razumovic J, Koluh A, Njoom MTM:** Biocompatibility and adhesion formation of different endoloop ligatures in securing the base of the appendix. *JSLs*, 17, 543-548, 2013. DOI: 10.4293/108680813X13654754534116
- Modareszadeh MR, Chogle SA, Mickel AK, Jin G, Kowsar H, Salamat N, Shaikh S, Qutbudin S:** Cytotoxicity of set polymer nanocomposite resin root-end filling materials. *Int Endod J*, 44 (2): 154-161, 2011. DOI: 10.1111/j.1365-2591.2010.01825.x
- Murray PE, Garcia-Godoy C, Garcia-Godoy F:** How is the biocompatibility of dental biomaterials evaluated? *Med Oral Patol Oral Cir Bucal*, 12:E258-66, 2007.
- Janković O, Paraš S, Tadić-Latinović Lj, Josipović R, Jokanović V, Živković S:** Biocompatibility of nanostructured biomaterials based on calcium aluminate. *Srp Arh Celok Lek*, 146, 634-640, 2018. DOI: 10.2298/SARH171211030J
- Violeta P, Vanja OG, Jokanović V, Jovanović M, Gordana BJ, Zivković S:** Biocompatibility of a new nanomaterial based on calcium silicate implanted in subcutaneous connective tissue of rats. *Acta Vet Beograd*, 62, 697-708, 2012. DOI: 10.2298/AVB1206697P
- Katica M, Čelebičić M, Gradašević N, Obhodžaš M, Suljić E, Očuz M, Delibegović S:** Morphological changes in blood cells after implantation of titanium and plastic clips in the neurocranium-experimental study on dogs. *Med Arch*, 71 (2): 84-88, 2017. DOI: 10.5455/medarh.2017.71.84-88
- Kramer PR, Woodmansey KF, White R, Primus CM, Opperman LA:** Capping a pulpotomy with calcium aluminosilicate cement: Comparison to mineral trioxide aggregates. *J Endod*, 40 (9): 1429-1434, 2014. DOI: 10.1016/j.joen.2014.02.001
- Opačić-Galić NV:** Study of biocompatibility of nanostructured biomaterials based on active calcium silicate system and hydroxyapatite. *PhD thesis*, University of Belgrade, Faculty of Dentistry, Belgrade, 2014.
- Zand V, Lotfi M, Aghbali A, Mesgariabbasi M, Janani M, Mokhtari H, Tehranchi P, Pakdel SMV:** Tissue reaction and biocompatibility of implanted mineral trioxide aggregate with silver nanoparticles in a rat model. *Iran Endod J*, 11 (1): 13-16, 2016. DOI: 10.7508/iej.2016.01.003
- Katica M, Gradasević N:** Hematologic profile of laboratory rats fed with bakery products. *Int J Res-Granthaalayah*, 5 (5): 221-231, 2017. DOI: 10.5281/zenodo.583912
- Švajhler T, Filipović-Zore I, Kobler P, Macan D:** The Use of experimental animals during investigation of dental implants. *Acta Stomatol Croat*, 31, 213-220, 1997.
- Katica M, Delibegović S:** Laboratorijske životinje: Osnovne Tehnike Eksperimentalnog Rada. 41-62, Dobra Knjiga, Sarajevo, 2019.
- McNamara RP, Henry MA, Schindler WG, Hargreaves KM:** Biocompatibility of accelerated mineral trioxide aggregate in a rat model. *J Endod*, 36 (11): 1851-1855, 2010. DOI: 10.1016/j.joen.2010.08.021
- Osan FD, Borzea D, Tătaru I, Prodan I, Mănălăchioae R, Marcus I:** Biocompatibility study concerning hematological reactions accompanying subcutaneous implantation of some dental products in wistar rats. *Bulletin UASVM, Vet Med*, 67, 185-192, 2010.
- Houda H, Fatiha G, Houria B, Aicha T, Rachid R, Mohammed Reda D:** Toxic effects of acrolyc denture teeth resin, lucitone 119 on animal model: Rats wistar. *Am Eur J Toxicol Sci*, 3 (1): 36-40, 2011.
- Jokanović V, Čolović B, Mitrić M, Marković D, Četenović B:** Synthesis and properties of a new dental material based on nano-structured highly active calcium silicates and calcium carbonates. *Int J Appl Ceram Technol*, 11 (1): 57-64, 2014. DOI: 10.1111/ijac.12070
- Christopher MM, Hawkins MG, Burton AG:** Poikilocytosis in rabbits: Prevalence, type, and association with disease. *Plos One*, 9 (11): e112455, 2014. DOI: 10.1371/journal.pone.0112455
- Harvey JW:** Atlas of Veterinary Haematology. W.B. Saunders Company, Philadelphia, 2001.
- Weiss DJ:** Uniform evaluation and semiquantitative reporting of hematologic data in veterinary laboratories. *Vet Clin Pathol*, 13 (2): 27-31, 1984. DOI: 10.1111/j.1939-165x.1984.tb00836.x
- Zini G, D'Onofrio G, Briggs C, Erber W, Jou JM, Lee SH, McFadden S, Vives-Corróns JL, Yutaka N, Lesesve JF:** ICSH recommendations for identification, diagnostic value, and quantification of schistocytes. *Int J Lab Hematol*, 34 (2): 107-116, 2012. DOI: 10.1111/j.1751-553X.2011.01380.x
- Minitab Statistical Software**, release 19. [Computer software]. State College, PA: Minitab, Inc., 2019.
- Car BD, Eng VM, Everds NE, Bounous DI:** Clinical pathology of the rat. In: Suckow MA, Weisbroth SH, Franklin CL (Eds): *The Laboratory Rat*. 2<sup>nd</sup> ed., 127-145, Elsevier, London, 2006.
- Kampfmann I, Bauer N, Johannes S, Moritz A:** Differences in hematologic variables in rats of the same strain but different origin. *Vet Clin Pathol*, 41 (2): 228-234, 2012. DOI: 10.1111/j.1939-165X.2012.00427.x
- Leprince JG, Zeitlin BD, Tolar M, Peters OA:** Interaction between immune system and mesenchymal stem cell in dental pulp and periapical tissues. *Int Endod J*, 45 (8): 689-701, 2012. DOI: 10.1111/j.1365-2591.2012.02028.x
- Bush BM:** Textbook of Interpretation of Laboratory Results for Small Animal Clinicians. Royal Veterinary College, 60-70, Blackwell Science, London, 1998.
- Vittori D, Nesse A, Perez G, Garbossa G:** Morphological and functional alterations of erythroid cells induced by longterm ingestion of aluminium. *J Inorg Biochem*, 76, 113-120, 1999.
- Vittori D, Garbossa G, Lafourcade C, Perez G, Nesse A:** Human erythroid cells are affected by aluminium. Alteration of membrane band 3 protein. *Biochim Biophys Acta*, 1558 (2): 142-150, 2002. DOI: 10.1016/S0005-2736(01)00427-8
- Božić T, Ivanović Z:** Patofiziologija Čelija Krvi. In: Božić T (Ed): *Patološka Fiziologija Domaćih Životinja*. 2<sup>nd</sup> ed., 40-67, Naučna KMD, Belgrade, 2012.
- Marks PW:** Hematologic manifestations of liver disease. *Semin Hematol*, 50 (3): 216-221, 2013. DOI: 10.1053/j.seminhematol.2013.06.003
- Amoroso A, Fanelli FR:** Semeiotica medica e metodologia clinica. In: Delfino A (Ed), *Semeiotica Del Sistema Emopoietico*, Capitolo, 9, 527-530, Medicina-Scienze, 2014.
- Katica M, Šeho-Alić A, Čelebičić M, Prašović S, Hadžimusić N, Alić A:** Histopathological and hematological changes by head abscess in rat. *Veterinaria*, 68 (3): 151-156, 2019.