

Interconnected Multiple Gastroesophageal Fish Hook Retrievals by Endoscopic or Surgical Interventions In Dogs: 13 Cases (2010-2017) ^[1]

Cenk YARDIMCI ^{1,a} Kamil Serdar İNAL ^{1,b} Taylan ÖNYAY ^{1,c} Ahmet ÖZAK ^{1,d}

^[1]The study was presented as a poster in the 11th International and 17th National Veterinary Surgery Congress of Turkey, 20-23th September 2018, Bafra, North Cyprus

¹ Ondokuz Mayıs University Faculty of Veterinary Medicine, Department of Surgery, TR-55200 Atakum, Samsun - TURKEY

^a ORCID: 0000-0001-6126-3603; ^b ORCID:0000-0003-0690-5743; ^c ORCID: 0000-0001-5638-7257; ^d ORCID:0000-0002-4359-0691

Article ID: KVFD-2019-22766 Received: 30.05.2019 Accepted: 30.09.2019 Published Online: 01.10.2019

How to Cite This Article

Yardimci C, İnal KS, Önyay T, Özak A: Interconnected multiple gastroesophageal fish hook retrievals by endoscopic or surgical interventions in dogs: 13 cases (2010-2017). *Kafkas Univ Vet Fak Derg*, 26 (2): 209-215, 2020. DOI: 10.9775/kvfd.2019.22766

Abstract

The aim of this study was to evaluate endoscopic and/or surgical removal of interconnected, multiple fish hooks that lodge in gastroesophageal region in dogs. Medical records were obtained and clinical, radiographic and endoscopic evaluations were performed for 13 dogs with gastroesophageal multiple fish hooks. Endoscopic, surgical and endoscopy assisted surgical removal was performed depending on penetration degree of the hooks. Distribution of the hooks were 9 (13.2%) in the cranial esophagus, 40 (58.8%) in the cervical esophagus, 17 (25%) in the thoracic esophagus and 2 (3%) in the stomach. Retrieval of the hooks was performed endoscopically in 11 cases, surgically in one case and combined in one case. There were no complicated mucosal erosions or lacerations associated with removal of the hooks. It is very important to remove fish hooks as soon as possible to reduce complication rates and the dog owners should be warned to beware of fishing areas.

Keywords: Dog, Endoscopy, Esophagus, Fish hooks, Foreign body

Köpeklerde Birbirine Bağlı Gastroözefageal Çoklu Balık Kancalarının Endoskopik ve Cerrahi Girişimlerle Uzaklaştırılması: 13 Olgu (2010-2017)

Öz

Bu çalışmanın amacı, köpeklerde gastroözefageal bölgeye takılan birbirlerine bağlı çoklu balık kancalarının endoskopik ve cerrahi girişimlerle uzaklaştırılmasının değerlendirilmesidir. Hastaların kayıtları alındıktan sonra gastroözefageal çoklu balık kancası olan 13 köpeğin radyografik ve endoskopik değerlendirilmeleri yapıldı. Kancaların penetrasyon derecesine bağlı olarak endoskopik, cerrahi ve endoskopi yardımcı cerrahi uzaklaştırma uygulandı. Kancaların dağılımları; kranial özofagusta 9 (%13.2), servikal özofagusta 40 (%58.8), torakal özofagusta 17 (%25) ve midede 2 (%3) idi. Kancaların uzaklaştırılması 11 olguda cerrahi, bir olguda endoskopik olarak gerçekleştirildi ve bir olguda kombine edildi. Kancaların uzaklaştırılmasına bağlı olarak komplike mukozal erozyon veya laserasyon gözlenmedi. Komplikasyon oranını azaltmak için balık kancalarını mümkün olan en kısa sürede çıkarmak oldukça önemlidir ve köpek sahipleri balık avlama alanlarında dikkatli olmaları için uyarılmalıdır.

Anahtar sözcükler: Balık kancası, Endoskopi, Köpek, Özefagus, Yabancı cisim

INTRODUCTION

Household pets are prone to foreign body ingestion and this occurrence is relatively common in dogs ^[1-3]. Bones are the most commonly encountered esophageal foreign bodies (EFB)s, although balls, toys, fish hooks and wood sticks were also reported ^[3-5]. Some dogs may remain asymptomatic but most show acute clinical symptoms that include gagging, hypersalivation, dysphagia and

discomfort on palpation ^[3]. When the symptoms are obvious, EFB is considered as an emergency case in veterinary medicine ^[3,5-7].

Clinical symptoms and complications of ingested fish hooks vary due to the number, size and localization of fish hooks, time elapsed since ingestion, depth of penetration and the presence and magnitude of perforation ^[8,9]. The most likely places of ingested fish hooks to lodge are



İletişim (Correspondence)



+90 362 3121919 (1228)



cyardimci@omu.edu.tr

the base of the heart, thoracic inlet and esophageal hiatus because of natural anatomical strictures [5,8]. While fish hooks can easily be detected in radiographic examination, endoscopy is still the golden diagnostic method of choice because it allows visualization of the hook and proper detection of mucosal damage [3]. Esophagitis, aspiration pneumonia, esophageal perforation, and esophageal stricture formations may occur due to damage from hooks [2,4,10-12].

Fishhook and bone more likely cause perforation in all EFBs. Endoscopic retrieval is preferred over surgery but it is not always possible because the hooks may be lodged in the mucosa and retrieval may cause tear damage. Barbed shape of the hooks disallows simple removal in most cases as they are designed to lodge in place. If endoscopic retrieval fails, and/or seemed to be too risky, surgical intervention must be considered [5]. The fish hook should be removed as soon as possible as movement due to peristaltic action may cause or worsen mucosal damage [2,4,10].

The purpose of this study was to demonstrate the clinical experience of endoscopic, endoscopy assisted surgical or surgical removal of multiple fish hooks that were attached to one another in the gastroesophageal area. Additionally, it is unique because this is the first paper to report ingestion of multiple hooks attached with a line to each other.

MATERIAL and METHODS

Animals

The study material was composed of 13 dogs that were brought to Animal Hospital of Ondokuz Mayıs University with suspicion of foreign body ingestion. They were confirmed to have interconnected multiple fish hooks in different sizes between their esophagus and pylorus. Signalment of the patients, time between ingestion and clinical intervention and methods used for removal are presented at *Table 1*.

After patient histories were noted, complete physical evaluations and oral cavity examinations were performed for each patient. The localization of fish hooks were noted in the general areas of the cranial esophagus (caudal pharynx), cervical esophagus (between cranial esophagus and thoracic inlet), thoracic esophagus (between thoracic inlet and diaphragm), caudal esophagus (between diaphragm and cardia) and stomach.

Grading of the Patients

Savary-Miller classification was used to grade esophageal lesions related to fish hooks [13]. According to this, single erosions were classified as grade I, confluent erosions were

Table 1. Case details of the dogs with ingested fish hooks

Case No	Signalment	Number of the Hooks	Hook Size	Localization of the Hooks	Duration of Time From Ingestion to Removal Attempt (Approximately)	Technique/Duration of the Procedure
1	Doberman Pinscher, 4-m-old, M, 32 kg	2 hooks	No:4 x 2	Cranial esophagus x 2	4 h	Endoscopic (10 min)
2	Mix breed, 18-m-old, M, 23 kg	4 hooks	No:4 x 4	Cervical esophagus x 4	8 h	Endoscopic (17 min)
3	Labrador Retriever, 3-y-old, M, 30 kg	10 hooks	No:4 x 10	Cervical esophagus x 2, Thoracic esophagus x 8	2 h	Endoscopic (75 min) + surgical (65 min)
4	Golden Retriever, 8-y-old, M, 33 kg	7 hooks	No:7 x 1 No:4 x 5 No:3 x 1	Cranial esophagus x 2, Cervical esophagus x 5	24 h	Endoscopic (26 min)
5	Mix breed, 9-m-old, F, 18 kg	5 hooks	No:4 x 5	Cervical esophagus x 5	18 h	Endoscopic (34 min)
6	Terrier, 15-m-old, M, 8 kg	3 hooks	No:3 x 3	Thoracic esophagus x 3	4 h	Endoscopic (20 min)
7	Labrador Retriever, 10-m-old, F, 22 kg	5 hooks	No:4 x 3 No:3 x 2	Cervical esophagus x 5	Unknown	Endoscopic (36 min)
8	Mix breed, 8-m-old, M, 14 kg	6 hooks	No:4 x 5 No:3 x 1	Cranial esophagus x 2 Cervical esophagus x 4	12 h	Endoscopic (19 min)
9	Golden Retriever, 14-m-old, M, 26 kg	8 hooks	No:7 x 8	Cervical esophagus x 8	24 h	Endoscopic (40 min)
10	Mix breed, 1-y-old, F, 15 kg	7 hooks	No:4 x 4 No:3 x 1 No:7 x 2	Cervical esophagus x 5 Thoracic esophagus x 2	2 h	Endoscopic (30 min)
11	Pointer, 18-m-old, F, 15 kg	2 hooks	No:3 x 2	Stomach x 2	Unknown	Surgical (40 min)
12	Mix breed, 2-y-old, M, 18 kg	6 hooks	No:3 x 6	Cervical esophagus x 2 Thoracic esophagus x 4	6 h	Endoscopic (27 min)
13	Mix breed, 15-m-old, M, 20 kg	3 hooks	No:4 x 3	Cranial esophagus x 3	Unknown	Endoscopic (10 min)

graded as II, while circular confluent erosions were graded as III and finally ulcerations, stenosis or perforations were graded as IV. Patients were evaluated according to their esophageal lesions as mild esophagitis (Grade I & II) or moderate esophagitis (Grade III & IV).

Anaesthesia

Initial endoscopic examination was performed under propofol anesthesia and soft tissue damage was visualized. If the fish hooks were not lodged in the soft tissue, endoscopic retrieval procedure was completed with propofol anesthesia. For fish hooks determined to be embedded in the soft tissue, the anesthesia was maintained with isoflurane (2% Isoflurane, Adeka®) and endoscopic retrieval procedure would then become a gastrotomy case. Simple endoscopic retrieval of the hooks was done under propofol anaesthesia (Propofol 1% Fresenius®) if the fish hooks and tangled lines could be removed easily. More complicated cases were intubated and maintained with isoflurane anesthesia (Isoflurane 2%, Adeka®).

Removal Process

Fish hooks which are not imbedded in the mucosa, were retrieved by endoscopy but the procedure was stopped immediately if pulling the entangled line and fish hooks would cause injury to the mucosa. If the fish hooks were lodged in, or pulling them would cause injury to the mucosa, surgery was performed. Endoscopic assistance was performed in some cases to reduce exposure of the surgery site.

Fish hooks were removed using three different methods; endoscopic, endoscopy assisted surgical, or surgical retrieval. If the hooks were retrieved solely by endoscopy, the procedure was classified as endoscopic retrieval. If the fish hook was removed surgically, it was classified as surgical retrieval. If the hooks were advanced to the caudal esophagus or cardia using endoscopy then removed via surgical intervention, this is classified as endoscopy assisted surgical retrieval.

In all patients, before any retrieval attempt, fishing line attachments were cut and hooks were separated in order to avoid complications during removal procedure. Endoscopic retrieval was performed by two techniques. In the first technique, free fish hooks were retrieved using flexible grasping forceps thorough the working channel of the endoscope. In the second technique, lodged fish hooks were retrieved with rigid grasping forceps without using the working channel of the endoscope. Retrograde endoscopic retrieval was performed with gastrotomy if the hooks could not be retrieved with endoscopy due to them being lodged in or would cause severe soft tissue damage upon retrieval.

Postoperative Care

After fish hooks retrieval, food is restricted for 24 h, after

12 h oral fluids has been given. Amoxicillin Clavulanic acid (Synulox, 12.5 mg oral tablet, Zoetis®) was administered for 5-7 days. In gastrotomy cases, meloxicam was also given for 3 days postoperatively at a dose of 0.1 mg/kg/day (Maxicam, 5 mg/mL, inj, Sanovel®, Turkey). The patients that endoscopic retrieval was performed on were discharged following recovery from the anaesthesia while the patients that required gastrotomy were hospitalized for 2 days.

Long term evaluation of patients was performed by clinical examinations, information from referring veterinarian or phone surveys with patient owners. Patient owners were asked if there were any signs of dysphagia, coughing, regurgitation or vomiting, especially during eating or drinking, and if any medical interventions were made 6 months following the removal of fish hooks.

The postoperative periods of the patients were graded according to their ability to consume food. As such, the patients that were able to consume any food without any difficulty was graded as very good. Patients that had some difficulty eating solid food such as kibbles with gag reflex but without vomiting were graded as good. The patients that could only consume soft food and liquids and gagged and vomited when eating solid food was graded as fair. Those having difficulty when eating even soft food and liquids are graded as poor.

RESULTS

The first clinical examination of patients revealed the symptoms of hypersalivation, and dampness of the front limbs due to this, unwillingness to eat or drink, reluctance to move the head with intermittent retching and gagging. Twelve of the 13 dogs in this study were large breed dogs and the male/female ratio was 9/4. The average age and body weights of the patients were 21.5 months and 21 kg, respectively. According to the international fish hook sizing chart, 41 of the hooks removed were size 4, 16 were size 3 and 11 were size 7 out of a total 68 fish hooks. The localization of fish hooks in the GI tract were as follows; 9 (13.2%) in the cranial, 40 (58.8%) in the cervical, 17 (25%) in the thoracic esophagus and 2 (3%) in the stomach. Aside from 3 cases (case no 7, 11 and 13) which the owners didn't know the exact time of occurrence, the time from ingestion to removal time was between 2-24 h (mean 10 h). The hooks were removed with endoscopy in 11 cases, endoscopy assisted surgery in one case and surgery in one case.

According to the patient histories, each owner stated that the probable time of ingestion was noticed but was deemed unimportant at the time because the ingested object was thought to be a piece of bread or fish. However since the incidents happened near common fishing spots, owners suspected something was wrong at the occurrence of the first clinical symptoms and brought their dogs immediately after.

Endoscopic Technique

This procedure was successfully performed in 11 of 12 (91.6%) patients to remove all fish hooks. In the remaining case (case no:3) five of the hooks were retrieved endoscopically and the other 5 were removed with endoscopy assisted gastrotomy. Endoscopic retrieval was not attempted in gastric cases due to possible complications. During endoscopic removal, barbs of the free hooks were held with the grasping forceps to avoid damaging the mucosal surface. The greatest challenge of endoscopic retrieval of attached hooks was their synchronized response to manipulations. In other words, the maneuvers made to remove one hook might have mobilized the others that are attached and that could have potentially damaged the mucosa or even lodged other hooks into it. To avoid this complication, lines attaching the hooks to each other were cut first. Freed single hooks were removed with a flexible grasping forceps (Fig. 1). However, this could not be done in lines that were tangled to each other in multiple

locations (Fig. 2a,b,c). In these cases, multiple hooks were tried to be removed at the same time (Fig. 2d). Superficial mucosal damage was either already present due to the fish hook ingestion (Fig. 3) or caused by the endoscopic retrieval (Fig. 4) due to barbs of the hooks in each case. However this superficial scarring was considered only as a mild disruption to the esophagus that did not require any kind of special treatment. The insertion of the endoscope from the mouth initiated the endoscopy duration and removal of the last hook marked the end. This duration changed depending on the number, size, localization of hooks, mucosal penetration level and the amount of entanglement. Endoscopy durations varied between 10 to 75 min with an average of 29 min.

Endoscopy Assisted Surgery

This was performed on 1 patient (case no:3) that swallowed 10 fish hooks (Fig. 5a) in total and endoscopic retrieval was only suitable for 5 of them. For removal of the remaining hooks that were lodged in diaphragmatic hiatus (Fig. 5b),

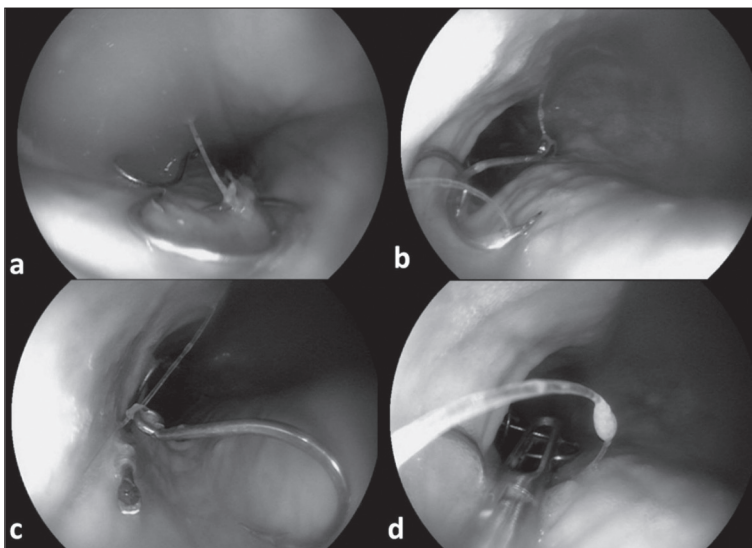


Fig 1. Free fish hooks were removed by taking care of the barbs for damaging the esophageal mucosa. First, lines were cut (a-c) and then hooks were grasped with forceps by securing the barb (d)

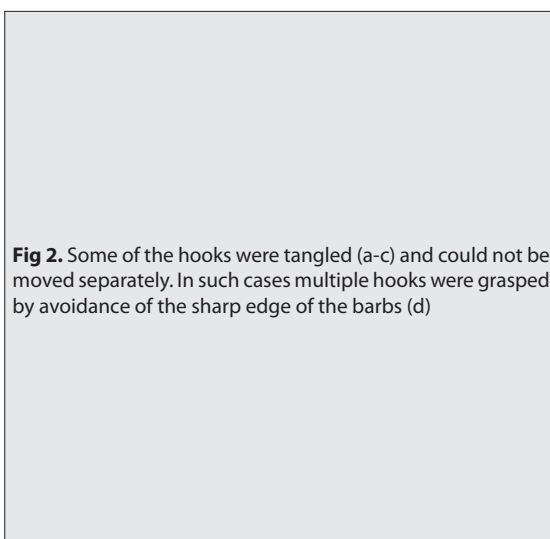
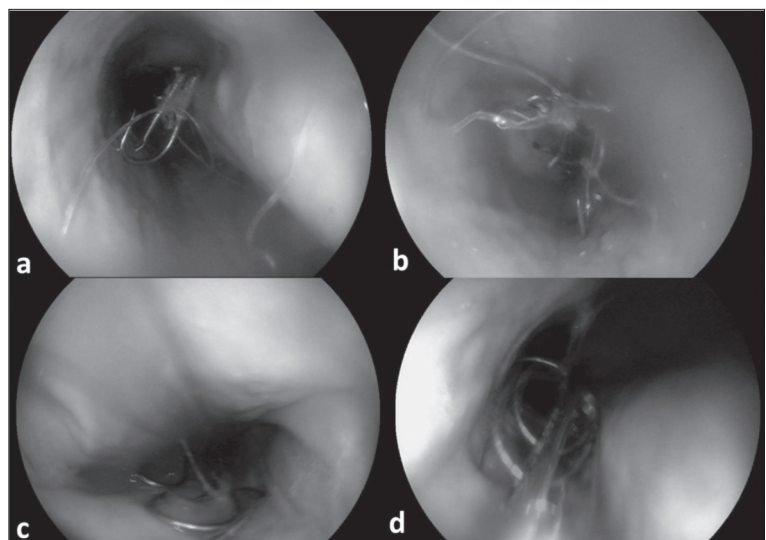


Fig 2. Some of the hooks were tangled (a-c) and could not be moved separately. In such cases multiple hooks were grasped by avoidance of the sharp edge of the barbs (d)



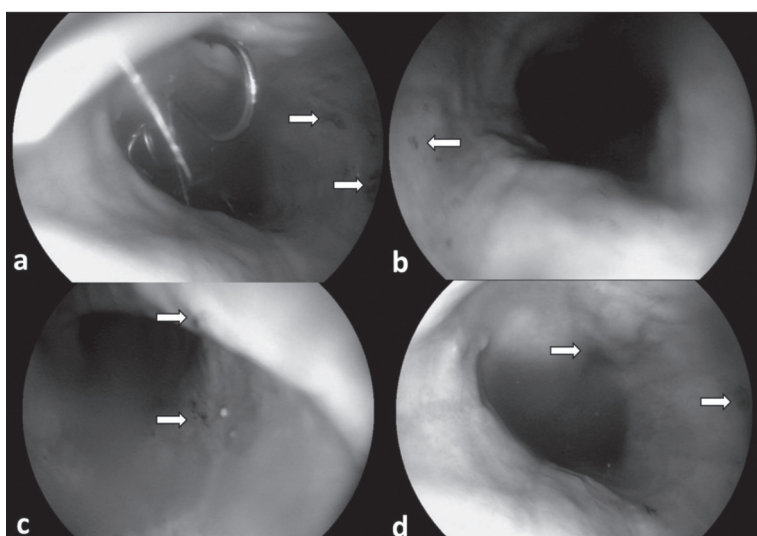


Fig 3. During endoscopic examination Savary-Miller Grade-I superficial erosions (arrows) of the esophageal mucosa owing to the free hooks were observed

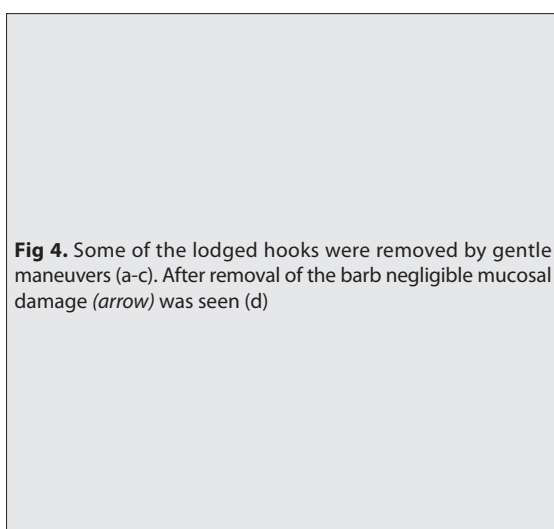
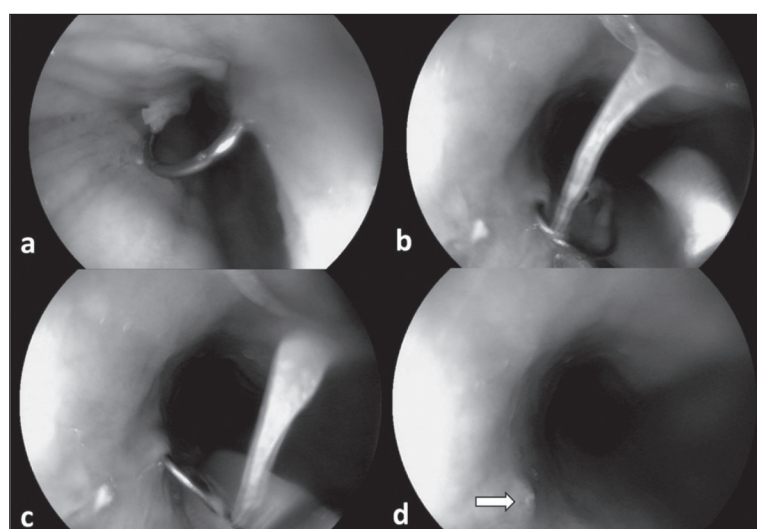


Fig 4. Some of the lodged hooks were removed by gentle maneuvers (a-c). After removal of the barb negligible mucosal damage (arrow) was seen (d)



retrograde esophagoscopy was performed following gastrotomy. The endoscope was passed through the cardia to the esophagus. The hooks lodged into the mucosa were removed with a rigid grasping forceps using slight force to the opposite side of the barbs to prevent serious damage to the mucosa. All were removed without any complication. The patient started consuming soft food at the 24th h and no long-term complications were observed.

Surgical Technique

This technique was performed in one case (case no: 11) with 2 fish hooks in the stomach. The stomach was exposed via a standard laparotomy and gastrotomy. One of the hooks was found embedded in the gastric muscle layer but the one attached to it was free. The free hook was seen to lose its sharp point, probably due to corrosion inside the stomach. The fish hook that pierced the gastric muscles was not pulled back but pushed forward in a circular fashion as to push its reverse barb out of the mucosa to cut it, then pulled back to the opposite side to remove it without tearing the gastric muscles or mucosa. Then, the

stomach and abdomen was routinely closed. The patient's condition was checked with regular phone surveys and its condition was found to be very well in the long term.

When long term results were evaluated, it was observed that all patients were very good. And no complications related to esophageal lesions were seen in any of the dogs.

DISCUSSION

The most common gastric and esophageal foreign bodies reported in dogs are bones, cartilage, chew treats and toys; the incidence of fish hooks are relatively low compared to the aforementioned foreign bodies [3,8]. This is probably due to the fact that fish hook usage is limited to lakes and coastal areas. No published data of esophageal multiple fish hook injuries of dogs have been reported until now [1,3,5,6,8]. In addition, the number of the gastric multiple fish hooks cases were reported to be only three [5]. This study evaluates only multiple fish hooks connected to each other with lines and whilst the case number may seem low, this retrospective

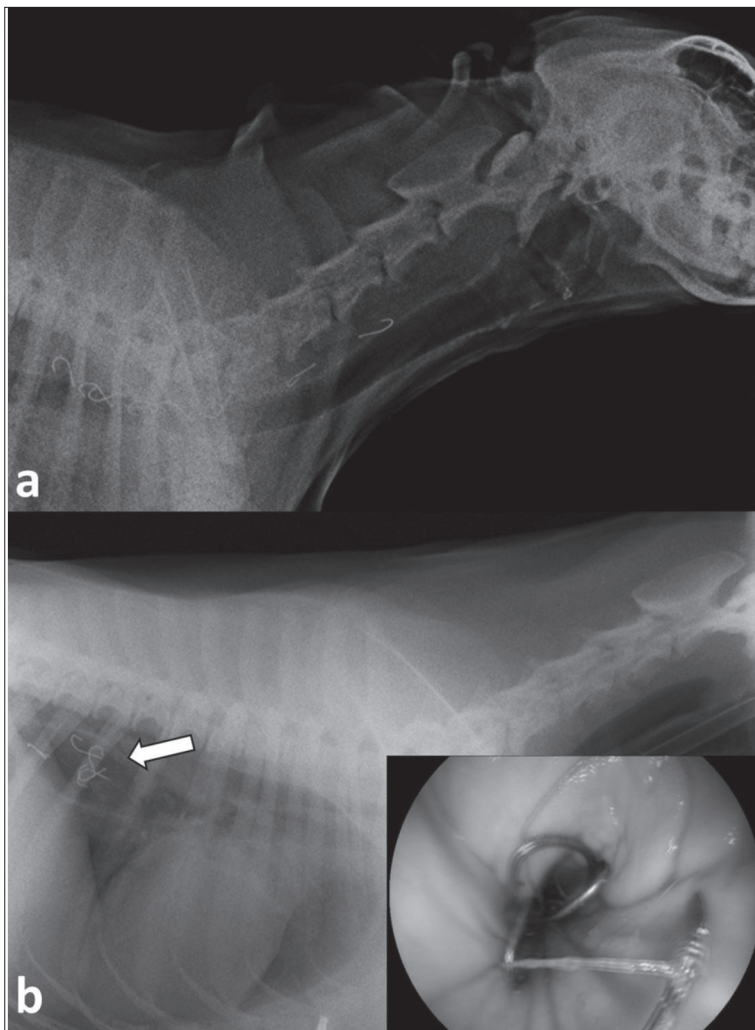


Fig 5. Lateral radiograph of a dog after ingestion of ten no: 4 fish hooks at the initial examination (a). Five of the hooks could remove endoscopically but the remaining five were tangled and stuck in the diaphragmatic hiatus (b). Following gastrotomy, retrograde esophagoscopy was performed for removal of the remaining hooks

study has the largest number of cases with interconnected multiple fish hook ingestion to date.

We could not find any etiological data concerning fish hook ingestion in dogs in the literature [5], but it is extremely improbable for a dog to find and ingest a fish hook without the human factor. Coastal fishing is very popular in the region where this study was done and is active all year round. According to the patient histories, most foreign body ingestions occurred due to fishing bait hiding hooks that were left behind by heedless fishermen. The most common etiological reason was the ingestion of multiple combination string hooks embedded in pieces of round bread pellet left unattended by fishermen, which can easily be swallowed by the dog because of its soft texture. Thus, it can be said that humans are responsible rather than animals in fish hook ingestion related injuries. Informing fishermen and dog owners about this subject should decrease the incidence of fish hook ingestion related injuries.

The initial lesions caused by the embedded fish hook is generally milder and more superficial than the ones caused during endoscopic removal. The combination of string's

attachment and entanglement levels is as important as the number of the hooks and their penetration levels to the mucosa. As such, any manipulation in order to remove one hook attached to others may cause them to penetrate the mucosa because they are also pulled away. To avoid this complication, cutting the combination fishing line initially is of utmost importance. Unfortunately it is not always possible with the use of endoscopy when the line is badly entangled. In such cases we think it would be best to move on to surgical removal without wasting any more time.

Complications occurring due to EFBs are generally classified as obstructions, local ischemias and lacerations. The main reported complications related to that are esophagitis esophageal lacerations, aspiration pneumonia, esophageal stricture formation and rarely pneumothorax, pneumomediastinum, pleural effusion, pyothorax, hemothorax, pneumonia, bronchoesophageal fistula, aortaesophageal fistula, cardiopulmonary arrest and death [2,4,10,11,14-17]. Previous study suggests that the perforation only becomes attached to the fish hook and bone within all EFBs [18].

Due to barbed structure of the fish hooks, mucosal injuries

are very compatible with lacerations and perforations from obstruction or ischemia. According to the authors, the reason for only superficial mucosal erosions in present study was evaluated as an intervention made shortly after the swallowing of the hooks. So, it should not be forgotten that early diagnosis and intervention is the most important step in preventing possible complications.

In a retrospective study including fish hook ingestions of 75 dogs and 3 cats in a duration of 16 years, multiple fish hooks were only seen in 4 dogs^[5]. In the same study, the fish hook localizations were as follows; 38 in the esophagus (all 38 had ingested only 1 fish hook), 39 in the stomach (36 had a single fish hook, 2 had 2 fishhooks each, and 1 had 5 fish hooks), and 1 fishhook in the distal portion of the esophagus with a second fish hook in the stomach. According to this study almost 50% of the fishhooks were found in the stomach, which does not correlate with our study when the location distribution is considered. The reason for this situation should be related to the local fishing habits in which a bait is used composed of multiple combination string hooks embedded in a piece of a bread pellet. After contacting with saliva, this pellet crumbles and the hooks release which set the stage for penetration to the esophageal mucosa. It was concluded that the fact that the number of fish hooks detected in the similar studies were much higher than those in our study was concealed in the baits that could be broken down by enzymatic digestion like fish.

There was no significant correlation between the number of hooks and their location between retrieval time but generally fish hooks that were imbedded and with entangled strings took longer to remove. The prognosis of ingested fish hooks may be better than other foreign body ingestions if treated expertly because the mucosal damage cannot be greater than the diameter of the needle in uncomplicated cases. That being said, the hooks should not be retrieved on the opposite direction of their barbs, if they are pulled like that, serious mucosal damage is unavoidable. If the fish hook pierced the mucosa or deeper into the muscle, maneuvering to remove the hook with endoscopy mostly end in failure or severe lacerations. While attempting to remove deeply lodged fish hooks, pushing the hook forward instead of pulling it back may cause less damage to the mucosa because of their shape. Using this maneuver for removal of the penetrated hooks did not complicate or cause any significant mucosal damage in any case of this study.

In conclusion, decisive and early treatment can decrease the morbidity of multiple hook ingestions. Endoscopic retrieval of fish hooks located in the esophagus is preferred because it has fewer complications than surgery. However, the main reason should not be discounted, with proper

education of the fishermen and pet owners about this subject, these incidents can be avoided entirely.

REFERENCES

- Rousseau A, Prittie J, Broussard JD, Fox PR, Hoskinson J:** Incidence and characterization of esophagitis following esophageal foreign body removal in dogs: 60 cases (1999-2003). *J Vet Emerg Crit Care*, 17 (2): 159-163, 2007. DOI: 10.1111/j.1476-4431.2007.00227.x
- Spielman B, Shaker E, Garvey M:** Esophageal foreign body in dogs: A retrospective study of 23 cases. *J Am Anim Hosp Assoc*, 28 (6): 570-574, 1992.
- Thompson HC, Cortes Y, Gannon K, Bailey D, Freer S:** Esophageal foreign bodies in dogs: 34 cases (2004-2009). *J Vet Emerg Crit Care*, 22 (2): 253-261, 2012. DOI: 10.1111/j.1476-4431.2011.00700.x
- Luthi C, Neiger R:** Esophageal foreign bodies in dogs: 51 cases (1992-1997). *Eur J Comp Gastroenterol*, 3, 7-11, 1998.
- Michels G, Jones B, Huss B, Wagner-Mann C:** Endoscopic and surgical retrieval of fishhooks from the stomach and esophagus in dogs and cats: 75 cases (1977-1993). *J Am Vet Med Assoc*, 207 (9): 1194-1197, 1995.
- Sale CSH, Williams JM:** Results of transthoracic esophagotomy retrieval of esophageal foreign body obstructions in dogs: 14 cases (2000-2004). *J Am Anim Hosp Assoc*, 42 (6): 450-456, 2006. DOI: 10.5326/0420450
- Teh H, Winters L, James F, Irwin P, Beck C, Mansfield C:** Medical management of esophageal perforation secondary to esophageal foreign bodies in 5 dogs. *J Vet Emerg Crit Care*, 28 (5): 464-468, 2018. DOI: 10.1111/vec.12757
- Gianella P, Pfammatter NS, Burgener IA:** Oesophageal and gastric endoscopic foreign body removal: Complications and follow-up of 102 dogs. *J Small Anim Pract*, 50 (12): 649-654, 2009. DOI: 10.1111/j.1748-5827.2009.00845.x
- King J:** Esophageal foreign body and aortic perforation in a dog. *Vet Med*, 96 (11): 828-829, 2001.
- Cohn LA, Stoll MR, Branson KR, Roudabush AD, Kerl ME, Langdon PF, Johannes CM:** Fatal hemothorax following management of an esophageal foreign body. *J Am Anim Hosp Assoc*, 39 (3): 251-256, 2003. DOI: 10.5326/0390251
- Doran IP, Wright CA, Moore AH:** Acute oropharyngeal and esophageal stick injury in forty-one dogs. *Vet Surg*, 37 (8): 781-785, 2008. DOI: 10.1111/j.1532-950X.2008.00448.x
- Binvel M, Poujol L, Peyron C, Dunie-Merigot A, Bernardin F:** Endoscopic and surgical removal of oesophageal and gastric fishhook foreign bodies in 33 animals. *J Small Anim Pract*, 59 (1): 45-49, 2018. DOI: 10.1111/jsap.12794
- Savary M, Miller G:** The Esophagus: Handbook and Atlas of Endoscopy. 248, Gassmann, Switzerland, 1978.
- Tams TR:** Endoscopy and laparoscopy in veterinary gastroenterology. In, Tams TR (Ed): Handbook of Small Animal Gastroenterology. 2nd ed., 97-117, Elsevier, Philadelphia, 2003.
- Dunlap AE, Risselada M:** Caudal mediastinal fish hook foreign body with pulmonary artery penetration in two dogs. *J Am Anim Hosp Assoc*, 55 (1): e551-01, 2019. DOI: 10.5326/jaaha-ms-6787
- Boyd C, Claus M, Hosgood G, Smart L:** Survival of two dogs with pyothorax secondary to perforating oesophageal foreign body. *Aust Vet J*, 95 (1-2): 41-45, 2017. DOI: 10.1111/avj.12548
- Burton AG, Talbot CT, Kent MS:** Risk factors for death in dogs treated for esophageal foreign body obstruction: A retrospective cohort study of 222 cases (1998-2017). *J Vet Intern Med*, 31 (6): 1686-1690, 2017. DOI: 10.1111/jvim.14849
- Sterman AA, Mankin KMT, Ham KM, Cook AK:** Likelihood and outcome of esophageal perforation secondary to esophageal foreign body in dogs. *J Am Vet Med Assoc*, 253 (8): 1053-1056, 2018. DOI: 10.2460/javma.253.8.1053