

Diagnosis of Multiple Congenital Cardiac Defects in a Newborn Calf

Meriç KOCATÜRK ^{1,a}✍ Volkan YAZICIOĞLU ^{2,b} Hakan SALCI ^{3,c} Ersoy BAYDAR ^{4,d} Zeki YILMAZ ^{1,e}

¹ Bursa Uludağ University, Faculty of Veterinary Medicine, Animal Teaching Hospital, Department of Internal Medicine, TR-16059 Bursa - TURKEY

² Bursa Uludağ University, Faculty of Medicine, Cardiovascular Surgery Department, TR-16059 Bursa - TURKEY

³ Bursa Uludağ University, Faculty of Veterinary Medicine, Animal Teaching Hospital, Department of Surgery, TR-16059 Bursa - TURKEY

⁴ Balıkesir University, Faculty of Veterinary Medicine, Animal Teaching Hospital, Department of Internal Medicine, TR-10100 Balıkesir - TURKEY

^a ORCID: 0000-0002-2849-1222; ^b ORCID: 0000-0001-5693-4978; ^c ORCID: 0000-0001-6548-8754; ^d ORCID: 0000-0002-2565-1796

^e ORCID: 0000-0001-9836-0749

Article ID: KVFD-2019-21761 Received: 15.01.2019 Accepted: 15.06.2019 Published Online: 19.06.2019

How to Cite This Article

Kocatürk M, Yazıcıoğlu V, Salcı H, Baydar E, Yılmaz Z: Diagnosis of multiple congenital cardiac defects in a newborn calf. *Kafkas Univ Vet Fak Derg*, 25 (6): 879-882, 2019. DOI: 10.9775/kvfd.2019.21761

Abstract

This case report presents the clinical diagnostic work-up and surgical approach via cardiopulmonary by-pass technique in 15 day-old, male, Simmental calf with multiple cardiac defects. Calf suffered from respiratory stress and poor growth. Cardiac auscultation revealed a loud pansystolic murmur with cardiac trill of both transthoracic area of the heart. Cardiomegaly and pulmonary artery bulge (x-ray) and atrial fibrillation were observed. Color Doppler transthoracic echocardiography revealed musculomembranous ventricular septal defect (VSD), atrial septal defect (ASD) and patent ductus arteriosus (PDA) with left to right shunt. Routine hematological and serum biochemistry profiles were non-specific. Calf underwent to lateral thoracotomy for surgical correction of multiple cardiac defects. During the cardiopulmonary by-pass, calf was dead due to hemodynamic imbalances and ventricular fibrillation. Necropsy confirmed the presence of multiple cardiac defects in this case.

Keywords: Calf, Multiple cardiac defect, Echocardiography, Cardiopulmonary by-pass

Yenidoğan Bir Buzağıda Çoklu Kongenital Kardiyak Defektlerin Tanısı

Öz

Bu olguda çoklu kalp defekti olan 15 günlük, erkek Simmental buzağıya diyagnostik yaklaşım planı ve olguya kardiyopulmoner by-pass tekniği ile cerrahi yaklaşımın sonuçları sunulmuştur. Buzağı solunum stresi ve büyüme geriliği şikayeti getirildi. Kardiyak oskültasyonda kalbin her iki transtorasik alanında titreşimle beraber yüksek pansistolik üfürüm belirlendi. Ayrıca kardiyomegali, pulmoner arter dolgunluğu (röntgen) ve atriyal fibrilasyon gözlemlendi. Renkli Doppler transtorasik ekokardiografide muskulomembranöz ventriküler septal defekt (VSD), atriyal septal defekt (ASD) ve soldan sağa şant ile beraber patent duktus arteriozus (PDA) tespit edildi. Rutin hematolojik ve serum biyokimyasal profiller nonspesifikti. Buzağıda çoklu kardiyak defektlerin cerrahi yolla düzeltilmesi için lateral torakotomi yapıldı. Kardiyopulmoner by-pass sırasında, buzağı hemodinamik dengesizlikler ve ventriküler fibrilasyon nedeni ile hayatını kaybetti. Nekropside çoklu kardiyak defekt varlığının ortaya konuldu.

Anahtar sözcükler: Buzağı, Çoklu kalp defekti, Ekokardiografi, Kardiyopulmoner by-pass

INTRODUCTION

Congenital cardiac malformations have been reported rarely in calves. Ventricular septal defect (VSD), a more common congenital heart disease among calves can be seen either alone or in combination with more complex abnormalities such as atrial septal defect (ASD) and patent ductus arteriosus (PDA) ^[1,2].

In physical examination, cyanosis of the mucous membranes and a loud systolic heart murmur are important to be suspected for congenital cardiac defect in neonatal calves ^[3,4]. In these cases, thoracic x-ray may present cardiac chamber dilations (cardiomegaly) and pulmonary edema. Based on these clinical findings, it could be possible to suspect the presence of cardiac defect(s), however echocardiography is still the most reliable diagnostic tool to confirm or rule



İletişim (Correspondence)



+90 224 2940817



merick@uludag.edu.tr

out the preliminary diagnosis. Congenital cardiac defects can lead to poor growth, un-responded to medical therapy and sudden death (economical losses). Early diagnosis of the cardiac defects can improve the disadvantages by removing from breeding and unnecessary usage of antibiotics or etc. Medical therapy can transiently improve the clinical signs such as respiratory distress and exercise intolerance, whereas surgical correction of cardiac defect has been considered for definitive solution. There are limited case reports on multiple cardiac defects and their surgical correction in calves. Thus, this paper is a report on diagnostic and surgical approaches in a Simmental calf with a combination of congenital cardiac defects (ASD, VSD and PDA).

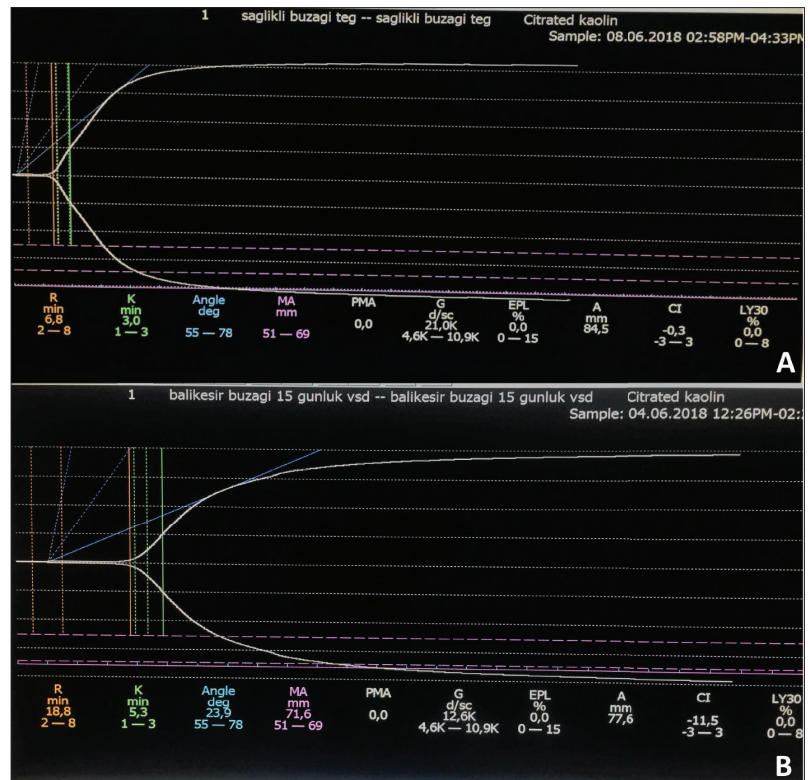
CASE HISTORY

A 15 day-old Simmental calf was presented to Animal Teaching Hospital of Faculty of Veterinary, Balikesir University with the complaint of respiratory stress, exercise intolerance, dyspnea and poor growth. After the diagnostic work-up, a PDA was suspected, and to be able to confirm the diagnosis, patient was referred to cardiology clinic of Animal Teaching Hospital of Faculty of Veterinary, Bursa Uludağ University. Clinical examination revealed cyanosis of mucous membranes, a loud gallop cardiac rhythm and pulse deficit. Cardiac auscultation revealed a grade-5 pansystolic murmur with cardiac trill of both trans-thoracic area of the heart. Complete blood cell count was within reference ranges, except a mild neutrophilia ($7.38 \times 10^9/L$, reference range: $0.6-6.7 \times 10^9/L$). Biochemical

profile (VetScan® Large Animal Profile, 10 parameters, Abaxis) was unremarkable. Coagulation status was evaluated by use of thrombo-elastography (TEG® 5000 Hemostasis System, USA). Of TEG, reaction time (R time: 18.8 min) and kinetic time (K time: 5.3 min) prolonged, compared to healthy control (Fig. 1).

Electrocardiographic evaluation (base apex leads) showed atrial fibrillation. Increased heart size and cardiac globalization, dorsal deviation of trachea, diffuse pulmonary edema in caudal lung lobes were detected on left lateral and ventro-dorsal thoracic radiographies (Fig. 2). After restraining lateral recumbence, phased array medium frequency echocardiography probe (3-5 mHz) was used (Esaote, Caris Plus, Italy) for the final diagnosis of case as mentioned previously [5]. Standard echocardiographic techniques were used for measurements (Table 1). Coupling gel applied on hair clipped area between the fourth and fifth intercostal spaces behind the olecranon. On right parasternal long axis and left apical 5 chamber views showed the presence of inlet VSD that was detected just below the aortic valve between two ventricles. A passage with strong left to right sided turbulence flow (Vmax: 1.54 m/s) was visualized in color flow Doppler of the left parasternal long axis view of the abnormal passage between ventricles (Fig. 3). An agitated saline contrast (bubble) study was performed right before injection by moving it rapidly back and forth between the 2 syringes that were connected to the 3-way stopcock. Positive echo contrast was seen 5 to 10 s after intravenous injection of mixture. The contrast of the air-saline mixture was visible as hyperechoic content

Fig 1. TEG evaluation of the calf (B) shows prolongation in Reaction time (R: 18.8 min) and Kinetic value (K: 5.3 min) compared to healthy control (A)



respectively in right atrium (RA), right ventricle (RV) and left ventricle (LV) that proved the abnormal passage between both atriums and ventricles respectively. Color flow Doppler examination showed a turbulent flow and low frequency regurgitant jet (Vmax: 1.11 m/s) and high pulmonary artery flow velocity (Vmax: 2.19 m/s) relating with PDA, a connection between ascending aortic root (Ao) and PA. VSD to Ao diameter ratio was 0.74 and PA to Ao ratio was 0.9 on right parasternal short and long axis views.

Surgery of cardiopulmonary by-pass was decided, and until

Table 1. Some echocardiographic parameters of the calf evaluated

Echocardiographic Parameters	Case	Reference Value	References
LVDd (cm)	7.50	4.15±0.12	[5]
RVDd (cm)	1.98	1.34±0.05	[5]
FS (%)	35	36.9±1.6	[5]
Ao (cm)	2.86	2.65±0.08	[5]
LA (cm)	6.35	2.12±0.05	[5]
LA/Ao	0.9	0.81±0.3	[5]
PA (cm)	3.11	F	-
PA/Ao	1.01	<1.0	[6]
PA V max (m/s)	2.19	F	-
Ao V max (m/s)	1.67	F	-
Kg	34.7	33.9±1.7	[5]
Age (days)	15	18.18±2.5	[5]

LVDd: left ventricular diastole diameter, **RVDd:** right ventricular diastole diameter, **EF:** ejection fraction, **FS:** fractional shortening, **Ao:** aorta, **LA:** left atrium, **RA:** right atrium, **PA:** pulmonary artery. **F** Reference value could not be found

the operation calf was treated with diuretic (furosemide, 2 mg/kg, im, 2x1, for 5 days) to reduce pulmonary edema and cardiac volume overload. After that, calf underwent right lateral thoracotomy to correct and repair multiple cardiac defects. Preoperatively, atropine sulphate (0.01 mg/kg sc) and xylazine HCl (0.01 mg/kg im) were injected respectively. Ketamine HCl (4 mg/kg, im) was administered for general anesthesia and to facilitate the orotracheal intubation. After intubation, isoflurane was inhaled during surgery using 2% concentration of oxygen. Respiration was assisted by mechanical ventilation (Anesthesia Ventilator 900 Series, AMS 200 Anesthesia Workstation, AMS Ltd. Şti., Ankara, Turkey). Patient was closely monitorized (Datex-Ohmeda Cardioscap/5, GE Healthcare, Helsinki, Finland) and all vital parameters were controlled and peripheral arterial (left femoral artery) and central venous pressures (left jugular vein) were checked and recorded at 15 min intervals during surgery. Urinary output was also controlled following urethral catheterization.

Following the routine right 4th intercostal thoracotomy, peripheral cannulations were completed from right jugular vein, right femoral artery and caudal vena cava. After clamping of aorta, cranial and caudal vena cava, anti-coagulant (Clexane®, 6000 IU/0.6 mL Anti-XA, Sanofi Aventis) was administered to circulation and cardiopulmonary by-pass was started. Cardioplegia solution (Cardioplegia Solution A, Baxter Healthcare Ltd) was applied through the aorta to stop the cardiac manners. And then atrial and ventricular septal defects were observed following to right atriotomy and incision of tricuspidal septal annulus. Defects of atrial and ventricular septums were repaired by pericardial patches, and right atrial incision was sutured

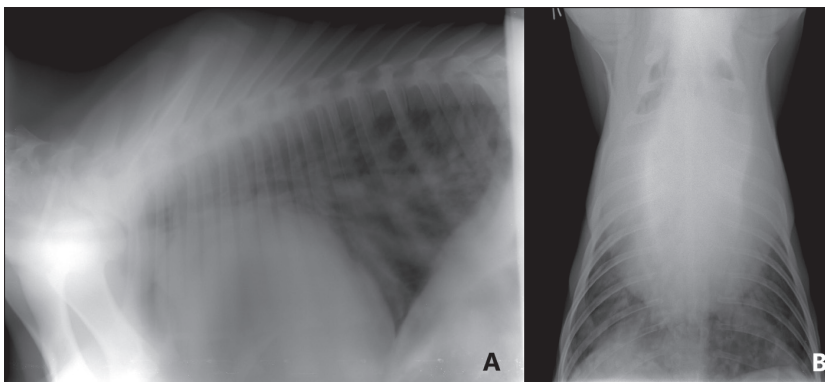
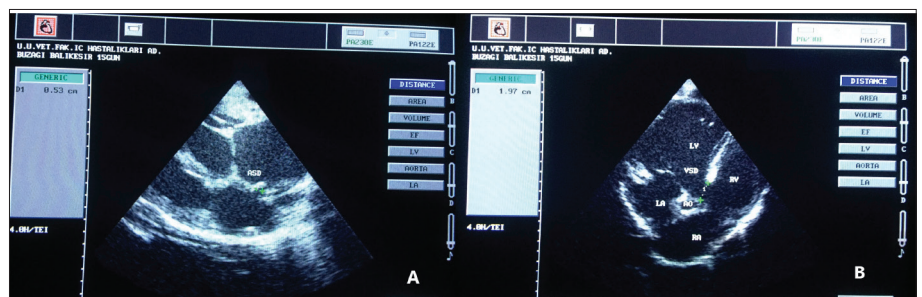


Fig 2. Increased heart size and cardiac globalization, dorsal deviation of trachea, diffuse pulmonary edema in caudal lung lobes on lateral (A) and ventrodorsal (B) x-ray of the thorax

Fig 3. Passages between atriums (A) and ventricles (B) on echocardiographic view of the heart. **VSD:** ventricular septal defect, **ASD:** atrial septal defect, **LA:** left atrium, **RA:** right atrium, **LV:** left ventricle, **RV:** right ventricle, **Ao:** Aorta



routinely. At that time, before right thoracotomy incision, the blood in the cardiopulmonary by-pass pump was re-loaded the circulation system, and cardiac pulsations were attempted. Pace was applied on the myocardium to constitute the normal cardiac rhythm; however, unresponsive atrial fibrillation formed, and the calf was dead despite having medical and intracardiac defibrillations which turned itself to ventricular fibrillation (VF). Necropsy showed the presence of PDA on the left side of the heart as well as ASD and VSD in this case.

DISCUSSION

Congenital cardiac defects such as ASD and membranous VSD and their relation with breed and sex predispositions were reported previously in calves [1-4,6-9], but the diagnostic steps and cardiopulmonary by-pass procedures of a combination of three congenital cardiac defects (ASD, VSD and PDA) in newborn calves has not been reported yet.

In this case, clinical (tachypnea, cyanosis and cardiac murmur), electrocardiographic (atrial fibrillation) and thoracic x-ray findings (cardiomegaly and pulmonary edema) were suggestive of congenital cardiac defect(s). Transthoracic echocardiography was performed as a gold standard for definitive diagnosis. VSD to Ao diameter ratio (0.74) was greater than 0.6 suggestive for large, unrestrictive VSD [8].

Several views of the main PA from both the right and left imaging windows have taken [5]. Decreased cardiac output that was characterized by low FS value (Table 1) due to overt cardiac size and diuretic usage to clear pulmonary edema before the evaluation of the calf might decrease the velocity of pulmonary artery; therefore there was not a serious turbulence (presence of low frequency regurgitant flow) in pulmonary trunk. It seems that volume and pressure change in RV resulted with right-sided heart failure and pulmonary hypertension in short life span of our patient. Due to low frequency pulmonary artery regurgitant flow, Eisenmenger's syndrome was not present in this case, in which a long-term left-to-right cardiac shunt caused by a congenital heart defect (VSD, ASD and/or PDA) changes to a cyanotic right-to-left shunt with pulmonary hypertension [3]. In this case, PA to Ao ratio (0.9) and peak pulmonary artery flow velocity (2.19 m/s) were not compatible with the presence of pulmonary hypertension [6].

The patient was treated with diuretic to improve clinical signs by decreasing pulmonary edema and cardiac volume overload for 5 days, before the cardiac surgery. In that period, coagulation status of calf was evaluated by thromboelastography (TEG) which could provide useful information of global platelet function and coagulation cascade [10]. In our case, mild hypocoagulable state was observed due to prolongation of R time (the time from the test start until the start of clot or fibrin formation) and K time (speed of the band formation between fibrin and platelets). This observation showed that coagulation status could be

changed by multiple congenital cardiac defects in calves, as reported in neonatal calves with endotoxemia [11,12].

Calf was dead during the cardiopulmonary by-pass due to AF and then VF that was un-responsive to medical therapy. AF is also one of the intra and postoperative arrhythmia causing mortality in human medicine [13]. It seems that another possible reason of death was prolonged mechanical ventilation process in our case.

In conclusion, a calf with multiple congenital cardiac defects (ASD, VSD and PDA) underwent to surgical correction via cardiopulmonary by-pass has been reported. By this case report, diagnostic evaluation steps of the calf with multiple congenital cardiac defects, operation possibilities and disadvantages of the procedure were reported briefly.

ACKNOWLEDGEMENTS

We kindly thank Perfussionist M. Hadi Çağlayan from Cardiovascular and Thoracic Surgery Department-Bursa Uludağ University for his technical support.

REFERENCES

1. van Nie CJ: Congenital malformations of the heart in cattle and swine. A survey of a collection. *Acta Morphol Neerl Scand*, 6, 387-893, 1966.
2. Hagio M, Murakami T, Otsuka H: Two-dimensional echocardiographic diagnosis of bovine congenital heart disease: Echocardiographic and anatomic correlations. *Nihon Juigaku Zasshi*, 49 (5): 883-894, 1987. DOI: 10.1292/jvms1939.49.883
3. Buczinski S, Fecteau G, DiFruscia R: Ventricular septal defects in cattle: A retrospective study of 25 cases. *Can Vet J*, 47, 246-252, 2006.
4. Sandusky GE, Smith CW: Congenital cardiac anomalies in calves. *Vet Rec*, 108, 163-165, 1981. DOI: 10.1136/vr.108.8.163
5. Boon J: Veterinary Echocardiography. 2nd ed., Wiley-Blackwell, UK, 2011.
6. Mitchell KJ, Schwarzwald CC: Echocardiography for the assessment of congenital heart defects in calves. *Vet Clin North Am Food Anim Pract*, 32, 37-54, 2016. DOI: 10.1016/j.cvfa.2015.09.002
7. Penrith ML, Bastianello SS, Petzer IM: Congenital cardiac defects in two closely related Jersey calves. *J S Afr Vet Assoc*, 65 (1): 31-35, 1994.
8. Demiraslan Y, Kadir A, Gürbüz İ, Özen H: Simental bir buzağıda görülen çoklu konjenital anomaliler. *Kafkas Univ Vet Fak Derg*, 20 (4): 629-632, 2014. DOI: 10.9775/kvfd.2014.10692
9. Halgür A, Halgür M, Özmen Ö: Congenital secundum atrial septal defect and membranous ventricular septal defect in a newborn Holstein-Friesian calf. *Turk J Vet Anim Sci*, 35, 365-368, 2011. DOI: 10.3906/vet-0907-121
10. Wiinberg B, Kristensen AT: Thromboelastography in veterinary medicine. *Semin Thromb Hemost*, 36, 747-756, 2010. DOI: 10.1055/s-0030-1265291
11. Gökçe G, Gökçe Hİ, Erdoğan HM, Güneş V, Çitil M: Investigation of the coagulation profile in calves with neonatal diarrhoea. *Turk J Vet Anim Sci*, 30, 223-227, 2006.
12. Borrelli A, Botto A, Maurella C, Falco S, Pagani E, Miniscalco B, Tarducci A, Bruno B: Thromboelastometric assessment of hemostasis in newborn Piemontese calves. *J Vet Diagn Invest*, 29 (3): 293-297, 2017. DOI: 10.1177/1040638716688044
13. Batra G, Ahlsson A, Lindahl B, Lindhagen L, Wickbom A, Oldgren J: Atrial fibrillation in patients undergoing coronary artery surgery is associated with adverse outcome. *Ups J Med Sci*, 124 (1): 70-77, 2019. DOI: 10.1080/03009734.2018.1504148