

The Effects of *Androctonus crassicauda* Venom on Pregnant Rats and Their Offsprings

Sule OZEL ^{1,a} Murside Ayse DEMIREL ^{2,b} Nilufer ERCAN GOKAY ^{1,c} Ozcan OZKAN ^{3,d}

¹ Department of Obstetrics and Gynecology, Zekai Tahir Burak Women's Health Education and Research Hospital, TR-06230 Ankara - TURKEY

² Gazi University, Faculty of Pharmacy, Department of Pharmacology, Laboratory Animals Care and Research Unit, TR-06330 Ankara - TURKEY

³ Çankırı Karatekin University, Faculty of Science, Department of Biology, TR-18100 Çankırı - TURKEY

^a ORCID: 0000-0001-8423-6907; ^b ORCID: 0000-0002-7082-8976; ^c ORCID: 0000-0001-9555-6025; ^d ORCID: 0000-0002-5216-8361

Article ID: KVFD-2019-21987 Received: 05.02.2019 Accepted: 02.06.2019 Published Online: 03.06.2019

How to Cite This Article

Ozel S, Demirel MA, Gokay N, Ozkan O: The effects of *Androctonus crassicauda* venom on pregnant rats and their offsprings. *Kafkas Univ Vet Fak Derg*, 25 (6): 835-840, 2019. DOI: 10.9775/kvfd.2018.21987

Abstract

Incidents of scorpion stings are common in Turkey. These cases can cause severe envenomation and so represent an important public health problem. In Turkey, the most venomous species are *Leiurus abduhbayrami* and *Androctonus crassicauda*. There has been no study on the effects of *A. crassicauda* stings on pregnant rats. Consequently, we investigated the effects of the scorpion venom on pregnant rats and their offspring. The supernatant of the *A. crassicauda* venom obtained after the venom extraction was dissolved in 7 mL of sterile saline before the experiment, in this way the injection volume was standardized as 1 mL/rat. Pregnant rats were randomly divided into two groups with six animals in each. *A. crassicauda* venom in 1 mL physiological saline solution (NaCl 0.9%) was subcutaneously injected in rats of the experimental group (EG), while sterile saline solution (1 mL) was subcutaneously administered to the rats of the control group (CG). All injections were applied to each group from the 7th to the 13th days of pregnancy, which correspond to the critical organogenesis period. Based on these results, it was shown that the scorpion venom affects the body weight of pregnant rats, the weights of placental tissues and fetuses in the rat model during pregnancy. *A. crassicauda* venom can induce abortion and cause restrictions in placenta and fetal growth. Therefore, medical professionals should be informed about possible adverse effects and risks in pregnancy.

Keywords: Scorpion, *Androctonus crassicauda*, Venom, Pregnancy, Fetal abnormalities

Androctonus crassicauda Zehirinin Gebe Siçanlar ve Yavruları Üzerine Etkileri

Öz

Akrep sokması vakaları Türkiye'de yaygın olarak görülmektedir. Bu olgular ciddi zehirlenmeye neden olarak önemli bir halk sağlığı sorununu oluşturur. Türkiye'de en zehirli akrep türlerinin *Leiurus abduhbayrami* ve *Androctonus crassicauda* olduğu bilinir. *A. crassicauda* sokmalarının gebeler üzerindeki etkileri konusunda bir çalışma yapılmamıştır. Bu nedenle, akrep zehirinin gebe siçanlar ve yavruları üzerindeki etkilerini araştırdık. Zehir ekstraksiyonundan sonra elde edilen *A. crassicauda* zehirinin süpernatantı, deneyden önce 7 mL fizyolojik tuzlu su (%0.9 NaCl) içinde eritildi, bu şekilde enjeksiyon hacmi, 1 mL/siçan olarak standart hale getirildi. Gebe siçanlar rastgele olarak her birinde altı hayvan bulunan iki gruba ayrıldı. 1 mL *A. crassicauda* zehiri, deney grubundaki siçanlara (EG) subkutan olarak uygulanırken, kontrol grubundaki siçanlara (CG) steril serum fizyolojik çözeltisi (1 mL) subkutan yolla verildi. Tüm enjeksiyonlar kritik organogenezis dönemine karşılık gelen gebeliğin 7. gününden 13. gününe kadar uygulandı. Bu sonuçlara dayanarak, akrep zehirinin gebelik sırasında siçan modelinde gebe siçanların vücut ağırlığını, plasental dokuların ve fetüslerin ağırlığını etkilediği gösterilmiştir. *A. crassicauda* zehri abortu uyandırabilir, plasenta ve fetal büyüme geriliğine neden olabilir. Bu nedenle, tıp uzmanları gebelikte olası olumsuz etkiler ve riskler hakkında bilgilendirilmelidir.

Anahtar sözcükler: Akrep, *Androctonus crassicauda*, Zehir, Gebe, Fetal anormaliteler

INTRODUCTION

Scorpions are terrestrial invertebrate animals classified as Arachnida whose existence dates back 430 million years to the Silurian era ^[1]. As a result, they can be considered

living fossils because morphologically they have changed so little ^[2]. In spite of developing medical approaches and other measures, in many tropical and subtropical countries scorpion envenomation cases still constitute a serious public health problem that can result in death, especially in



İletişim (Correspondence)



+90 376 2189537 Fax: +90 376 2189541



ozcanozkan@karatekin.edu.tr

children^[3]. Among scorpion species, *Androctonus crassicauda* is known as the deadly scorpion and so is of great concern to medicine^[4].

In addition to Turkey, the same scorpion can be found in Jordan, Syria, Iran, Iraq and Saudi Arabia and is medically important in these countries as well^[5]. In Turkey, *A. crassicauda* is the most significant scorpion species responsible for scorpion sting cases and for antivenom production. In addition, depending on the structure of the culture and socio-economic characteristics, many women work outdoors, particularly in the southeastern region of Turkey, thus the probability of scorpion stings increases among females. Indeed, many demographic reports in the country confirm that over 50% of scorpion sting cases occur in females^[5-7]. As a result, it should be remembered that pregnant women are potential victims.

Some studies have emphasized that the venom of the *A. amoreuxi*, *Tityus serrulatus* and *T. bahiensis* scorpion species can lead to congenital abnormalities and fetal resorption in pregnant animal models after injection. In addition, *Buthus minax* and *Leiurus quinquestriatus* scorpion venom has been shown to induce abortion in pregnant women. Scorpion stings in pregnant women can result in acute conditions such as vaginal bleeding, fetal loss, preterm delivery and placental and fetal abnormalities^[3,8-11].

Although the toxicity of *A. crassicauda* venom is well documented, there is little research about fetal effects on pregnancy. In Turkey, this is the first study specifically designed to determine if repetitive maternal exposure to *A. crassicauda* venom during organogenesis has deleterious effects on pregnant rats and their offspring in the fetal and obstetric outcome. Therefore, the aim of this work in the rat experimental model of pregnancy was to investigate the effects of *A. crassicauda* scorpion venom on pregnant rats and their offspring.

MATERIAL and METHODS

Scorpions and Venom Extraction

The scorpions were captured in Sanliurfa province in the southeastern region of Turkey and kept in plastic cages with free access to food and water. Venom was obtained from mature *A. crassicauda* scorpions by electrical stimulation of the telson as described by Ozkan and Filazi^[2]. The venom was diluted with sterile double distilled water and centrifuged at 15.000 rpm for 20 min at 4°C^[12]. Then, the supernatant was taken and stored at -20°C until use at Cankiri Karatekin University. The protein content of the venom was also determined according to the Bradford method^[13] before use.

Bioethics and Animals

The study was approved by the Experimental Animals Ethics Committee of Gazi University (G.Ü.ET-18.088). Furthermore,

all experimental procedures were conducted in accordance with the ethical guidelines of the Ethics Commission on Animal Use (CEUA) and the Guide for the Care and Use of Laboratory Animals of NIH. Adult female (n=12) and male (n=3) Wistar Albino rats weighing 200-250 g were used for experimental procedures. The animals were housed in polysulfone cages at 21-24°C, 40-45% humidity and under light-controlled conditions (12 h light/12 h dark) at the Laboratory Animals Breeding and Experimental Research Center, Faculty of Pharmacy, Gazi University. Tap water and commercial pellet food were available *ad libitum*.

Mating of Rats and Pregnancy Diagnosis

Following one week of acclimatization, female rats were allowed to mate with mature males (one male per four females) from 4.00 p.m. to 8.00 a.m. Pregnancy was determined by the presence of a vaginal plug (*Fig. 1A*), which showed evidence of mating, and then these females were diagnosed as pregnant^[14]. This was considered as pregnancy day 0. The pregnant rats were maintained in individual cages.

Experimental Design

The whole venom of the *A. crassicauda* scorpion was dissolved in 7 mL of physiological saline solution (PSS: NaCl 0.9%) solution and the injection volume was standardized as 1 mL/rat. The subcutaneous injection route in rats was chosen to mimic natural scorpion stings. The pregnant rats were randomly divided into two groups with six animals in each. The dose of 1 mL of the venom was subcutaneously injected in rats of the experimental group (EG), while the saline solution (1 mL) was subcutaneously administered to the rats of the control group (CG). All injections were applied to each group from the 7th to the 13th days of pregnancy^[15], which correspond to the critical organogenesis period^[16].

Maternal Effects

The female rats were determined for weight gain on 0, 7, 13 and 21 days of pregnancy, the weight gain in both groups were recorded. Also noted were symptoms of the venom injection such as erythema, local pain on the injection site, respiratory perturbation, lacrimation and salivation increase and possible pregnancy complications were recorded after each injection.

Termination of the Experimental Procedure

On the last day (21st) of pregnancy, surgery was aseptically performed on the animals under general anesthesia with xylazine hydrochloride 2% (10 mg/kg; XylazinBio®, Intermed, Ankara, Turkey) and ketamine hydrochloride 10% (100 mg/kg; KetasoI®, Interhas, Ankara, Turkey). The fetuses were removed and an ovariohysterectomy was performed^[15]. The uterine horns were cut immediately and the fetuses and their placenta were extracted and weighed to determine the effect of venom on reproductive

organs. Ovaries and uterine tissues of each rat were weighed by precision scale. In addition, they were carefully examined in terms of the gross morphological abnormal findings. The uterine tissues were reweighed after removal of the ovaries. The vitality of offspring removed from the uterus was confirmed with the existence of fetal movement after tactile massage. The numbers of dead and live newborns were recorded. For morphometric analysis, occipitonasal lengths, tail lengths and chest width of all offspring were measured using a micrometer. In addition, the offspring were examined for assessment of any dysmorphism.

Postoperative Treatment and Care

The rats were monitored daily by a veterinarian. The surgical site of each rat was treated with povidone-iodine twice daily. Furthermore, the survival time of the offspring was recorded until the end of weaning. Maternal rats were sacrificed for the next analysis at the end of the lactation period and their internal organs were removed.

Statistical Analysis

The data were evaluated using the SPSS 23.0 program. The results were expressed as mean \pm SD or percentage of total number. Mann Whitney U test was used to determine the significance of differences between groups and these were considered significant when $P \leq 0.05$.

RESULTS

Within a few minutes of each dose of *A. crassicauda* venom injection, systemic symptoms such as local pain and erythema at the injection site, tachypnea, deep dyspnea, increases in salivary, eye and nasal secretions and jumping, shaking and rigidity in hind limbs began and persisted for approximately 30 min and then the rats returned to their normal state within approximately two hours. There was a significant increase (Fig. 1) in the body weight of rats in the EG at the 7th day of pregnancy ($P < 0.05$). In all the measurements after the 10th day of pregnancy, the body weight of pregnant rats in the EG was significantly weaker than the CG ($P < 0.05$) (Table 1). Also, it was observed that the weights of fetuses and placental tissues in the EG were lower than in the CG ($P < 0.01$) (Table 2).

Eighty newborns were detected in rats of the CG and 67 in the EG. There was no fetus in the uterus of one rat in the EG and this rat was evaluated as if aborted (Fig. 1F). A significant decrease ($P < 0.01$) was detected between the newborn weight of venom-treated rats and the control group (Table 3). Although all newborns of venom-treated rats died within one hour of birth, there were no newborn deaths in the CG in this time period. A significant decrease ($P < 0.05$) was observed for occipitonasal and tail lengths and chest width in repetitively envenomed rats in comparison to control rats (Table 3).

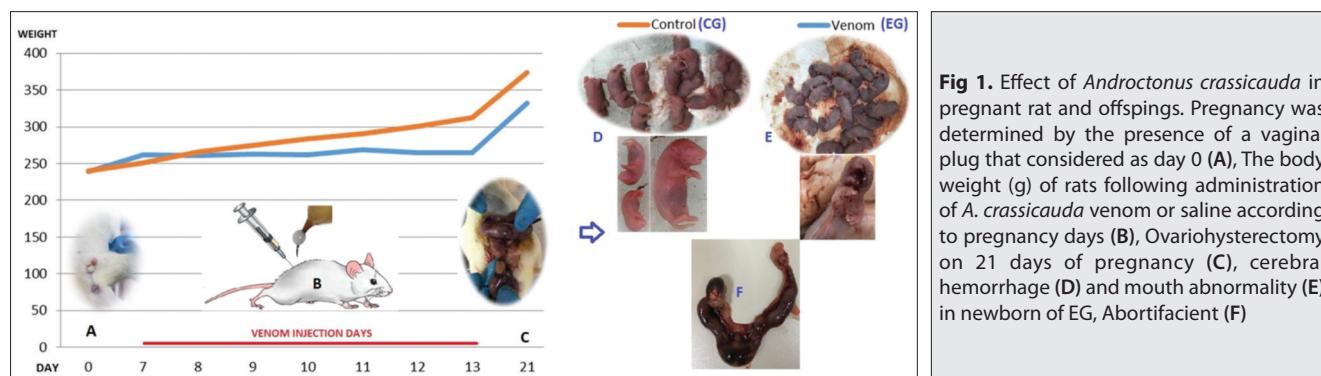


Fig 1. Effect of *Androctonus crassicauda* in pregnant rat and offsprings. Pregnancy was determined by the presence of a vaginal plug that considered as day 0 (A), The body weight (g) of rats following administration of *A. crassicauda* venom or saline according to pregnancy days (B), Ovariohysterectomy on 21 days of pregnancy (C), cerebral hemorrhage (D) and mouth abnormality (E) in newborn of EG, Abortifacient (F)

Table 1. Comparison of body weight (g) measurements of rats between groups

Pregnancy Days	CG (n=6)	EG (n=5*)	P
0	240.3 \pm 9.3	238.9 \pm 16.0	0.686
7 th	250.5 \pm 8.3	261.5 \pm 14.3	0.045
8 th	266.0 \pm 10.9	260.5 \pm 15.5	0.261
9 th	274.7 \pm 8.8	262.5 \pm 13.2	0.150
10 th	283.8 \pm 6.7	262.0 \pm 12.1	0.010
11 th	290.5 \pm 5.6	268.7 \pm 12.1	0.006
12 th	301.0 \pm 12.5	265.3 \pm 9.8	0.004
13 rd	312.5 \pm 17.2	264.4 \pm 12.3	0.004
21 st	374.0 \pm 14.0	332.5 \pm 41.7	0.030

Mean weight \pm SD * An abortion

Table 2. Comparing weight measurements (g) of internal genital organs with fetuses and placenta between control group and experimental groups

Parameters	CG (n=6)	EG (n=5)	P
Total weight of uterus, ovaries and fetuses	103.3±9.2	67.0±35.3	0.004
Total weight of uterus, ovaries and placenta	82.1±6.4	47.9±27.8	0.004
Weight of ovaries	0.89±0.18	0.83±0.08	0.194
Placental weight	0.83±0.28	0.54±0.08	0.004

Table 3. The evaluation of some morphometric parameters of offspring between groups

Parameters	Newborn Rats of CG (n=80)	Newborn Rats of EG (n=67)	P
Weight of newborn rats (g)	5.48±0.04	3.07±1.50	0.003
Occipitonasal - tail lengths (cm)	4.0±0.0	2.3±1.1	0.002
Chest width (cm)	2.0±0.0	0.7±0.3	0.002
Tail length (cm)	2.0±0.0	1.1±0.5	0.001
Cerebral hemorrhage-ratio (%)	0 (0%)	67/67 (100%)	0.001
Cleft lip-ratio (%)	0 (0%)	4/67 (5.97%)	0.019

When we examined the macroscopic findings of newborn rats, we observed cerebral hemorrhage macroscopically in all newborns of the EG and none in the CG, and the presence of this pathology was significantly different between the two groups. Also, we defined cleft lips in four newborns of venom-treated rats and none in the CG, and there were significant differences in comparisons between the groups ($P < 0.05$) (Table 3).

DISCUSSION

Scorpion envenomation remains a serious public health problem, especially in the Southeastern Anatolia region of Turkey. In 2008, Ozkan et al.^[17] reported 24.261 scorpion sting cases in Turkey, of which 22.6% occurred in Sanliurfa province. Pregnant women are among the possible victims given the high incidence of scorpion sting cases in Turkey. *A. crassicauda* is one of the most venomous scorpions in the world, and that includes Turkey^[4-7]. In this research, we chose repetitive doses of the venom because there have been reports of more than one scorpion sting of a pregnant woman in Turkey. As a result, the single scorpion venom was divided equally into seven portions one of which was injected daily together with 1 mL of saline solution.

In rats, blastocyst implantation in the uterus occurs between days four and five of pregnancy and then organogenesis continues until the 16th day and fetal development proceeds until birth^[14]. In addition, this is a critical stage during which, on the 10th day of pregnancy, the formation of several organs such as the eyes, brain and heart and aortic arches, axial skeleton, palate and urogenital system occur in the organogenesis period. Materials introduced during the organogenesis period may have teratogenic effects^[18]. In the assessment of maternal weight, the body weight of rats in the venom group decreased significantly

from days 7 to 13 of pregnancy when compared to the control. Contrary to this, Barao et al.^[19] reported a significantly greater weight increase from days 16 to 21 of pregnancy after the evaluation of maternal weight in rats injected with *T. serrulatus* scorpion venom on the 10th day of pregnancy.

Both human and experimental animal studies show that the venom of the scorpion induces alterations in the maternal reproductive system^[10,15,20,21]. In this sense, *L. quinquestriatus* scorpion venom increases the release of kinins that cause uterine contractions, and this effect caused abortions in rats^[21,22]. In addition to *B. occitanus* and *T. serrulatus*, other scorpion venoms had similar results^[8,23]. Another *A. amoreuxi* scorpion species caused fetal resorption, ossification defects and weight loss in survivor rats after the venom^[24]. Some studies on pregnant rats conducted with *T. serrulatus*, *T. bahiensis* and *T. discrepans* scorpion venom showed that single or repetitive injections on different days of pregnancy caused pregnancy losses without changes to maternal weight^[8-10]. In the present study, it was found that the weights of offspring, placenta and uterine and ovarian tissues decreased in the EG. In particular, it was thought that the reduced weight of placental tissues caused fetal growth retardation. The weights and morphometric parameters of all offspring decreased in the EG and they died within one hour following delivery. It is known that the placenta is a temporary endocrine organ that provides the relationship between offspring and uterine tissue. The various physiological functions of fetuses take place by means of the placenta^[16]. It has been suggested that the venom of *A. crassicauda* may cause damage to the placenta and fetal growth restriction.

In many previous clinical cases described by Langley^[25], Guler et al.^[26], Kamalak and Kosus^[27], Kaplanoglu and Helvacı^[28], Bozkurt et al.^[29], Sarı et al.^[30] and Ozturk and

Koca^[31], no adverse effect was reported in mothers or their fetuses after being stung by scorpion in different periods of pregnancy. Similarly, in a recent retrospective case series and literature review study, 24 pregnant women were admitted to the emergency department at Suruc (Sanliurfa) State Hospital due to scorpion stings and no important effects were reported on the fetus or the mother according to their medical records^[11]. On the other hand, Zengin et al.^[32] stated that a woman at 32 weeks of pregnancy developed lethargy and intense pelvic pain as the result of a scorpion sting. The patient was diagnosed with eclampsia as a complication of scorpion sting after medical examination. In addition, Duman et al.^[33] reported vaginal bleeding in a woman. Erdogan et al.^[34] reported that a pregnant woman stung by a scorpion developed an early membrane rupture and the newborn was followed up with the diagnosis of growth retardation, patent ductus arteriosus and bronchopulmonary dysplasia. Similarly, in a retrospective work of 14 years in Tunisia by Ben Nasr et al.^[15] although twenty pregnant women and their fetuses showed no complications, scorpion stings caused intense pelvic pain in two patients and vaginal bleeding in one. In another study, Ismail et al.^[24] noted abortion cases in pregnant woman following an *A. amoreuxi* scorpion sting. Finally, in India there are many reports of pregnant women who died because of the red scorpion sting^[35]. In the current study, rat dams of the EG survived during the experimental procedure. Eventhough in only one rat abortion was observed and none in the control group, it could refer to the venoms possible abortive effect.

In conclusion, no adverse effects were reported in mothers or their fetuses after being stung by a scorpion in some previous clinical pregnant cases in Turkey. On the other hand, the findings of the current study reveal that the venom of *A. crassicauda* can cause abortion as well as restrictions in placental and fetal growth. It has been shown that scorpion venom affects the development of offspring in the rat model during pregnancy. Therefore, medical professionals should be informed about possible adverse effects and risks in pregnancy. However, further studies are needed in this area to determine effects on the development of offspring.

CONFLICT OF INTERESTS

The authors explicitly state that there are no conflicts of interest in connection with this article.

REFERENCES

1. Senji Laxme RR, Suranse V, Sunagar K: Arthropod venoms: Biochemistry, ecology and evolution. *Toxicon*, 158, 84-103, 2019. DOI: 10.1016/j.toxicon.2018.11.433
2. Ozkan O, Filazi A: The determination of acute lethal dose-50 (LD₅₀) levels of venom in mice, obtained by different methods from scorpions, *Androctonus crassicauda* (Oliver 1807). *Turkiye Parazitoloj Derg*, 28 (1): 50-53, 2004.
3. Santos MS, Silva CG, Neto BS, Grangeiro Júnior CR, Lopes VH, Teixeira Júnior AG, Bezerra DA, Luna JV, Cordeiro JB, Júnior JG, Lima MA: Clinical and epidemiological aspects of scorpionism in the World: A systematic review. *Wilderness Environ Med*, 27 (4): 504-518, 2016. DOI: 10.1016/j.wem.2016.08.003
4. Abd El-Aziz FEA, El Shehaby DM, Elghazally SA, Hetta HF: Toxicological and epidemiological studies of scorpion sting cases and morphological characterization of scorpions (*Leiurus quinquestriatus* and *Androctonus crassicauda*) in Luxor, Egypt. *Toxicol Rep*, 6, 329-335, 2019. DOI: 10.1016/j.toxrep.2019.03.004
5. Ozkan O, Alcigir ME: A comparative pathomorphological findings between *Leiurus abdullahbayrami* and *Androctonus crassicauda* (Scorpion: Buthidae) envenomation in rabbit animal model. *J Arthropod Borne Dis*, 13 (1): 104-115, 2019. DOI: 10.18502/jad.v13i1.937
6. Al B, Yılmaz Arı D, Söğüt Ö, Orak M, Üstündağ M, Bokurt S: Epidemiological, clinical characteristics and outcome of scorpion envenomation in Batman, Turkey: An analysis of 120 cases. *JAEM*, 8 (3): 9-14, 2009.
7. Cesaretli Y, Ozkan O: Scorpion stings in Turkey: Epidemiological and clinical aspects between the years 1995 and 2004. *Rev Inst Med Trop Sao Paulo*, 52 (4): 215-220, 2010. DOI: 10.1590/S0036-46652010000400010
8. Mendonça M, Profeta Da Luz MM, Freire-Maia L, Cunha-Melo JR: Effect of scorpion toxin from *Tityus serrulatus* on the contraction of the isolated rat uterus. *Toxicon*, 33 (3): 355-361, 1995. DOI: 10.1016/0041-0101(94)00162-2
9. D'suze G, Moncada S, Gonzáles C, Sevcik C, Aguilar V, Alagón A: Relationship between plasmatic levels of various cytokines, tumour necrosis factor, enzymes, glucose and venom concentration following *Tityus* scorpion sting. *Toxicon*, 41, 367-375, 2003. DOI: 10.1016/S0041-0101(02)00331-8
10. Dorce ALC, Dorce VAC, Nencioni ALA: Effects of in utero exposure to *Tityus bahiensis* scorpion venom in adult rats. *Neurotoxicol Teratol*, 32 (2): 187-192, 2010. DOI: 10.1016/j.ntt.2009.11.002
11. Ates S, Karahan MA, Altay N, Akelci K, İkiz N, Guzel B, Ozer MW, Yılmaz HD: Approach to scorpion stings in pregnancy: A retrospective case series and literature review. *Taiwan J Obstet Gynecol*, 57, 692-695, 2018. DOI: 10.1016/j.tjog.2018.08.014
12. Özkan Ö, Çiftçi G, Karaer Z: Electrophoretical comparison of proteins of *Mesobuthus eupeus* and *Mesobuthus gibbosus* scorpion venoms. *Kafkas Univ Vet Fak Derg*, 17 (Suppl. A): S153-S158, 2011. DOI: 10.9775/kvfd.2011.4190
13. Bradford MM: A rapid and sensitive method for the quantitation of microgram quantities of protein utilizing the principle of protein-dye binding. *Anal Biochem*, 72 (1-2): 248-254, 1976. DOI: 10.1016/0003-2697(76)90527-3
14. Voipio HM, Nevalainen T: Improved method for vaginal plug detection in rats. *Scand J Lab Anim Sci*, 25 (1): 5-9, 1998.
15. Ben Nasr H, Hammami TS, Sahnoun Z, Rebai T, Bouaziz M, Kassis M, Zeghal KM: Scorpion envenomation symptoms in pregnant women. *J Venom Anim Toxins Incl Trop Dis*, 13 (1): 94-102, 2007. DOI: 10.1590/S1678-91992007000100007
16. Manson J, Kang YS: Test methods for assessing female reproductive and developmental toxicology. In, Hayes AW (Ed): Principles and Methods of Toxicology, 311-359. Raven Press, New York, 1989.
17. Ozkan O, Uzun R, Adıgüzel S, Cesaretli Y, Ertek M: Evaluation of scorpion sting incidence in Turkey. *J Venom Anim Toxins Incl Trop Dis*, 14, 128-140, 2008. DOI: 10.1590/S1678-91992008000100010
18. Dorce ALC, Dorce VAC, Nencioni ALA: Mild reproductive effects of the *Tityus bahiensis* scorpion venom in rats. *J Venom Anim Toxins Incl Trop Dis*, 20: 4, 2014. DOI: 10.1186/1678-9199-20-4
19. Barao ASS, Bellot RG, Dorce VAC: Developmental effects of *Tityus serrulatus* scorpion venom on the rat offspring. *Brain Res Bull*, 76, 499-504, 2008. DOI: 10.1016/j.brainresbull.2008.02.033
20. Cruttenden K, Nencioni ALA, Bernardi MM, Dorce VAC: Reproductive toxic effects of *Tityus serrulatus* scorpion venom in rats. *Reprod Toxicol*, 25 (4): 497-503, 2008. DOI: 10.1016/j.reprotox.2008.04.011

- 21. Osman OH, Ismail M, El-Asmar MF, Ibrahim SA:** Effect on the rat uterus of the venom from the scorpion *Leiurus quinquestriatus*. *Toxicon*, 10 (4): 363-366, 1972. DOI: 10.1016/0041-0101(72)90059-1
- 22. Marei ZA, Ibrahim SA:** Stimulation of rat uterus by venom from the scorpion *Leiurus quinquestriatus*. *Toxicon*, 17, 251-258, 1979. DOI: 10.1016/0041-0101(79)90215-0
- 23. Meki AMA, Nassar AY, Rochat H:** A bradykinin-potentiating peptide (peptide K12) isolated from the venom of Egyptian scorpion *Buthus occitanus*. *Peptides*, 16 (8): 1359-1365, 1995. DOI: 10.1016/0196-9781(95)02036-5
- 24. Ismail M, Ellison AC, Tilmisany AK:** Teratogenicity in the rat of the venom from the scorpion *Androctonus amoreuxi* (Aud. & Sav.) *Toxicon*, 21 (2): 177-189, 1983. DOI: 10.1016/0041-0101(83)90002-8
- 25. Langley RL:** A review of venomous animal bites and stings in pregnant patients. *Wilderness Environ Med*, 15 (3): 207-215, 2004. DOI: 10.1580/1080-6032(2004)15[207:AROVAB]2.0.CO;2
- 26. Guler A, Karadaş S, Kurdoglu Z:** Approach to scorpion stings during pregnancy: Two cases. *J Turk Soc Obstet Gynecol*, 8 (3): 205-208, 2001. DOI: 10.5505/tjod.2011.92259
- 27. Kamalak Z, Koşuş N:** Scorpion sting during pregnancy: A case report accompanied by literature. *Cumhuriyet Med J*, 35, 605-607, 2013. DOI: 10.7197/1305-0028.1888
- 28. Kaplanoglu M, Helvacı MR:** Scorpion stings in pregnant women: An analysis of 11 cases and review of literature. *Clin Exp Obstet Gynecol*, 42 (2): 228-230, 2015.
- 29. Bozkurt S, Okumus M, Utku B, Arıkan DC, Lok U, Duygu FB:** Scorpion sting in a pregnant woman: A case report. *Arch Clin Exp Surg*, 4 (2): 118-120, 2015.
- 30. Sarı Gökay S, Çelik T, Yılmaz HL, Kılıç R:** Scorpion sting in pregnancy. *J Pediatr Emerg Intens Care Med*, 2 (1): 41-44, 2015. DOI: 10.5505/cayb.2015.43153
- 31. Öztürk Ö, Koca E:** Scorpion sting in a pregnant women: A case report of three patients. *JAMER*, 2 (1): 1-8, 2017.
- 32. Zengin S, Al B, Oktay MM, Kilic H:** Scorpion sting: Eclampsia. *BMJ Case Rep*, 2012: bcr1220115401, 2012. DOI: 10.1136/bcr.12.2011.5401
- 33. Duman A, Daglı B, Akoz A, Avcil M, Orun S, Turkdogan KA:** Importance of antivenom in management of scorpion envenomation with epidemiologic and clinical characteristics. *Biomed Res*, 28 (8): 3763-3768, 2017.
- 34. Erdogan MN, Uguz M, Kaymak S:** Scorpion sting during pregnancy: Case report. *Türkiye Klinikleri J Case Rep*, 23 (1): 22-25, 2015. DOI: 10.5336/caserep.2013-34348
- 35. Kankonkar RC, Kulkurni DG, Hulikavi CB:** Preparation of a potent anti-scorpion-venom serum against the venom of red scorpion (*Buthus tamulus*). *J Postgrad Med*, 44 (4): 85-92, 1998.