

Efficacy of Topical *Curcuma longa* and *Nigella sativa* Combination for Feline Head and Neck Dermatitis: An Open Pilot Study

Kerem URAL ^{1,a} Mehmet GÜLTEKİN ^{1,b} Hasan ERDOĞAN ^{1,c}

¹ Adnan Menderes University, Veterinary Faculty, Internal Medicine, TR-09016, Aydın - TURKEY

^a ORCID: 0000-0003-1867-7143; ^b ORCID: 0000-0002-5197-2403; ^c ORCID: 0000-0001-5141-5108

Article Code: KVFD-2018-21260 Received: 25.10.2018 Accepted: 04.02.2019 Published Online: 04.02.2019

How to Cite This Article

Ural K, Gültekin M, Erdoğan H: Efficacy of topical *Curcuma longa* and *Nigella sativa* combination for feline head and neck dermatitis: An open pilot study. *Kafkas Univ Vet Fak Derg*, 25 (4): 517-522, 2019. DOI: 10.9775/kvfd.2018.21260

Abstract

Two medicinal plants, *Curcuma longa* (turmeric) and *Nigella sativa* (black cumin), have generated growing interest for their therapeutic anti-inflammatory action. We hypothesize that commercially available topical *C. longa* and *N. sativa* cream (Dermacumin cream®) will significantly decrease both the Feline Dermatitis Extent (FDE) and Severity Index (SI) and the pruritus scores after 3 weeks of twice-daily treatment of feline head and neck dermatitis. Ten client-owned cats with feline head and neck dermatitis which had received no previous treatment. FDE and SI scores gradually decreased on days 7 ($P<0.001$) and 28 ($P<0.0001$) compared to day 0. Similarly, decreased Visual Analog Scale (VAS) scores were detected on days 7 and 28 ($P<0.0001$). Cats receiving the herbal cream for 3 weeks all had significantly decreased FDE and SI scores, from 171.8 to 0 ($P<0.0001$), and VAS scores from 6.3 to 0 ($P<0.0001$). A positively elevated correlation ($r=0.62$, $P<0.001$) between FDE and SI and VAS scores for each case through evaluation period was revealed. The present study supports a potential benefit of topical herbal medicine against feline head and neck dermatitis.

Keywords: Black cumin, Curcumin, Dermatitis, Feline, Pruritus, Treatment

Kedi Baş ve Boyun Dermatitisi İçin Topikal *Curcuma longa* ve *Nigella sativa* Kombinasyonunun Etkinliği: Açık Pilot Çalışma

Öz

İki şifalı bitki, *Curcuma longa* (zerdeçal) ve *Nigella sativa* (çörek otu), terapötik anti-enflamatuar etkileri yüzünden giderek artan ölçüde ilgi çekmektedir. Sunulan çalışmada piyasada bulunan topikal *C. longa* ve *N. sativa* içeren krem (Dermacumin krem®), baş ve boyun dermatitli kedilerde günde iki kez tedavi edilmesinden 3 hafta sonra Feline Dermatitis Extent (FDE), Severity Index (SI) ve kaşıntı skorlarını önemli ölçüde azaltacağını varsayıyoruz. Bu amaçla daha önce tedavi görmemiş olan baş ve boyun dermatiti olan on sahipli kedi kullanıldı. FDE ve SI skorlarının 0. güne kıyasla 7. ($P<0.001$) ve 28. günde ($P<0.0001$) azaldığı belirlendi. Benzer şekilde, Görsel Analog Skala (GAS) skorlarındaki azalma 7 ve 28. günlerde ($P<0.0001$) saptandı. Bitkisel kremi 3 hafta boyunca alan kedilerin hepsinde FDE ve SI skorları anlamlı olarak azalmış, 171.8'den 0'a ($P<0.0001$) ve GAS skorları 6.3'den 0'a ($P<0.0001$) düşmüştür. Değerlendirme süresi boyunca her bir olgu için FDE/SI ve GAS skorları arasında pozitif olarak yüksek bir korelasyon ($r=0.62$, $P<0.001$) ortaya çıkarılmıştır. Bu çalışma, topikal bitkisel ilaçların kedilerin baş ve boyun dermatitine karşı potansiyel faydasını desteklemektedir.

Anahtar sözcükler: Çörek otu, Zerdeçal, Dermatitis, Feline, Kaşıntı, Tedavi

INTRODUCTION

Head/neck excoriations and pruritus in feline cases is due to papular and erythematous alterations existing on the face/neck related to alopecia, crusts, miliary dermatitis, seborrhea, and self-induced trauma ^[1]. Given the limited treatment options reported previously for feline allergic disease, it should not be unwise to state for the known facts, long-term risks of immunosuppressive treatment.

There is an unfulfilled demand for a reliable and effective anti-inflammatory and probably non-immunosuppressive treatment option for feline head and neck dermatitis (Fhnd). The purpose of the present open-label, non-controlled study was to elucidate the probable efficacy of a herbal cream containing *Curcuma longa* (*C. longa*; turmeric) and *Nigella sativa* (*N. sativa*; black cumin) in Fhnd. It was hypothesized that turmeric and black cumin might effectively mitigate inflammation in cats suffering



İletişim (Correspondence)



+90 256 2470700/6247 Fax: + 90 256 2470720



kural@adu.edu.tr

from Fhnd. It was further suggested that the combined anti-inflammatory effects of the latter compounds might account for the observed pruritus alleviation and relevant clinical signs.

MATERIAL and METHODS

Animals and Samples

The open-label, non-controlled study enrolled with written owner consent due to ethical guidelines of Adnan Menderes University HADYEK Committee (no: 64583101/2017/053) and compared to FEDESI and Vas pruritus scores with values on two subsequent re-evaluations at weeks 1 and 4.

Research Period/Inclusion Criteria

The present study was conducted at the Aydin Adnan Menderes University, Faculty of Veterinary, Department of Internal Medicine (n=6) and to private practices in İzmir (n=2) and Muğla (n=2) municipalities. A total of 10 cats with pruritic dermatoses (Fhnd) were initially analyzed for preliminary allergy background based on owner compliances, clinical findings, cytological and necessary dermatological examination involving hair plucking, deep skin scraping and acetate tape impression, and beside fungal cultures. Regular flea control by the referring veterinarians was evident in all cats. Prior to the current study, all cats were subjected to a food trial with hydrolyzed proteins (protection for food allergy) (n=7) or novel home cooked (n=3) for at least 8 weeks. No prior drug administration was evident, which was one of the inclusion criteria. Cats were excluded if bacterial or fungal infections (based on laboratory diagnostic); ectoparasites (based on, for example, a flea comb, cytology, dermatoscopy, or skin scraping); flea allergy; or metabolic or other non allergic disorders were diagnosed [2]. Flea control was previously available in all of the cats but was not continued throughout the study as none of the cats had flea allergic dermatitis. Rapid diagnostic ELISA test kits for antigens were used for excluding viral diseases. Complete blood count, serum biochemistry, and endocrine panels were available on days 0 and 28 for all cats involved.

Trial Protocol

The referring veterinary surgeons applied herbal cream (Dermacumin®, Veterinary Herbal Medicine; V.H.M., Antalya, TURKEY) twice daily (at least 2 pumps, similar to what has been described elsewhere) [3] for 3 weeks onto the affected lesions located on head and neck regions. The cream was apportioned in commercial bottles with a pump nozzle able to be used as a spray. The herbal cream included an equal combination of 90% pure *C. longa* and 85% pure *N.sativa*. Entire clinical evaluation were performed on days 0, 7, and 28 at the referring veterinary clinic. The Feline Dermatitis Extent and Severity Index (FeDESI) was used to

score the clinical findings involving excoriations/erosions, erythema and self-induced alopecia (presented as self-induced depilation resulting from excessive grooming and licking) [4]. The owners assessed pruritus (defined as scratching) via a 10 cm visual analog scale (VAS) involving signifier [5] similar to another study [3]. The owners were asked to complete a questionnaire for the number of treatment applications, side effects, or other necessary information.

Data Interpretation

Feline Dermatitis Extent and Severity Index and VAS pruritus scores on days 7 and 28 were compared to day 0 for the assessment of therapeutic efficacy. The distribution of data was analyzed with the D'Agostino and Pearson normality test. Friedman's test with Dunn's post-hoc tests were the choice to analyze assess the differences among FeDESI scores. One-way repeated-measures ANOVA tests with Tukey post-hoc tests were performed to make interpretation of VAS pruritus scores. The correlation between FeDESI and VAS pruritus scores for each feline case during study period was assessed via Pearson's correlation test. Statistical software was used to analyze the data and present the results (Prism 6; Graphpad Inc., San Diego, CA, USA).

RESULTS

A total of 10 Fhnd case were involved. To those of cats enrolled 8 were domestic long hairs, 1 each a domestic short hair and a Scottish short hair. Regarding sex 3 were neutered males and the rest 7 were spayed females. At initial referral, the mean age was 3.1 years (SD 1.6 years), and the mean weight was 4.5 kg (SD 1.2 kg). None of the Fhnd cases were removed from the study or received antibiotic therapy.

Complete blood count and serum biochemistry (ALT, AST, urea, creatinine) were available on days 0 and 28 (completion of the study) for all cats involved in which abnormal values were not detected apart from leukocytosis evident in 2 cats. Endocrine panels involving plasma cortisol and total and free thyroxine values were checked for all cases, which determined reference ranges. Rapid diagnostic ELISA test kits gave negative results for feline immunodeficiency virus/feline leukemia and calicivirus antigens.

Post-hoc tests denoted that initial day (0) values were significantly elevated in contrast to scores at the end of weeks 1 and 4 (Fig. 1 and Fig. 2). Average FeDESI scores decreased from 171.8 to 0 (P<0.0001) with a significant difference in average VAS pruritus scores from 6.3 to 0 (P<0.0001) on days 0 to 28 respectively. As a brief explanation, two cats with Fhnd also had lesions in other body parts with a total score of 442 and 251 surprisingly, out of maximum FeDESI score of 165 for Fhnd (Fig. 1 and Fig. 2).

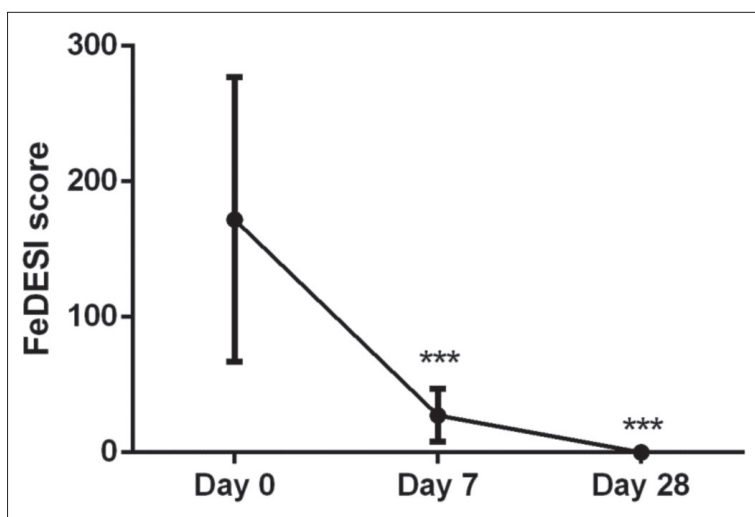


Fig 1. Changes in FeDESI score in cats treated with *Curcuma longa* and *Nigella sativa* (means \pm SD)

Fig 2. Changes in VAS pruritus score in cats treated with *Curcuma longa* and *Nigella sativa* (means \pm SD)

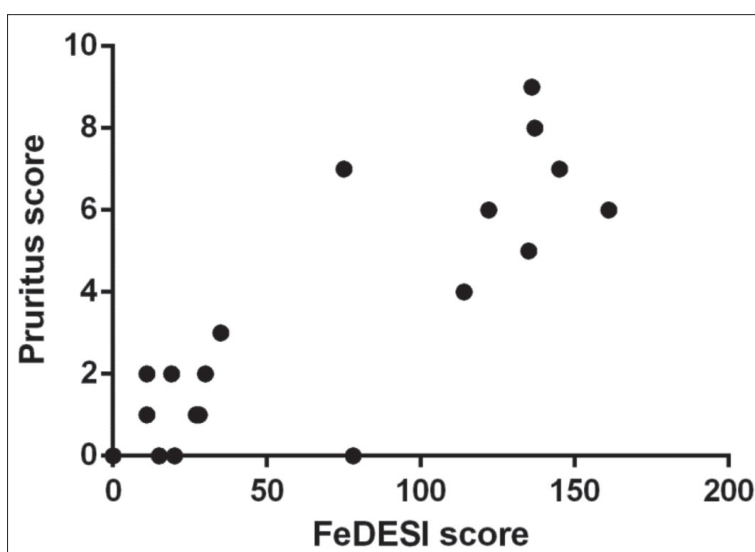
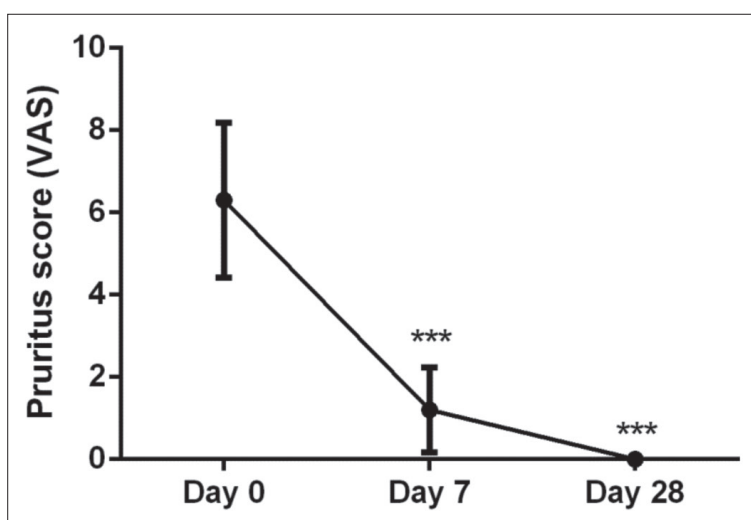


Fig 3. Correlation graph between the FeDESI score and VAS pruritus score for each cat at each time point

In addition, significant differences from days 7 to 28 were also evident, and all scores declined. Apart from lesional scores of each cat, it was evidenced that 9 out of 10 cats

were effectively in clinical recovery by day 7, and all were cured without side effects on day 28. It is surprising and interesting to observe that the cats' scores went down to 0.

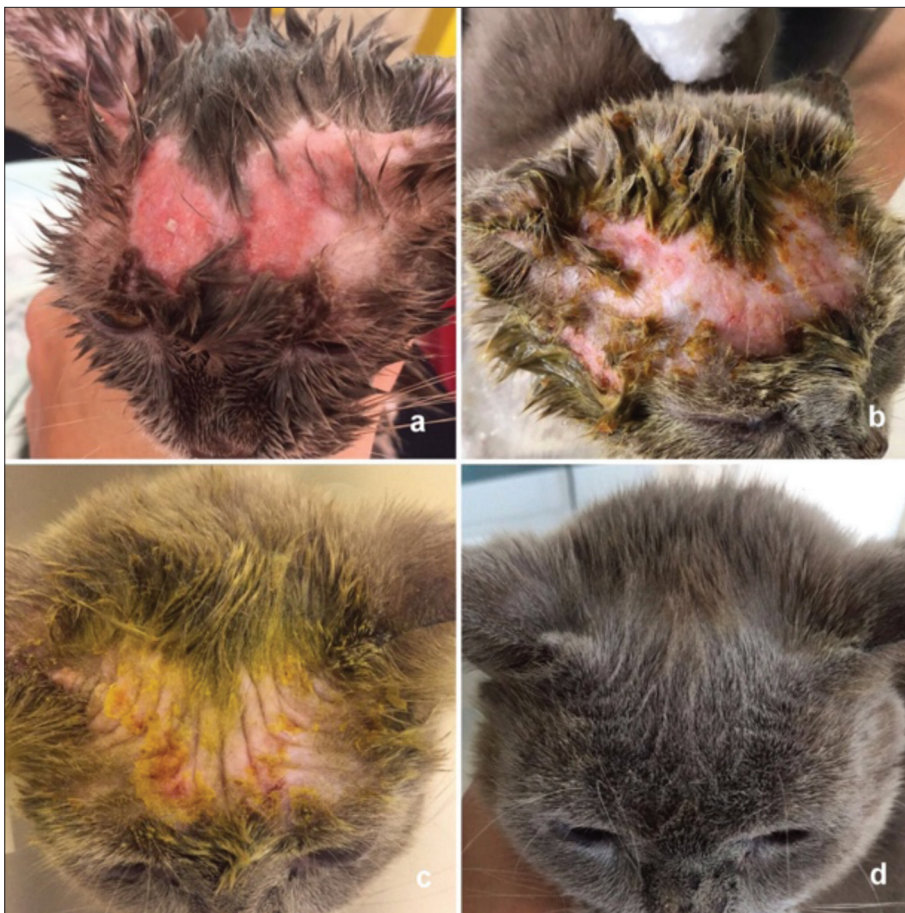


Fig 4. Feline head and neck dermatitis with erythema and alopecia respond to turmeric and black cumin cream treatment. a- Day 0, b- Day 3, c- Day 7, d- Day 28

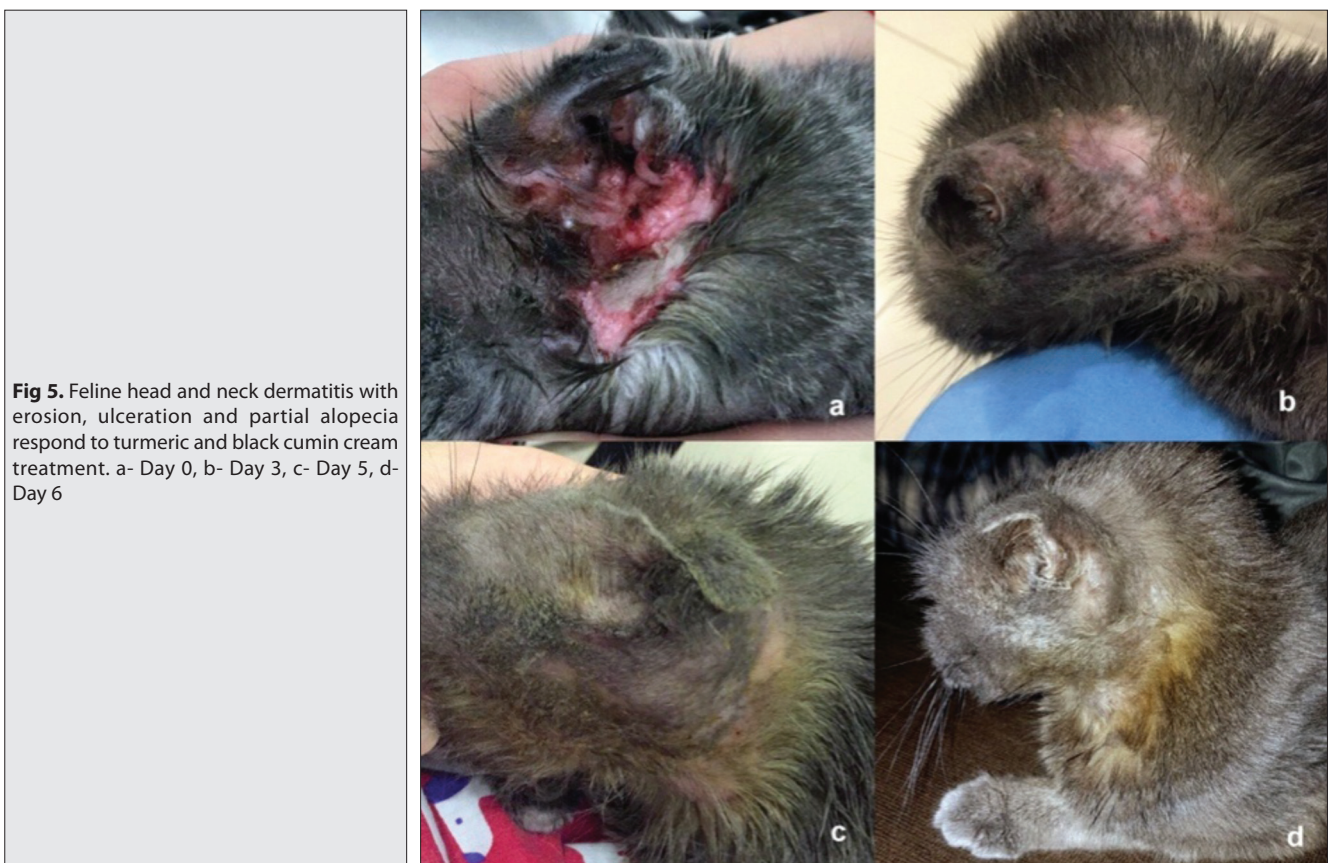

Fig 5. Feline head and neck dermatitis with erosion, ulceration and partial alopecia respond to turmeric and black cumin cream treatment. a- Day 0, b- Day 3, c- Day 5, d- Day 6

The correlation between FeDESI and VAS pruritus scores for every Fhnd cases at study duration were assessed via Pearson's correlation test, which revealed a high positive correlation ($r=0.62$, $P<0.001$; Fig. 3).

There was no side effects dedicated to the curcumin and black cumin treatment in any of the cases. The bitter taste of black cumin was over whelmed by vanilla extract included in the present compound, and food binders allowed the patients to lick the cream without adverse effect. Clinical photographs of a selected case were shown in Fig. 4 and Fig. 5 describing before and after treatment records.

DISCUSSION

The present study denoted that a topical administration of *C. longa* (turmeric) and *N. sativa* (black cumin) emerged to be a highly effective therapeutical option for Fhnd. There were significant alterations in both pruritus and clinical lesions, as detected by FeDESI. All Fhnd cases ($n=10$) presented decreased both FeDESI [on days 7 ($P<0.001$) and 28 ($P<0.0001$) compared to day 0; from 171.8 to 0 ($P<0.0001$)] and VAS pruritus scores [on days 7 and 28 ($P<0.0001$); from 6.3 to 0 ($P<0.0001$)] at the time point dedicated to a remarkable clinical recovery in this study. The FeDESI and pruritus scores were strikingly have correlation, indicating both that the herbal cream caused alterations among relevant clinical signs and that the augmentation was to the authors' knowledge, relevant to the efficacy, which might be due to turmeric's anti-allergic^[6] and anti-inflammatory^[7] effects and is probably due to suppression of IgE-mediated allergic reaction and activated mast cells, as reported previously in different models^[8]. For a better understanding, the efficacy of the present study's scoring systems should be discussed briefly in depth. In a prior investigation, 32 cats with allergic dermatitis and treated with cyclosporine were examined with both Scoring Feline Allergic Dermatitis (SCORFAD) and FeDESI prior to and after treatment. In that study, FeDESI and SCORFAD scores correlated well, whereas SCORFAD was less correlated with pruritus. According to the latter authors, FeDESI might be more suitable for use. Regarding allergic dermatitis in cats, SCORFAD might be used for assessing the severity of the disease^[2]. On the other hand, FeDESI, another scoring system for evaluating hypersensitivity, was found easier to complete than SCORFAD^[2] and was preferred as a global and intuitive scoring method in the present study. It may be briefly discussed that the assessment of pruritus in cats could not be easy. As was also reported and used in a prior study and adapted in the present study, the pruritus scale has been approved in dogs^[5] but not for cats.

Data regarding turmeric evidenced that this compound is highly pleiotropic, able to interact with different molecular targets participating in inflammation^[7,8]. Turmeric attenuates the inflammatory response by down regulating the activities of nitric oxide synthase, lipoxigenase, and

cyclooxygenase-2^[8]. On the other hand, black cumin might possess immune-stimulatory, anti-inflammatory^[9], and antiallergic^[10] effects. Turmeric and black cumin caused complete recovery and totally decreased pruritus scores in this study. This effect might be comparable with cyclosporine, resulted in well clinical achievement ½ portion to all cats involved in that researches^[11,12], or with hydrocortisone aceponate spray against allergic dermatitis in cats, where scores of initial day were momentarily superior to the scores at weeks 2, 4,6 and 8 ($P<0.0001$)^[3].

In the present study, the response to herbal cream therapy was accelerated, with the majority of the clinical recovery as evidenced by week 1. Clinical scores showed tendency to gradually boost there after in almost all of the cats. Available evidence suggested that this response was similar to that in feline allergic dermatitis, where 8 out of 10 cats achieved clinical remission by 28 days by use of a hydrocortisone aceponate spray^[3].

In addition to the important limitation of a lacking control group (non-controlled study due to ethical concerns and the design of the research, as this was a pilot study), a major flaw is the small sample size of the present study. As previous studies were not available to confirm the researchers' hypothesis that assessed the clinical response in Fhnd over a 3-week period of following local turmeric and black cumin treatment, the study was designed to confirm or reject this hypothesis before embarking on a larger, more expensive study. There was no adverse event detected in the present study. Longer studies are promptly needed to see the full effects and/or adverse effects of turmeric and black cumin.

In conclusion, this herbal cream bona fides well efficacy and toleration in 10 cats with head and neck dermatitis. This herbal product has been licensed in Turkey for usage in cats and dogs. Further studies are warranted to support the findings of this small-scale open-label pilot study.

REFERENCES

- Favrot C:** Feline non-flea induced hypersensitivity dermatitis: Clinical features, diagnosis and treatment. *J Feline Med Surg*, 15, 778-784, 2013. DOI: 10.1177/1098612X13500427
- Noli C, Cena T:** Comparison of FEDESI and SCORFAD scoring systems for the evaluation of skin lesions in allergic cats. *Vet Dermatol*, 26, 481-483, 2015. DOI: 10.1111/vde.12253
- Schmidt V, Buckley LM, Mcewan NA, Rème CA, Nuttall TJ:** Efficacy of a 0.0584% hydrocortisone aceponate spray in presumed feline allergic dermatitis: An open label pilot study. *Vet Dermatol*, 23, 11-16, 2012. DOI: 10.1111/j.1365-3164.2011.00993.x
- Nuttall TJ, Steen RV, Cawood MI, Houghton CA:** FC-49 feline dermatitis extent and severity index: A pilot study. *Vet Dermatol*, 15, 36, 2004. DOI: 10.1111/j.1365-3164.2004.411_49.x
- Hill PB, Lau P, Rybnicek J:** Development of an owner-assessed scale to measure the severity of pruritus in dogs. *Vet Dermatol*, 18, 301-308, 2007. DOI: 10.1111/j.1365-3164.2007.00616.x
- Suzuki M, Nakamura T, Iyoki S, Fujiwara, A, Watanabe Y, Mohri K, Isobe K, Ono K, Yano S:** Elucidation of anti-allergic activities of

curcumin-related compounds with a special reference to their anti-oxidative activities. *Biol Pharm Bull*, 28, 1438-1443, 2005. DOI: 10.1248/bpb.28.1438

7. Zhang N, Li H, Jia J, He M: Anti-inflammatory effect of curcumin on mast cell-mediated allergic responses in ovalbumin-induced allergic rhinitis mouse. *Cell Immunol*, 298, 88-95, 2015. DOI: 10.1016/j.cellimm.2015.09.010

8. Lee JH, Kim JW, Ko NY, Mun SH, Her E, Kim BK, Han JW, Lee HY, Beaven MA, Kim YM, Choi WS: Curcumin, a constituent of curry, suppresses IgE-mediated allergic response and mast cell activation at the level of Syk. *J Allergy Clin Immunol*, 121, 1225-1231, 2008. DOI: 10.1016/j.jaci.2007.12.1160

9. Dwarampudi LP, Palaniswamy D, Nithyanantham M, Raghu PS:

Antipsoriatic activity and cytotoxicity of ethanolic extract of *Nigella sativa* seeds. *Pharmacogn Mag*, 8, 268-272, 2012. DOI: 10.4103/0973-1296.103650

10. El Gazzar M, El Mezayen R, Marecki JC, Nicolls MR, Canastar A, Dreskin SC: Anti-inflammatory effect of thymoquinone in a mouse model of allergic lung inflammation. *Int Immunopharmacol*, 6, 1135-1142, 2006. DOI: 10.1016/j.intimp.2006.02.004

11. Noli C, Scarpella F: Prospective open pilot study on the use of ciclosporin for feline allergic skin disease. *J Small Anim Pract*, 47, 434-438, 2006. DOI: 10.1111/j.1748-5827.2006.00110.x

12. Vercelli A, Raviri G, Cornegliani L: The use of oral ciclosporin to treat feline dermatoses: A retrospective analysis of 23 cases. *Vet Dermatol*, 17, 201-206, 2006. DOI: 10.1111/j.1365-3164.2006.00514.x