

# The Efficacy of Conjunctiva Coverage in Combination with Amnion Liquid Supernatant Eye Drop on Deep Layer Corneal Ulcer in Canine Caused by Alkali Burn Combined with Mechanical Injury

Jiasan ZHENG<sup>1</sup> Renyue WEI<sup>1</sup> Jiaren ZHANG<sup>1</sup> Zheng WANG<sup>1</sup>  
Tingting ZHU<sup>1</sup> Hongri RUAN<sup>1</sup> Jun SONG<sup>1</sup>✉

<sup>1</sup>College of Animal Science and Veterinary Medicine, Heilongjiang Bayi Agricultural University, Daqing, 163319, CHINA

Article Code: KVFD-2018-21007 Received: 20.09.2018 Accepted: 30.12.2018 Published Online: 30.12.2018

## How to Cite This Article

**Zheng J, Wei R, Zhang J, Wang Z, Zhu T, Ruan H, Song J:** The efficacy of conjunctiva coverage in combination with amnion liquid supernatant eye drop on deep layer corneal ulcer in canine caused by alkali burn combined with mechanical injury. *Kafkas Univ Vet Fak Derg*, 25 (3): 365-372, 2019. DOI: 10.9775/kvfd.2018.21007

## Abstract

The purpose of this study was to establish the model of canine deep layer corneal ulcer by means of alkali burn combined with mechanical injury and evaluate the efficacy of conjunctival covering combined with amnion liquid supernatant deep layer corneal ulcer in beagles. By using alkali burn and mechanical injury established the beagle deep layer corneal ulcer model (n=15), randomly divided into 3 groups: deep layer corneal ulcer (C group), conjunctival covering group (T1 group), conjunctival covering combined amnion liquid supernatant eyedrop group (T2 group). On -3, 1, 7, 14, 21, 45 days, examine the levels of Interleukin -1 (IL-1), Interleukin-8 (IL-8), Vascular Endothelial Growth Factor (VEGF), Matrix metalloproteinase-1 (MMP-1), Matrix metalloproteinase-2 (MMP-2) and Matrix metalloproteinase-9 (MMP-9) in canine aqueous humor; On the 45<sup>th</sup> day, two experimental canines were randomly selected from each group to collect corneal tissue for histopathological observation. C group compared to groups T1 group and T2 group, the levels of IL-1, IL-8, VEGF, MMP-1, MMP-2, MMP-9 in canine aqueous humor significantly decreased (P<0.05). Histopathology revealed that in the T2 group corneal epithelial blood vessels were less, corneal thickness was moderate, the cornea was more complete, the cornea had fewer blood vessels, and the inflammatory cell infiltration was lower. Conjunctival coverage combined with amnion liquid supernatant eyedrop can effectively reduce keratitis cell infiltration of canine deep layer corneal ulcer, reduce corneal damage, and improve corneal transparency, the therapeutic effect is better than conjunctival coverage individually.

**Keywords:** Canine, Alkali burn combined with mechanical injury, Amnion liquid supernatant, Conjunctival cover, Corneal ulcer

## Köpeklerde Mekanik Hasar ve Alkali Yakma İle Oluşturulan Derin Korneal Ülserde Amniyon Sıvısı Süpernatantı Göz Damlası İle Birlikte Kullanılan Konjunktiva Örtüsünün Etkinliği

### Öz

Bu çalışmanın amacı, alkali yakma ile birlikte mekanik hasar oluşturularak Beagle köpeklerde derin korneal ülser meydana getirmek suretiyle bir model oluşturmak ve oluşturulan bu derin korneal ülserde amniyon sıvısı süpernatantı ile birlikte korneal örtmenin etkisini araştırmaktır. Alkali yakma ve mekanik hasar ile derin korneal ülser oluşturmak amacıyla Beagle köpekler (n=15) rastgele olarak 3 gruba ayrıldı: Derin korneal ülser grubu (C grubu), konjunktival örtü grubu (T1 grubu) ve amniyon sıvısı süpernatantı göz damlası ile birlikte konjunktival örtü grubu (T2 grubu). Çalışmanın -3, 1, 7, 14, 21 ve 45. günlerinde, köpeklerin akuöz humorlarında İnterlökin-1 (IL-1), İnterlökin-8 (IL-8), Vasküler Endotelial Büyüme Faktörü (VEGF), Matriks metalloproteinaz-1 (MMP-1), Matriks metalloproteinaz-2 (MMP-2) ve Matriks metalloproteinaz-9 (MMP-9) seviyeleri incelendi. Çalışmanın 45. gününde, her bir gruptan rastgele iki köpek seçilerek histopatolojik inceleme amacıyla korneal dokuları elde edildi. T1 ve T2 grubu ile karşılaştırıldığında C grubu köpek akuöz humorlarında IL-1, IL-8, VEGF, MMP-1, MMP-2, MMP-9 seviyelerinin anlamlı derecede azaldığı gözlemlendi (P<0.05). Histopatolojik incelemede, T2 grubundaki hayvanlarda korneal epitelyal kan damarları daha az, korneal kalınlık orta derecede, kornea daha fazla tamam, korneada daha az kan damarı ile daha az yangısal hücre infiltrasyonu gözlemlendi. Amniyon sıvısı süpernatantı göz damlası ile birlikte konjunktival örtü uygulaması köpeklerde derin korneal ülserle ilişkin keratite bağlı hücre infiltrasyonunu ve korneal hasarı etkili bir şekilde azaltmış ve korneal transparanlığı artırmıştır. Bu bulgular, Amniyon sıvısı süpernatantı göz damlası ile birlikte konjunktival örtü uygulamasının tek başına konjunktival örtü uygulamasından daha iyi tedavi edici etkisinin olduğunu göstermiştir.

**Anahtar sözcükler:** Köpek, Alkali yakma ile birlikte mekanik hasar, Amniyon sıvısı süpernatantı, Konjunktival örtü, Korneal ülser



### İletişim (Correspondence)



+86 1577 6501082



songjun\_2005@126.com

## INTRODUCTION

Deep corneal ulcers are severe corneal diseases caused by microbial infection, chemical burns, or trauma [1,2]. In the absence of timely and effective treatment, it is possible to cause blindness in corneal perforation [3]. The purpose of this study was to establish a model of deep corneal ulcer in canine by alkali burn combined with mechanical injury. Conjunctival coverage combined with supernatant of canine amnion was used to treat deep corneal ulcer in canine. We evaluate the clinical efficacy of treatment. This experiment provides reliable data support and new treatment ideas for deep corneal ulcer in canine.

## MATERIAL and METHODS

### **Ethics**

The animal study was approved by the Institutional Animal Care and Use Committee (IACUC). All beagle experimental procedures were performed in accordance with the regulations for the Administration of Affairs Concerning Experimental Animals approved by the school Council of Heilongjiang Bayi Agricultural University of China Daqing. The study protocol was approved by the Ethics Committee on the Use and Care of Animals of Heilongjiang Bayi Agricultural University (Daqing, China).

### **Preparation of Clear Liquid on Amniotic Membrane**

Fresh sterile amniotic membrane was extracted by caesarean section in healthy immunized female dogs that reached the expected delivery date. Add appropriate amount of liquid nitrogen to the aseptic fresh amniotic membrane and grind it quickly until it becomes powdery. Powder was added into the centrifugal tube, and PBS phosphate buffer was added in a 1:1 mass ratio for dilution. On the shaking table full range 20 min, put in 4°C high speed centrifuge, 8000 r/min, the centrifugal 10 min, remove the liquid supernatant and set aside.

### **Establishment of Experimental Animal Model**

Choose healthy beagles (n=15), weight 4-5 kg, aging 1-2 years old. The model of deep corneal ulcer was established by alkali burn combined with mechanical injury. General anesthesia was performed on the experimental dogs, Bupivacaine was applied to the eyes of experimental dogs, and then sterilization filter paper was used to dry the eye surface. The circular filter paper with a diameter of 6 mm was fully infiltrated in the NaOH solution. The filter paper was attached to the corneal surface for 90 s, and then the filter paper was removed. Then the normal saline was used to rinse thoroughly until the pH value of the ocular surface was about 7.0. Negative pressure corneal trephine was used to cut the cornea of alkali burns with a cutting depth of 0.4 mm and a cutting diameter of 6 mm. After cutting, the cornea was peeled off and then washed with

physiological saline to complete the modeling. After modeling, all experimental animals wore Elizabeth collars to prevent scratching and biting.

### **Grouping of Experimental Animals**

The successful model beagles were randomly divided into three groups. Deep corneal ulcer group (C group, without surgical treatment, gatifloxacin eye drops were given 2 drops/time and 5 times/day), Conjunctiva coverage group (T1 group, only with gatifloxacin eye drop after conjunctiva coverage, 2 drops/time and 5 times/day), The conjunctiva coverage in combination with amnion liquid supernatant group (T2 group, after the conjunctiva coverage was given to Gatifloxacin Eye Drop 2 drops/time and 5 times/day and amnion liquid supernatant for 2 drops/time and 5 times/day). During the experiment, all experimental animals were given butorphanol (0.02 mg/kg) analgesic management.

### **Sample Collection**

Three days before the experiment, 1, 7, 14, 21, 45 days after the beginning of the experiment, Bupivacaine was applied twice to the eyes of experimental dogs, and 10% iodov solution was used to disinfect the skin and conjunctival sac of eyelid of experimental dogs. Use your left hand to hold the upper and lower eyelids open, the assistant illuminates with a hand-held light source, 1 mL syringe needle was used for anterior chamber puncture. The puncture position was 1 mm inside the Angle sclera margin, and the needle was inserted in the direction of parallel iris, and the tip inclined plane was upward. After the tip enters the anterior chamber, collect the aqueous humor 0.2-0.3 mL. Use 10 times dilution sample diluent, in -80°C refrigerators save, waiting for inspection.

Corneal tissue samples were collected 45 days after treatment. Experimental dogs general anesthesia, after conventional disinfection of the surgery department, eyelid opener was used to expand the eyelids. Corneal tissue was collected with a corneal knife and placed in a solution of 10% formaldehyde. Routine care was given to experimental animals after surgery.

### **Aqueous Humor Testing Indicators**

Interleukin-1, IL-8, VEGF, MMP-1, MMP-2 and MMP-9 were tested by ELISA kit. All aqueous humor samples and reagents were placed in the room for complete temperature recovery. First, test samples and standard substances of different concentrations were added to the orifice plate. Horseradish peroxidase was added into each hole and incubated in a incubator for 60 min. Get rid of the orifice plate liquid, rinse thoroughly with cleaning fluid, then add substrates A and B, 37°C avoid light incubation 15 min. Finally, add the termination fluid. The absorbance (OD) value in each hole was measured by enzyme-labeled instrument, and the standard curve

was drawn. Calculate the content of each sample.

### Corneal Histopathological Examination Results

The corneal tissue was placed in 10% formaldehyde for 24 h. dehydration treatment, paraffin embedding, 4  $\mu\text{m}$  thick continuous slices, HE staining and observation with an optical microscope.

### Data Analysis

SPSS 19.0 software was used for statistical analysis of the test data using one-way anova.

## RESULTS

The content of VEGF was very significant differences between T1 group and T2 group in 7 days ( $P<0.01$ ) and it is significant differences between T1 group and T2 group in 14 and 21 days ( $P<0.05$ ). The content of VEGF was very significant differences between T2 group and group C in 7, 14, 21, 45 days ( $P<0.01$ ). On the 14<sup>th</sup> day after treatment, VEGF content in the aqueous humor of both the experimental group and the C group reached the maximum at the same time. The maximum values of C group were  $673.3914\pm 12.4211$  pg/mL, the maximum values of T1 group was  $462.3956\pm 5.6017$  pg/mL and the maximum values of T2 group was  $446.925\pm 3.4829$  pg/mL. The specific test results are shown in Fig. 1.

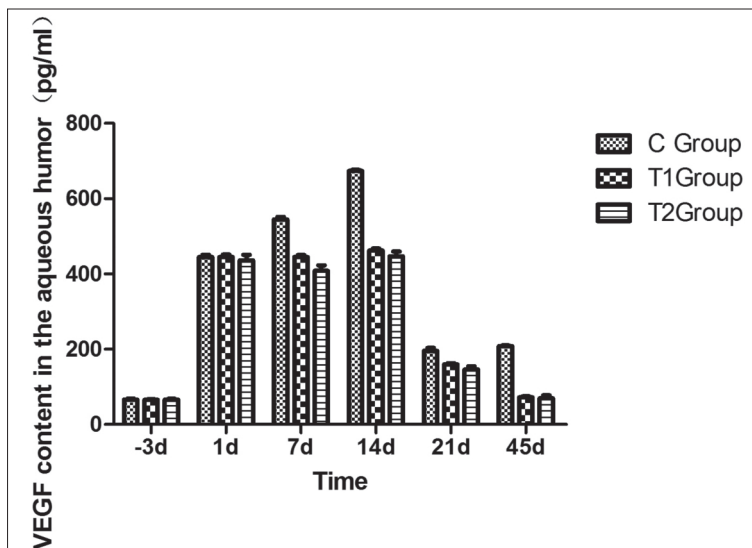
The content of IL-1 in aqueous humor was very significant differences between T1 group and T2 group in 7 days and 14 days ( $P<0.01$ ) and it is significant differences between T1 group and T2 group in 21 days ( $P<0.05$ ). There was no significant difference at other time points ( $P>0.05$ ). The content of IL-1 in aqueous humor was very significant differences between T2 group and group C in 7, 14, 21, 45 days ( $P<0.01$ ). IL-1 content in canine eye aqueous humor in the experimental group reached the maximum on the 7<sup>th</sup> day after treatment. The maximum values of T1 group

were  $166.1077\pm 4.1936$  pg/mL, the maximum values of T1 group were  $146.8177\pm 2.1139$  pg/mL. IL-1 content in canine eye aqueous humor in the C group reached the maximum on the 14<sup>th</sup> day after treatment. The maximum values of C group were  $193.2093\pm 4.2624$  pg/mL. The specific test results are shown in Fig. 2.

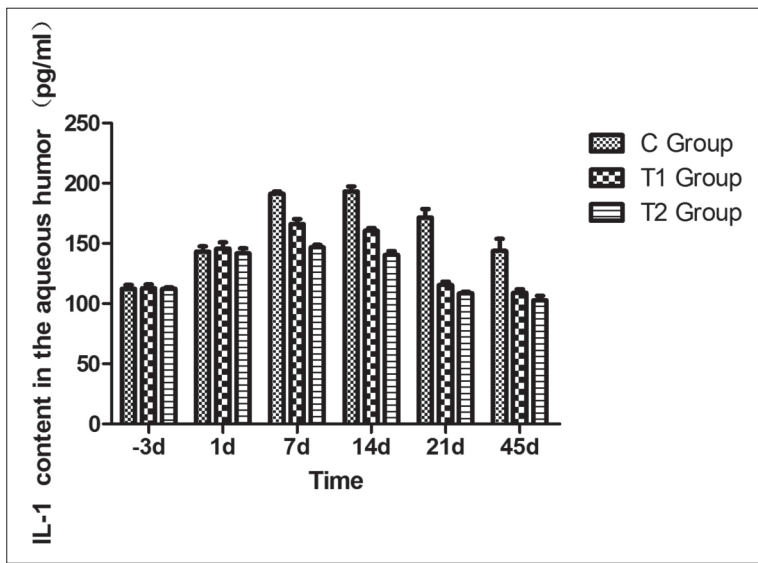
The content of IL-8 in aqueous humor was significant differences between T1 group and T2 group in 7, 14, 45 days ( $P<0.05$ ). The content of IL-8 in aqueous humor was very significant differences between T2 group and group C in 7, 14, 21, 45 days ( $P<0.01$ ). IL-8 content in the aqueous humor of canine eyes in both the experimental group and the C group reached the maximum on the 7<sup>th</sup> day after treatment. The maximum values of C group were  $168.1898\pm 4.8832$  pg/mL, the maximum values of T1 group were  $145.6043\pm 6.9070$  pg/mL, the maximum values of T2 group were  $137.4154\pm 4.3391$  pg/mL. The specific test results are shown in Fig. 3.

The content of MMP-1 in aqueous humor was very significant differences between T1 group and T2 group in 7, 14 days ( $P<0.01$ ) and it is significant differences between T1 group and T2 group in 21, 45 days ( $P<0.05$ ). The content of MMP-1 in aqueous humor was very significant differences between T2 group and group C in 7, 14, 21, 45 days ( $P<0.01$ ). MMP-1 content in the aqueous humor of canine eyes in both the experimental group and the C group reached the maximum on the 7<sup>th</sup> day after treatment. The maximum values of C group were  $115.8756\pm 4.2794$  ng/mL, the maximum values of T1 group were  $104.6135\pm 3.8075$  ng/mL, the maximum values of T2 group were  $92.0798\pm 2.0476$  ng/mL. The specific test results are shown in Fig. 4.

The content of MMP-2 in aqueous humor was significant differences between T1 group and T2 group in 7, 14 days ( $P<0.05$ ). There was no significant difference at other time points ( $P>0.05$ ). The content of MMP-2 in aqueous humor

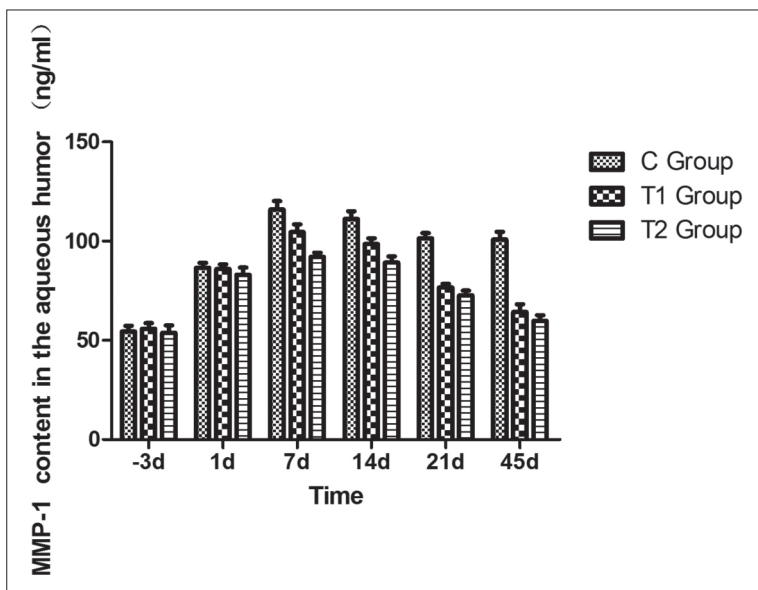
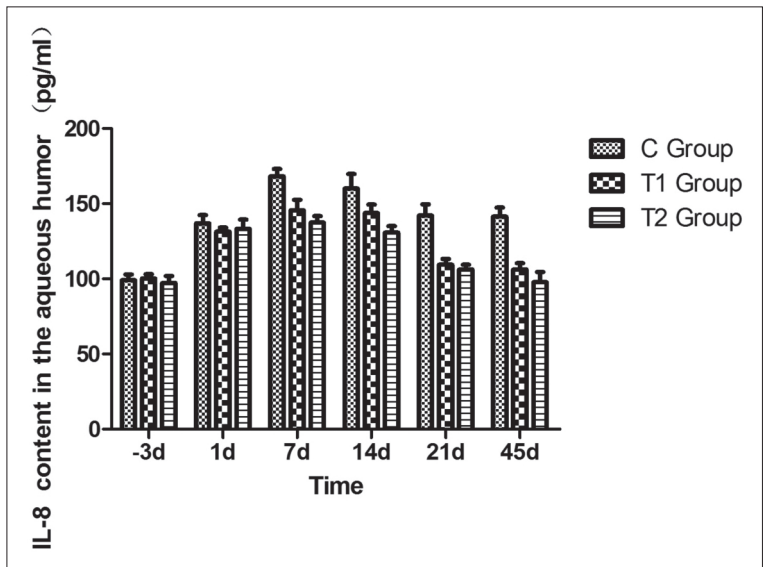


**Fig 1.** The content of VEGF was very significant differences between T1 group and T2 group in 7 days ( $P<0.01$ ) and it is significant differences between T1 group and T2 group in 14 and 21 days ( $P<0.05$ ). The content of VEGF was very significant differences between T2 group and group C in 7, 14, 21, 45 days ( $P<0.01$ )

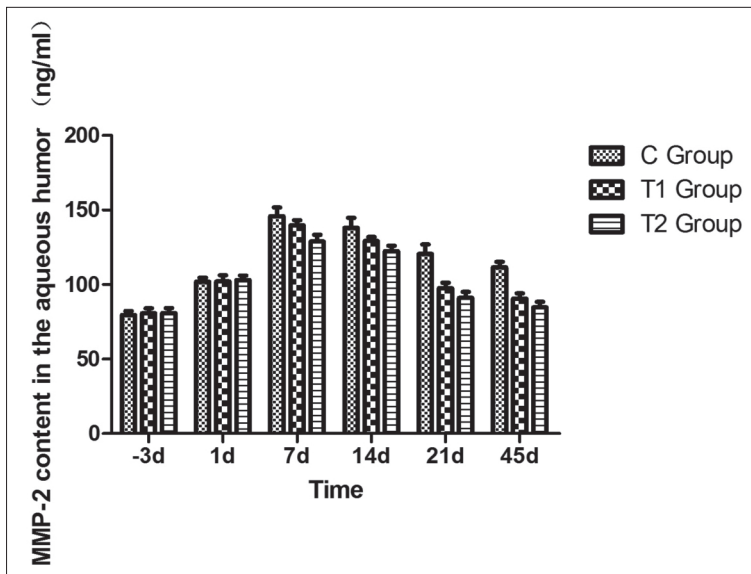


**Fig 2.** the content of IL-1 in aqueous humor was very significant differences between T1 group and T2 group in 7 days and 14 days ( $P<0.01$ ) and it is significant differences between T1 group and T2 group in 21 days ( $P<0.05$ ). There was no significant difference at other time points ( $P>0.05$ ). The content of IL-1 in aqueous humor was very significant differences between T2 group and group C in 7, 14, 21, 45 days ( $P<0.01$ )

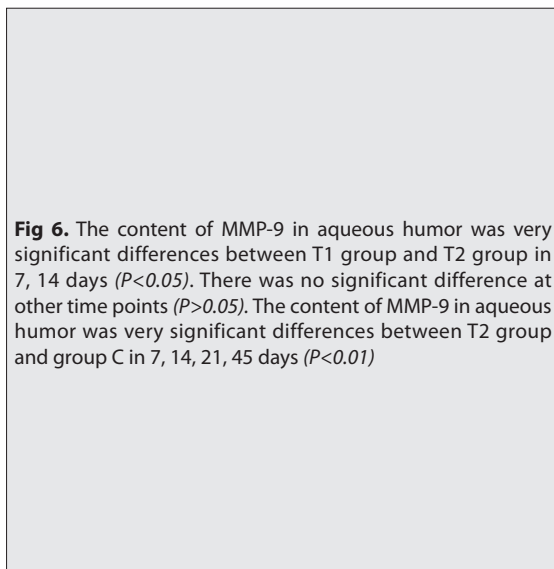
**Fig 3.** The content of IL-8 in aqueous humor was significant differences between T1 group and T2 group in 7, 14, 45 days ( $P<0.05$ ). The content of IL-8 in aqueous humor was very significant differences between T2 group and group C in 7, 14, 21, 45 days ( $P<0.01$ )



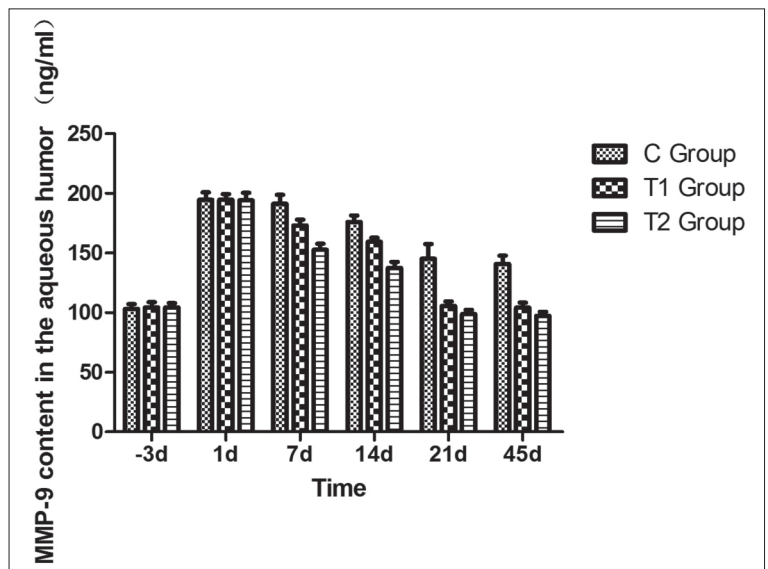
**Fig 4.** The content of MMP-1 in aqueous humor was very significant differences between T1 group and T2 group in 7, 14 days ( $P<0.01$ ) and it is significant differences between T1 group and T2 group in 21, 45 days ( $P<0.05$ ). The content of MMP-1 in aqueous humor was very significant differences between T2 group and group C in 7, 14, 21, 45 days ( $P<0.01$ )



**Fig 5.** The content of MMP-2 in aqueous humor was significant differences between T1 group and T2 group in 7, 14 days ( $P < 0.05$ ). There was no significant difference at other time points ( $P > 0.05$ ). The content of MMP-2 in aqueous humor was very significant differences between T2 group and group C in 7, 14, 21, 45 days ( $P < 0.01$ )



**Fig 6.** The content of MMP-9 in aqueous humor was very significant differences between T1 group and T2 group in 7, 14 days ( $P < 0.05$ ). There was no significant difference at other time points ( $P > 0.05$ ). The content of MMP-9 in aqueous humor was very significant differences between T2 group and group C in 7, 14, 21, 45 days ( $P < 0.01$ )



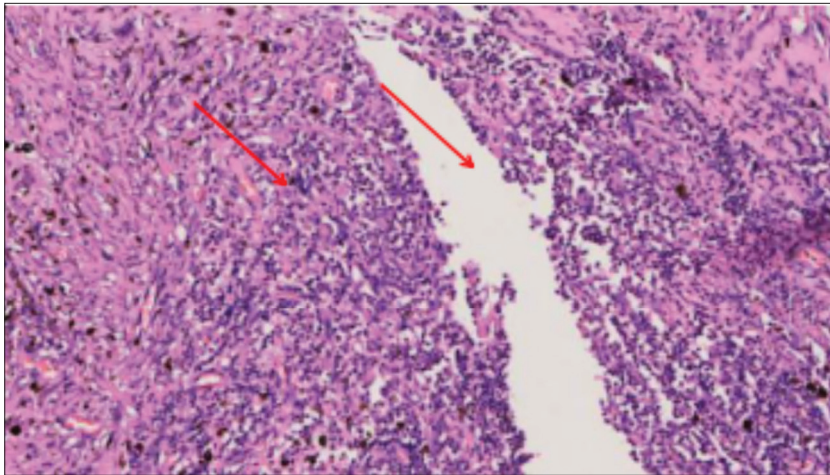
was very significant differences between T2 group and group C in 7, 14, 21, 45 days ( $P < 0.01$ ). MMP-2 content in the aqueous humor of canine eyes in both the experimental group and the C group reached the maximum on the 7<sup>th</sup> day after treatment. The maximum values of C group were  $145.8769 \pm 5.9418$  ng/mL, the maximum values of T1 group were  $139.6685 \pm 3.6469$  ng/mL, the maximum values of T2 group were  $128.8777 \pm 4.6122$  ng/mL. The specific test results are shown in Fig. 5.

The content of MMP-9 in aqueous humor was very significant differences between T1 group and T2 group in 7, 14 days ( $P < 0.05$ ). There was no significant difference at other time points ( $P > 0.05$ ). The content of MMP-9 in aqueous humor was very significant differences between T2 group and group C in 7, 14, 21, 45 days ( $P < 0.01$ ). MMP-9 content in the aqueous humor of canine eyes in both the experimental group and the C group reached the maximum on the first day after treatment. The maximum values of C

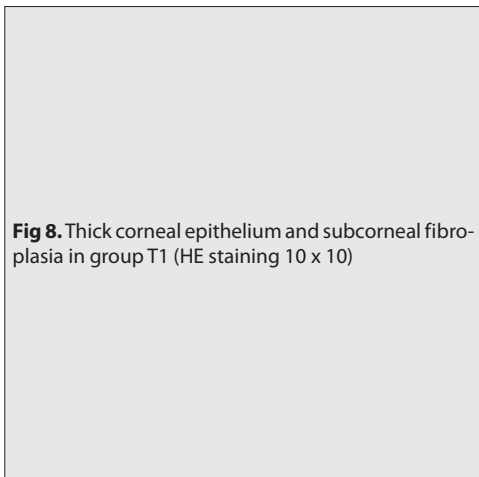
group were  $194.6672 \pm 6.1742$  ng/mL, the maximum values of T1 group were  $194.7671 \pm 4.6571$  ng/mL, the maximum values of T2 group were  $194.2776 \pm 6.2889$  ng/mL. The specific test results are shown in Fig. 6.

On the 45<sup>th</sup> day, the histopathological examination showed that the corneal epithelium was relatively intact and the corneal epithelium was thickened and healed. Under the epithelium, inflammation is very visible, the corpus ciliare is ruptured and the dilated and hyperemic vessels are seen in the mesenchyme below the epithelium, mainly with capillaries (Fig. 7). T1 group corneal epithelium is complete, partial thickness corneal thickness, corneal fiber hyperplasia, and the junction of conjunctiva blood vessels are less, neutrophils is relatively rare, corneal epithelium no inflammatory cell infiltration phenomenon (Fig. 8); In T2 group, the corneal epithelium was intact, the cornea was healed, the cornea thickness was moderate, some tissues had hyperplasia, and the corneal epithelium had few blood

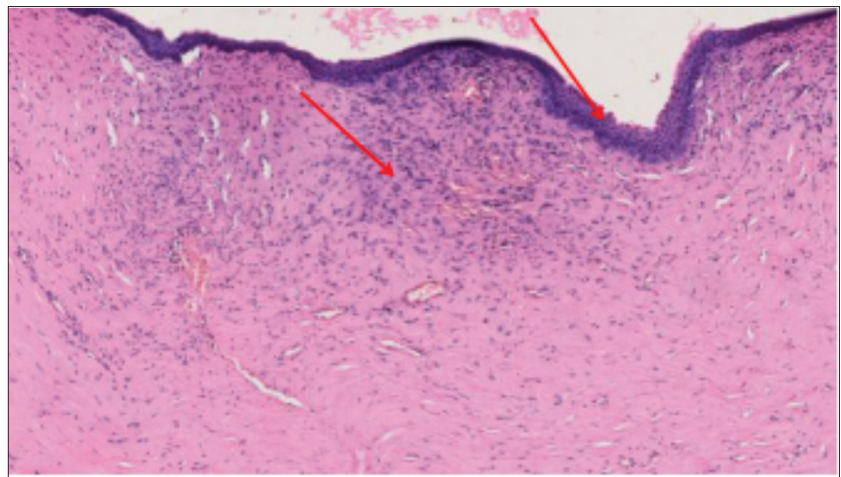




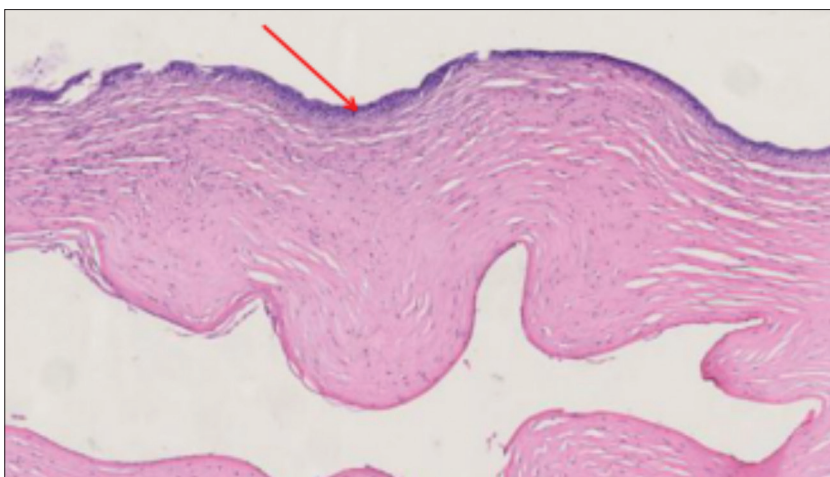
**Fig 7.** Large amounts of blood capillary and ciliary body fracture in group C (HE staining 10 x 20)



**Fig 8.** Thick corneal epithelium and subcorneal fibroplasia in group T1 (HE staining 10 x 10)



**Fig 9.** Corneal epithelium thickness is moderate and corneal healing is good in group T2 (HE staining is 10 x 10)



vessels, few inflammatory cells, and no inflammatory cell infiltration (Fig. 9).

## DISCUSSION

After corneal ulcer, the blood vessels of the conjunctiva membrane are rapidly growing in the direction of corneal damage from the Angle of the sclera. Causes the cornea

to appear the blood vessel, VEGF plays an important role in promoting vascular endothelial cell proliferation and angiogenesis [4]. Studies have also shown that VEGF overexpression exists in corneal neovascularization caused by various causes to varying degrees [5]. IL-1 and IL-8 are two important cytokines in the development of inflammatory corneal disease [6]. Inflammatory cell infiltration plays an important role, and its expression level is closely related

to the occurrence and development of inflammation and the degree of injury of corneal tissue [7]. In this study, VEGF, IL-1 and IL-8 in group C were sustained at a high level, it's consistent with previous research, it may be related to the infiltration of inflammatory cells after corneal ulcer. Since IL-1 and other inflammatory factors can induce neutrophil to chemotaxis to the cornea and aqueous humor. In addition, the increase of neutrophils can stimulate the release of local secondary inflammatory factors, aggravate corneal injury, and a large number of inflammatory cells infiltrate and cause local hypoxia. Hypoxia inducible factor-1 is one of the important promoters of VEGF, which provides support for the continuous high level expression of VEGF. In the T2 group, the levels of VEGF, IL-1 and IL-8 in the aqueous chamber were significantly reduced, which may be related to the TIMPs, IL-1ra, PEDF and other cytokines in the amniotic epithelial cells and mesenchyme cells [8,9]. At the same time, the amniotic membrane can achieve anti-inflammatory effect by reducing the chemokine's of neutrophils, improve the surrounding environment of corneal tissue, reduce the occurrence of hypoxic environment, and further inhibit the expression of VEGF. It is indicated that the amniotic fluid can synergize the corneal neovascularization and reduce the inflammatory infiltration.

Matrix metalloproteinases are important proteases that affect the structure of collagen fibers, and are related to various tissue damage and repair. More than 90% of corneal tissue is the matrix layer, and collagen fiber is an important component to maintain the stable structure of stromal layer, and it is of great significance to ensure the properties and structure of collagen fibers. The changes of MMP content directly affect the pathological changes of corneal tissue. The stability of collagen fibers in corneal stromal cells plays an important role in maintaining hydrophobicity of corneal epithelium and corneal transparency.

Studies have confirmed that amniotic membrane may inhibit the activity of matrix metalloproteinase (MMP) by increasing the expression level of tissue inhibitor of metalloproteinase-1 (TIMP-1) in the cornea, thus inhibiting the action of corneal ulcer. Paterson et al.<sup>[10]</sup> confirmed that TIMP-1 plays an important role in inhibiting the occurrence and development of corneal ulcer. In this study, the contents of MMP-1, 2 and 9 in the T2 group were significantly lower than that in T1 group, and very significantly lower than group C. This is consistent with previous research results. This may be associated with MMP hydrolyzed substrate, because deep corneal ulcer will cause massive damage corneal stromal layer collagen fiber, in the case of inflammation, MMP enzymes are activated, release, involved in cell migration, the removal of the necrotic tissue and wound healing process [11]. In group C, the corneal healing was slow, and the cornea was in a high state of traction, while the high amplitude of traction caused MMP-2 to significantly increase, while

inhibiting the expression of TIMP, affecting the corneal healing. After the conjunctiva coverage, the corneal tension was relieved, and the bFGF and other growth factors in the amniotic membrane accelerated the fusion of cornea and conjunctiva. Meanwhile, the anti-inflammatory action of amniotic membrane can improve the corneal environment, further reduce the activation of MMP enzyme, and achieve the important role of inhibiting corneal ulcer and accelerating corneal healing.

In the case of deep corneal ulcer, the integrity of corneal tissue is destroyed, and Herretes S<sup>[12]</sup> research shows that amniotic fluid can effectively reduce inflammatory cell infiltration in corneal tissue and inhibit the formation of new blood vessels. Corneal histopathological observations showed that the inflammatory cells in group C were significantly infiltrated, and the corneal stromal layer was disordered and the capillaries with more hyperemia were scattered. This was consistent with the results of significantly increased IL, VEGF and MMP in group C. There were capillaries between the conjunctiva flap and cornea in the T1 group, indicating that the healing was incomplete and the conjunctiva was not corneal. The hyperplasia of the corneal stroma indicates that the collagen fibers have not yet completed the repair of the corneal epithelium and corneal stromal layer, and the cornea debridement has not been completed. T2 group corneal thickness is moderate, vascular hyperplasia of only a small amount. Results show that amniotic membrane eye accelerated the supernatant points on the cornea of speed, reducing the inflammatory cell infiltration, at the same time by reducing the content of VEGF inhibition new angiogenesis, and to promote healing of corneal transparency has played a positive role.

## CONFLICT OF INTEREST

The authors declare that they have no competing interests.

## ACKNOWLEDGEMENTS

This research was supported by grants from the Heilongjiang Bayi Agricultural university campus cultivation project (Grant no. XZR2017-05) and the National Key Research and Development Program (Grant no. 2016YFD0501008)

## REFERENCES

- Ramani C, Rambabu K, D'Souza NJ, Vairamuthu S, Subapriya S, William BJ:** Surgical bacteriology and grading of corneal ulcers in dogs a retrospective study in 24 dogs. *Indian J Canine Practice*, 5 (1): 136-138, 2013.
- Ito S, Terakado K, Ichikawa Y, Zama T, Minami T, Kudo S, Kanemaki N:** Repair of a traumatic corneal laceration in a cat using a tectonic heterograft. *e-Polish J Vet Ophthalmol*, (2): 1-6, 2014.
- Chanie M, Bogale B:** Thelaziasis: Biology, species affected and pathology (conjunctivitis): A Review. *Acta Parasitol Globalis*, 5, 65-68, 2014.
- Morabito A, De Maio E, Di Maio M, Normanno N, Perrone F:** Tyrosine kinase inhibitors of vascular endothelial growth factor receptors in clinical trials: Current status and future directions. *Oncologist*, 11 (7): 753-764, 2006. DOI: 10.1634/theoncologist.11-7-753

- 5. Lai CM, Spilsbury K, Brankov M, Zaknich T, Rakoczy PE:** Inhibition of corneal neovascularization by recombinant adenovirus mediated antisense VEGF RNA. *Exp Eye Res*, 75 (6): 625-634, 2002. DOI: 10.1006/exer.2002.2075
- 6. Stapleton WM, Chaurasia SS, Medeiros FW, Mohan RR, Sinha S, Wilson SE:** Topical interleukin-1 receptor antagonist inhibits inflammatory cell infiltration into the cornea. *Exp Eye Res*, 86 (5): 753-757, 2008. DOI: 10.1016/j.exer.2008.02.001
- 7. Matsumoto K, Ikema K, Tanihara H:** Role of cytokines and chemokines in pseudomonal keratitis. *Cornea*, 24 (8): S43-S49, 2005. DOI: 10.1097/01.ico.0000178737.35297.d4
- 8. Fine HF, Biscette O, Chang S:** Ocular hypotony: A review. *Compr Ophthalmol Update*, 8 (1): 29-37, 2007.
- 9. Volpert OV, Zaichuk T, Zhou W, Reiher F, Ferguson TA, Stuart PM, Amin M, Bouck NP:** Inducer-stimulated Fas targets activated endothelium for destruction by anti-angiogenic thrombospondin-1 and pigment epithelium-derived factor. *Nat Med*, 8 (4): 349-357, 2002. DOI: 10.1038/nm0402-349
- 10. Paterson CA, Wells JG, Koklitis PA, Higgs GA, Docherty AJ:** Recombinant tissue inhibitor of metalloproteinases type 1 suppresses alkali-burn-induced corneal ulceration in rabbits. *Invest Ophthalmol Vis Sci*, 35 (2): 677-684, 1994.
- 11. Sivak JM, Fini ME:** MMPs in the eye: Emerging roles for matrix metalloproteinases in ocular physiology. *Prog Retin Eye Res*, 21 (1): 1-14, 2002. DOI: 10.1016/S1350-9462(01)00015-5
- 12. Herretes S, Suwan-Apichon O, Pirouzmanesh A, Reyes JMG, Broman AT, Cano M, Gehlbach PL, Gurewitsch ED, Duh EJ, Behrens A:** Use of topical human amniotic fluid in the treatment of acute ocular alkali injuries in mice. *Am J Ophthalmol*, 142 (2): 271-278, 2006. DOI: 10.1016/j.ajo.2006.03.025