

Bimanual Capsulorhexis Using a New Hand Tool: An Experimental Study in Sheep Eye

Koray KARADAYI¹ Çağrı GÜLTEKİN^{2,a} Ersin AYTAÇ^{3,b}

^[1] This work was supported by the Near East University [grant numbers: CE028-2016]

¹ Near East University School of Medicine, Department of Ophthalmology, 99138 Lefkoşa, TRNC

² Department of Surgery, Faculty of Veterinary Medicine, Near East University, 99138 Lefkoşa, TRNC

³ Near East University Innovation and Information Technologies Center, NEURobotics Lab, 99138 Lefkoşa, TRNC

^a ORCID:0000-0001-8586-1472; ^b ORCID: 0000-0001-6401-2949

Article Code: KVFD-2018-20031 Received: 27.04.2018 Accepted: 29.07.2018 Published Online: 29.09.2018

How to Cite This Article

Karadayi K, Gültekin Ç, Aytaç E: Bimanual capsulorhexis using a new hand tool: An experimental study in sheep Eye. *Kafkas Univ Vet Fak Derg*, 24 (5): 769-774, 2018. DOI: 10.9775/kvfd.2018.20031

Abstract

The purpose of this study was to design a cheap and easy-to-use hand tool that allows a better-centered capsulorhexis of consistent shape and size for inexperienced and experienced surgeons in cataract surgery. Forty-five eyes of dead adult sheep from a local slaughterhouse were grouped as; group 1, the continuous curvilinear capsulorhexis (CCC) group (n: 15); group 2, the cerclage wire group (n: 15); and group 3, the polylactic acid (PLA) hand tool group (n: 15). In group 1, one corneal incision was made. In groups 2 and 3, two incisions were made at 3:00 and 11:00 o'clock directions. Methylene blue was used for capsular staining. After injecting viscoelastic into the anterior chamber and the capsule was punctured, the devices were inserted at 3:00 o'clock. All capsulorhexes were performed using the Utrata forceps following the internal contour of the devices. As a result of the study, capsulorhexes were successfully performed in 9 of 15 eyes in group 1; 2 of 15 eyes in group 2; and 12 of 15 eyes in group 3. Statistically, the correlation between the distributions of groups 1 and 2 ($\chi^2=7.033$, $P=0.008$); and for groups 1 and 3 ($\chi^2=6.171$, $P=0.002$) were found to be significant. This study showed that CCC was performed using the newly designed PLA hand tool more successfully than the classical method by the beginning surgeon.

Keywords: Polylactic acid, Capsulorhexis, Continuous curvilinear capsulorhexis, Cataract surgery

Yeni Bir El Aleti Kullanarak Bimanuel Kapsülöreksis: Koyun Gözünde Deneysel Çalışma

Öz

Bu çalışma, katarakt cerrahisinde deneyimsiz ve deneyimli cerrahlar için kullanımı kolay, ucuz ve uygun şekil ve boyutta sentralize bir kapsülöreksis yapılabilmesine olanak tanıyan bir el aleti tasarlamak amacıyla yapıldı. Yerel bir mezbahanedен toplanan 45 ölü koyun gözü; grup 1, sürekli eğrisel kapsülöreksis (CCC) grubu (n: 15); grup 2, serklaj tel grubu (n: 15); ve grup 3, polilaktik asit (PLA) aleti grubu (n: 15) olarak ayrıldı. Grup 1'de bir korneal ensizyon yapıldı. Grup 2 ve 3'te, saat 3:00 ve 11:00 yönlerinde iki ensizyon yapıldı. Kapsül, metilen mavisi ile boyandı. Ön kamaraya viskoelastik enjekte edildikten sonra kapsül delindi, cihazlar saat 3:00 yönünden yerleştirildi. Tüm kapsülöreksisler, cihazların iç kontürünü izleyen Utrata forsepsi kullanılarak gerçekleştirildi. Çalışma sonucunda, grup 1'deki 15 gözün 9'u, grup 2'deki 15 gözün 2'si; ve grup 3'teki 15 gözün 12'sinde kapsülöreksis başarıyla gerçekleştirildi. İstatistiksel olarak, grup 1 ve 2'nin ($\chi^2=7.033$, $P=0.008$); ve grup 1 ve 3'ün ($\chi^2=6.171$, $P=0.002$) dağılımları arasındaki korelasyon anlamlı bulundu. Bu çalışma, deneyimsiz cerrah tarafından yeni tasarlanmış PLA cihaz kullanılarak yapılan CCC'nin klasik yöntemle göre daha başarılı olduğunu göstermiştir.

Anahtar sözcükler: Polilaktik asit, Kapsülöreksis, Sürekli eğrisel kapsülöreksis, Katarakt cerrahisi

INTRODUCTION

Cataract surgery is the most commonly performed eye surgery in most countries. The surgery basically consists of the stages of corneal incision, capsulorhexis, phaco-fragmentation/aspiration and intraocular lens (IOL) insertion.

One study demonstrates that capsulorhexis is the most difficult step in cataract surgery and depends on the surgeon's experience^[1]. Gimbel and Neuhann's continuous curvilinear capsulorhexis (CCC) technique made it possible for capsulorhexis to be of appropriate shape and diameter. Although the shape and diameter of CCC is not always



İletişim (Correspondence)



+90 533 31042 81



cagri.gultekin@neu.edu.tr

consistent, with this method, the fixation and centration of the IOL is highly assured [2]. To create a CCC of more consistent shape and diameter, various techniques and devices have been used. Because of the increasing use of premium multifocal IOLs, a standard diameter and shape of rhexis as well as a smooth capsule edge is now of utmost importance. It is known that the rhexis edge created using the highly priced Femtosecond Laser Assisted Cataract Surgery System (FLACS) is not as smooth and strong as that which created by the classical manual capsulorhexis [3]. Studies are conducted on animal eyes or surgical simulators to enhance surgical training and practice, while new instruments are continuously developed in order to facilitate capsulorhexis [4-11]. However, many of the instruments developed so far have not been applied to clinical-use with sufficient success due to either their high cost or lack of practicality [12-15].

As a new manufacturing technology, three-dimensional printers are used in producing custom shaped prostheses, implants, and various surgical instruments [16-19]. One of the most durable and bioadaptable thermoplastic materials used in the production of surgical instruments is the polylactic acid (PLA) polymer [15]. PLA, which is an FDA-approved biocompatible, biodegradable, and environment friendly polymer, is a lactic acid-based aliphatic polyester. Its filaments are dissolved by means of bacteria or through a hydrolysis process [20]. These manufactured PLA devices can be readily sterilized with plasma sterilization technology [21]. Furthermore, their production cost is lower than that of other similar surgical instruments [18].

We aimed in this study to develop a new cost-efficient and easy-to-use instrument to facilitate capsulorhexis especially for the beginning cataract surgeon, also to

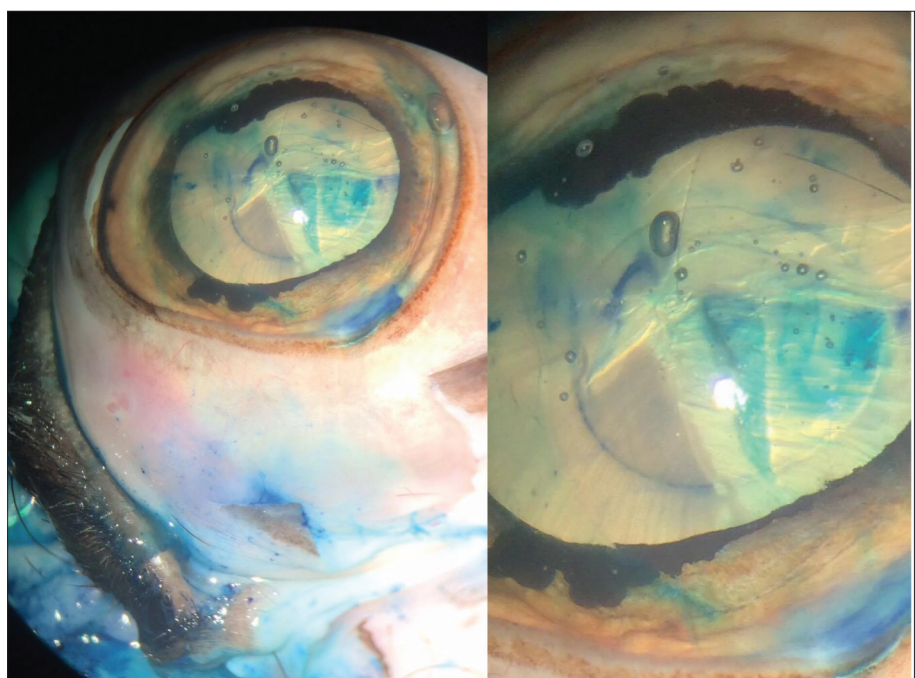
insure a better-centered capsulorhexis of consistent shape and size for the experienced surgeon wishing to implant a premium IOL.

MATERIAL and METHODS

Forty five eyes of dead adult sheep were obtained from a local slaughterhouse. In the study, we compared the bending cerclage wire and PLA tool, which are the two low costly materials with the CCC method. Routine CCC was performed in group 1 (n: 15) using a bent cystotome and a Utrata forceps (*Fig. 1*). In group 2 (n:15), capsulorhexis was performed bimanually with the aid of a cerclage wire improvised by bending a cerclage wire of 70 mm length and 0.8 mm width (20 gauge, Tektel surgical steel wire, Doğsan Inc., Turkey) into a semicircle of 7 mm-diameter (*Fig. 2*).

The PLA instrument used in group 3 (n: 15) was designed in Solidworks 2016 (Dassault Systems Solidworks Corp.) and produced in Ultimaker Extended 2 Plus (Ultimaker B.V., Netherlands), a 3D printer was used. PLA filaments used in production were in the form of standard PLA of (Ultimaker PLA - Ultimaker B.V.) 2.85 mm in diameter. Ultimaker 3D Printer is using FDM (Fused Deposition Modeling) technique. FDM is an additive manufacturing technology working as follows; the polymer is pulled from the spool via a stepper motor and introduced in the hot end which is 215°C where the polymer reaches superfluidity. The polymer was produced through the method of stacking up over printing tray in which it was poured from a height of 0.1 mm using stepper motors working in a precision of 0.1 mm in the X-Y-Z coordinate axis system. Also through the printing process, the print bed is kept at 60°C which is the critical temperature for the PLA to start its crystallization.

Fig 1. CCC was successfully performed using a cystotome and a Utrata forceps in Group 1






Fig 2. The cerclage wire device

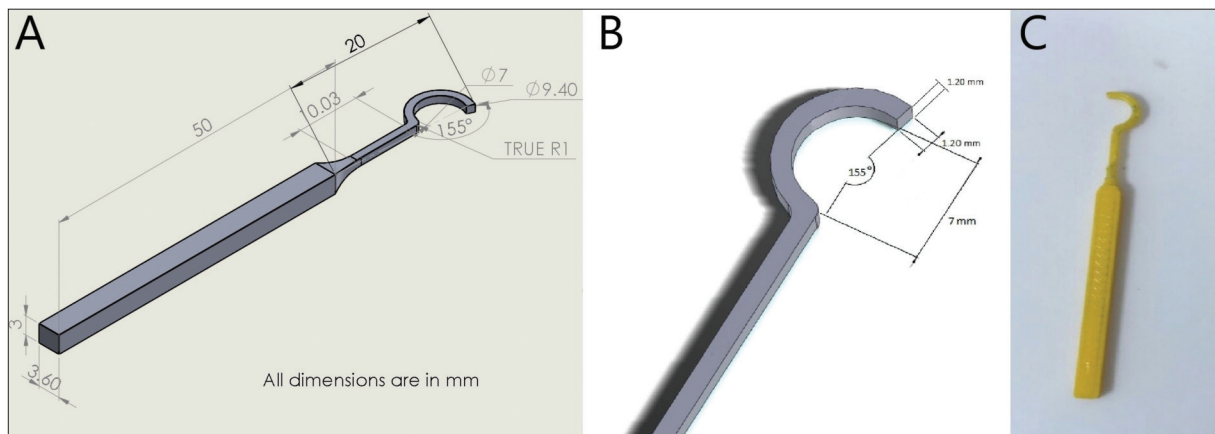


Fig 3. A) Technical Solidworks manufacturing drawing of invented PLA hand tool, B) Detailed technical drawing of the tip, C) Actual 3D printed invented PLA hand tool

After the instrument is designed in Solidworks, designed part tested by Solidworks simulation tool. The simulation process was to hold the ring part on its place and applying force to the handle bar to observe the stress in the transition part. The applied force ranged from 1 Newton (N) to 10N and the von Mises stress on the transition part changed from $1.244e+0.8$ to $1.244e+0.9$ in which the part is still in the range of elastic deformation. Elastic deformation is the type of deformation where the object turns back to its original shape. In capsulorhexis technique; to tear the anterior capsule with constant shape and size the applied force will never exceed 1.01 kilogram force (kgf), since the invented tool is a disposable item, therefore there were no need for fatigue analysis. After the simulation the design is exported as STL (STereo Lithography) format. An STL file describes a raw, unstructured triangulated surface by the unit normal and vertices of the triangles using a three dimensional Cartesian coordinate system. The STL is then introduced to a slicing software called Cura. Cura is a 3D printing slicing application. Cura exports the file in G-Code format, which is one of the variants of the most widely used numerical control (NC) programming language. The Ultimaker 3D printer accepts G-Code to manufacture the device as designed. The length of the instrument produced is 70.45 mm. The width of its stem part is 3.6 mm and its height 3 mm, forming a circle of 205° at the end of

the instrument. The inner diameter of the circle is 7 mm and the outer 9.4 mm. The tip at the end is 1.2 mm-thick and square-shaped providing a smooth bottom contact surface with square edges as opposed to the circular shape of cerclage wire (Fig. 3).

All eyes collected from the local slaughter house were preserved in 7% NaCl solution in cold chain and studied within 12 h. The eyes had been removed with the eyelids. In all groups the eyes were exposed open by medial canthotomy, then fixed onto a polystyrene foam with 2 needles. Anterior chamber was entered at 11 o'clock position using a 3.2 mm slit angled corneal knife. Anterior capsule was stained with methylene blue after air was injected into the anterior chamber. Following irrigation of the anterior chamber, a viscoelastic substance (Viscoat, Alcon Lab. Inc., Texas, USA) was injected to fill the anterior chamber as usual. The lens capsule was punctured with a cystotome. In group 1, capsulorhexis was performed monomanually as usual using a Utrata forceps inserted through the incision at 11 o'clock.

In groups 2 and 3, the instruments to be tested were inserted into the anterior chamber through the second incision at 3 o'clock as to supply a crescent guide inferiorly in the direction of 3-6-9 o'clock hours (Fig. 4A). After laying the improvised guide onto the capsule, a capsulorhexis of

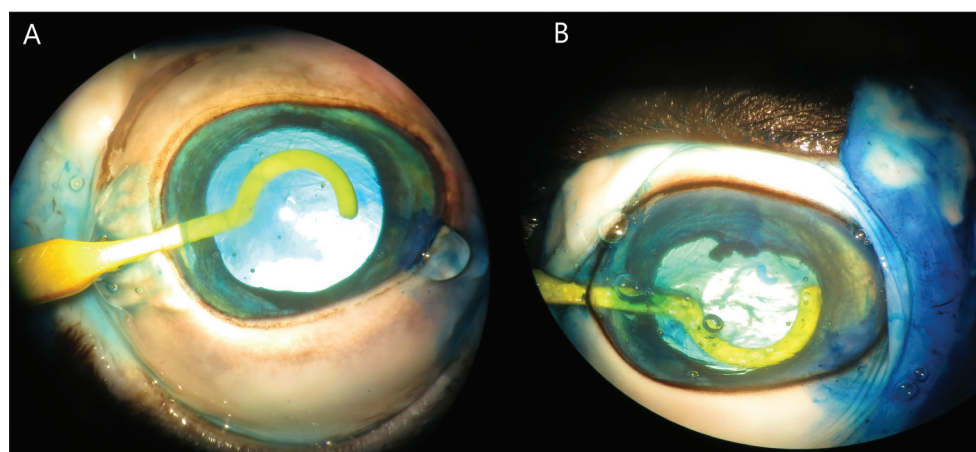


Fig 4. A) In group 3, the instruments to be tested were inserted into the anterior chamber through the incision at 3 o'clock and to supply a crescent guide inferiorly in the direction of 3-6-9 o'clock hours, B) The PLA hand tool turned around 180 degrees on its long axis into the anterior chamber, and reinserted over the anterior capsule in the direction of 9-12-3 o'clock hours

80-200 degrees was fashioned using a Utrata forceps inserted at the 11 o'clock entrance after the puncturing the capsule with the cystotome. At that stage, the improvised instrument (the cerclage wire or the PLA guide) was taken out of the anterior chamber, turned around 180 degrees on its long axis and reinserted into the anterior chamber, thus laying superiorly over the anterior capsule in the direction of 9-12-3 o'clock hours (Fig. 4B). Then the capsular flap was regripped with the Utrata forceps to complete the other (160-180 degrees) half of the rhexis, following the contour of the internal edge of the instrument just as the inferior half.

Successful CCC was defined as a smooth continuous curvilinear circle of 6 to 7 mm of diameter as the acronym CCC implies. In all 3 groups, the rate of success was recorded either as successful or unsuccessful. Statistically, the data obtained was evaluated with the Chi-square test.

All surgeries were performed by the same veterinary surgeon that had no prior experience in capsulorhexis. As the beginning surgeon, he started with the first group of 15 eyes and then proceeded with the second group and the third, consecutively.

RESULTS

In the first group, successful CCC was obtained in 9 of 15 eyes. In the unsuccessful 6 eyes, either the capsule was torn or the rhexis was not of a full-circle shape. In group 2, a full circle of CCC was created in only 2 of 15 eyes. The cause of unsuccessful rhexis in this group was tearing of the rhexis edge off course close to the distal end of the wire.

In group 3, a successful CCC of 7 mm diameter was created in 12 of 15 eyes. Of note, in this group the unsuccessful cases were the first 3 cases. In all 3 cases, the rhexis edge was observed to tear away at the same point consistently close to the middle part of the guide all in the same manner. On magnified close inspection, we observed a flaw at this region- a very small protuberance at the base of the inferior surface (which was supposed to be immaculate) of

Table 1. The distribution of results for group 1 and group 2

Groups		Results		Total
		Unsuccessful	Successful	
CCC group	n	6	9	15
	% Line	40.0%	60.0%	100.0%
	% Total	20.0%	30.0%	50.0%
Cerclage wire group	n	13	2	15
	% Line	86.7%	13.3%	100.0%
	% Total	43.3%	6.7%	50.0%
Total	n	19	11	30
	% Line	63.3%	36.7%	100.0%
	% Total	63.3%	36.7%	100.0%

Table 2. The distribution of results for group 1 and group 3

Groups		Results		Total
		Unsuccessful	Successful	
CCC group	n	6	9	15
	% Line	40.0%	60.0%	100.0%
	% Total	22.2%	33.3%	55.6%
PLA Tool	n	0	12	12
	% Line	0.0%	100.0%	100.0%
	% Total	0.0%	44.4%	44.4%
Total	n	6	21	27
	% Line	22.2%	77.8%	100.0%
	% Total	30.0%	70.0%	100.0%

the guide. After this protuberance was polished away, the remaining 12 cases were all successful.

The correlation between the distribution of results for group 1 and group 2 was found to be statistically significant ($\chi^2=7.033$, $P=0.008$) (Table 1). The correlation between the distribution of results for group 1 and group 3 was also statistically significant ($\chi^2=6.171$, $P=0.002$), proving that the higher success rate in group 3 was statistically significant (Table 2).

DISCUSSION

A new practical and reproducible method for CCC is definitely needed in order to facilitate and make it safer for the beginning surgeon as well as for the experienced surgeon in an era when premium multifocal IOLs are being widely used. Creating a capsulorhexis of 5.5-6.0 mm size reproducibly is in fact difficult also for the experienced surgeon. To solve this problem, various techniques and instruments have been developed most of which are either high cost (as in FLACS, precision pulse capsulotomy-PPC) or lack clinical practicability [12-15].

Various animal eyes are used in educational and experimental studies throughout the world. In those studies, pig eyes are used more often, while cow, goat, sheep and rabbit eyes are other alternatives [3,5,22-24]. In our study, sheep eye was chosen because it is similar to human eye with respect to anterior chamber depth, axial length, equatorial diameter, and is easily obtained in our area. Corneal diameter of sheep eye is more than twice that of human eye. That's why the improvised instruments to be tested (cerclage wire and PLA) are of larger size accordingly. An instrument to be used in a human eye would be of smaller size, although this very instrument could be used with minimal changes in the semi-circle diameter to suit the human lens size. The design of the instrument is more important than the scaling, because the square shape and smoothness of the bottom surface of the PLA device uniformly supports the underlying capsule surface providing a better guiding contour for the advancing rhexis front.

In one study, the size of corneal incision was too small to insert the tested instrument -which had a circular shape- into the anterior chamber, thus the researchers decided to enlarge the corneal incision to allow for a successful capsulorhexis [8]. However, for small-incision cataract surgery the developed hand tool should be of proper size. In our study, a semi-circular shape was proper to entry into the anterior chamber through a smaller corneal incision.

In conventional capsulorhexis, the capsular edge may tear away toward periphery due to centripetal zonular forces, which adversely affects the success of capsulorhexis. To eliminate these forces in such instances, several prevention and correction methods are recommended [25-28]. Because of the round structure of cerclage wire used in Group 2, the instrument did not have enough contact area with the lens surface and the capsule was torn towards the periphery mostly in the direction of 8 to 10 o'clock, most probably due to insufficient pressure against the capsular surface. In the PLA instrument group, a semi-circle diameter of 205° and the contact surface that is flatter and larger eliminated the effects of capsular forces and thus, allowed for more successful capsulorhexis.

This study shows that, with the aid of the cost-efficient

PLA hand tool and the bimanual technique described, a reproducible CCC of consistent size and shape could be achieved even by a beginning surgeon more easily compared to the classical CCC technique. The development studies will be continued to adjust the instrument sizes according to anterior chamber width, lens capsule thickness and pupil size in various species and determine its effectiveness upon live tissue.

FINANCIAL DISCLOSURE AND FUNDING

All authors will be named as the inventors, in a patent application with the Near East University covering the details in this report. This work was supported by the Near East University [grant numbers: CE028-2016].

ACKNOWLEDGEMENTS

The authors would like to thank İlker Etikan, PhD for his statistical analyses of this study.

REFERENCES

- Dooley IJ, O'Brien PD:** Subjective difficulty of each stage of phacoemulsification cataract surgery performed by basic surgical trainees. *J Cataract Refract Surg*, 32, 604-608, 2006. DOI: 10.1016/j.jcrs.2006.01.045
- Gimbel HV, Neuhann T:** Development, advantages, and methods of the continuous circular capsulorhexis technique. *J Cataract Refract Surg*, 16, 31-37, 1990. DOI: 10.1016/S0886-3350(13)80870-X
- Izak AM, Werner L, Pandey SK, Apple DJ, Izak MGJ:** Analysis of the capsule edge after Fugo plasma blade capsulotomy, continuous curvilinear capsulorhexis, and can-opener capsulotomy. *J Cataract Refract Surg*, 30 (12): 2606-2611, 2004. DOI: 10.1016/j.jcrs.2004.05.020
- Kayıkcioglu O, Egrilmez S, Emre S, Erakgun T:** Human cataractous lens nucleus implanted in a sheep eye lens as a model for phacoemulsification training. *J Cataract Refract Surg*, 30, 555-557, 2004. DOI: 10.1016/j.jcrs.2003.08.018
- Mohammadi SF, Mazouri A, Jabbarvand M, Rahman AN, Mohammadi A:** Sheep practice eye for ophthalmic surgery training in skills laboratory. *J Cataract Refract Surg*, 37, 987-991, 2011. DOI: 10.1016/j.jcrs.2011.03.030
- Bozkurt Oflaz A, Ekinci Köktekir B, Okudan S.** Does cataract surgery simulation correlate with real-life experience? *Turk J Ophthalmol*, 48, 122-126, 2018.
- El Chehab H, Agard E, Dot C:** Evaluation of surgical simulation sessions of the French society of ophthalmology. A new surgical instruction method. *J Fr Ophthalmol*, 40 (8): 636-641, 2017.
- Powers MA, Kahook MY:** New device for creating a continuous curvilinear capsulorhexis. *J Cataract Refract Surg*, 40, 822-830, 2014. DOI: 10.1016/j.jcrs.2013.10.041
- Soylak M:** Novel device for creating continuous curvilinear capsulorhexis. *SpringerPlus*, 5:2053, 2016. DOI: 10.1186/s40064-016-3736-6
- Tassignon MJ, Rozema JJ, Gobin L:** Ring-shaped caliper for better anterior capsulorhexis sizing and centration. *J Cataract Refract Surg*, 32 (8): 1253-1255, 2006. DOI: 10.1016/j.jcrs.2006.02.067
- Wallace RB:** Capsulotomy diameter mark. *J Cataract Refract Surg*, 29 (10): 1866-1868, 2003. DOI: 10.1016/S0886-3350(03)00354-7
- Fugo RJ, Del Campo DM:** The Fugo blade: the next step after capsulorhexis. *Ann Ophthalmol*, 33 (1): 12-20, 2001. DOI: 10.1007/s12009-001-0066-1
- Kranitz K, Takacs A, Mihaltz K, Kovacs I, Knorz MC, Nagy ZZ:** Femtosecond laser capsulotomy and manual continuous curvilinear capsulorhexis parameters and their effects on intraocular lens centration.

J Refract Surg, 27, 558-563, 2011. DOI: 10.3928/1081597X-20110623-03

14. Palanker D, Nomoto H, Huie P, Vankov A, Chang DF: Anterior capsulotomy with a pulsed-electron avalanche knife. *J Cataract Refract Surg*, 36, 127-132, 2010. DOI: 10.1016/j.jcrs.2009.07.046

15. Hooshmand J, Abell RG, Allen P, Vote BJ: Thermal capsulotomy: Initial clinical experience, intraoperative performance, safety, and early postoperative outcomes of precision pulse capsulotomy technology. *J Cataract Refract Surg*, 44 (3): 355-361, 2018. DOI: 10.1016/j.jcrs.2017.12.027

16. Fedorovich NE, Alblas J, Hennink WE, Öner FC, Dhert WJ: Organ printing: The future of bone regeneration? *Trends Biotechnol*, 29 (12): 601-606, 2011. DOI: 10.1016/j.tibtech.2011.07.001

17. Kondor S, Grant CG, Liacouras P, Schmid MJR, Parsons LM, Rastogi VK, Macedonia C: On demand additive manufacturing of a basic surgical kit. *J Med Devices*, 7 (3): 030916, 2013. DOI: 10.1115/1.4024490

18. Rankin TM, Giovinco NA, Cucher DJ, Watts G, Hurwitz B, Armstrong DG: Three-dimensional printing surgical instruments: Are we there yet? *J Surg Res*, 189 (2): 193-197, 2014. DOI: 10.1016/j.jss.2014.02.020

19. Serra T, Mateos-Timoneda MA, Planell JA, Navarro M: 3D printed PLA-based scaffolds: A versatile tool in regenerative medicine. *Organogenesis*, 9 (4): 239-244, 2013. DOI: 10.4161/org.26048

20. Lunt J: Large-scale production, properties and commercial applications of polylactic acid polymers. *Polym Degrad Stab*, 59 (1-3): 145-152, 1998. DOI: 10.1016/S0141-3910(97)00148-1

21. Nuutinen JP, Clerc C, Virta T, Törmälä P: Effect of gamma, ethylene

oxide, electron beam, and plasma sterilization on the behaviour of SRPLLA fibres *in vitro*. *J Biomater Sci Polym Ed*, 13 (12): 1325-1336, 2002. DOI: 10.1163/15685620260449723

22. Nagy Z, Takacs A, Filkorn T, Sarayba M: Initial clinical evaluation of an intraocular femtosecond laser in cataract surgery. *J Refract Surg*, 25 (12): 1052-1060, 2009. DOI: 10.3928/1081597X-20091117-04

23. Sengupta S, Dhanapal P, Nath M, Haripriya A, Venkatesh R: Goat's eye integrated with a human cataractous lens: A training model for phacoemulsification. *Indian J Ophthalmol*, 63 (3): 275-277, 2015. DOI: 10.4103/0301-4738.156937

24. Tahi H, Fantes F, Hamaoui M, Parel JM: Small peripheral anterior continuous curvilinear capsulohexis. *J Cataract Refract Surg*, 25 (6): 744-747, 1999. DOI: 10.1016/S0886-3350(99)00041-3

25. Mohammadpour M: Rescue of an extending capsulorhexis by creating a midway tangential anterior capsular flap: A novel technique in 22 eyes. *Can J Ophthalmol*, 45 (3): 256-258, 2010. DOI: 10.3129/i09-260

26. Mohammadpour M: Management of radial tears during capsulorhexis. *Tech Ophthalmol*, 4 (2): 56-60, 2006.

27. Mohammadpour M, Erfanian R, Karimi N: Capsulorhexis: Pearls and pitfalls. *Saudi J Ophthalmol*, 26 (1): 33-40, 2012. DOI: 10.1016/j.sjopt.2011.10.007

28. Little BC, Smith JH, Packer M: Little capsulorhexis tear-out rescue. *J Cataract Refract Surg*, 32 (9): 1420-1422, 2006. DOI: 10.1016/j.jcrs.2006.03.038