

The Clinical and Radiological Evaluation of Medial Coronoid Disease in Dogs: 20 Cases

Didar AYDIN KAYA ¹  Kemal ALTUNATMAZ ¹

¹ Istanbul University, Veterinary Faculty, Surgery Department, TR-34320 Avcilar, Istanbul - TURKEY

Article Code: KVFD-2018-19772 Received: 17.03.2018 Accepted: 27.06.2018 Published Online: 27.06.2018

How to Cite This Article

Aydın Kaya D, Altunatmaz K: The clinical and radiological evaluation of medial coronoid disease in dogs: 20 cases. *Kafkas Univ Vet Fak Derg*, 24 (5): 709-716, 2018. DOI: 10.9775/kvfd.2018.19772

Abstract

In this study, clinical status and treatment outcomes of 20 dogs, which were referred to Istanbul University, Faculty of Veterinary Medicine, and Department of Surgery with the complaint of forelimb lameness and diagnosed with medial coronoid disease (MCD), were assessed. The diagnosis was made based on radiographic findings in 16 patients, on arthroscopic findings in 2 and on computed tomographic findings in other 2 patients. Arthrotomy aimed at removal of fragmented medial coronoid process and debridement of the surrounding tissues was carried out on a total of 20 elbow joints. Average functional recovery period after arthrotomy was 31 days and postoperative lameness scores on day 30 were "1" and "0" in 8 and 12 cases, respectively. Recovery rates on postoperative day 60 were detected to be moderate, good and very good in 9, 5 and 6 dogs, respectively. In the current study, treatment options were evaluated in the dogs with medial coronoid disease and the outcomes were aimed to be a contribution to veterinary practice.

Keywords: Medial coronoid process, Fragmentation, Dog

Köpeklerde Medial Koronoid Hastalığının Klinik ve Radyografik Olarak Değerlendirilmesi: 20 Olgu

Öz

Bu çalışmada İstanbul Üniversitesi Veteriner Fakültesi Cerrahi Anabilim Dalı'na ön bacakta topallık şikayetiyle getirilip, medial koronoid hastalığı (MKH) tanısı konulan 20 adet köpeğin klinik durumları ve sağaltım sonuçları değerlendirilmiştir. MKH'nin tanısı 16 hastada direkt radyografi, 2 hastada artroskopi ve 2 hastada bilgisayarlı tomografi ile konulmuştur. MKH'na bağlı medial koronoid prosesin kırık parçasının uzaklaştırılması ve bölgenin debridmanına yönelik artrotomi işlemi toplam 20 dirsek eklemine uygulanmıştır. Artrotomi sonrasında fonksiyonel iyileşme ortalama 31 gün, postoperatif 30. gün topallık dereceleri 8 olguda "1", 12 olguda "0" olarak belirlenmiş olup 60. gün sonunda iyileşmeleri 9 olguda vasat, 5 olguda "iyi", 6 olguda ise "çok iyi" olarak değerlendirildi. Sunulan bu çalışmada medial koronoid hastalığı olan köpeklere uygulanan sağaltım yöntemleri değerlendirilmiş olup sonuçlarının meslek pratiğine aktarılması amaçlanmıştır.

Anahtar sözcükler: Medial koronoid proses, Kırık, Köpek

INTRODUCTION

Medial coronoid disease (MCD) which is one of the most frequently encountered pathology of the forelimb lameness is most particularly seen in the young individuals of medium or large dog breeds ^[1-5]. Medial coronoid disease is a component of a phenomenon called as canine elbow dysplasia complex which includes ununited anconeal process (UAP), osteochondrosis (OC) or osteochondritis dissecans of humerus condyle (OCD) and radioulnar joint incongruence ^[6-8]. Fragmentation or fissuring of the medial coronoid process (FMCP) and occurrence of

pathological changes in the subchondral bone and at the periphery of the articular cartilage play an important role in the diagnostic approach of the disease ^[2,9,10]. Clinical manifestations in dog may be seen at 4-8 months of age and were reported to have occurred earlier (3 months of age) or later (>6 years) ages, as well ^[2,11-14]. Clinical signs comprise lameness, timid and stiff gait and tendency to keep the affected leg in the abducted position. Articular effusion, crepitus and pain reaction may be observed at the physical examination ^[8,13]. Disorders in endochondral ossification, abnormalities in subchondral bone and abnormal load distribution due to radioulnar joint non-



İletişim (Correspondence)



+90 532 3921994



didaraydin@hotmail.com

conformity rank among the etiological factors apart from the mostly pronounced genetic predilection [3,8,9]. Miscellaneous breeds such as Labrador and Golden Retrievers, German Shepherds, Bernese Mountain Dogs and Rottweilers are predisposed to the disease. Male dogs are affected two times more often than the females [9,14,15]. Radiography, computed tomography (CT), arthrotomy/arthroscopy, scintigraphy and ultrasonography, magnetic resonance imaging (MRI) are utilized in the diagnosis of MCD [16,17]. The disease is identified best on mediolateral projection of the flexed elbow joint and radiographic view of the elbow joint extended in mediolateral position with the antebrachium pronated at 15 degrees. Nonetheless, computed tomography which is known to be more sensitive than radiography is of great diagnostic significance at earlier ages (14 months of age) [18,19].

Treatment for MCD may consist of different surgical techniques. The set of alternatives can be listed as follows: Surgical removal of the fragment by arthrotomy or arthroscopy, subtotal coronoidectomy, articular cartilage debridement, distal ulnar ostectomy, proximal ulnar osteotomy, bi-oblique dynamic proximal ulnar osteotomy and the releasing procedures of the biceps/brachialis muscle [12,20-23].

This retrospective study has been designed to evaluate and compare the therapeutic approaches in the dogs diagnosed with MCD between the years 2007 and 2017 in an attempt to establish an applied guidance for the veterinary surgeons.

MATERIAL and METHODS

The study material consisted of 20 dogs of different breeds, ages and genders which were referred to the clinic of the

Department of Surgery, Faculty of Veterinary Medicine, Istanbul University between 2007-2017 with the complaint of forelimb lameness. After having received a complete medical history, the dogs were subjected to a throughout orthopedic examination followed by radiographic imaging of both elbow joints positioned mediolaterally in complete flexion and extended craniocaudally with pronation of the antebrachium at 15 degrees. After radiographic examination was performed in all patients, of 4 suspected cases (Fig. 1) with MCD diagnosis of 2 (case numbers 19 and 20) were based computed tomographic findings (Fig. 2) and other 2 (case numbers 4 and 5) were diagnosed according to arthroscopic findings (Fig. 3).

For arthroscopic examination equipment consisted of a 2.7 mm diameter, 175 mm length 0° angle Rema arthroscope and accessories, 250 Watt Rema HLS-M-250 halogen cold light source, 170 cm fiberoptic cable, Rema CCD 950 camera system, 15" 105S Phillips digital colored monitor and Sony UP-230P/2 video printer were used. Dogs were positioned in lateral recumbency. The irrigation of the joint was maintained using saline solution (0.9% NaCl). At the beginning, in order to distend the joint, saline was injected inside the joint by using a 18 G cannula in a craniodistal and slight lateral direction, beginning just proximal or adjacent to the anconeus. The joint was filled until moderate pressure was felt by digital touching of the distended joint capsule. The arthroscope cannula was established caudally and distally to the medial epicondyle of the humerus. The thumb was placed on the medial epicondyle and drawn down distally and caudally until the approximate level of the joint was reached. A short incision through the skin and superficial soft tissues was made with a small blade (no. 11). The articular capsule was penetrated with the arthroscope cannula fitted with a

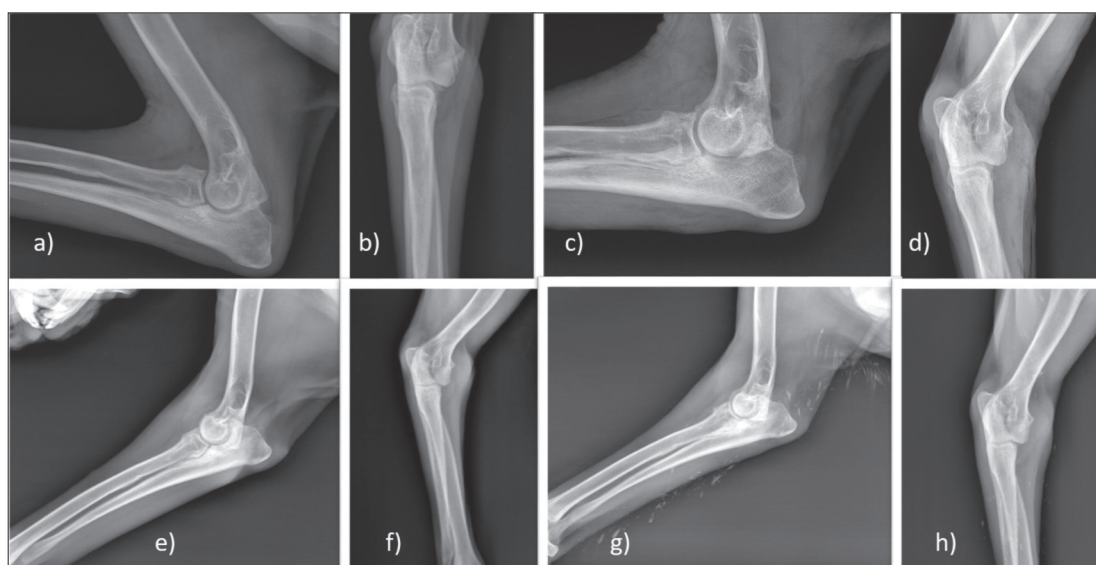


Fig 1. One of suspected cases (Case number 19): pre-operative (a, b) and immediately post-operative (c, d), postoperatively 30th day (e, f) and 60th day (g, h) later radiographic view of right humeroradial joint. a, c, e, g- mediolateral and b, d, f, h- craniocaudal oblique positions

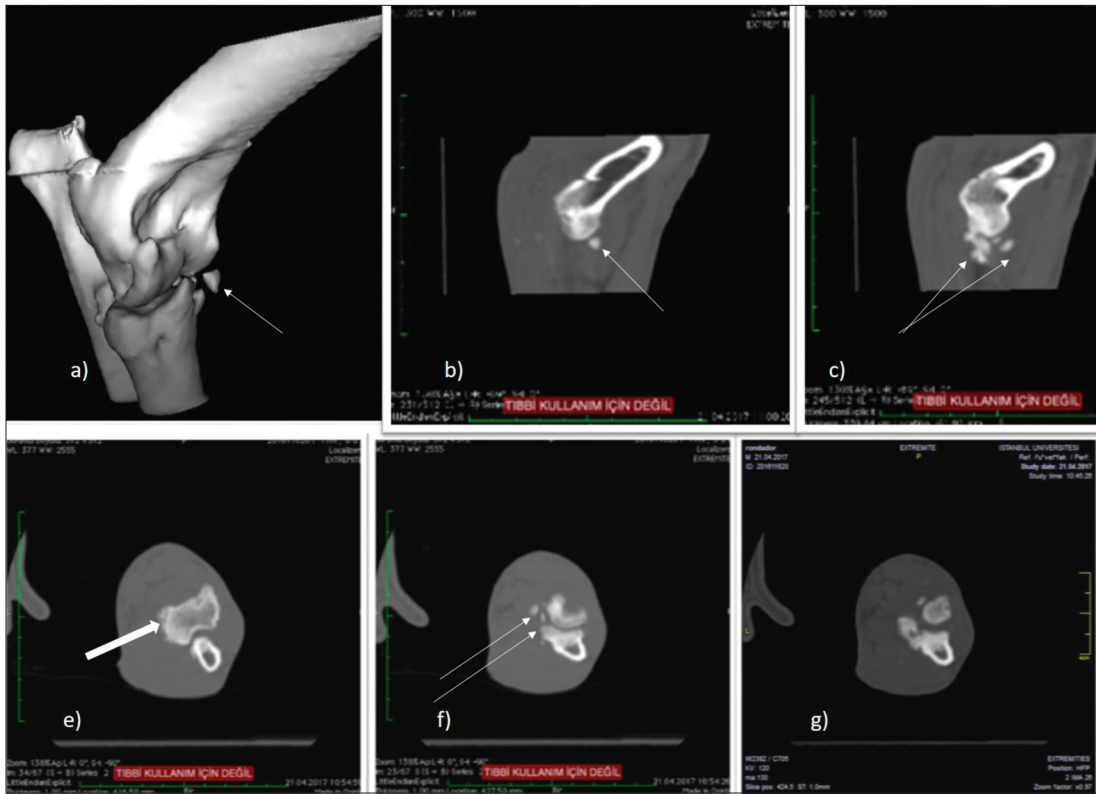


Fig 2. Transverse computed tomography (CT) images 1.0 mm thick were obtained and reconstructed into 3D image and sagittal view of right humeroradial joint of case number 19. **a, b, c, f, g-** thin arrows: abnormal shape of the medial coronoid process (MCP) with a distinct fragments, **d- thick arrow:** degenerative changes in distal humeral condyle

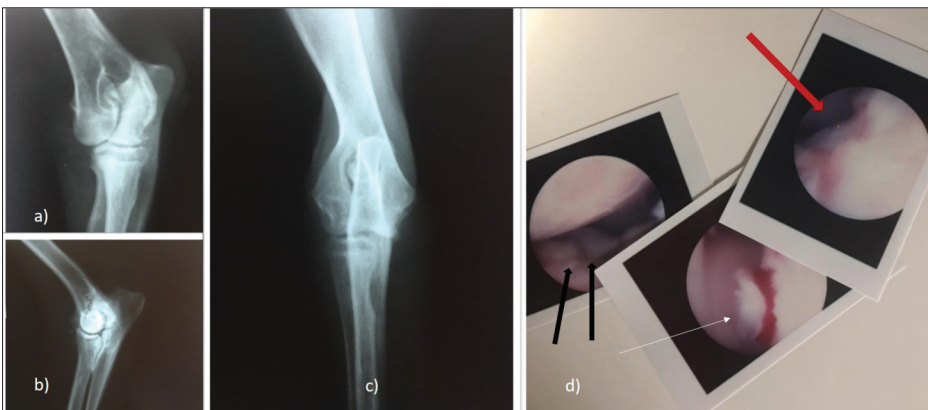


Fig 3. One of suspected cases (case number 5) and preoperative a- oblique, b- mediolateral, c- craniocaudal radiographic, arthroscopic view of the right humeroradial joint. **black arrows:** fragmented bones in the joint cavity, **white arrow:** distinct nondisplaced fragment of the coronoid process, **red arrow:** irregularity of medial coronoid process

sharp obturator. Sequentially, the cannula was substituted by the arthroscope. After the visualization of the joint that seen nondisplaced fragments, observative arthrotomy were ended.

In CT study, general anaesthesia was achieved with slow IV injection of propofol (Propofol 1% Fresenius® 200 mg/20 mL-Sweden-10 mg/kg) and dogs were positioned in dorsal recumbency on the CT scanning table with the elbow joint extended approximately 135°. CT images of elbow joint was obtained with a single slice scanner Shimadzu, SCT7800 TC, Japan using 120 KV, 130 mA parameters. Transverse images 1.0 mm thick were obtained and reconstructed into sagittal and 3D images.

All preoperative laboratory data (total blood counts and biochemical parameters) were evaluated prior to the surgical procedure. Anesthesia was induced by Ketamine HCl (5 mg/kg, IV, Ketamine, Eczacıbaşı®, Turkey) followed by Xylazine HCl (2 mg/kg, IM, Rompun, Bayer®, Germany) premedication and then maintained by Isoflurane (Forane, 100ml, Abbott, Switzerland) at an initial concentration of 4% followed by 2% via endotracheal intubation. The subjects were tilted on the operation desk enabling the affected leg to be seated underneath. Strictly following the principles for asepsis and antisepsis, a skin incision was made with a slight curve, starting from the medial condylus of the humerus and proceeding on the middle

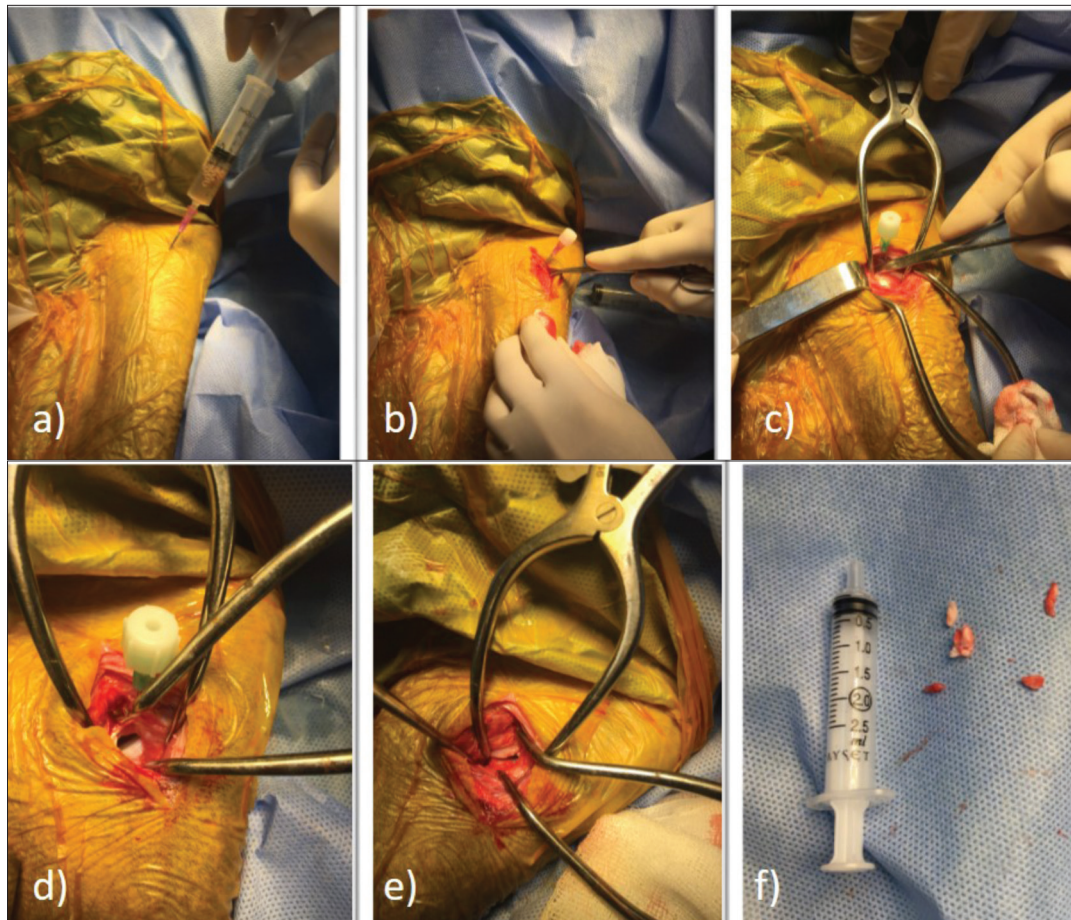


Fig 4. Intraoperative views of case number 19

plane of the joint. Antebrachial fascia was dissected and pronator teres and flexor carpi radialis muscles were separated by blunt dissection. Gelpi retractors were used not to damage the arteries and the nerves located on the medial region. Then the articular space was distinguished by the aid of a 20 G cannula and 5-10 mL of physiological saline was injected enabling the distention of the articular capsule. A horizontal incision was made on the articular capsule and Gelpi retractors were placed beneath. Then the fragment was released and removed from the joint. Articular space was rinsed with abundant physiological saline before the articular capsule and the skin incisions were closed in accordance with the routine surgical principles (Fig. 4). Postoperatively, the patients received 20-40 mg/kg of Ceftriaxone (Forsef, IM, 1000 mg/mL Bilim İlaç, Turkey) daily for a week and were strictly prescribed exercise restriction for the following 4 weeks.

As for the patients with bilateral FMCP, the second limb was operated after the achievement of complete functional recovery of the first limb. The ununited process was removed at the same session in the patients with FMCP accompanied by UAP.

Pre- and postoperative scores of all patients were comparatively evaluated (Fig. 1). In the patients with

bilateral lesions, the following 30th day of the first arthroscopy was determined as the baseline. Functional recovery periods were recorded according to face to face meetings or on-phone dialoging with the owners. Lameness scores were based on a 5-point scale: 0 = no detectable lameness; 1 = mild weightbearing lameness; 2 = moderate weight-bearing lameness; 3 = marked weight-bearing lameness; and 4 = nonweight-bearing lameness [24]. Clinical and radiographic (Fig 1. e, f, g, h) evaluations were carried out on days, 30 and 60 and all data collected were assessed.

RESULTS

The demographic features like breed, body weight and gender of the dogs, diagnostic methods, the localization of the lesions, and presence of an accompanying lesion and time span of lameness were recapitulated in Table 1.

Reluctance to move and lameness were noted in the anamnesis received from the patients' owners. In cases of unilateral involvement, owners reported intermittent lameness, and in cases of bilateral MCD patients manifested a progressive lameness with a sudden onset. Severe pain reaction was detected when the elbow joint was positioned in flexion or extension during the clinical

Table 1. Summary of the case details included in the study

Dog	Breed	Sex	Age (month)	Weight (kg)	Duration of Lameness	LS	Co-existence of UAP	Pre-op LS	Post-op LS	FHT	Outcome
1	GSD	♂	9	28	45	L	-	2	0	20	G
2	Ptb	♀	8	35	30	R	-	3	0	14	VG
3	BM	♀	8	43	15	B	+	2	1	60	MOD
4	GSD	♂	8	29	20	L	-	3	1	45	MOD
5	ASD	♂	8	40	30	R	-	2	0	18	VG
6	GSD	♂	8	27	20	B	-	2	0	16	VG
7	Lab	♂	9	28	30	L	+	3	1	35	MOD
8	Lab	♂	9	29	30	R	-	3	0	14	VG
9	BM	♂	8	55	20	R	-	2	0	18	G
10	GR	♀	9	28	40	L	+	2	0	35	MOD
11	GR	♀	36	39	30	B	-	2	0	21	G
12	GR	♂	14	29	15	L	-	3	0	14	VG
13	Lab	♀	10	32	30	L	-	3	0	30	MOD
14	GSD	♂	10	34	60	B	-	3	1	45	MOD
15	ASD	♂	12	43	90	R	-	2	1	40	MOD
16	Aust SD	♂	7	22	45	R	-	3	0	40	G
17	BM	♂	7	60	60	B	+	4	1	45	MOD
18	DA	♂	12	45	45	R	-	4	1	42	MOD
19	GSD	♀	8	30	20	R	-	3	0	25	VG
20	Ptb	♂	9	38	30	B	-	4	1	35	G

GSD: German Shepherd Dog, Ptb: Pitbull, BM: Bernese Mountain, ASD: Anatolian Sheep Dog, Lab: Labrador, GR: Golden Retriever, Aust SD: Austrian Sheep Dog;

Pre-op LS: Preoperatively lameness score, Post-op LS: Postoperatively lameness score, FHT: Functional healing time;

L: left, R: right, B: bilateral;

VG: Very good, G: Good, MOD: Moderate

examination. On physical examination, mild/moderate muscular atrophy was noted particularly in dogs with unilateral lesion. Lameness was recorded to have lasted for an average of 35 days before the referral of the dogs to the clinic. All patients were admitted to the Surgery Clinic with unilateral forelimb lameness however; clinical and radiographic examinations revealed bilateral involvement in 6 cases (case numbers: 3, 6, 11, 14, 17 and 20).

The diagnosis was made based on radiographic findings in 16 patients, on arthroscopic findings in 2 (case numbers 4 and 5) and on computed tomographic findings in other 2 (case numbers 19 and 20) patients.

Radiographic Findings: Radiography revealed (Fig. 5, Fig. 6) subtrochlear notch sclerosis (Fig. 6b); osteophyte formations on the medial surfaces of epicondyles (Fig. 5a, thin white arrow) radial head and anconeus (Fig. 4b,c) and structural deformities on the medial coronoid process in most of the cases. Coronoid fracture was apparent in 16 (6 were bilaterally involved) out of 20 cases. Furthermore, UAP (Fig. 6) was diagnosed concurrently with FMCP in 4 cases (case numbers: 3, 7, 10, 17). Humeroulnar joint incongruence was detected in none of the cases.

Arthroscopic Findings: Arthroscopy revealed non displaced fragments and irregular fibrocartilagenous tissue in case number 4 and 5 (Fig. 3d).

Computed Tomographic Findings: Computed tomography showed heterogenous aspect of medial coronoid process with distinct rounded fragments in case number 19 (Fig. 2) and 20.

Average duration of preoperative lameness was 35 days whereas functional recovery period was recorded to be 31 days. Postoperative lameness scores on day 30 revealed 0 = no detectable lameness and 1 = mild weightbearing lameness in 12 and 8 cases, respectively. When the preoperative lameness and weight-bearing of extremities were compared with those of postoperative day 60; 6, 5 and 9 cases revealed excellent, good and moderate recovery, respectively.

DISCUSSION

Medial coronoid disease, is seen in middle or large breed dogs, especially younger individuals of these breeds. Clinical manifestations of Medial coronoid disease in dogs

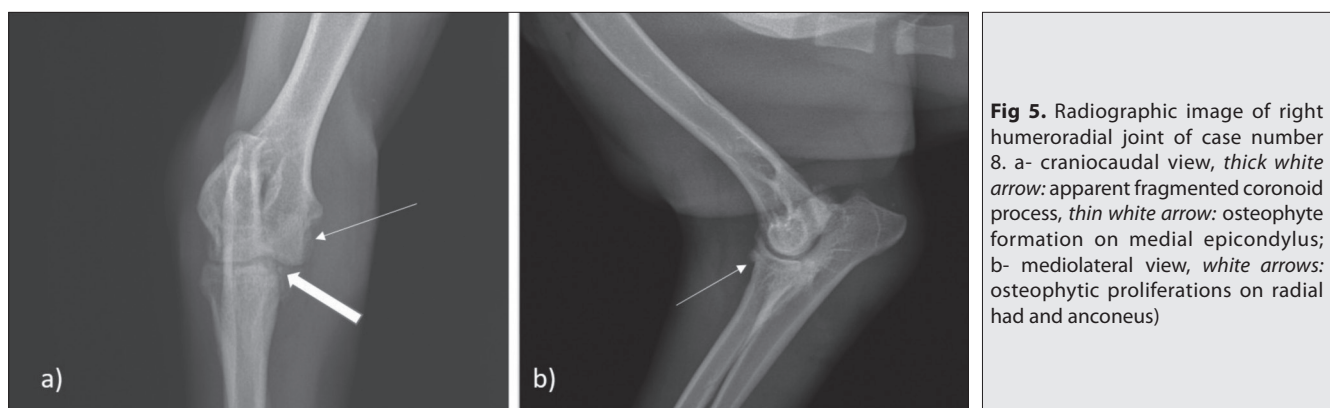


Fig 5. Radiographic image of right humeroradial joint of case number 8. a- craniocaudal view, *thick white arrow*: apparent fragmented coronoid process, *thin white arrow*: osteophyte formation on medial epicondylus; b- mediolateral view, *white arrows*: osteophytic proliferations on radial had and anconeus)

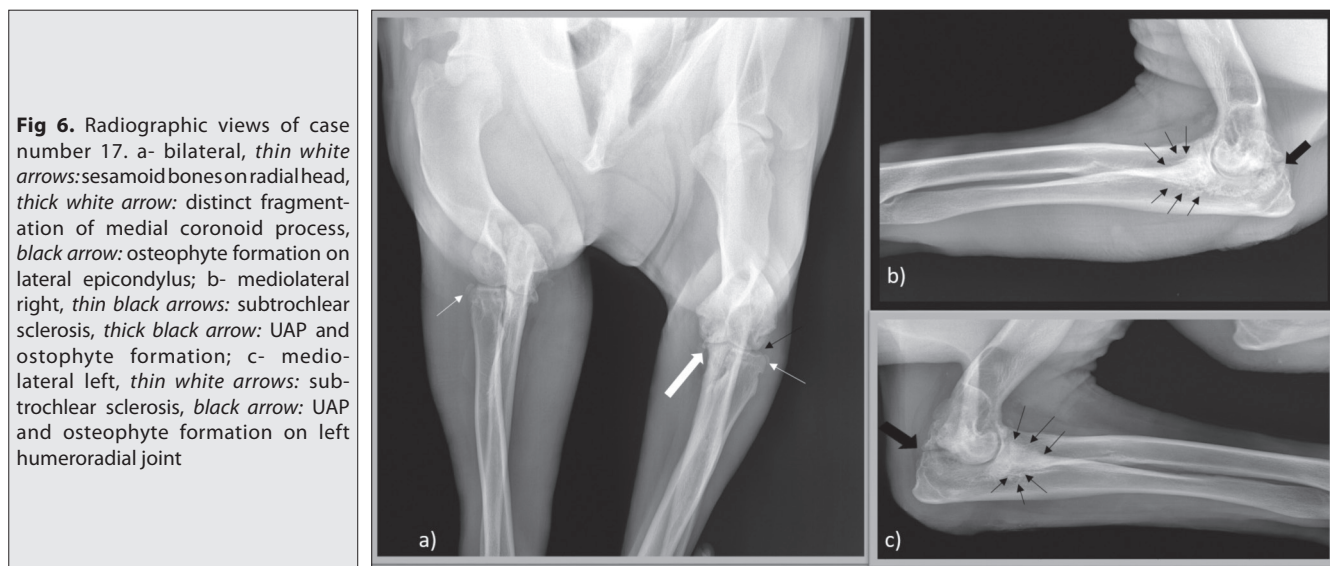


Fig 6. Radiographic views of case number 17. a- bilateral, *thin white arrows*: sesamoid bones on radial head, *thick white arrow*: distinct fragmentation of medial coronoid process, *black arrow*: osteophyte formation on lateral epicondylus; b- mediolateral right, *thin black arrows*: subtrochlear sclerosis, *thick black arrow*: UAP and osteophyte formation; c- mediolateral left, *thin white arrows*: subtrochlear sclerosis, *black arrow*: UAP and osteophyte formation on left humeroradial joint

most commonly occur at 4-8 months of age and in some occasions the disease was reported to have developed in adult animals (>6 years) [14]. Gender predilection was noted in males as 2 folds of the female individuals [3,9]. In this study, it is seen that all of the cases consisted of large breed dogs. Despite the lack of a study with respect to the prevalence of the disease in Anatolian Sheep Dogs, that the 2 out of 20 patients were of this breed was found to be noteworthy. When the age is evaluated in terms of age, two dogs were older (case number 11: 36 months old; case number 12: 4 months old) than the reported average age range which indicated that clinical signs might have occurred at later periods of life [14]. It was also determined that the incidence of MCD is higher in male dogs than in female dogs. Both breed type and age range at the onset of the disease were found to be consistent with the sources predominantly formed in male dogs [3,9,14].

In dogs with medial coronoid disease, variable lameness are marked by muscular atrophy due to degenerative lesions in the joint, as well as stiff and stilted gait. Reduced range of motion on hyperextension and hyperflexion of the radioulnar joint accompanied by pain [1]. Clinical examination findings of the cases showed that the

abnormal gait, muscle atrophy, decreased range of motion of the elbow joint were compatible with the other reports.

Periarticular osteophytosis was detected in all cases based on radiographic findings. Besides, medial coronoid process was morphologically detected however; percentage values of subtrochlear sclerosis and milimetric calculations of osteophyte depth [23,25] were unable to be assessed. Therefore, no correlation could be established between the preoperative subjective radiographic findings and functional recovery period or the postoperative outcome. Furthermore, no correlation was found between the duration of preoperative lameness and functional recovery period or postoperative outcome according to the postoperative patient owner's report.

Despite the surgical treatment of joint diseases, subsequent radiographic evaluation revealed that osteoarthritis was a progressive process and as it was already known that radiography alone was an inconclusive diagnostic tool in detecting the early pathologic changes of the joint, computed tomography and arthroscopy, in contrast, were most likely to have yielded more accurate results [10]. In this regard, however; relatively short-term monitoring of the

patients and the small number of the cases included were considered to be the limiting factors of the current study so as to judge the accuracy of these techniques.

Computed tomography is considered to be a more reliable diagnostic tool than the other imaging techniques. Standard transversal sequences obtained with computed tomography enable the coronoid process to be viewed without the negative impact of the images of superimposed adjacent bone tissue rendering this diagnostic tool a high sensitivity and specificity in the diagnosis of fragmented coronoid process [18,26]. Recently, the use of computed tomography has become increasingly widespread in veterinary practice and recent studies have shown that MCD might be detected as early as 14 weeks of age. In order to obtain the most effective results in the therapeutic approach, the lesions should be detected before severe osteoarthritis developed [18]. Therefore, we are in agreement with the argument that early orthopedic examination should be planned concurrently with the vaccination program being scheduled.

In the study, UAP was detected in 4 out of 20 cases on the same joint. Concurrent occurrence of FCP and UAP was reported to be a sporadic finding in the previous studies [7,19,27]. That UAP was detected in 4 cases in this study was considered to have pointed out the frequency of this entity unlike the reported studies [27]. Nevertheless, it was considered that concurrent occurrence of FCP and UAP might have demonstrated a negative impact on the functional recovery period and the outcome of the disease on the basis of the results obtained. Although UAP was reported to have most commonly encountered in German Shepherd dogs [27,28], that none of the cases with UAP in this study were of this breed was an intriguing finding.

The treatment of Medial Coronoid Disease includes conservative therapy or the surgical removal of the fragment by arthroscopy/arthrotomy. Certain authors suggested the superiority of arthroscopy in terms of the speed of the healing process and improved visualization over arthrotomy [10,29,30]. On the other hand, it was reported in recent studies with respect to objective evaluations by gait analysis (inverse dynamics and peak vertical forces, vertical impulse and goniometry) that arthroscopy revealed no superiority over medical therapy or arthrotomy [31]. In this study, removal of the fragmented or fissured portion and the debridement of the remnants from medial coronoid process were unable to be performed by arthroscopy due to the inadequacy of the technical equipment and the use of the technique was limited only to the full recognition of the lesion in 2 cases. Furthermore, the arthrotomy procedure was performed in almost the same time with minimal arthroscopy.

Recent studies showed that local abnormal loading forces resulted in the pathologic lesions of medial coronoid process. Different methods of ulnar osteotomy were

suggested for the treatment [20-23]. Humeroulnar joint non-conformity was detected in none of the cases, therefore proximal ulnar osteotomy or bioblique dynamic ulnar osteotomy was not considered along with the removal of the fragmented portion.

Although periarticular degenerative changes developed in all cases, the lameness score on day 30 was reported to be 0 in 12 cases, which was considered to be associated with the relief of pain in the joint after the removal of the intraarticular fragments. The score of 1 in 8 cases in the early postoperative period was considered to have resulted from the severity of the articular damage.

In conclusion, clinical improvement was achieved in the dogs with the lesions due to medial coronoid disease by the aid of a proper therapeutic approach.

REFERENCES

- Boulay JP:** Fragmented medial coronoid process of the ulna in the dog. *Vet Clin North Am: Small Anim Pract*, 28 (1): 51-74, 1998. DOI: 10.1016/S0195-5616(98)50004-6
- Fitzpatrick N, Smith TJ, Evans RB, Yeardon R:** Radiographic and arthroscopic findings in the elbow joints of 263 dogs with medial coronoid disease. *Vet Surg*, 38, 213-223, 2009. DOI: 10.1111/j.1532-950X.2008.00489.x
- Morgan JP, Wind A, Davidson AP:** Hereditary bone and joint diseases in the dog: Osteochondroses, hip dysplasia, elbow dysplasia. 77-78, Hannover: Schlütersche GmbH&Co. KG, 2000.
- Temwichitr J, Leegwater PAJ, Hazewinkel HAW:** Fragmented coronoid process in the dog: A heritable disease. *Vet J*, 185 (2): 123-129. 2010. DOI: 10.1016/j.tvjl.2009.06.022
- Wavreille V, Fitzpatrick N, Drost WT, Russell D, Allen MJ:** Correlation between histopathologic, arthroscopic, and magnetic resonance imaging findings in dogs with medial coronoid disease. *Vet Surg*, 44 (4): 501-510, 2015. DOI: 10.1111/j.1532-950X.2014.12233.x
- Gemill TJ, Clements DN:** Fragmented coronoid process in the dog: Is there a role for incongruity? *J Small Anim Pract*, 48, 361-368, 2007. DOI: 10.1111/j.1748-5827.2007.00320.x
- Grøndalen J, Grøndalen T:** Arthrosis in the elbow joint of young rapidly growing dogs. V. A pathoanatomical investigation. *Nord Vet Med*, 33 (1): 1-16, 1981.
- Lau SF:** Development of medial coronoid disease in Labrador retrievers: Diagnostic and pathologic studies. *PhD Thesis*, Utrecht University, Netherlands, 2013.
- Griffon DJ:** Surgical diseases of the Elbow. In, Tobias MK, Johnston AS (Eds): *Veterinary Surgery Small Animal*. 736-749, Saunders, Missouri, 2012.
- Coppieters E, Seghers H, Verhoeven G, Gielen I, Samoy Y, De Bakker E, Van Ryssen B:** Arthroscopic, computed tomography, and radiographic findings in 25 dogs with lameness after arthroscopic treatment of medial coronoid disease. *Vet Surg*, 45, 246-253, 2016. DOI: 10.1111/vsu.12443
- Hazewinkel HAW, Meij BP, Theyse LFH:** Surgical treatment of elbow dysplasia. *Vet Q*, 20 (Suppl.1): 29-31, 1998.
- Michelsen J:** Canine elbow dysplasia: Aetiopathogenesis and current treatment recommendations. *Vet J*, 196 (1): 12-19, 2013. DOI: 10.1016/j.tvjl.2012.11.009
- Olsson SE:** The early diagnosis of fragmented coronoid process and osteochondritis dissecans of the canine elbow joint. *J Am Anim Hosp Assoc*, 19, 616-626, 1983.
- Vermote KAG, Bergenhuyzen ALR, Gielen I, van Bree H, Duchateau L, Van Ryssen B:** Elbow lameness in dogs of six years and older: Arthroscopic and imaging findings of medial coronoid disease in

51 dogs. *Vet Comp Orthop Traumatol*, 23 (1): 43-50, 2010. DOI: 10.3415/Vcot-09-03-0032

15. Narojek T, Fiszdon K, Hanyzs E: Canine elbow dysplasia in different breeds. *Bull Vet Inst Pulawy*, 52, 169-173, 2008.

16. Cook CR, Cook JL: Diagnostic imaging of canine elbow dysplasia: A review. *Vet Surg*, 34 (2): 144-153, 2009. DOI: 10.1111/j.1532-950X.2008.00481.x

17. Franklin SP, Burke EE, Holmes SP: Utility of MRI for characterizing articular cartilage pathology in dogs with medial coronoid process disease. *Front Vet Sci*, 4 (25): 1-9, 2017. DOI: 10.3389/fvets.2017.00025

18. Lau SF, Wolschrijn CF, Hazewinkel HAW, Siebelt M, Voorhout G: The early development of medial coronoid disease in growing Labrador retrievers: Radiographic, computed tomographic, necropsy and micro-computed tomographic findings. *Vet J*, 197, 724-730, 2013. DOI: 10.1016/j.tvjl.2013.04.002

19. Carpenter LG, Schwarz PD, Lowry JE, Park RD, Steyn PF: Comparison of radiologic imaging techniques for diagnosis of fragmented medial coronoid process of the cubital joint in dogs. *J Am Vet Med Assoc*, 203 (1): 78-83, 1993.

20. Caron A, Fitzpatrick N: Bi-Oblique dynamic proximal ulnar osteotomy: Surgical technique and clinical outcome in 86 dogs. *Vet Surg*, 45 (3): 356-363, 2016. DOI: 10.1111/vsu.12464

21. Ness MG: Treatment of fragmented coronoid process in young dogs by proximal ulnar osteotomy. *J Small Anim Pract*, 39, 15-18, 1998. DOI: 10.1111/j.1748-5827.1998.tb03663.x

22. Puccio M, Marino DJ, Stefanacci JD, McKenna B: Clinical evaluation and long term follow-up of dogs having coronoidectomy for elbow incongruity. *J Am Anim Hosp Assoc*, 39 (5): 473-478, 2003. DOI: 10.5326/0390473

23. Fitzpatrick N, Caron A, Solano MA: Bi-oblique dynamic proximal ulnar osteotomy in dogs: Reconstructed computed tomographic assessment of radioulnar congruence over 12 weeks. *Vet Surg*, 42 (6): 727-738, 2013. DOI: 10.1111/j.1532-950X.2013.12014.x

24. Cogar SM, Cook CR, Curry, SL, Grandis A, Cook JL: Prospective

evaluation of techniques for differentiating shoulder pathology as a source of forelimb lameness in medium and large breed dogs. *Vet Surg*, 37 (2): 132-141, 2008. DOI: 10.1111/j.1532-950X.2007.00364.x

25. Hazewinkel HAW: Elbow dysplasia: Introduction, clinical investigation and force plate evaluation. *International Elbow Working Group Annual Meeting WSAVA Congress*, Bangkok Thailand. 2015. <http://www.vet-iewg.org/wp-content/uploads/2017/02/proceedings2015.pdf>, Accessed: 10.10.2017.

26. Villamonte-Cevalier A, Van Bree H, Broeckx BJG, Dingemans W, Soler M, Van Ryssen B, Gielen I: Assessment of medial coronoid disease in 180 canine lame elbow joints: A sensitivity and specificity comparison of radiographic, computed tomographic and arthroscopic findings. *BMC Vet Res*, 11, 243, 2015. DOI: 10.1186/s12917-015-0556-9

27. Meyer-Lindenberg A, Staszuk C, Gasse H, Fehr M, Nolte I: Caudomedial approach for removal of an ununited anconeal process and assessment of the medial coronoid process of the ulna. *J Vet Med A Physiol Pathol Clin Med*, 49 (5): 277-280, 2002. DOI: 10.1046/j.1439-0442.2002.00421.x

28. Meyer-Lindenberg A, Fehr M, Nolte I: Co-existence of ununited anconeal process and fragmented medial coronoid process of the ulna in the dog. *J Small Anim Pract*, 47 (2): 61-65, 2006. DOI: 10.1111/j.1748-5827.2006.00051.x

29. Meyer-Lindenberg A, Langhann A, Fehr M, Nolte I: Arthrotomy versus arthroscopy in the treatment of the fragmented medial coronoid process of the ulna (FCP) in 421 dogs. *Vet Comp Orthop Traumatol*, 16 (4): 204-210, 2003. DOI: 10.1055/s-0038-1632780

30. Evans RB, Gordon-Evans WJ, Conzemius MG: Comparison of three methods for the management of fragmented medial coronoid process in the dog. A systematic review and meta-analysis. *Vet Comp Orthop Traumatol*, 21, 106-109, 2008.

31. Galindo-Zamora V, Dziallas P, Wolf DC, Kramer S, Abdelhadi J, Lucas K, Nolte I, Wefstaedt P: Evaluation of thoracic limb loads, elbow movement, and morphology in dogs before and after arthroscopic management of unilateral medial coronoid process disease. *Vet Surg*, 43 (7): 819-828, 2014. DOI: 10.1111/j.1532-950X.2014.12250.x