

EFFECT OF TOPICAL KEFIR APPLICATION ON OPEN WOUND HEALING: AN IN VIVO STUDY

Gültekin ATALAN* İbrahim DEMİRKAN* Hilmi YAMAN**
 Mete CİHAN* Feyyaz ÖNDER*** Mahmut SÖZMEN****

Geliş Tarihi : 24.03.2003

Summary: In this study, based on the rabbit model it was aimed to investigate the effect of kefir on open wound healing. Twelve rabbits (5 males and 7 females) were used and allocated to two groups, each consisted of 6 rabbits. Group I corresponded kefir application group whereas Group II served as control population. A square shaped skin plug (1.5x1.5 cm) was removed from two cm lateral to dorsal aspect of the thoracic spine on the left side for each rabbit. Alterations in blood leukocyte were measured at four days intervals until 20 days for both groups. Vaseline was only applied to the Group II whereas a mixture of vaseline and kefir was applied to the Group I animals until their wound healed. After healing, skin samples were taken for histopathological examination from the all rabbits.

The observation of the wound healing revealed that the Group I had a quicker healing than Group II. At the third week examination, all rabbits in Group I and 3 in Group II displayed a complete wound healing. The histopathological examination made on healed wound indicated that both groups displayed complete epithelisation. In group I, there was capillary hyperaemia, epithelial acantosis and eosinophiles in the examined tissues. However, in Group II, there was a mild capillary hyperemia without eosinophiles. There were also some area of necrosis with pycnosis and karyorrhexis. Leukocyte numbers were detected to rise following 4th day of the surgery. On the 12, 16 and 20th days, there was statistically a non-significant difference in the leukocyte numbers between both groups despite a slight rise for the Group II.

It was concluded that kefir pomade could promote the wound healing.

Key Words: Kefir, Wound healing, Rabbit.

Kefir Uygulamasının Açık Yara İyileşmesi Üzerine Etkisi: İn Vivo Bir Çalışma

Özet: Bu çalışmada, tavşan modeli kullanılarak, kefirin açık yara iyileşmesi üzerine olan etkisi araştırıldı. Beş erkek ve 7 dişi olmak üzere toplam 12 adet tavşan altışarlı olmak üzere iki gruba ayrıldı. Birinci Grup tavşanlar kefir uygulanan grubu, II. Gruptakiler ise kontrol grubunu oluşturmak üzere gruplandırıldılar. Her bir tavşan için sol toraksta dorsal median hattın 2 cm distalinde, 1.5x1.5 cm boyutlarında kare şeklinde bir deri alanı uzaklaştırıldı. Yara oluşturulmasını takiben her iki grup tavşan için 4 günde bir olmak üzere 20. güne kadar kan lökosit değişimleri saptandı. Vazelin ve kefir karışımından oluşan pomat I. Grup hayvanlara yaraları iyileşinceye kadar uygulandı. II. Grup tavşanlara ise sadece vazelin uygulandı. Yaraların iyileşmesinden sonra deri örneklerinin histopatolojik muayenesi yapıldı.

Yara iyileşmesi üzerine yapılan gözlemler, I. Grup tavşanların Grup II'ye göre daha kısa sürede iyileştiğini gösterdi. I. Gruba ait tavşanların tamamı üçüncü haftada tam bir yara iyileşmesi gösterirken, II. Gruba ait tavşanların yalnızca 3'ünde tam bir iyileşme not edildi. İyileşmiş yaraların histopatolojik muayeneleri her iki gruba da tam bir epitelizeasyon ortaya çıkardı. Bununla beraber, I. Grup tavşanlarda kapillar damarların eritrositlerle dolgunluğu, epitelyal akantosis ve eosinofilia tablosu gözlenirken II. Grup tavşanlarda, orta derecede kapillar hiperemi saptandı. Bu grup tavşanlarda eosinofilia bulgusu olmaksızın, deri örneklerinin bazı bölgelerinde piknosis, karyoreksis ve nekroz bulguları belirlendi. Lökosit sayılarının deri ensizyonunu takiben her iki grup için de 4. günde arttığı tespit edildi. 12, 16 ve 20. günlerde II. Grup hayvanlarda lökosit sayılarında yükselme olmasına karşılık, istatistiksel olarak her iki grup hayvanda önemli bir farklılık yoktu.

Kefirli pomat uygulamasının yara iyileşmesi üzerine olumlu yönde bir etki sağladığı sonucuna varıldı.

Anahtar Sözcükler: Kefir, Yara iyileşmesi, Tavşan.

INTRODUCTION

Generally, the skin may be injured in many ways such as trauma, surgery, and noxious stimulus including excessive heat or cold, chemicals, irradiation, infection, and neoplasia¹. A wide spectrum of biological events occur following tissue injury. Both structural and functional normality to scar formation or the persistence of the inflammatory process take for weeks, months or years².

Wound healing, a biological and functional restoration of organ injuries and characterized by cellular and metabolic processes that occur in a

relatively constant sequence³, can occur via several pathways including first intention healing (closure of the wound by sutures, staples, or tape), second intention healing (granulation, epithelisation, and contraction) and third intention healing (secondary wound closure using sutures or staples)¹. This process follows a certain pattern that may continue for months³.

Treatment of wound includes removal of necrotic tissues and lavage, local and/or systemic application of antimicrobial agents, surgical closure of wound, dressing, drainage and replacement of missing factors (vitamins, minerals, and fluids)^{3,4}.

Bio-substances such as collagen gels and spongy matters have been reported to be useful in wound management⁴⁻⁷. In addition, insulin⁸, chitin and chitosan⁹ have been reported to be effective on wound healing.

Kefir is obtained from kefir grains through fermentation that contain proteins and polysaccharides¹⁰. Kefir microflora possesses yeast, lactic acid bacteria, and acetic acid bacteria such as *Saccharomyces*, *Candida*, *Kluyveromyces*, *Lactobacillus*, *Lactococcus*, *Leuconostoc*, and *Acetobacter*¹¹⁻¹³. Kefir has been used for centuries for the treatments of gastrointestinal and metabolic disorders, atherosclerosis, allergic diseases, tuberculosis and neoplastic disease. Additionally, kefir displays an immune modulator role (stimulation of immune system)¹⁴⁻¹⁶. Antibacterial and antifungal effects of the kefir have also been well documented^{17,18}.

Usage of kefir for the treatment of open wound, to our knowledge, has been poorly documented. Therefore, in this *in vivo* study it was aimed to evaluate the healing process of experimentally induced wound by topical kefir application in rabbits.

MATERIALS and METHODS

Animals: A total of 12 (5 male and 7 female) cross-bred rabbits were included in the study. Prior to the study, animals were checked for their health status. They were allocated to two groups. Group I had 1 male and 5 female whereas Group II consisted of 2 female and 4 male rabbits. The average age was 8 months in both groups. The body weight was measured between 2.3 and 3.2 kg (average 2.8 kg) in Group I and between 2 and 3 kg (average 2.7 kg) in Group II. The Group II served as Control Group in which vaseline alone was applied.

Conduction of wound area: Animals were premedicated with intramuscular administration of xylazine HCl (Rompun 2%, Bayer) as a dose of 5 mg/kg body weight. An area sized 5x5 cm, two cm lateral to dorsal aspect of the left thoracic spine was clipped, shaved and prepared for aseptic surgery. The area was locally anaesthetised with 1 ml of 2% lidocaine (Adokain, Sanovel, Turkey). Full thickness of skin (1.5x1.5 cm) was resected from the thoracodorsal site on one side of the midline by means of a sharp sterile scalpel.

Preparation of kefir pommade: Kefir granules were obtained from division of milk technology, Ege University, Izmir, Turkey. The pommade was made

evenly mixing equal amount of kefir granules and vaseline, and stored at +4 °C until used.

Treatment protocols: In Group II, the wound was topically spread with vaseline alone daily for 28 days. In Group I, kefir pommade was applied to the wound as a thin layer once a day until satisfactory scar tissue developed. Dressing was practiced to protect the wound from inflictions by animal itself or by other animals. Development of wound healing was also evaluated daily.

Laboratory analyses: Blood samples (approximately 1 ml) from vena auricularis externa were obtained to examine the changes in total leukocytes status. The samples were taken every 4 days until the 20th day (a total of 5 samplings). For histopathological examination tissue samples were taken after granulation tissues completed. The specimens were fixed in 10% formalin saline, embedded in paraffin, cut into 5 µm thick sections, and stained with hematoxylin-eosin.

Evaluation of wound healing status: The healing status of wounds was performed by macroscopic and microscopic examinations. Macroscopically, the wound were evaluated for the presence of granulation tissues, its size, the status of infection and complete healing time. Histopathological changes were assessed with a light microscope.

Statistical analyses: Using *Student-t test*, changes in leukocytes counts were compared between day 0 and others (4, 8, 12, 16 and 20th days) using Minitab Statistical Package Program (Pennsylvania State University).

RESULTS

Clinical Assessment: On day 4 following the wound creation (first examination), the wound was contaminated in all animals, appeared to be edematous in nature, red in color and suppurated in character with accompanying copious amount of exudates.

On day 8, infection of the wound in Group II persisted while there was a slight dryness on the wound surfaces (crusty appearance) of 3 rabbits. However in Group I granulation tissue developed in 3 rabbits and the infection was regressed in remaining 3 rabbits. A typical centrifugal granulation tissue formation was observed (from central aspect of the wound towards periphery).

On day 12, in Group II four rabbits showed evidence of infection in spite of a slight granulation

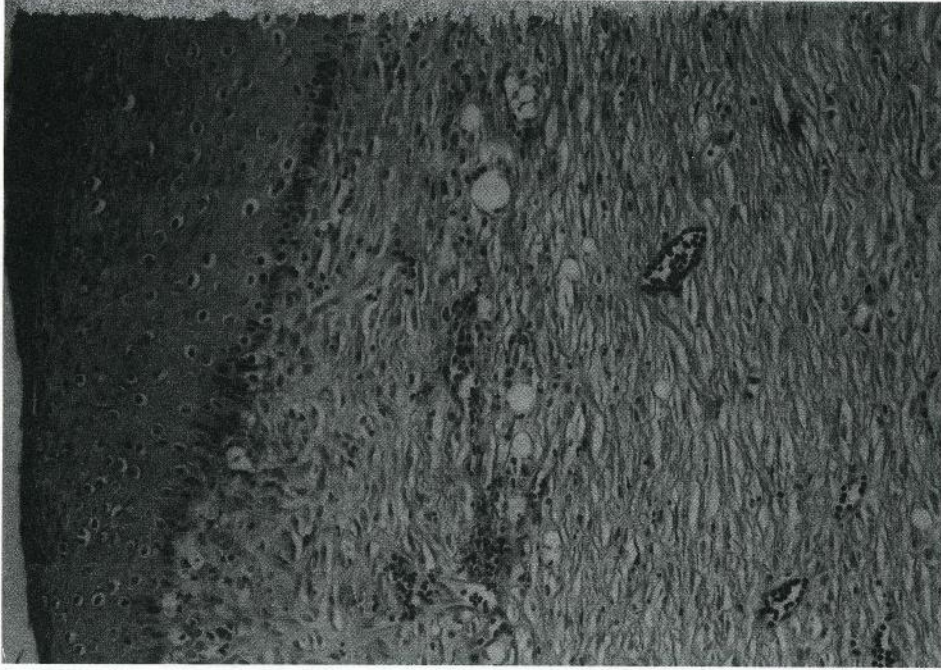


Figure 1. Histopathologic appearance of a group I rabbit skin after wound healing. Capillary vessels filled with erythrocytes. Slight subepidermal leukocyte infiltration is present. Notice the epithelial acanthosis and eosinophilia (HEX200).

Resim 1. Yara iyileşmesini takiben, I. grup bir tavşan derisinin histopatolojik görünümü. Kapillar damarlar eritrositlerle dolu olarak görünüyor. Hafif subepidermal lökosit infiltrasyonları mevcut. Epitelyal akantosis ve eosinofiliya belirgin olarak göze çarpmakta.

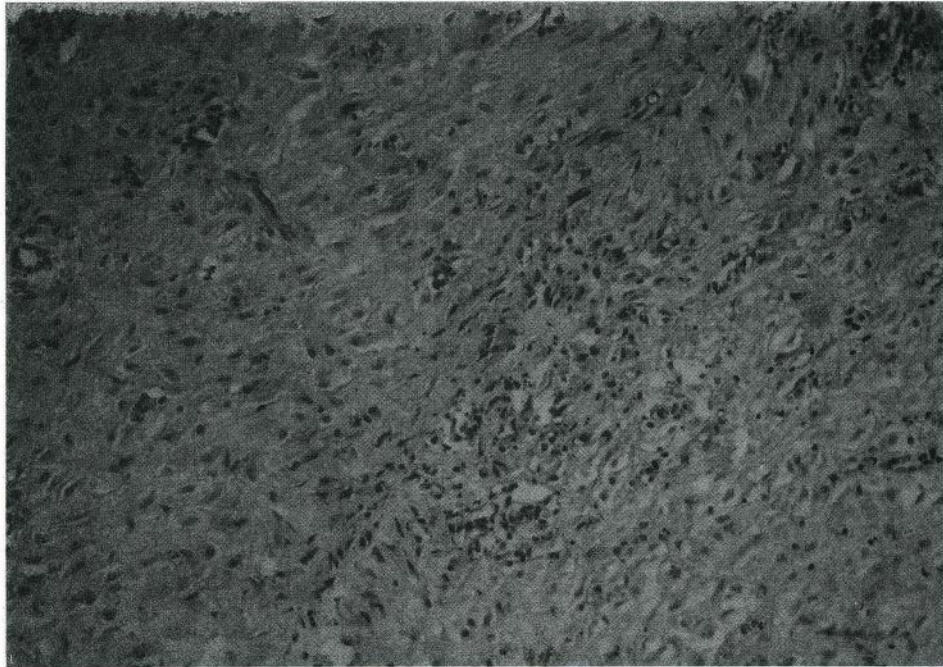


Figure 2. Histopathologic appearance of a group II rabbit skin after wound healing. Capillary hyperemia. Moderate leukocyte infiltration without eosinophils and areas with necrosis. Notice pyknosis and karyorrhexis (HEX200).

Resim 2. Yara iyileşmesi sonrası, grup II'deki bir tavşan derisinin histopatolojik görünümü. Orta derecede kapiller hiperemi. Eosinofiliya görülmezsizin orta derecede lökositosis ile birlikte nekrozlu bölgeler göze çarpmakta. Piknosis ve karyoreksis varlığı izlenmekte.

Table 1. Average leukocyte counts of the rabbits in groups I and II until 20 days after wound creation.
Tablo 1. Yara oluşturulmasını takiben 20. güne kadar I ve II. grup tavşanlara ait ortalama lökosit sayıları.

Days	Group II						Group I					
	0	4	8	12	16	20	0	4	8	12	16	20
Leukocyte Counts (x±sem)	52	69*	70*	64	62	58	53	72*	57	54	52	54
	±3.02	±3.79	±4.81	±4.22	±4.42	±4.64	±3.93	72±7.86*	±4.72	±4.45	±3.48	±4.80

Statistical analyses were performed by the comparison of day 0 with the data obtained from the days of 4, 8, 12, 16 and 20.
*: P<0.05, x: mean, sem: Standart error mean

tissue formation, whereas 2 rabbits displayed moderate granulation formation without infection.

However, in Group I, all wounds became smaller than group I with a complete epithelisation except for central area.

At the 3rd week, almost all rabbits showed no evidence of infection in Group I. Completed wound healing with a visible scar was observed. However in group II at the end of 28 day (last examination) 3 rabbits showed complete wound healing whereas remaining 3 still had a mild infection.

Laboratory Findings

Histopathological findings: Skin sections from completely healed wound showed a full epithelization for the both groups. In dermis, the fibroblasts were horizontally extended together with connective tissue proliferation. There was an increase in the numbers of collagen bands and capillary vessels (Figure 1). Around the capillaries infiltration of mononuclear cells, eosinophils and lymphocytes were notable (Figure 2). However eosinophil leukocyte infiltration was more evident in Group I than in Group II. No hair follicles and skin appendages were seen in fibroblastic tissues. In Group I the surface of the granulation was covered by a thick epithelial layer. The granulation tissue had abundant neovascularization.

Hematological analysis: Average leukocyte counts at day 0, 4, 8, 12 and 20 are summarized in Table 1. On day 4, leukocyte count showed a statistically significant increase in Group II in comparison to day 0 (p<0.05). But this value was more emphasized in Group I (p<0.05). This trend continued in Group II (p<0.05), not in Group I on day 8. There was still an increase in Group II during the 12, 16 and 20th days although it was not statistically significant. The number of leukocyte was found to be in normal range in group I between 8 and 20 days.

DISCUSSION

The kefir group, histologically, reconstituted

normal tissue earlier than the non-kefir group.

Previously it was reported that kefir has a paramount antibacterial effects on saprophytes and pathogenic microorganisms^{11,19}. This may be the reason that kefir further protect the wound from bacterial growth.

Blood and histological analyses demonstrated that the number of eosinophils was high in Group I. It could be due to foreign substance effect of kefir. When leukocyte count was compared there was an increase in Group II not in Group I especially till 8th day of the treatment. Because the infection was more pronounced in Group II than Group I that indicates the antibacterial effect of kefir.

Wounds caused by various offending agents in domesticated and wild animals are common. These injuries are normally treated by control of hemorrhagia, debridement and removal of the necrotic tissues, local antiseptic application, drainage, dressing and administration of local and systemic antimicrobial agents^{1,3}. In the present study, none of the above mentioned methods were performed in order to reveal local effect of kefir. As an alternative medicine, pure honey²⁰, chitin and chitosan⁹, collagen gel and membrane^{6,21}, sponges^{4,5}, normal gelatin⁷ were reported to positively effect wound healing by encouraging angiogenesis and epithelisation, or increasing the contraction of wound edges. Some proteolytic enzymes such as trypsin are released from damaged cells or leukocytes and are involved in cell mobilization during the epithelisation phase. After mobilization, epithelial cells enlarge and begin to migrate down and across the wound²². No other effects of kefir to treat wound rather than antimicrobial effect have been reported. But, kefir might have induced the similar biological effect for the healing.

When a full-thickness portion of skin lost, the wound edges initially retract, enlarging the wound. A fibrin clot is formed over the wound surface by the immediate exudation of blood and tissue fluids. The clot dehydrates, forming a scab. Leukocytes and

macrophages move into the wound to remove debris²³. Initially, the predominant cell is the polymorph nuclear (PMN) leukocytes, whose primary role is destruction of bacteria. As PMNs degenerate and die, their outer membranes rupture and release enzyme-containing granules. These enzymes are released and attack extracellular debris. In clean wounds, PMNs are soon superseded by monocytes²⁴. In our study, leukocytes numbers predominated in Group II than Group I indicating pronounced bacterial involvement in non-kefir group, not in kefir group. This shows that kefir may enhance the activity of PMN at the site of infection.

The present study indicated that kefir improved the wound between 14 to 21 days and a similar result was obtained when pure honey was used²⁰. The healing period varies, for example in cats using insulin, the wound healed within 6-9 days⁸, in dogs using chitosan healing took place approximately 28 days⁹ and using collagen membrane in horses had effect in 43 days²¹. Our results appear to be superior to chitosan and collagen membrane application although animals used in these studies were from different species. This may affect the healing process since each species has unique immunological response against infections.

The interaction of local antimicrobial agents when used with kefir has not been determined. Further study is required to reveal this interaction.

The present study suggests that Kefir, a probiotic, can safely be used in open wounds without any side effects. It is also cheap and does not necessitate complicated preparation process. In addition, contamination of meat with antibiotics is a great concern in terms of human consumption. Therefore, findings of the study further recommend that the treatment of open wound infections with kefir may be used without any concern in livestock

REFERENCES

- 1 **Harari J:** Wound Healing. In: Harari J (Ed): Small Animal Surgery. Waverly Co, Baltimore, pp. 33-38, 1996.
- 2 **Woolf N:** The natural history of acute inflammation I: Healing. In: Johnston DE (Ed): Cell, Tissue and Disease, The Basis of Pathology. Second Ed. Bailliere Tindal, London, pp. 80-97, 1988.
- 3 **Probst CW:** Wound healing and specific tissue regeneration. In: Bednarski RM (Ed): Textbook of Small Animal Surgery R.M. Second Ed. WB Saunders Co, London, pp. 53-62, 1993.
- 4 **Chvapil M, Chvapil TA, Owen, JA:** Comparative study of four wound dressings on epithelization of partial-thickness wounds in pigs. *J Trauma*, 27: 278-282, 1987.
- 5 **Chvapil M, Holubec H, Chvapil T:** Inert wound is not desirable. *J Surg Res*, 51: 245-252, 1991.
- 6 **Pandit A, Ashar R, Feldman D, Thompson A:** Investigation of acidic fibroblast growth factor delivered through a collagen scaffold for the treatment of full-thickness defects in a rabbit model. *Plast Reconstr Surg*, 101: 766-775, 1998.
- 7 **Ulubayram K, Çakar A, Korkusuz P, Ertan C, Hasircı N:** EGF containing gelatin-based wound dressings. *Biomaterial*, 22: 1345-1356, 2001.
- 8 **Koç B, Özaydın İ, Özba B, İnsaldı E, Okumuş Z:** Doku kayıplı-gangrenli açık yaralarda lokal insulin ve pinch greft uygulamaları ile iyileşmenin hızlandırılması üzerine klinik gözlemler. 2. Ulusal Veteriner Cerrahi Kongresi. Mersin/Alata, 61, 1990.
- 9 **Okamoto Y, Shibasaki K, Minami S, Matsubashi A, Tanioka S, Shigemasa Y:** Evaluation of Chitin and Chitosan on open wound healing in dogs. *J Vet Med Sci*, 57: 851-854, 1995.
- 10 **Abraham AG, De Antoni GL:** Characterization of kefir grains grown in cow's milk and Soya milk. *J Dairy Res*, 66: 327-335, 1999.
- 11 **Angulo L, Lopez E, Lema C:** Microflora present in kefir grains of the Galician Region (North-West of Spain). *J Dairy Res*, 60: 263-267, 1993.
- 12 **Kosikowsky F:** Cheese and fermented milk foods. In: Kosikowski F (Ed): Fermented Milk Foods. 2nd Ed. Kosikowski and Associates, New York, 1982.
- 13 **Toba T:** Fermented milks produced with mesophilic acid bacteria: kefir Scandinavian ropy sour milk. *Jap Dairy Food Sci*, 36: 235-244, 1987.
- 14 **Hosono A, Tanabe T, Otani H:** Binding properties of lactic acid bacteria isolated from kefir milk with mutagenic amino acid pyrolyzates. *Milchwissenschaftliche*, 45: 647-651, 1990.
- 15 **Murofushi M, Shiomi M, Aibara K:** Effect of orally administered polysaccharide from kefir grain on delayed-type hypersensitivity and tumor growth in mice. *Jap Med Scien*, 36: 49-53, 1983.
- 16 **Osada K, Nagira K, Teruya K, Tachibana H, Shirahata S, Murakami H:** Enhancement of interferon production with sphingomyelin from fermented milk. *Biotherapy*, 7: 115-123, 1994.
- 17 **Saloff-Coste CJ:** Kefir: Nutritional and health benefits of yogurt and fermented milks. Danone World Newsletter, 11:1-7, 1996.
- 18 **Zacconi C, Parisi PG, Sarra P, Dallavalle P, Botazzi V:** Competitive exclusion of Salmonella kedougou in kefir fed chicks. *Microbiol Aliment Nutr*, 12: 387-390, 1995.
- 19 **Schillinger V:** Bacteriocins of lactic acid bacteria. In: Bills DD, Kung S (Eds): Biotechnology and Food Safety. Butterworth-Heinemann, Boston, Mass, pp. 55-79, 1990.
- 20 **Oryan A, Zaker SR:** Effects of topical application of honey on cutaneous wound healing in rabbits. *Zentralbl Veterinarmed*, 45: 181-188, 1998.
- 21 **Yvorchuk K, Gaughan E, Guy ST, Frank R:** Evaluation of a porous bovine collagen membrane bandage for management of wounds in horses. *Am J Vet Res*, 56: 1663-1667, 1995.
- 22 **Johnston DE:** The processes in wound healing. *Am An Hos Assoc*, 13: 186-189, 1977.
- 23 **Ross R:** The fibroblast and wound repair. *Biologic Review*, 43: 51-55, 1968.
- 24 **Silver IA:** Basic physiology of wound healing in the horse. *Equine Vet J*, 14: 7-10, 1982.