

# Unilateral Renal Agenesis in an Aged Dog with Severe Urine Accumulation and Urinary Tract Infection

Akiko UEMURA <sup>1,a</sup>  Ryou TANAKA <sup>1,b</sup> 

<sup>1</sup> Department of Veterinary Surgery, Faculty of Veterinary Medicine, Tokyo University of Agriculture and Technology, 3-5-8 Saiwaicho, Fuchu, Tokyo 183-8509, JAPAN

<sup>a</sup> ORCID: 0000-0003-2671-5074; <sup>b</sup> ORCID: 0000-0001-9948-6490

Article Code: KVFD-2017-18665 Received: 30.08.2017 Accepted: 17.10.2017 Published Online: 20.10.2017

## Citation of This Article

Uemura A, Tanaka R: Unilateral renal agenesis in an aged dog with severe urine accumulation and urinary tract infection. *Kafkas Univ Vet Fak Derg*, 24 (1): 153-157, 2018. DOI: 10.9775/kvfd.2017.18665

## Abstract

A 7-year-old intact female Large Münsterländer developed abdominal distention. Computed tomography showed absence of the right kidney and ureter, marked hydronephrosis, and left ureter dilatation. Five years later, the patient was hospitalized as an emergency. Diagnostic imaging showed a >350-mm-diameter cyst communicating with the left kidney displacing the abdominal organs, another approximately 150-mm-diameter cyst in the right kidney position, and marked parenchymal thinning of the left kidney. At laparotomy, a left kidney nephrostomy was established; 8.230 mL of urine were drained with paracentesis. There was no ureter connecting the left kidney and bladder, but an enlarged, ureterocele-like, tubular organ connected the left kidney to a urine-containing cyst on the right side. A short, tubular organ connected the urine-containing cyst on the right side with a bladder-like organ, but it showed almost no urine accumulation. Urine cultures tested positive for *Klebsiella pneumoniae*. Postoperatively, the patient was discharged after four days. This is the first case about unilateral renal agenesis (URA) in an aged dog. Some dogs may have undiagnosed URA. When URA manifests after a dormant period, cases may be severe, with total loss of appetite, abdominal distension, elevated inflammatory markers, and cyst-like phenomena on abdominal ultrasonography. In such cases, URA must be considered in the differential diagnosis.

**Keywords:** Unilateral renal agenesis (URA), Aged dog, Urine accumulation, Urinary tract infection

## Yaşlı Bir Köpekte Şiddetli İdrar Birikmesi ve İdrar Yolu Enfeksiyonu İle Birlikte Unilateral Renal Agenesis

## Özet

Yedi yaşında dişi Büyük Münsterländer köpekte abdominal şişkinlik gelişti. Bilgisayarlı tomografide sağ böbrek ve üreter mevcut olmayıp şiddetli hidronefroz ve sol üreterde dilatasyon gözlemlendi. Beş yıl sonra, hasta acilde hastaneye alındı. Tanısal görüntüleme >350mm çapında sol böbrek ile temasta olup abdominal organların yerini değiştiren bir kist ile yaklaşık 150 mm çapında sağ böbrek hizasında bir kist ile sol böbreğin parankiminde belirgin bir inceleme tespit edildi. Laparotomide sol böbrek nefrostomisi uygulandı ve 8.230 mL idrar parasentez sırasında drene edildi. Sol böbreği idrar kesesine bağlayan bir üreter bulunmaması birlikte sol böbreği sağ tarafta idrar içeren bir kiste bağlayan genişlemiş üreterosel benzeri tübüler bir organ gözlemlendi. Sağ tarafta idrar içeren kist ile idrar kesesi benzeri organı bağlayan kısa tübüler bir organ mevcut olup neredeyse hiç idrar toplanması bulunmamaktaydı. İdrar kültürü testi *Klebsiella pneumoniae* için pozitif sonuç verdi. Postoperatif olarak hasta dört gün sonra taburcu edildi. Bu vaka takdimi yaşlı bir köpekte unilateral renal agenezis (URA) için ilk sunum olma özelliği taşımaktadır. Bazı köpeklerde tanı konulmamış URA bulunabilir. Dormant dönemi sonrası URA belirince vakalar iştah kaybı, abdominal şişkinlik, artmış yangısal belirteçler ve abdominal ultrasonografide kist benzeri olgu ile birlikte şiddetli seyredebilir. Bu durumlarda URA ayırıcı tanıda düşünülebilir.

**Anahtar sözcükler:** Unilateral renal agenezis (URA), Yaşlı köpek, İdrar birikmesi, İdrar yolu enfeksiyonu

## INTRODUCTION

Unilateral renal agenesis (URA) has an incidence of 1 in 500 to 1000 live births in the human population and is a

relatively frequent congenital anomaly <sup>[1-3]</sup> with reportedly no major adverse impact on survival <sup>[4]</sup>. However, risk factors for URA are proteinuria, renal insufficiency, and hypertension <sup>[5]</sup>, and the relevant risk management should



### İletişim (Correspondence)



+81 42 3675904, Fax: +81 42 3675904



anco@vet.ne.jp (A. Uemura); ryo@vet.ne.jp (R. Tanaka)

be initiated in childhood [6]. URA becomes particularly important in middle and old age [4]. In humans, URA is sometimes associated with uterine and vaginal anomalies [7-9]. The associated menstrual abnormality is reported to result in acute abdominal symptoms [10].

Reports of canine URA date back many years [11,12]. In another study, 50% of dogs with uterine anomalies showed ipsilateral absence of the kidney [13]. URA was also an incidental finding in the case of a 10-month-old bitch undergoing sterilization [14]. Concomitant familial unilateral renal aplasia was found in Dalmatian puppies with recessively inherited acute respiratory distress syndrome [15]. URA was also observed in a three-year-old dog with renal failure [16]. All of these reports involved young dogs: health problems and treatment strategies for older dogs with URA have not been elucidated.

The case of URA in the present report was presented for emergency treatment a long time after the first diagnosis was made. The patient showed marked urine accumulation with impaired renal and urinary function. The patient underwent laparotomy for draining of a giant cyst by paracentesis and establishment of a nephrostomy for the left kidney, and her general condition was alleviated. In this case, we report our observations of a medical emergency that can develop in older dogs with URA.

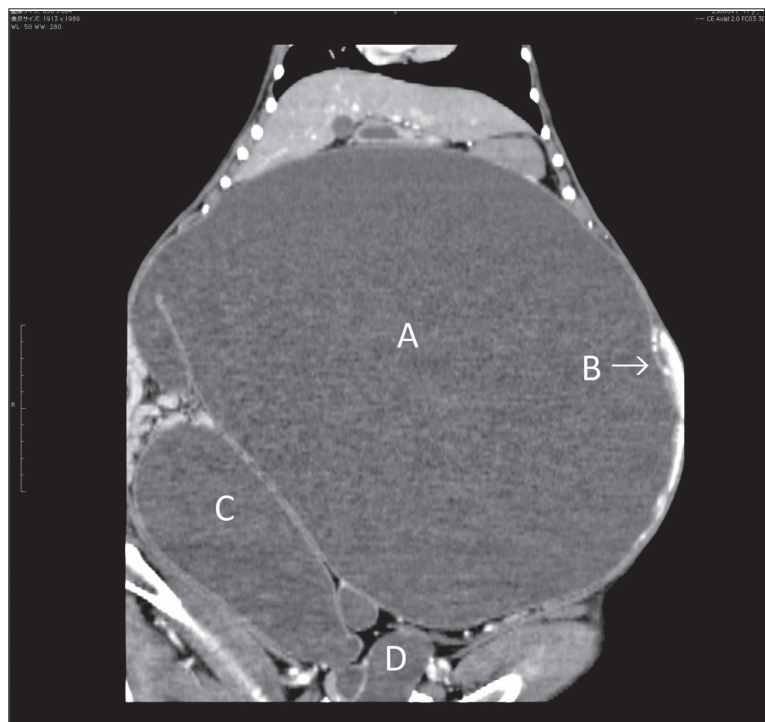
## CASE HISTORY

At the start of this case, the patient, an intact, female Large Münsterländer, was seven years old and weighed 16.5 kg. She was presented for examination at our hospital with abdominal distention as the main complaint (Day 1). She had a normal, healthy appetite and showed no clinical signs other than mild abdominal distention. No specific abnormalities were noted on blood tests (blood urea nitrogen (BUN) 12.0 mg/dL, creatinine (CRE) 0.9 mg/dL). Computed tomography (CT) showed absence of the right kidney and ureter, marked hydronephrosis, and dilatation of the left ureter. With no clinical manifestations other than the mild abdominal distention, a course of follow-up observation by the local veterinarian was decided upon the owner's wish.

Five years after the initial presentation, the 12-year-old patient was hospitalized for reduced appetite, vomiting, diarrhea, and small-scale genital bleeding (Day 1826). She had been in a state of estrus for three weeks previously, and a local veterinarian suspected pyometra after examination with abdominal ultrasound. She was presented at our hospital with a complete loss of appetite and dystasia (shown over the

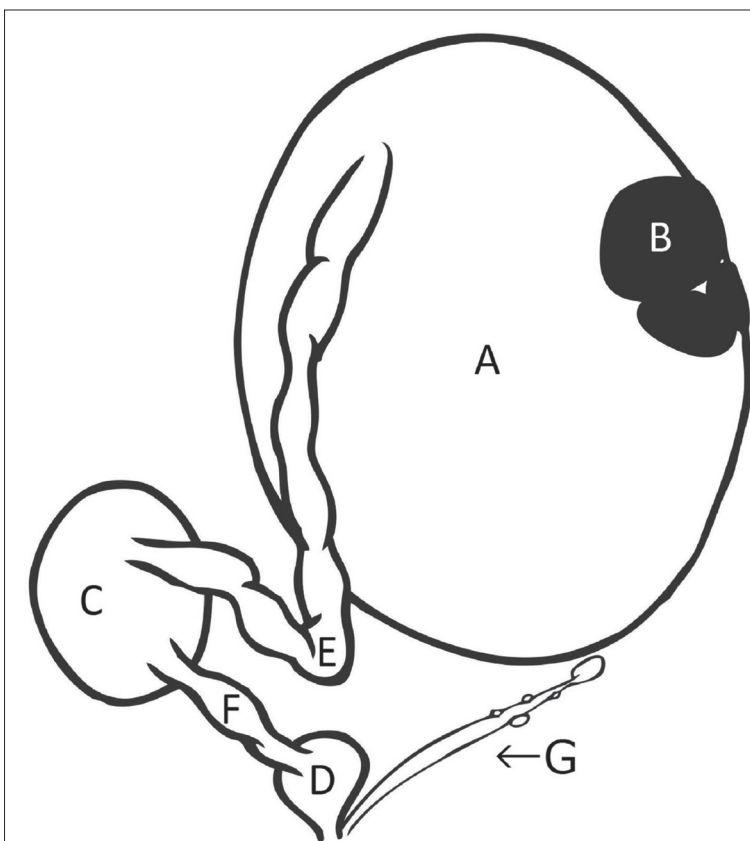
preceding days) and hospitalized for emergency care. She showed an increased body weight of 23.0 kg, temperature of 39.2°C, heart rate of 64 beats/min, respiratory rate of 20 breaths/min, a pink mucosa, slight dehydration, and marked abdominal distension. Hematology showed a leucocyte count (WBC) of  $188 \times 10^2/\mu\text{L}$ , erythrocyte count (RBC) of  $369 \times 10^4/\mu\text{L}$ , hemoglobin concentration (HGB) of 7.9 g/dL, and a hematocrit value (HCT) of 23.0%. Blood biochemistry revealed a BUN of 43.9 mg/dL, CRE of 1.1 mg/dL, calcium of 10.4 mg/dL, phosphorus of 4.2 mg/dL, elevated C-reactive protein (CRP, inflammatory marker) of 16 mg/dL, and non-regenerative anemia (reticulocytes: 1%; reticulocyte production index: 0.2%). A fluid-retaining, cyst-like lesion, which encompassed most of the abdominal region, was observed by ultrasonography. The patient underwent CT imaging under general anesthesia [induced with subcutaneous atropine at 0.05 mg/kg and intravenous Propofol (Mylan, Mylan Inc., Tokyo, Japan) at 5 mg/kg and maintained with isoflurane inhalation (Isoflurane for animals, Intervet K.K., Tokyo, Japan) at 1.0% to 2.0%]. CT showed a giant cyst (diameter exceeding 350 mm) that involved the left kidney and strongly displaced the abdominal organs into the upper right and left abdominal walls. Marked thinning of the parenchyma of the left kidney was observed. Another cyst (diameter of approximately 150 mm) was located in the position of the right kidney (Fig. 1).

After the CT examination, the patient was moved to



**Fig 1.** CT examination (Day 1826)

A: the giant cyst (diameter exceeding 350 mm) that involved the left kidney; B: marked thinning of the parenchyma of the left kidney (with contrast effect); C: another cyst (diameter of approximately 150 mm) which was located in the position of the right kidney; D: bladder-like organ

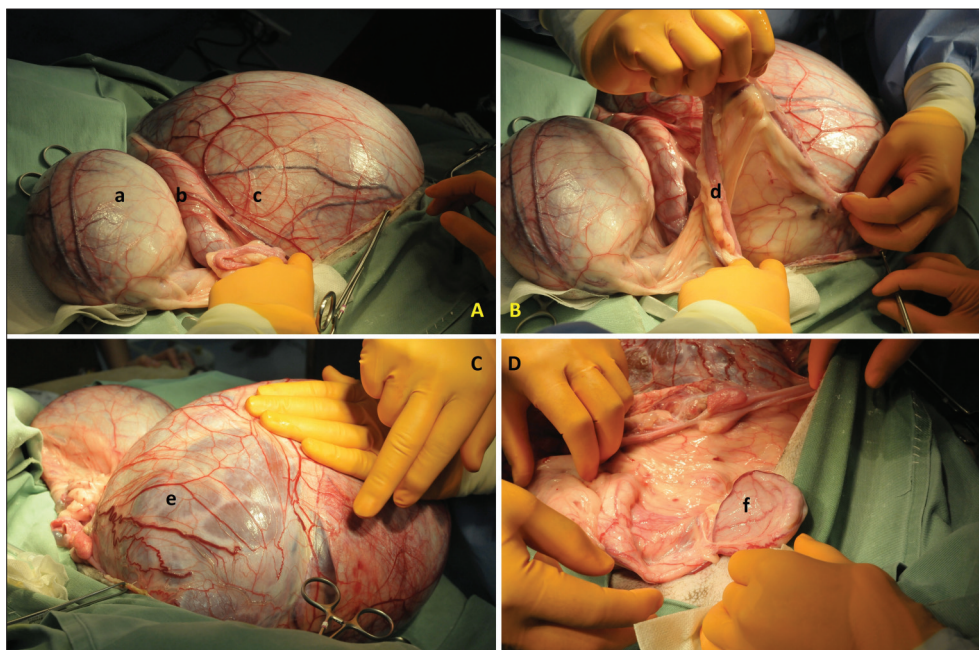


**Fig 2.** Schema of organs

A: the giant cyst involved the left kidney; B: the parenchyma of the left kidney; C: another urine-containing cyst on the right side; D: bladder-like organ; E: ureterocele-like, tubular organ; F: a short, tubular organ; G: the ovary and uterine horn (left side)

the operation room, and the laparotomy was performed. Nephrotomy was conducted on the giant cyst to alleviate the abdominal displacement and to support urination function. The giant cyst involved the left kidney and occupied almost all of the abdominal cavity. 8.230 mL of urine were drained from the cyst. Urinalysis showed a urine-protein-to-creatinine ratio of 1.51. The giant cyst involving the left kidney and another urine-containing cyst on the right side were connected with an enlarged, ureterocele-like, tubular organ (diameter approximately 5 cm), which seemed to derive from the left ureter. The urine-containing cyst on the right side and bladder-like organ were connected with a short, tubular organ; however, the bladder-like organ had no function to expand and showed no urine accumulation. There was no enlargement of the ovary or uterus; however, the ovary and uterine horn ipsilateral to the absent kidney (right side) were also absent (Fig. 2, Fig. 3). A nephrostomy catheter (MILA PEG 20Fr, AVS Co., Ltd., Tokyo, Japan) was placed on the left kidney (20 Fr), and a total ovariectomy was performed.

Urine collected during the surgical procedure was sent for cultivation of bacteria, and it was positive for *Klebsiella pneumoniae*. After surgery, the patient was given fluid (SOLDEM 3, TERUMO Corp., Tokyo, Japan), antibiotic medication (MAXIPIME®, Bristol-Myers Squibb



**Fig 3.** Macroscopic findings

(A) a: another urine-containing cyst on the right side; b: ureterocele-like, tubular organ; c: the giant cyst involved the left kidney; (B) d: the ovary and uterine horn (left side); (C) e: the parenchyma of the left kidney; (D) f: bladder-like organ



Inc., Tokyo, Japan) (cefepime dihydrochloride hydrate, 40 mg/kg, iv, TID), and erythropoietin (Epojin<sup>®</sup>, Chugai Pharmaceutical Co., Ltd. Tokyo, Japan) (100 IU/kg, s.c., TIW) intravenously. The patient was discharged four days after surgery.

Fifteen days after discharge, the patient weighed 16.7 kg and appeared able to maintain the symptom-free status she had shown when she was seven years old. She is now largely incapable of self-urination and the owner must remove urine from the nephrostomy tube with a syringe twice a day at the home. The daily amount of collected urine is approximately 600 mL (35 mL/kg/day). Her general condition and blood parameters (WBC:  $114 \times 10^2/\mu\text{L}$ , RBC:  $490 \times 10^4/\mu\text{L}$ , HGB: 10.8 g/dL, HCT: 31.4%, BUN: 33.8 mg/dL, CRE: 0.9 mg/dL, Ca: 10.6 mg/dL, P: 4.8 mg/dL, CRP: 1.95 mg/dL) have shown great improvement.

## DISCUSSION

The URA patient in the present study was able to lead an active life up to the advanced age of 12 years without receiving any special medical treatment and without showing clinical manifestations. Because URA is frequently reported in people as an incidental finding and has no major adverse impact on survival<sup>[4]</sup>, a similar situation may occur in dogs. In the same way that human URA patients can develop a condition requiring emergency care, old canine URA patients can take a sudden turn for the worse. However, the cause of the sudden exacerbation in this case seemed to be different from those in human medicine, which are related to reproductive organ disorders<sup>[10]</sup>. The sudden exacerbation in this canine case may have resulted from the following factors: abdominal organ displacement by a giant renal cyst within the abdominal cavity or an opportunistic urinary tract infection (UTI) under impaired renal and urinary function. Therefore, the therapeutic strategy focused on alleviating the abdominal organ displacement and palliating the general condition quickly. For this purpose, nephrostomy-assisted urination and a course of antibiotics to manage the UTI was conducted. URA sometimes occurs with ipsilateral absence of the ureter and a normal, contralateral kidney and ureter<sup>[14]</sup>, with contralateral renal dysplasia<sup>[16]</sup>, or with a normal, ipsilateral ureter<sup>[12]</sup>. The findings in the present case showed not only the absence of the right kidney and anomalies in the left kidney, but also a specific pattern of urinary transit in which the left ureter was connected to the urine-containing cyst on the right side rather than to the bladder. The very large amount of urine accumulation has not been reported in the previous reports and appears to be a characteristic finding in the present case. Because an increased CRE was not seen, it is possible that the elevated BUN arose mainly from the hypermetabolism related to dehydration and loss of appetite on Day 1826. It is possible that the increased BUN originated with the accompanying improvement

of the physical status, because the patient took a predominantly meat diet on Day 1845.

Deficient elimination of residual urine from the bladder is often a factor implicated in UTI onset; however, in this case, the bladder failed to expand and there was very little urine accumulation. It appears that urine accumulation in the kidney and ureter were a regular event for this patient. Vesicoureteral reflux is reported in human URA<sup>[3]</sup>. The presence of vesicoureteral reflux could not be determined in this case, but the markedly decreased urine accumulation in the non-expanding bladder was likely associated with the accumulation of large quantities of urine in the upper urinary organs. Although the urine accumulation in the left kidney appeared to reach a severe level, the patient did not show any clinical signs for a long time. CT findings showed very little fluid accumulation in the bladder-like organ, and most of the fluid had accumulated in the cyst-like structure over a long period of time. *Klebsiella pneumoniae*, which, is sometimes reported as a canine UTI pathogen, was detected by urinary cultures<sup>[17]</sup>. It seems that this aggravation of clinical status was induced by multiple factors including UTI, which were caused by the urine accumulation. In addition to the UTI, urine that accumulated within the giant cyst also caused severe displacement of the abdominal organs, causing the general condition of the patient to be exacerbated.

Although URA is a relatively common congenital anomaly in humans, it has been reported only sporadically in comparatively young dogs. Accordingly, the details of canine URA are not clearly understood. The dog in this case reached an advanced age without showing clinical symptoms, and it seems that a not inconsiderable number of dogs exist with undiagnosed URA. When URA manifests after a period of clinical silence, patients may show total loss of appetite, abdominal distension, elevated inflammatory markers, and abdominal ultrasonography images of cyst-like phenomena. The findings are similar to pyometra; however, URA should be considered in the differential diagnosis.

## ACKNOWLEDGMENT

We have no sources of support in the form of grants, equipment, or drugs. We have no financial or other types of conflicts of interest. This work has not been previously presented at any scientific meeting in whole or in part.

## REFERENCES

1. Kiproff DD, Colvin RB, McCluskey RT: Focal and segmental glomerulosclerosis and proteinuria associated with unilateral renal agenesis. *Lab Invest*, 46 (3): 275-281, 1982.
2. Roodhooft AM, Birnholz JC, Holmes LB: Familial nature of congenital absence and severe dysgenesis of both kidneys. *N Engl J Med*, 310 (21): 1341-1345, 1984. DOI: 10.1056/NEJM198405243102101
3. Janchevska A, Gucev Z, Tasevska-Rmus L, Tasic V: Congenital

anomalies of the kidney and urinary tract in children born small for gestational age. *Pril (Makedon Akad Nauk Umet Odd Med Nauki)*, 38 (1): 53-57, 2017. DOI: 10.1515/prilozi-2017-0007

4. **Argueso LR, Ritchey ML, Boyle ET, Jr Milliner DS, Bergstralh EJ, Kramer SA:** Prognosis of patients with unilateral renal agenesis. *Pediatr Nephrol*, 6 (5): 412-416, 1992.
5. **Doğan ÇS, Torun Bayram M:** Renal outcome of children with unilateral renal agenesis. *Turk J Pediatr*, 55 (6): 612-615, 2013.
6. **Lubrano R, Gentile I, Falsaperla R, Vitaliti G, Marcellino A, Elli M:** Evolution of blood pressure in children with congenital and acquired solitary functioning kidney. *Ital J Pediatr*, 43 (1): 43, 2017. DOI: 10.1186/s13052-017-0359-7
7. **Arikan, II, Harma M, Harma MI, Bayar U, Barut A:** Herlyn-Werner-Wunderlich syndrome (uterus didelphys, blind hemivagina and ipsilateral renal agenesis) - A case report. *J Turk Ger Gynecol Assoc*, 11 (2): 107-109, 2010. DOI: 10.5152/jtgga.2010.011
8. **Han BH, Park SB, Lee YJ, Lee KS, Lee YK:** Uterus didelphys with blind hemivagina and ipsilateral renal agenesis (Herlyn-Werner-Wunderlich syndrome) suspected on the presence of hydrocolpos on prenatal sonography. *J Clin Ultrasound*, 41 (6): 380-382, 2013. DOI: 10.1002/jcu.21950
9. **Fernandez-Ibieta M, Hernandez-Anselmi EB, Fernandez-Cordoba MS:** Pelvic cystic mass and ipsilateral renal agenesis detected by ultrasound in a young girl: early onset of Herlyn-Werner-Wunderlich Syndrome. *Med Ultrason*, 18 (3): 405-406, 2016. DOI: 10.11152/mu.2013.2066.183.ibi
10. **Khaladkar SM, Kamal V, Kamal A, Kondapavuluri SK:** The Herlyn-Werner-Wunderlich Syndrome - A case report with radiological review. *Pol J Radiol*, 81, 395-400, 2016. DOI: 10.12659/PJR.897228
11. **Vymetal F:** Case reports: Renal aplasia in beagles. *Vet Rec*, 77 (46): 1344-1345, 1965.
12. **de Schepper J, van Bree H, van der Stock J, Mattheeuws D, Verleyen P, de Rick A:** *In-vivo* diagnosis of right renal aplasia in a pekingese bitch. *Vet Rec*, 97 (24): 475, 1975.
13. **McIntyre RL, Levy JK, Roberts JF, Reep RL:** Developmental uterine anomalies in cats and dogs undergoing elective ovariohysterectomy. *J Am Vet Med Assoc*, 237 (5): 542-546, 2010. DOI: 10.2460/javma.237.5.542
14. **Fujita A, Tsuboi M, Uchida K, Nishimura R:** Complex malformations of the urogenital tract in a female dog: Gartner duct cyst, ipsilateral renal agenesis, and ipsilateral hydrometra. *Jpn J Vet Res*, 64 (2): 147-152, 2016.
15. **Holopainen S, Hytonen MK, Syrja P, Arumilli M, Jarvinen AK, Rajamaki M, Lohi H:** ANLN truncation causes a familial fatal acute respiratory distress syndrome in Dalmatian dogs. *PLoS Genet*, 13 (2): e1006625, 2017. DOI: 10.1371/journal.pgen.1006625
16. **Morita T, Michimae Y, Sawada M, Uemura T, Araki Y, Haruna A, Shimada A:** Renal dysplasia with unilateral renal agenesis in a dog. *J Comp Pathol*, 133 (1): 64-67, 2005. DOI: 10.1016/j.jcpa.2005.01.002
17. **Shimizu T, Harada K:** Determination of minimum biofilm eradication concentrations of orbifloxacin for canine bacterial uropathogens over different treatment periods. *Microbiol Immunol*, 61 (1): 17-22, 2017. DOI: 10.1111/1348-0421.12461