

The Assessment of Diagnostic and Ultrasonographic Findings in a Bitch with True Vaginal Prolapse

İsfendiyar DARBAZ¹  Osman ERGENE¹ Esra CANOĞLU²
Cagri GULTEKİN³ Selim ASLAN¹

¹ Department of Obstetrics and Gynecology, Faculty of Veterinary Medicine, Near East University, 99138, Nicosia - NORTHERN CYPRUS

² Department of Obstetrics and Gynecology, Faculty of Veterinary Medicine, Erciyes University, 38039, Kayseri - TURKEY

³ Department of Surgery, Faculty of Veterinary Medicine, Near East University, 99138, Nicosia - NORTHERN CYPRUS

Article Code: KVFD-2017-17721 Received: 08.03.2017 Accepted: 02.06.2017 Published Online: 03.06.2017

Citation of This Article

Darbaz I, Ergene O, Canooglu E, Gultekin C, Aslan S: The assessment of diagnostic and ultrasonographic findings in a bitch with true vaginal prolapse. *Kafkas Univ Vet Fak Derg*, 23 (5): 843-846, 2017. DOI: 10.9775/kvfd.2017.17721

Abstract

A 4-year old crossbred Pointer, with observable vaginal prolapse was brought to our hospital at the 47th day of gestation. The prolapse reoccurred next day despite of the vulval suturing. During the examination of the prolapsed mass towards the cranium via palpation, it was observed that gestational sacs and urinary bladder were also in the prolapsed mass as well. Ultrasonographic imaging of the tissue revealed that puppies were presented into one-third section of the prolapsed vagina and there were no signs of vitality in the puppies. Although it is rare, vaginal prolapse might occur in association with simultaneous dilation of urinary bladder with a part of uterus in the third trimester of the gestation in dogs. In this case, the probability of true vaginal prolapse during gestation was restated and it was revealed that as an innovation ultrasound was a beneficial and guiding technique for the diagnosis of this case.

Keywords: Bitch, Pregnancy, Ultrasonography, Vaginal prolapse

Bir Dişi Köpekte Görülen Gerçek Vaginal Prolapsus Olgusunda Tanı ve Ultrasonografik Bulguların Değerlendirilmesi

Özet

Dört yaşlı, Pointer melezi bir köpeğin kontrolleri sonucunda gebeliğinin 47. gününde olduğu ve ilk muayenede vulva dikişi uygulandığı halde vaginal prolapsusun tekrardan şekillendiği tespit edildi. Prolabe olan kitlenin kaudalden kraniale doğru yapılan palpasyonunda, kitle içinde yavruya ait bölümler ve idrar kesesinin olduğu tespit edildi. Doğrudan prolabe olan kitleye yapılan ultrasonografik muayenede yavruların prolabe vaginanın ilk üçte birlik bölümünde bulunduğu ve ölü oldukları belirlendi. Köpeklerde çok ender de olsa, gebeliğin son üçte birlik döneminde prolapsus vagina olgularının uterusun bir bölümünü ve idrar kesesini de içine alabilecek şekilde gelişebildiği görülmüştür. Bu olguda köpeklerde oldukça az karşılaşılan gerçek vaginal prolapsus olgusunun gebelikte gelişebileceği bir kere daha gösterilmiş olmakla birlikte, yenilik olarak, benzer olguların tanısında olayın derecesi ve ciddiyetini belirlemede ultrasonografinin yararlı ve yol gösterici olarak kullanılabileceği gösterilmiştir.

Anahtar sözcükler: Köpek, Gebelik, Ultrasonografi, Vaginal prolapsus

INTRODUCTION

True vaginal prolapse might occur in dogs during pregnancy and is correlated with low levels of progesterone, together with elevated levels of estrogen^[1]. True vaginal prolapse is the complete protrusion of vagina with cervix out of vulva and is commonly associated with dilatation of the urethral orificium and prolapse of other organs^[2,3].

While vaginal hyperplasia or vaginal fold prolapse is observed mostly during the term close to estrus; true vaginal prolapse usually occurs antepartum in dogs^[2,4]. No other organ observed on the vaginal prolapse besides protrusive oedematous vagina. In spite of the vaginal mucosa, protrusion of urethral orificium is observed in Type III vaginal prolapses^[5]. True vaginal prolapse cases are observed rarely in bitches. Whilst vaginal prolapse Type



İletişim (Correspondence)



+90 533 8663500



isfendiyardarbaz@hotmail.com

Ill cases were defined during pregnancy and especially on the last trimester of gestation. However; case reports presenting vaginal prolapse together with partial uterine prolapse are extremely rare and our purpose is to present this one.

CASE HISTORY

A 4-year old crossbred Pointer weighing 18 kg was referred to our hospital; it was assessed to be at the 47th days of the gestation. Despite of suturing in the first inspection vaginal prolapsus (VP) were determined.

One day previously a mass was detected and prolapsed mass is rejected and vulva suture was applied in any clinic. The vagina is protruded completely due to tenesmus and also green flux from orificium uteri externa were observed (Fig. 1). Prolapsed vagina was approximately 17 cm in length and 9 cm wide. When the prolapsed mass were examined by external cranial palpation; various body parts of puppies determined to be inside this mass and also urinary bladder was observed to be protruded. Ultrasonography (USG) were performed directly on the tissue (Mindray®DC-N3Vet; 5.0 MHz; convex probe); puppies were revealed to be attached to the first third of the prolapsed vagina and showing no signs of vitality (no heartbeat or movement detected). The vagina was also shown to be interlocked with the cranial part of the uterus, with its borders clearly defined (Fig. 2). Ultrasonography

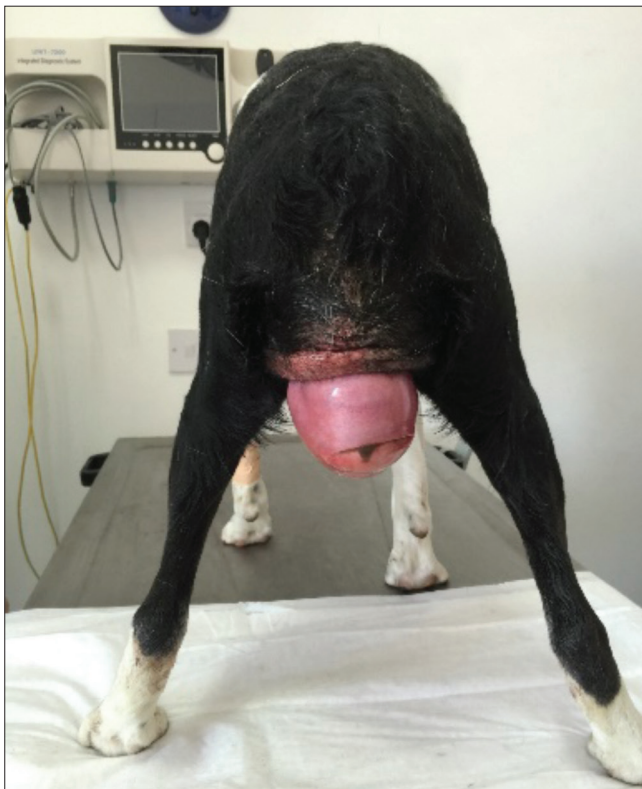

Fig 1. Appearance of vaginal prolapse

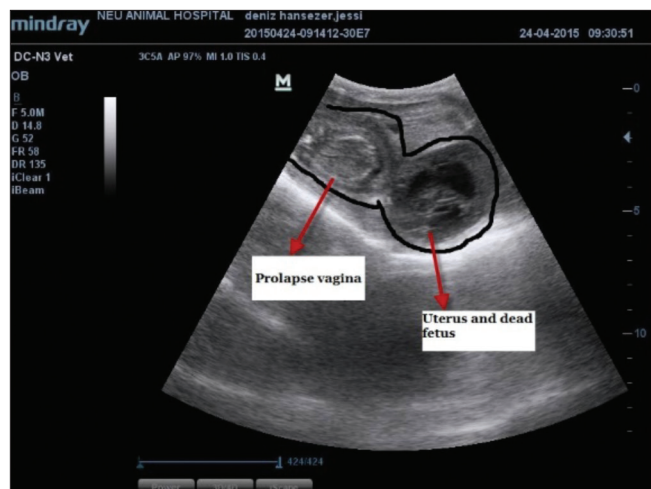


Fig 2. Ultrasonographic view of the prolapsed uterus and vagina

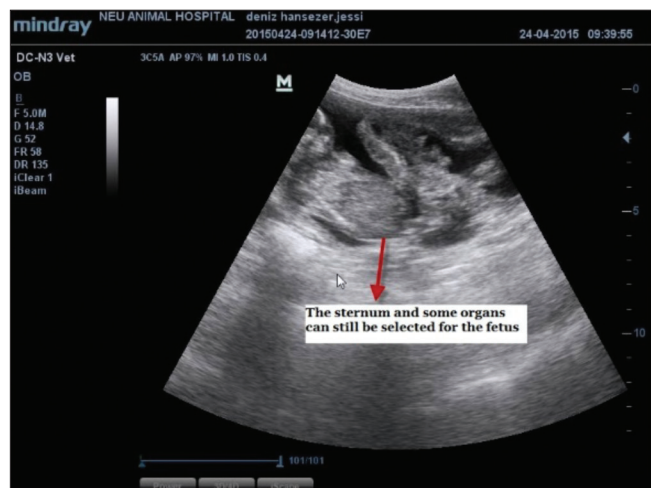

Fig 3. Abdominal ultrasonographic image of the fetus

examination of the abdomen presented osteoid sternum-like structures, but still no fetal movement or heartbeat were detected. Slow movement from caudal to cranial with the ultrasonography probe, revealed that the uterus continued behind the symphysis pelvis (Fig. 3).

Following the consideration of blood tests (WBC $35.2 \times 10^9/L$, oestradiol $17-\beta$ measured value 2 days after the prolapsus is 23.5 pg/mL) and the request of the patient owner dead foetuses and prolapsed tissue were removed via "cesarean section". Prior to the surgery part of the mass were rejected to inside. The incision was made in line with linea alba. Uterus were removed without hysterotomy (Fig. 4), and following the removal four dead puppies with approximately $8.0 \times 3.2 \text{ cm}$ dimensions were detected. Prolapsed uterus section have revealed enlargement of the cranial region and an increase in the levels of oedema (Fig. 4). The prolapsed part of the vagina had shrunk completely within one day post ovariohysterectomy. 3 day after surgery, no VP was observed externally; in spite

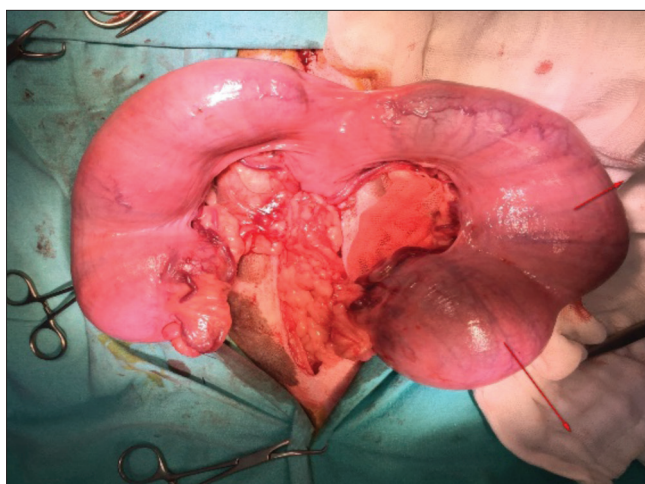


Fig 4. Oedema and color change in the right uterine corn which is a prolapsed (arrows)

of this the patient were transferred to the our hospital department of surgery for cystopexy and uteropexy procedures since the previously rejected urinary bladder was still partially prolapsed and could be easily seen externally. Urinary bladder was rejected during surgery and returned to its anatomical position were performed according to Mc Namara et al.^[6]. After consultation, the bladder was reported to have regressed one day following the subsequent examinations revealed that the dog had fully recovered.

DISCUSSION

True vaginal prolapses are cases with protrusion of vaginal walls, urinary bladder, uterine tissue and/or distal part of colon. Cases accompanied with vaginal prolapse and uterine prolapse are extremely rare^[6].

Even though exact etiology is not known, vaginal prolapses are more frequently encountered during terms where oestrogen levels are elevated such as cystic ovary^[7], exogenous oestrogen application^[8], granulosa cell tumors^[9] and follicular phase^[5] of sexual cycle. In addition, factors like relaxation of ligaments due to aging^[5], abdominal pressure increase due to gestation and ascites, trauma^[10] causes vaginal fold prolapse. It is more appropriate to define cases which are regressed at dioestrus and neither vaginal hyperplasia nor true prolapse as vaginal fold prolapses^[11]. No neoplastic tissues were observed in this case. Vaginal prolapse cases are considered to be based on oestrogenic influences when rejected before arrival to the clinic and true vaginal prolapse is considered to be developed due to internal pressure which is caused by uterine contractions continued after vulva suture application. The potential for vaginal prolapse development is reported to be starting from estrus (or end of proestrus) until almost the end of gestation^[12]. In this case, true vaginal prolapse is determined as developing at

a time near the parturition. Concannon et al.^[13] revealed that progesterone (P4) serum values are around 4.5 ± 0.6 ng/mL nearly 120 h before postpartum. Having 5.6 ng/mL P4 values indicates that the cases occur closer to parturition. Other publications report that true vaginal prolapse occurs during a period near postpartum where P4 values start to decrease and oestrogen values begin to increase^[4,14,15]. In the present case, it was easy to diagnose since puppies could be palpated on first one third caudal part of clinically prolapsed vagina and a second layer with palpation. Also, this shows that determination using ultrasonographic imaging diagnosis of partial uterine tissue engaged in vaginal prolapse at the caudal region of the mass is possible. Determination of additional foetus and other parts of uterus on the caudal parts when abdomen was palpated to the caudal of pecten pubis shows that part of the uterus remaining in cranial was prolapsed with vagina. Vaginal prolapses can be easily diagnosed with identification of protrusive cylindrical part^[16]. As understood from published cases that prolapsed uterus with vagina is revealed after operation^[4]. This case reveals diagnosis of true vaginal prolapse with palpation and especially through the use of ultrasonographic imaging techniques. There are many publications regarding pathological and physiological changes of the uterus with ultrasonographic^[17]; however, to our knowledge this is the first account regarding the determination of true vaginal prolapse using USG.

In previous reports in cases of true vaginal prolapse or vaginal fold prolapse upon determination of both live and dead puppies via ultrasonography; generally a ovariohysterectomy were performed^[4,16]. In this case the reason for surgical intervention were the death of the foetuses and the failure of the repositioning of the tissue(s). While excessive tenesmus related to dystocia causes prolapse, stenosis related to dystocia on reproductive canal reported to be possibly prevents repositioning the organ^[4].

As a result, it is concluded that, even though it is extremely rare in dogs, during the last third term of gestation, a part of uterus and bladder may be dilated accompanied with vaginal prolapse. In this report possibility of development of true vaginal prolapse in the pregnancy period were represented, and benefits and guidance of ultrasonographic method in the diagnosis of such cases are revealed.

REFERENCES

1. Johnston SD, Kustritz MVR, Olson PNS: Disorders of the canine vagina, vestibule and vulva. In, Canine and Feline Theriogenology. 225-242, WB Saunders Company, Philadelphia, 2001.
2. Gouletsou PG, Galatos AD, Apostolidis K, Sideri AI: Vaginal fold prolapse during the last third of pregnancy, followed by normal parturition, in a bitch. *Anim Reprod Sci*, 112, 371-376, 2009. DOI: 10.1016/j.anireprosci.2008.04.032
3. Schaeffers-Okkens AC: Vaginal oedema and vaginal fold prolapse

in the bitch in press, including surgical management. **In, Concannon PW, England G, Verstegen J** (Eds): *Recent Advances in Small Animal Reproduction*. International Veterinary Information Service (www.ivis.org), Ithaca, New York, 2001. Available at: http://www.ivis.org/advances/Concannon/schaefer/chapter_frm.asp?FLA=1 Accessed: October, 2016.

4. Alan M, Çetin Y, Şendağ S, Eski F: True vaginal prolapse in a bitch. *Anim Reprod Sci*, 100, 411-414, 2007. DOI: 10.1016/j.anireprosci.2006.10.022

5. Schutte AP: Vaginal prolapse in the bitch. *J S Afr Vet Med Ass*, 38 (2): 197-203, 1967.

6. McNamara PS, Harvey HJ, Dykes N: Chronic vaginocervical prolapse with visceral incarceration in a dog. *J Am Hosp Assoc*, 33, 533-536, 1997. DOI: 10.5326/15473317-33-6-533

7. Ragni RA: What is your diagnosis? *J Small Animal Pract*, 47, 625-627, 2006. DOI: 10.1111/j.1748-5827.2006.00168.x

8. Sarrafzadeh-Rezaei F, Saifzadeh S, Mazaheri R, Behfar M: First report of vaginal prolapse in a bitch treated with oestrogen. *Anim Reprod Sci*, 106, 194-199, 2008. DOI: 10.1016/j.anireprosci.2008.01.009

9. Nak D, Alasonyalilar Demirel A, Tuna B, Nak Y, Özyiğit Ö: Vaginal prolapse related to ovarian granulosa cell tumor in an Anatolian Shepherd. *Turk J Vet Anim Sci*, 36 (1): 61-66, 2012. DOI: 10.3906/vet-1012-7

10. Arbeiter K, Bucher A: Traumatically caused perineal prolapse of

the vagina followed by retroflexion of the urinary bladder in the bitch. *Tierarztl Prax*, 22, 78-79, 1994.

11. Purswell BJ: Vaginal disorders. **In, Ettinger SJ, Feldman EC** (Eds): *Textbook of Veterinary Internal Medicine*. 4th edn., 1566-1571, WB Saunders, London, 1995.

12. Memon MA, Pavletic MM, Kumar MS: Chronic vaginal prolapse during pregnancy in a bitch. *J Am Anim Vet Med Assoc*, 202, 295-297, 1993.

13. Concannon PW, Hansel W, Vlsek WJ: The ovarian cycle of the bitch: Plasma estrogen, LH and progesterone. *Biol Reprod*, 13 (1): 112-121, 1975.

14. König GJ, Handler J, Arbeiter K: Rare case of a vaginal prolapse during the last third of pregnancy in a Golden Retriever bitch. *Kleintierpraxis*, 49, 299, 2004.

15. Rani RU, Kathiresan D, Sivaseelan S: Vaginal fold prolapse in a pregnant bitch and its surgical management. *Indian Vet J*, 81, 1390-1391, 2004.

16. Payan-Carreira R, Albuquerque C, Abreu H, Maltez L: Uterine prolapse with associated rupture in a Podengo bitch. *Reprod Domest Anim*, 47 (4): e51-5, 2012. DOI: 10.1111/j.1439-0531.2011.01944.x

17. Davidson A, Baker T: Postpartum disorders in the bitch and queen. *81st Annual Western Veterinary Conference*, Las Vegas, NV, USA, p. V239, 2009.