


Management of Feline Glaucoma with Surgical Interventions: Some Less Preferred But Beneficial Options

Murat KARABAĞLI¹ Kürşat ÖZER¹ 

¹ Faculty of Veterinary Medicine, University of Istanbul, Department of Surgery, TR-34320 Avcılar, Istanbul - TURKEY

Article Code: KVFD-2017-17471 Received: 23.01.2017 Accepted: 20.03.2017 Published Online: 21.03.2017

Citation of This Article

Özer K, Karabağlı M: Management of feline glaucoma with surgical interventions: Some less preferred but beneficial options. *Kafkas Univ Vet Fak Derg*, 23 (4): 621-627, 2017. DOI: 10.9775/kvfd.2017.17471

Abstract

Glaucoma is an eye disease which, particularly in cats, cannot always be controlled with medical treatment, and in most cases requires surgical treatment methods. It is a known fact that blindness occurs within 1-30 months even in feline glaucoma patients where intraocular pressure (IOP) is controlled with medical treatment and vision is present. This study comprised 11 eyes with glaucoma, in a total of 10 cats (3 female, 7 male). The selected and performed surgical methods were; cyclocryosurgery in 6 patients, trabeculectomy in 3 and chemical ablation in 1 patient. The patients were re-examined at regular intervals in the post-operative period and changes in intraocular pressure (IOP) and the degree of pain and vision were assessed. Nine cats with vision prior to surgery were assessed on post-operative Day 60 for criteria including; IOP, presence of vision and pain. The blind cat was assessed with respect to IOP and pain. The results of trabeculectomy performed in 3 cats with vision in the pre-operative period were unsuccessful. In the patients that received cyclocryosurgery (6 cases) and chemical ablation (1 case), IOP was controlled and pain eliminated. In conclusion, since we know that feline glaucoma almost always ending with blindness, surgical interventions like cyclocryosurgery and chemical ablation should be considered especially when the IOP can not be controlled with medical therapy.

Keywords: Feline, Glaucoma, Trabeculectomy, Cyclocryosurgery, Chemical ablation

Kedilerde Glokomun Cerrahi Yaklaşımlarla Kontrol Altına Alınması: Az Tercih Edilen Ancak Faydalı Bazı Seçenekler

Özet

Glokom özellikle kedilerde, çoğu zaman tıbbi tedavi ile kontrol altına alınamayan, olguların büyük bir kısmında cerrahi tedavi yöntemlerinin kullanılmasını gerektiren bir hastalıktır. Tıbbi tedavi ile göz içi basıncı (GİB) kontrol altına alınabildiği ve görmenin var olduğu glokom hastası kedilerde dahi sonraki 1-30 ay içerisinde körlük şekillendiği bilinmektedir. Çalışmamıza 3 dişi, 7 erkek toplam 10 kediye ait 11 glokomlu göz dahil edildi. Hastalardan altısında siklokriyocerrahi, üçünde trabekülektomi, bir tanesinde ise kimyasal ablasyon operasyon yöntemi olarak seçildi ve uygulandı. Hastalar postoperatif dönemde belli aralıklarla kontrol edilerek, GİB'deki değişimler, ağrı ve görme durumu açısından değerlendirildi. Operasyon öncesi görebilen 9 kedi post operatif 60. Gün GİB, görüş varlığı ve ağrı gibi kriterlere bakılarak değerlendirildi. Kör olan bir kedi ise GİB ve ağrı açısından değerlendirildi. Preoperatif dönemde görme var olan 3 kedide trabekülektomi ile başarılı sonuçlar elde edilemedi. Siklokriyoterapi (altı olgu) ve kimyasal ablasyon (1 olgu) yapılan hastalarda ise GİB kontrol altına alınabildiği gibi ağrı da ortadan kaldırılabildi. Sonuç olarak, kedilerde glokomun çoğu zaman körlükle sonuçlandığı için, medikal tedavi ile GİB kontrol altına alınamayan hastalarda siklokriyocerrahi ve kimyasal ablasyon gibi cerrahi girişimlerin de tedavi seçeneği olarak düşünülmesinin uygun olabileceği kanısına varılmıştır.

Anahtar sözcükler: Kedi, Glokom, Trabekülektomi, Siklokriyocerrahi, Kimyasal ablasyon

INTRODUCTION

Glaucoma is described as, the progressively worsening loss of vision as a result of (IOP) remaining at a much higher level than where the optic nerve and retina can function normally^[1]. Today, veterinary ophthalmologists still indisputedly consider it to be the most challenging eye disease to treat^[2].

Since it is a multifactorial disease with many different phenotypes and varying etiology, its classification is equally difficult. Depending on its etiology, stage and iridocorneal angle morphology, glaucoma can be classified as; primary, secondary or congenital; early non-congestive, acute congestive or chronic; open-angled, narrow/closed-angled or glaucomas progressing with goniodysgenesis, respectively^[3]. However, this classification has limited



İletişim (Correspondence)



+90 212 4737070/17298



ozar_kursat@yahoo.com

significance for a surgeon developing a suitable treatment protocol for each individual patient. In any case, 95-98% of glaucoma cases observed in cats are of secondary character and originate from factors causing changes in aqueous humor flow dynamics, such as uveitis, tumour, trauma and intraocular haemorrhage [4]. The normal IOP value determined using applanation tonometry in cats is 18.4 (\pm 0.67) mm Hg [5].

According to data collected by the Veterinary Medical Database over a period of 20 years, glaucoma causes loss of vision in 1 in 367 cats [1]. Also, feline glaucoma is different to canine glaucoma in that it develops insidiously and is a constantly deteriorating disease, where cats are usually presented by their owners for clinical examination in the late period [4,6]. The main target at this point is to alleviate the perception of pain by lowering IOP, therefore, improving the quality of life [7].

In cats, if it is not possible to bring down IOP to under 25 mmHg with medical treatment, selection of a surgical method is indicated. The main criteria in selecting the surgical method to be used is whether or not vision is present in the eye with glaucoma [7]. In cats that can still see, cyclodestructive procedures, which decrease aqueous humor production, or filtering procedures, which increase aqueous humor drainage are used. Surgical interventions such as chemical ablation and enucleation are preferred in cats that have total loss of vision [8].

Using present clinical medical treatment methods, IOP can not be lowered to less than 10-15 mmHg and the painful phase remains persistent [1]. Also, medical therapy is beneficial in the early stages of the disease in controlling glaucoma, however, for the long term control of IOP, surgical intervention is almost always necessary [9]. In spite of the general knowledge, even in feline glaucoma patients that have vision and IOP under control by medical treatment, blindness could be occur within 1-30 months [7]. In addition, there is only a relatively small number of clinical studies carried out on the surgical treatment of glaucoma in cats [6]. The aim of this study is to present information regarding the contribution of trabeculectomy and cyclocryosurgery, administered in addition to medical treatment, to the process of controlling glaucoma in cats, as well as the clinical results of chemical ablation performed in a patient with total loss of vision.

MATERIAL and METHODS

In this study, 11 glaucomatous eyes of 10 cats (3 female, 7 male) were treated surgically. The age range was between 24-48 months. Breed distribution was; 2 Siamese, 1 Persian and 7 mixed breed. Cyclocryosurgery in 6 patients, trabeculectomy in 3 and chemical ablation in 1 patient were performed.

Patient Selection

Cats with IOP higher than 25 mmHg were considered to be glaucoma patients. None of the patients had received glaucoma treatment previously. All patients were initially given medical treatment. For medical therapy, an agent containing carbonic anhydrase inhibitor and beta-blocker (Cosopt®, Merck Sharp & Dohme) was prescribed for use twice daily. IOP values of the patients were measured 3 and 7 days later.

First Examination

Examination of the eye was carried out using an indirect ophthalmoscope, slit lamp, retinal camera (Kowa, RC-2, Japan) and applanation tonometer (Tono-Pen XL®, Reichert). Vision was considered to be present in cats that followed the movements of a cotton wool ball and displayed the menace response. The mean value of five consecutive measurements performed using the applanation tonometer was determined and recorded.

Surgical Procedure Selection and Anaesthesia

In the follow-up examination of the patients on Day 7, either trabeculectomy or cyclocryosurgery was performed in patients whose vision was present, while at the same time, where IOP could not be lowered to less than 25 mmHg. In patients where IOP could not be lowered to less than 40 mmHg after one week of medical treatment, trabeculectomy was selected as the surgical procedure. Cyclocryosurgery was carried out in cats where IOP could be lowered to under 30 mmHg following a 7-day medical treatment. Chemical ablation was performed in a cat with no vision but with moderate buphthalmos. Pre-operative complete blood count and some serum biochemical parameters (glucose, AST, ALT, BUN, creatinin) were examined. Patients suitable for anaesthesia were sedated using 1 mg/kg IV xylazine hydrochloride (Rompun®, Bayer). Anaesthesia induction was done by administering ketamine hydrochloride (Ketalar®, Bayer) at a dose of 20 mg/kg IM.

Trabeculectomy

The anaesthetised patient was placed in lateral recumbency with the affected eye uppermost. Initially, a limbus-based conjunctival flap in the 12 o'clock position was elevated. A ½ thickness square scleral flap with a dimension of approximately 4x4 mm was elevated from the sclera directly below the conjunctiva and the trabeculum was reached. At this stage, gauze soaked in mitomycin-c (Mitomycin-c®, Onko) at a concentration of 0.25 mg/mL was placed on the sclera for approximately 3 min and sclera was irrigated with 10 mL isotonic NaCl solution. Then a trabecula with a dimension of approximately 1x3 mm was removed (Fig. 5). In the next stage, iridectomy was performed. The scleral flap was attached with only 2 sutures using 8/0 (Vicryl®, Ethicon) absorbable suture material. In the final stage, the conjunctival flap was

sutured using 8/0 (Vicryl®, Ethicon) absorbable suture material with simple interrupted sutures and the procedure was completed.

Cyclocryosurgery

The anaesthetised patient was placed in lateral recumbency with the affected eye uppermost. For the cyclocryosurgery procedure, the 1.5 mm-diameter cryoprobe of the nitrous oxide cyclocryosurgery device (Metzen) was used. The cryoprobe was placed on the sclera 2-3 mm caudal to the limbus and the cooling process was begun (Fig. 4). The maximum temperature reached by the probe tip during the cooling process was -76°C. The cooling process was continued until a sphere of ice formed at the cryoprobe's point of contact. The cooling process was applied to 6-8 different points between the 12 and 9 o'clock positions. No extra care was taken to prevent the sphere of ice from coinciding with the 3 and 9 o'clock positions.

Chemical Ablation

The anaesthetised patient was placed in lateral recumbency with the affected eye uppermost. The 0.75 mL chemical ablation emulsion was prepared by filling a syringe with 20 mg gentamycin sulphate (Gensif® 80 mg ampul, AVICENNA) and 1 mg dexamethasone (Dekort® 8 mg ampul, Deva). Initially, a 22-gauge 2 mL syringe was used to enter the front camera through the limbus and approximately 0.8 mL aqueous humor was removed. The prepared emulsion was injected into the globe via the same route and the chemical ablation procedure was completed.

Post-operative Assessment

The cats were called back for check-ups on post-operative days 1, 7, 14, 30 and 60 and assessed for presence of complications, state of vision, pain and changes in IOP. Vision was considered to be present in cats that followed the movement of a cotton wool ball and displayed the menace response. Surgery was considered to be successful in patients that had an IOP below 25 mmHg on post-operative day 60 with no evidence of pain and that had vision. The pre-operatively blind case that received chemical ablation was considered to be successful on account of the IOP value dropping to under 25 mmHg on post-operative day 60 and that no pain was evident.

RESULTS

The study included 11 eyes with glaucoma from a total of 10 cats; of which 3 (30%) were female and 7 (70%) were male. The age range was 24-48 months (mean 35 months). Breed distribution was; 2 Siamese, 1 Persian and 7 mixed breed. Glaucoma was due to secondary to uveitis in 7 patients, trauma in 2 patients and of congenital origin in 1 patient. Any acute symptoms related with the uveitis

(aqueous flare, peripheral iridal hypemia, dyscoria etc.) were not determined during first clinical examination in uveitis induced secondary glaucoma patient cats. In the first examination, while 9 of the cats had vision, 1 was blind. Glaucoma had developed in the right eye in 3 patients, in the left eye in 6 patients and bilaterally in 1 patient. Mean IOP in the affected eyes was 33.6 mmHg in the initial examination. Following one week of medical treatment, mean IOP was determined to be 29.7 mmHg, while the difference between mean IOP values was found to be 3.9 mmHg. Surgically, trabeculectomy was performed in 3 cats, cyclocryosurgery in 6 cats and chemical ablation in 1 cat (Table 1).

When obtaining the history from patient owners, it was recorded that 7 cats (case no.s 1, 3, 6, 7, 8, 9, 10) had suffered from Herpes virus infection, with subsequent clinical complaints relating to the eye. In the clinical examination of these 7 cats, there were no clinical findings such as lens luxation, tumour, corneal oedema, rubeosis iridis or aqueous flare. Glaucoma diagnosis was made based on the presence of clinical findings such as episcleral congestion, pain, raised IOP and buphthalmus (Fig. 1). In the author's opinion, glaucoma in these patients had occurred due to the blockage in the flow route of the aqueous humor secondary to uveitis. In 1 (case no. 2) of the 3 cats that developed glaucoma following trauma, the iris was found to be bulging during clinical examination. The narrowing of the iridocorneal angle in this patient was evident even in clinical examination. Therefore it was assessed as a closed-angle glaucoma due to trauma. Eyedrops could not be administered to this patient (case no. 2) due to aggression so trabeculectomy was performed without the medical treatment option. Bilateral aniridia was determined on clinical examination in one patient (case no. 5) diagnosed with bilateral congenital glaucoma (Fig. 2). On fundus photography, none of the patients displayed optic disk cupping (Fig. 3).

In the follow-up examination on post-operative day 1, a slight hyphema had developed in all of the patients that had received trabeculectomy (Fig. 6). Two of these patients (case no.s 1 and 3) were prescribed eye drops containing dexamethasone to be administered 1 drop 4 times daily, and eye drop containing an ciprofloxacin to be administered 1 drop 6 times daily. On post-operative day 7, the hyphema was seen to have resolved in these two cases. In the follow-up examination of one of the patients (case no. 2) on post-operative day 7, no significant decrease was determined in the IOP and, since medical treatment was not possible for this patient, the related eye was removed. In the follow-up examinations of case no.s 1 and 3 on post-operative day 60, although vision was present, it was determined that IOP could not be lowered to under 25 mmHg and that the pain sensation continued. In 3 cats receiving trabeculectomy, the result was considered to be unsuccessful.

Table 1. Preoperative informations belongs to patients, IOP variations during medical treatment and preferred surgical procedures

Case No	Age (month)	Breed	Sex	Etiology	Clinical Examination Findings	Evaluation of Vision	Side	IOP 1 st Day (mm Hg)	IOP 3 rd Day (mm Hg)	IOP 7 th Day (mm Hg)	Surgical Procedure
1	24	Mix	♂	Uveitis	P, EC, Bup+	Sighted	Unilateral Right	44	36	41	Trabeculectomy
2	36	Mix	♂	Traumatic	Iris bombe, P, EC, Bup+	Sighted	Unilateral Left	41	-	-	Trabeculectomy
3	36	Mix	♀	Uveitis	P, EC, Bup+	Sighted	Unilateral Left	43	36	40	Trabeculectomy
4	30	Mix	♂	Traumatic	P, EC, Bup+	Sighted	Unilateral Left	29	27	26	Cyclocryosurgery
5	24	Siamese	♂	Congenital	Aniridia, P, EC, Bup+	Sighted	Bilateral	R29/L32	R29/L30	R28/L27	Cyclocryosurgery
6	36	Mix	♂	Uveitis	P, EC, Bup+	Sighted	Unilateral Right	30	28	28	Cyclocryosurgery
7	48	Persian	♀	Uveitis	P, EC, Bup+	Sighted	Unilateral Right	29	30	28	Cyclocryosurgery
8	42	Mix	♀	Uveitis	P, EC, Bup+	Sighted	Unilateral Left	32	30	29	Cyclocryosurgery
9	48	Mix	♂	Uveitis	P, EC, Bup+	Sighted	Unilateral Left	31	27	26	Cyclocryosurgery
10	24	Siamese	♂	Uveitis	P, EC, Bup ++	Blind	Unilateral Left	34	28	27	Chemical ablation

P, pain; EC, episcleral congestion; Bup+, mild buphthalmos; Bup ++, moderate buphthalmos

Table 2. Postoperative variations of IOP, postoperative complications and visibility after surgery

Case No	Procedure	Preoperative IOP (mm Hg)	Postoperative Complications	Postoperative 1 st Day IOP (mm Hg)	Postoperative 7 th Day IOP (mm Hg)	Postoperative 14 th Day IOP (mm Hg)	Postoperative 30 th Day IOP (mm Hg)	Postoperative 60 th Day IOP (mm Hg)	Evaluation of Vision After Surgical Intervention
1	Trabeculectomy	41	Hyphema	40	30	36	34	38	Sighted
2	Trabeculectomy	41	Hyphema	37	38	-	-	-	-
3	Trabeculectomy	40	Hyphema	32	29	36	38	36	Sighted
4	Cyclocryosurgery	26	-	24	18	18	16	18	Sighted
5	Cyclocryosurgery	R28/L27	-	R28/L24	R20/L22	R14/L17	R14/L14	R12/L14	Sighted
6	Cyclocryosurgery	29	-	24	20	18	16	16	Sighted
7	Cyclocryosurgery	28	-	24	22	18	16	18	Sighted
8	Cyclocryosurgery	29	-	28	29	29-Reop	20	16	Sighted
9	Cyclocryosurgery	26	-	26	20	20	16	16	Sighted
10	Chemical ablation	27	-	30	20	14	18	14	Blind




Fig 1. Appearance of eye at initial examination. Episcleral congestion, mydriasis and mild buphthalmos in right eye (case no 7)

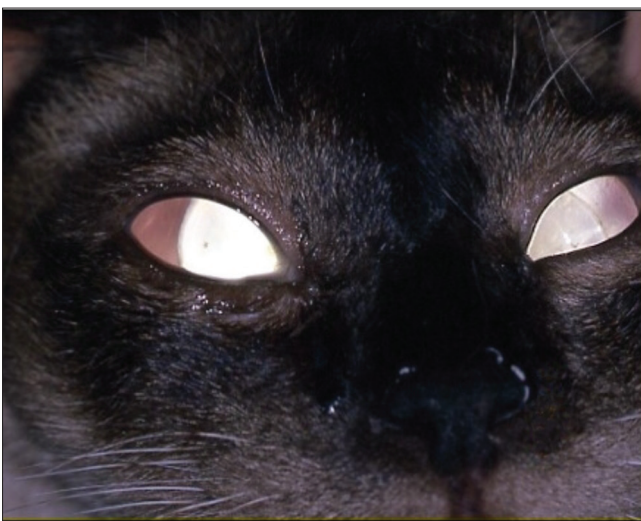


Fig 2. Clinical appearance of bilateral aniridia in case no 5

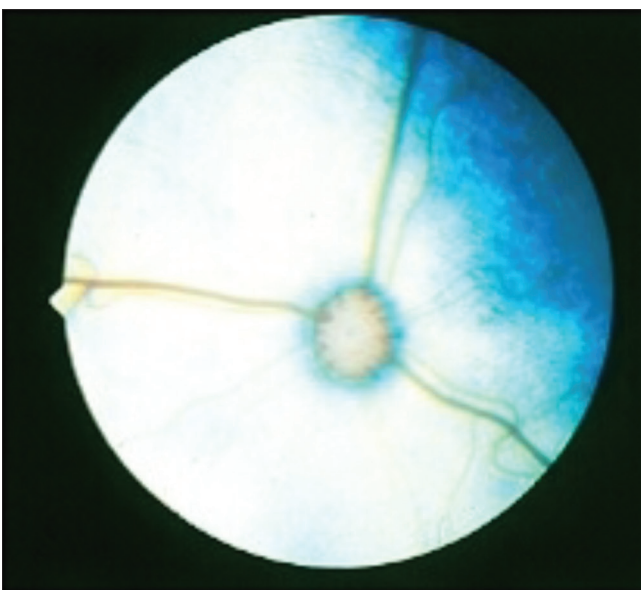


Fig 3. Fundus photography of case no 6, optic disc cupping was not present

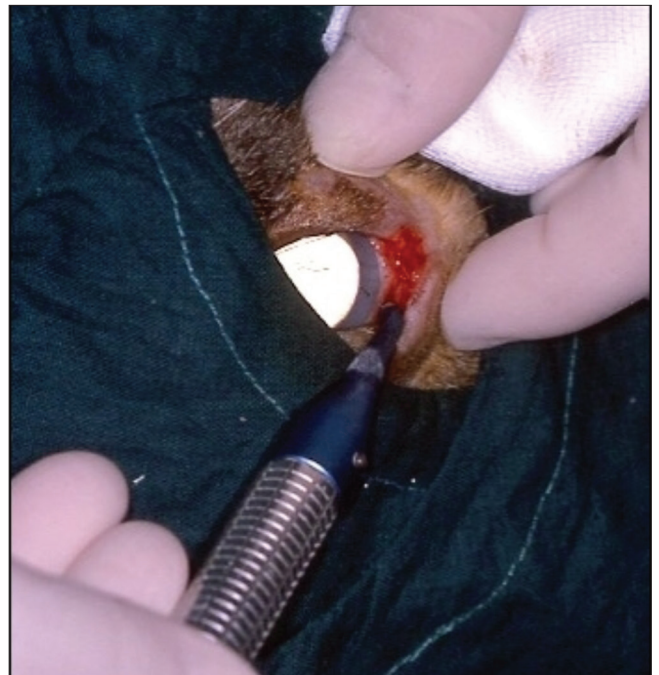

Fig 4. Cyclocryosurgery. Touch point of cryoprobe 2-3 mm caudal to the limbus

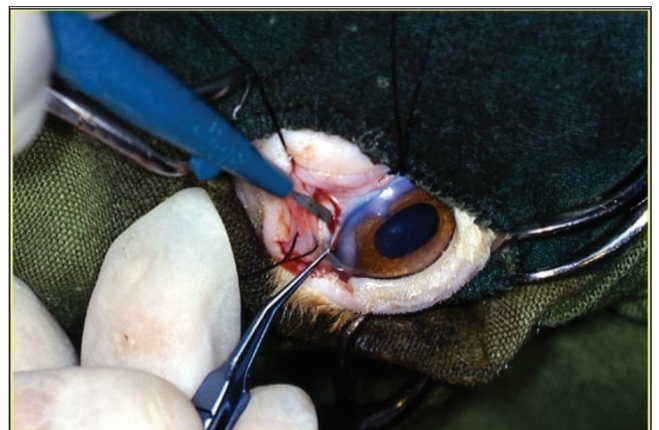

Fig 5. Stage of 1x3 mm trabecula removing during trabeculectomy

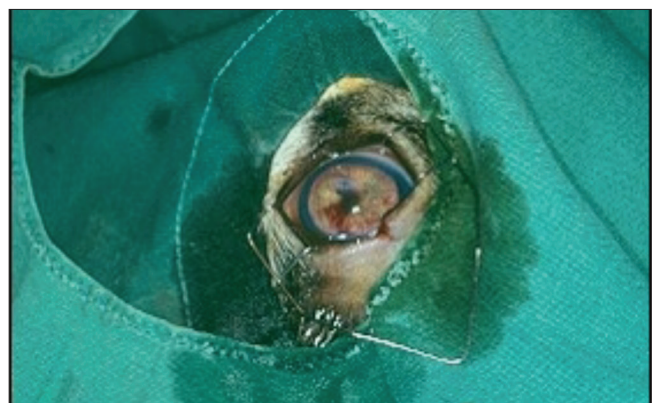


Fig 6. Postoperative hyphema complication after trabeculectomy (case no 1)

In patients that received cyclocryosurgery, there were no post-operative complications such as partial necrosis in the iris, blindness or retinal detachment. Only in one cat (case no. 8) almost no reduction occurred in IOP in the post-operative period and the state of pain continued. The same procedure was repeated in this case 14 days after the first operation. In the second operation, the cryoprobe made contact with 8 different points between the 3 and 12 o'clock positions where ice spheres were formed and the procedure was completed. In the follow-up examination on post-operative day 60, IOP levels were below 20 mmHg in all patients receiving cyclocryosurgery and the mean value of these 7 cats was 15.7 mmHg. Considering the mean IOP value of patients receiving cyclocryosurgery was 27.5 mmHg in the pre-operative period, a 42% reduction in mean IOP values was demonstrated. As well as the continued presence of vision in patients in this group, pain was also eliminated. A successful result was achieved in patients receiving cyclocryosurgery (Table 2).

The cat receiving chemical ablation had an IOP value of 14 mmHg on post-operative day 60 and pain was not present. Due to the fact that this cat was already blind in the pre-operative period and since targets such as, the eye remaining *in situ* for cosmetic reasons, elimination of pain and lowering IOP were met, the result was considered to be a success (Table 2).

DISCUSSION

Glaucoma is an eye disease which, particularly in cats, cannot always be controlled with medical treatment, and in most cases requires surgical treatment methods^[10]. However, there is not an overall single method that would benefit all glaucoma patients^[1].

Different filtration procedures to increase aqueous humor drainage have been described for the surgical treatment of glaucoma. Transscleral iridencleisis applied together with cyclodialysis and posterior sclerotomy, trabeculectomy, glaucoma shunts and gonioimplants are used for this purpose^[2,3,9,11,12]. For many years, trabeculectomy has been used and accepted as the gold standard among filtration procedures in human medicine. Studies carried out in human medicine in recent years have focused on comparing long-term results of surgical inter-ventions performed using GDD and trabeculectomy^[13]. The use of glaucoma drainage devices is increasing day by day. However, the fact that feline glaucoma generally occurs secondary to uveitis, which causes glaucoma drainage tubes to be blocked by the inflammatory filtrate, limits its use. Other factors contributing to the difficulty of using these devices include, the conformation of the orbit in cats, its relatively taut structure and the presence of buphthalmus^[4]. On

the other hand, not many studies exist on the use of the trabeculectomy procedure in the treatment of secondary glaucoma in cats. In this study, trabeculectomy was preferred in order to achieve a significant and rapid drop in patients with an IOP higher than 40 mmHg. However, in these patients neither could IOP be lowered to below 25 mmHg, nor could pain be eliminated.

Cyclocryosurgery and cyclophotocoagulation are procedures used to lower IOP by decreasing aqueous humor production and to control glaucoma, and could be used like filtration procedures in patients that still have vision^[2]. It has been suggested that, in order to avoid causing damage to the long ciliary arteries while administering cyclocryosurgery, the cryoprobe should not make contact at the 3 and 9 o'clock positions^[7,9]. In the present study, however, this idea warning of the risk of necrosis patches developing in the iris was disregarded. Also serious complication risk of cyclodestructive procedures are considered to be low^[14].

Although the use of nitrous oxide and liquid nitrogen for cyclocryosurgery serve the same purpose, there are some differences. When liquid nitrogen is used, a temperature of -185°C is produced at the tip of the cryoprobe, leading to the ciliary epithelium to cool down to -23°C. With the use of nitrous oxide, a temperature of between -60°C and -80°C is produced at the tip of the cryoprobe and the ciliary epithelium cools down to -15°C. The aim in cryosurgery is to generate not complete but only partial necrosis in the ciliary epithelium in order to decrease aqueous humor production^[9]. The temperature in the ciliary epithelium required to produce this condition has been reported as between -12°C and -15°C. In the author's opinion, the use of nitrous oxide in this study may have been effective in the lack of post-operative complications, by producing an optimal degree of cilioneclerosis in the ciliary epithelium.

In one of the patients receiving cyclocryosurgery, since IOP did not show any indication of decreasing in the post-operative period, cyclocryosurgery was repeated 14 days after the first operation. Recordings taken 45 days after the second operation in this patient revealed that IOP had been controlled and pain eliminated. The reason for the necessity of a second operation in this patient may be due to the fact that adequate cilioneclerosis could not be produced in the first instance because of the change in the anatomical position of the ciliary epithelium^[4] caused by buphthalmus in some situations.

Despite the fact that previous studies indicate that cyclocryosurgery in cats does not produce results as successful as those in dogs with respect to controlling IOP^[11]. In the present study, the results obtained from cyclocryosurgery performed using nitrous oxide were successful.

Chemical ablation is a method which decreases IOP, eliminates pain and, when compared to enucleation, produces a more successful cosmetic result by the chemical destruction of the ciliary epithelium in patients with no vision due to glaucoma. Although it is suggested that this method causes intravitreal sarcoma developing in later stages ^[15], the relationship between chemical ablation using gentamycin and sarcoma has not been clearly identified ^[4].

Despite no ophthalmic abnormalities being detected in the eye examination, patients with an IOP higher than the reference range are considered to have primary glaucoma. In this study, glaucoma was determined to have developed secondary to uveitis in 7 patients (case nos 1, 3, 6, 7, 8, 9, 10). However, no ophthalmic abnormality such as lens luxation, aqueous flare, corneal oedema, tumour etc. was observed in any of the patients. The reason the author is able to state that glaucoma had developed secondary to uveitis in these patients was the fact that, all the cats had a history of Herpes virus infection and that glaucoma had not developed bilaterally in any of the cases. In the author's opinion, the inflammatory products generated during uveitis had blocked the iridocorneal angle, permanently preventing aqueous humor drainage, leading to the development of secondary glaucoma.

Studies indicate that the most common surgical intervention used in glaucoma patients is enucleation ^[6]. Yet, in a disease where it has been proven that patients can lose their vision within 1-30 months even in situations where IOP can be controlled with medical treatment ^[7], the fact that surgical methods should be used more often is an obvious statement. Results obtained, particularly with cyclocryosurgery, in the patient population most of which still have vision, are favorable and may be beneficial for use in feline glaucoma patients.

REFERENCES

- 1. Miller PE:** Glaucoma. In, Slatter D (Ed): Textbook of Small Animal Surgery. Vol. 2, 3rd edn., 1454-1477, Saunders, Philadelphia, 2003.
- 2. Sapienza JS:** Surgical procedures for glaucoma: what the general practitioner needs to know. *Top Companion Anim Med*, 23, 38-45, 2008. DOI: 10.1053/j.ctsap.2007.12.005
- 3. Maggio F:** Glaucomas. *Top Companion Anim Med*, 30, 86-96, 2015. DOI: 10.1053/j.tcam.2015.07.011
- 4. McLellan GJ, Miller PE:** Feline glaucoma-a comprehensive review. *Vet Ophthalmol*, 14 (s1): 15-29, 2011. DOI: 10.1111/j.1463-5224.2011.00912.x
- 5. Rusanen E, Florin M, Hässig M, Spiess BM:** Evaluation of a rebound tonometer (Tonovet®) in clinically normal cat eyes. *Vet Ophthalmol*, 13, 31-36, 2010. DOI: 10.1111/j.1463-5224.2009.00752.x
- 6. Blocker T, Van der Woerd A:** The feline glaucomas: 82 cases (1995-1999). *Vet Ophthalmol*, 4, 81-85, 2001. DOI: 10.1046/j.1463-5224.2001.00169.x
- 7. Dietrich U:** Feline glaucomas. *Clin Tech Small Anim Pract*, 20, 108-116, 2005. DOI: 10.1053/j.ctsap.2004.12.015
- 8. Abrams KL:** Medical and surgical management of the glaucoma patient. *Clin Tech Small Anim Pract*, 16, 71-76, 2001. DOI: 10.1053/svms.2001.22809
- 9. Cook CS:** Surgery for glaucoma. *Vet Clin North Am: Small Anim Pract*, 27, 1109-1129, 1997. DOI: 10.1016/S0195-5616(97)50105-7
- 10. Jacobi S, Dubielzig RR:** Feline primary open angle glaucoma. *Vet Ophthalmol*, 11, 162-165, 2008. DOI: 10.1111/j.1463-5224.2008.00614.x
- 11. McLellan GJ, Teixeira LB:** Feline glaucoma. *Vet Clin North Am: Small Anim Pract*, 45, 1307-1333, 2015. DOI: 10.1016/j.cvs.2015.06.010
- 12. Park KH, Kim JY, Choo SW, Yoon HY, Jeong SW:** Ahmed glaucoma valve implantation with Ologen® collagen matrix for the surgical treatment of feline glaucoma. *Vet Ophthalmol*, 2016, 1-5, 2016. DOI: 10.1111/vop.12422
- 13. Maggio F, Bras D:** Surgical treatment of canine glaucoma: Filtering and end-stage glaucoma procedures. *Vet Clin North Am: Small Anim Pract*, 45, 1261-1282, 2015. DOI: 10.1016/j.cvs.2015.06.008
- 14. Gorsler I, Thieme H, Meltendorf C:** Cyclophotocoagulation and cyclocryocoagulation as primary surgical procedures for open-angle glaucoma. *Graefes Arch Clin Exp*, 253, 2273-2277, 2015. DOI: 10.1007/s00417-015-3159-z
- 15. Duke FD, Strong TD, Bentley E, Dubielzig RR:** Feline ocular tumors following ciliary body ablation with intravitreal gentamicin. *Vet Ophthalmol*, 16 (s1): 188-190, 2013. DOI: 10.1111/vop.12066