

## A Case of *Trichophyton mentagrophytes* Infection in Rabbits Accompanied by Farm Staff Infection in China

Xiancheng ZENG <sup>1</sup>  Qingli ZHENG <sup>1</sup> Xuelin CHI <sup>1</sup>

<sup>1</sup> College of Animal Sciences, Fujian Agriculture and Forestry University, Fuzhou 350002, CHINA

Article Code: KVFD-2016-16685 Received: 27.08.2016 Accepted: 22.12.2016 Published Online: 26.12.2016

### Citation of This Article

Zeng X, Zheng Q, Chi X: A Case of *Trichophyton mentagrophytes* infection in rabbits accompanied by farm staff infection in China. *Kafkas Univ Vet Fak Derg*, 23 (3): 497-501, 2017. DOI: 10.9775/kvfd.2016.16685

### Abstract

*Trichophyton (T.) mentagrophytes* is common tinea infection with high incidence in rabbits and also a classical zoonotic infection in people exposed to infected animals. However, many cases never got a correct diagnosis, let alone considerable management and treatment, which could cause certain economic losses in rabbit farms. An outbreak of a highly contagious skin disease infecting rabbits and accompanying all farm staff on a large scale rabbit farm in China was investigated. The disease was diagnosed by routine physical examinations, and the etiology of the disease was identified as *T. mentagrophytes* by fungal culture, sequence of ribosomal internal transcribed spacer (ITS+) and chitin synthase-1 gene (pchs-1). To date, there is no report of Dermatophytosis infection in rabbits accompanied by farm staff infection in mainland China. In this case, the etiology is identified by using advanced molecular techniques and clinical, microbiological aspects and the histological features of the infection are described.

**Keywords:** Dermatophytosis, Zoonosis, *Trichophyton*, Rabbits

## Çin'de Çiftlik Çalışanları ile Birlikte Tavşanlarda *Trichophyton mentagrophytes* Enfeksiyonu Olgusu

### Özet

*Trichophyton (T.) mentagrophytes* tavşanlarda yüksek oranda gözlemlenen yaygın bir mantar enfeksiyonu olup enfekte hayvanlarla temas halindeki insanlarda da gözlemlenen klasik zoonotik bir enfeksiyondur. Tavşan çiftliklerinde çoğu vaka doğru teşhis edilemeyip bakım ve tedavi masrafları sebebiyle önemli ekonomik kayıpların oluşmasına neden olabilmektedir. Bu çalışmada Çin'de büyük ölçekli bir tavşan çiftliğindeki tavşanlarda ve çiftlik çalışanlarında gözlemlenen oldukça bulaşıcı bir deri hastalığı salgını incelendi. Hastalığın rutin fiziksel muayene ile tanısı konuldu ve hastalığın etiolojisi fungal kültür, ribozomal internal transkript spacer (ITS+) ve kitin sentaz-1 gen sekansları ile *T. mentagrophytes* olarak belirlendi. Bugüne kadar Çin'de tavşanlarda ve çiftlik çalışanlarında aynı zamanlı olarak tespit edilen Dermatophytosis enfeksiyonuna dair bir rapor bulunmamaktadır. Bu vakada etioloji gelişmiş moleküler teknik, klinik, mikrobiyolojik ve hastalığın histolojik yapısı ile tanımlandı.

**Anahtar sözcükler:** Dermatomikoz, Zoonoz, *Trichophyton*, Tavşan

## INTRODUCTION

Rabbit dermatophytoses are highly contagious zoonotic diseases. The organisms causing these dermatophytoses mainly include *Trichophyton*, *Microsporum* and *Epidermophyton* genera within the *Fungi Imperfecti*, most of which reproduce asexually by sprouting or budding <sup>[1]</sup>. Many types of *Trichophyton* can infect humans as well as animals. For instance, *Trichophyton rubrum*, *Trichophyton mentagrophytes (T. mentagrophytes)*, *Trichophyton tonsurans*, *Trichophyton verrucosum* and *Trichophyton schoenleinii* are common in clinical infections. Among rabbits, *T. mentagrophytes* is one of the most important patho-

mycetes, which incubates and develops in keratin tissues and damages the skin, hair and nails of the animals. *T. mentagrophytes* infection is characterized by inflamed, itchy skin with irregular lumps, alopecia, and dermatitis <sup>[2]</sup>. Previous epidemiological studies have demonstrated a high incidence of *T. mentagrophytes* in rabbits and its transmission to humans <sup>[3-5]</sup>, but there are no case reports in mainland China. In this study, we diagnosed a case of a highly contagious skin disease infecting rabbits and all farm staff on a large scale rabbit farm in this region as *T. mentagrophytes* by using advanced molecular techniques and clinical, microbiological aspects and the histological features of the infection are described.



### İletişim (Correspondence)



+86 591 83758852



zxc206@163.com

## CASE HISTORY

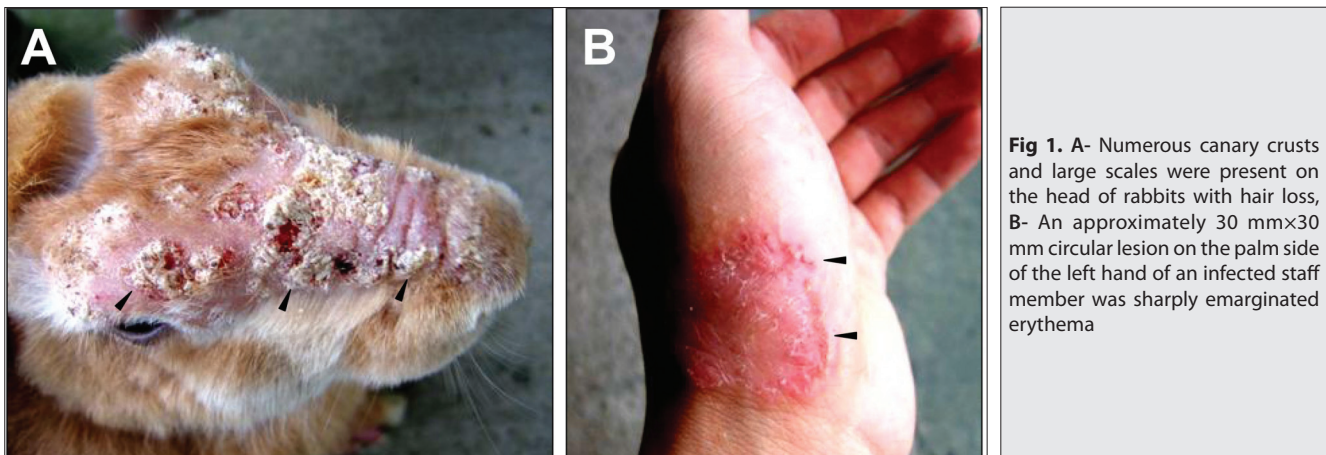
During a technical visit to a large scale farm containing approximately 1000 rabbits in the Fujian Province of China, a case of highly contagious rabbit dermatophytoses was reported. Prior to our visit, over a 5 week period, approximately 70% of rabbits of all ages had developed or were developing hair loss, crusts and scales. Meanwhile, all farm staff, including 6 males and 2 females (20 to 30 years of age), who were exposed to the sick rabbits successively showed itching ringworm lesions. They did not realize they suffered from dermatophyte infection and treated the lesions themselves with topical applications of iodine tincture. The skin lesions of some of the staff had recovered while some were still suffering dermatoses. At the beginning, the veterinarian diagnosed this disease as bacterial infection, and antibiotics were administered to sick rabbits. During the outbreak, environmental disinfection was conducted in the rabbit houses, although these measures had little effect. The disease spread to the entire farm, including accompanying staff and they asked us for assistance.

Dermatological examination revealed hair loss and scales on all body locations. A great deal of canary crusts was present on the top of the head of rabbits with alopecia (Fig. 1A). Numerous canary scales were present around the eyes, the ears and the back. Hair loss appeared also on the abdomen and limbs. In infected staff, the lesion sites were mainly on the finger joints, palms, arms, necks and legs, with symptoms of itching, redness, peeling and blistering. An approximately 30 mm×30 mm circular lesion on the palm side of the left hand was sharply marginated erythema (Fig. 1B).

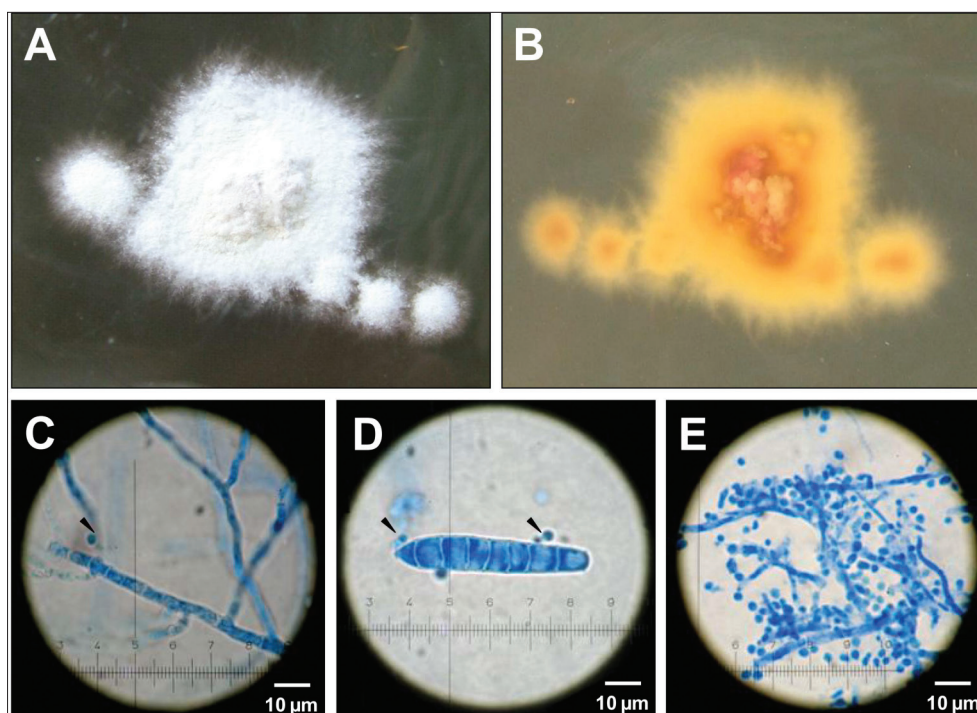
Initially, direct microscopic examination of rabbit skin crusts and scales with 15% KOH showed septate, and branching hyphae by re-examination, confirming our hypothesis of dermatophyte infection. Rabbit skin samples of nine rabbits and cotton swab samples of three infected staff members were inoculated onto slants of Sabouraud glucose agar (Hangzhou Tianhe Microorganism Reagent

Co, Ltd, China) with 10<sup>6</sup> U/L penicillin (Beyotime, China) and 10 mg/L of chloramphenicol (Shanghai Sangon Biotech, China). The cultures were incubated in an incubator at 28°C. After 7 d, white mycelium were seen at the beginning, turning gradually to irregularly shaped colonies with a powdery surface (Fig. 2A, Fig. 2B). Under microscopic observation, elongated mycelium could be seen with septate and branching (Fig. 2C). Two types of spores were observed. The large conidia were rod-like with 6-8 divisions and few in number (Fig. 2D), while small conidia were round or pear-shaped with large numbers (Fig. 2E). The morphology of colonies, the mycelium and spores from different samples looked very similar, suggesting the biological agents of dermatophyte infection in the rabbits and farm staff were identical.

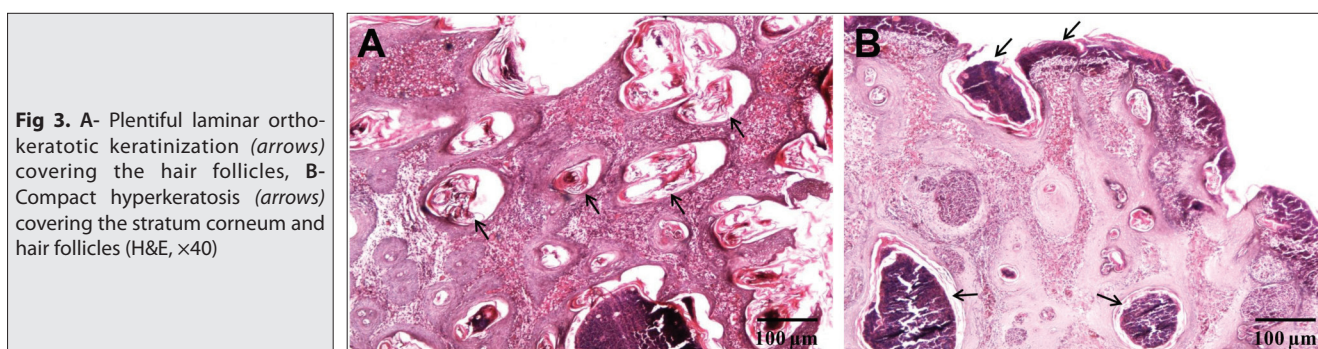
To molecularly identify the dermatophyte, a region (ITS+, 900-950 bp) spanning across the ITS-1, 5.8 S and ITS-2 of the nuclear ribosomal and part of chitin synthase 1 gene (CHS-1) gene (897 bp) were amplified separately using specific primers as the following: ITS+ (forward primer 5'-CCAGGGAGGTTGGAAACGACCG-3'; reverse primer 5'-CTA CAAATTACAATCTGGACCC-3'), CHS-1 (forward primer 5'-GACTGTCCCATTCCACCA-3'; reverse primer 5'-GTTCTTGTC ATTCTGTAGCG-3'). All ITS+ and CHS-1 amplicons produced from genomic DNA samples were purified using minicolumns (OMEGA bio-tek, USA) and automated nucleotide sequencing was performed using 3730XL DNA Analyzer with the BigDye terminator v3.1 by Shanghai SanGong Biological Engineering Technology Service Co., LTD, China. The sequences of CHS-1 from different DNA samples were identical, as were the ITS+ sequences. These results demonstrated that the rabbits must have been the source of the farm staff infection. Sequence data reported in this paper are available in GenBank under accession numbers KM355551 (ITS+) and KM355549 (CHS-1). The sequences were aligned with previously published sequences from GenBank by using the ClustalW method, identifying the dermatophyte infection as *T. mentagrophytes* and confirming that the strains isolated from nine rabbits and three staff are identical.



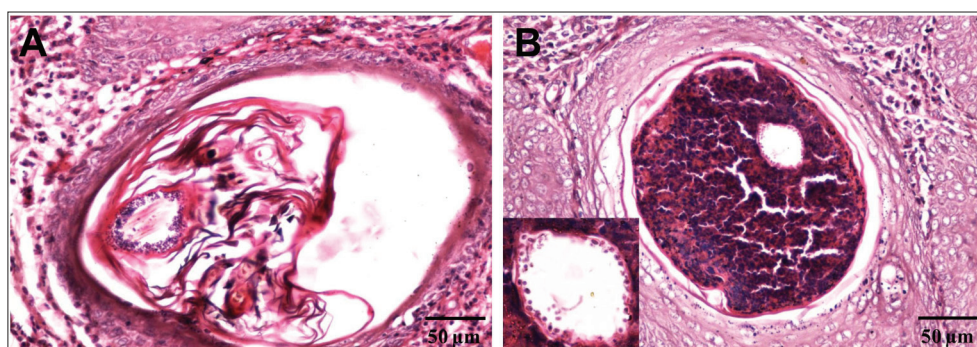
**Fig 1.** A- Numerous canary crusts and large scales were present on the head of rabbits with hair loss, B- An approximately 30 mm×30 mm circular lesion on the palm side of the left hand of an infected staff member was sharply emarginated erythema



**Fig 2.** A- Cultured pure *T. mentagrophytes*: surface of colony show powder-like shape, white, loose irregular mycelium on the edge, B- Back side of *Trichophyton mentagrophytes*: pale yellow color, C- Mycelium: elongated, divisions and branches, D- Large conidia (size: 4-8×40-50 μm), E- Small conidia (size: 2-3×2-4 μm) and mycelium



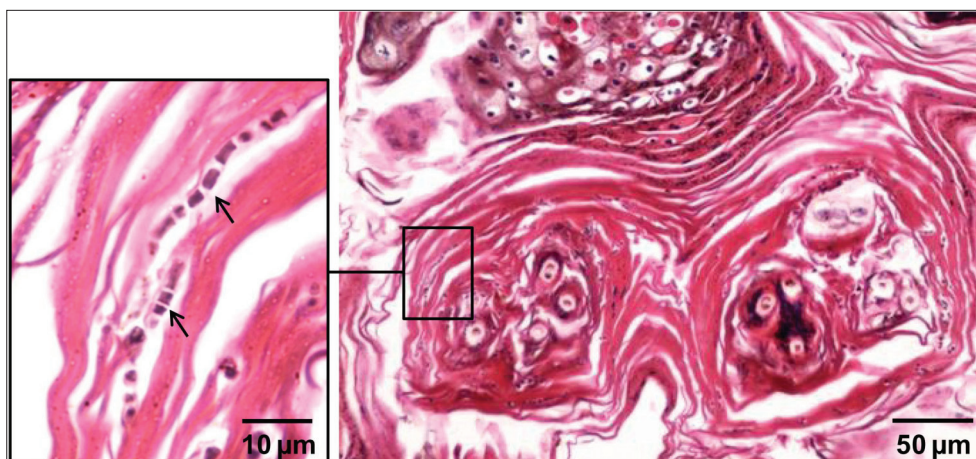
**Fig 3.** A- Plentiful laminar orthokeratotic keratinization (arrows) covering the hair follicles, B- Compact hyperkeratosis (arrows) covering the stratum corneum and hair follicles (H&E, ×40)



**Fig 4.** A- Numerous, round, fungal spores in lamina hyperkeratotic scale in the hair follicles, B- In compact hyperkeratotic scale in the hair follicles. Arrows show fungal spores. (H&E, ×200)

In order to understand histological features of *T. mentagrophytes* infection in rabbits, biopsy specimens from the back skin of a severe infected rabbit were obtained and submitted for histological examination. In the epidermis, the general changes were acanthosis, multifocal spongiosis, hyperplasia of epidermal cells, lymphocyte infiltration in the basal layer, and lamellar or compact hyperkeratosis present in the hair follicles and the stratum corneum (Fig. 3A, Fig. 3B). By further examination, the

typical characteristic of the fungal infection was revealed. In lamina hyperkeratotic scale (Fig. 4A) and compact hyperkeratotic scale (Fig. 4B) in the transverse section of hair follicles, at high power, numerous, round, fungal spores were observed. Furthermore, longitudinal section showed fungal spores with various shapes were widely distributed throughout the hair follicles. In addition, a large number of fungal spores were also observed in the lamina orthokeratotic keratinization in the stratum corneum



**Fig 5.** Stratum corneum on the back skin. Large number fungal spores and hyphae (arrows) were present in the lamellar orthokeratotic keratinization (H&E, x40) Inset, high-power photomicrograph shows elongated, septate mycelium (arrows), x1000

(Fig. 5). However, fungal hyphae were mainly distributed in the lamellar orthokeratotic keratinization in the stratum corneum, and inset showed mycelium were elongated and obviously septate.

After hyphae were observed by direct microscopic examination of rabbit skin scrapings, a miconazole nitrate cream (Trade name: Da Ke Ning, Xi'an Janssen Pharmaceutical Ltd, China) was applied on affected areas of the farm staff twice per day. The lesions disappeared gradually and the infection resolved completely after one week of treatment. In infected rabbits, the ten rabbits with the heaviest crusts were euthanized and disposed of appropriately. Those rabbits with heavier crusts were separated in a single room, given the oral antifungal drug griseofulvin (Beijing Zhong Xin Pharmaceutical Factory, China) for four weeks. Meanwhile, voriconazole was administered by intramuscular injection. Those rabbits with light visible skin lesions were given only griseofulvin. At the same time, the farm was disinfected and dehumidified with quicklime. The dermatophytoses were under control after one month of treatment and only sporadic cases were encountered thereafter.

## DISCUSSION

This case describes the first case of rabbit dermatophytes accompanying farm staff infection in Fujian Province, China. The lack of epidemiological data on the rabbit tinea in this region hampers the understanding of its clinical significance. Before our technological visit, this dermatophyte was misdiagnosed and under reported. In this case, hyphae were observed by direct microscopic examination, confirming our hypothesis of fungal infection. Fungal culture is thought the most reliable technique for confirming dermatophytosis [6]. We performed the fungal culture and we found the morphology of colonies, the mycelium and spores from different samples looked very similar. Biomolecular tools have been used for the identification of rabbit dermatophytes by amplification of CHS-1 gene and ITS+ sequence [6]. By using molecular

methods, we identified the dermatophytic infection as *T. mentagrophytes* and confirmed the strains isolated from nine rabbits and three staff are identical.

After the preliminary diagnosis of fungal infection, topical applications of miconazole nitrate cream was performed immediately and effectively treated human infections, but there were some problems with the control dermatophytic infections in rabbit. Griseofulvin was added into the fodder for oral administration and voriconazole was administered by intramuscular injection. After four weeks of continuous use, the epidemic situation was effectively controlled. However, the use of these drugs affected the growth and performance of the rabbits, especially females, whose reproductive performance decreased. Female rabbits developed symptoms like premature birth and stillbirth, and some of them did not come into estrus. After stopping medication, drug adverse reaction gradually disappeared.

Despite the epidemiological and molecular features of *T. mentagrophytes* in rabbits having been documented [3-5,7], few studies have described histological features of rabbit infection. In this study, histological examination revealed a usual feature that lamellar or compact hyperkeratosis was widely distributed in the hair follicles and the stratum corneum. Most notably, we observed fungal hyphae and spores in large numbers in lamellar hyperkeratotic scale in the stratum corneum and numerous spores were widely distributed throughout the hair follicles. Based on the above facts, it is reasonable to make predictions that hyperkeratosis in the hair follicles and the stratum corneum lead to the production of large numbers scales and hair loss for ensuring the transmission of the fungus, suggesting the main origination of transmission of this fungus in rabbits is the infected hairs and scales.

Similarly, *M. canis* infection in cats and dogs and *T. verrucosum* infection in calves show a usual feature of the production of abundant arthrospores [8,9]. By contrast, the histological feature of *T. mentagrophytes* infection in dogs shows hyphae and spores were usually sparse and often

difficult to observed <sup>[10]</sup>. This discrepancy of histological feature is presumably related to infection in adapted hosts or nonadapted hosts. Thus, rabbits are likely a reliable host for *T. mentagophytes* infection.

#### ACKNOWLEDGMENTS

We thank professor Baomin Qi and Miss Huihui Jian (College of Animal Sciences, Fujian Agriculture and Forestry University, Fuzhou, China) for their support in histopathological technology.

#### COMPETING INTERESTS

The authors declare that they have no competing interests.

#### REFERENCES

1. **Weitzman I, Summerbell RC:** The dermatophytes. *Clin Microbiol Rev*, 8, 240-259, 1995.
2. **Degreef H:** Clinical forms of dermatophytosis (ringworm infection). *Mycopathologia*, 166, 257-265, 2008. DOI: 10.1007/s11046-008-9101-8
3. **Torres-Rodríguez JM, Dronda MA, Rossell J, Madrenys N:** Incidence of dermatophytoses in rabbit farms in Catalonia, Spain, and its repercussion on human health. *Eur J Epidemiol*, 8, 326-329, 1992. DOI: 10.1007/BF00158563
4. **Proverbio D, Perego R, Spada E, Bagnagatti de Giorgi G, Della Pepa A, Ferro E:** Survey of dermatophytes in stray cats with and without skin lesions in Northern Italy. *Vet Med Int*, 2014. DOI: 10.1155/2014/565470
5. **Cafarchia C, Camarda A, Coccioli C, Figueredo LA, Circella E, Danesi P, Capelli G, Otranto D:** Epidemiology and risk factors for dermatophytoses in rabbit farms. *Med Mycol*, 48, 975-980, 2010. DOI: 10.3109/13693781003652620
6. **Bond R:** Superficial veterinary mycoses. *Clin Dermatol*, 28, 226-236, 2010. DOI: 10.1016/j.clindermatol.2009.12.012
7. **Cafarchia C, Weigl S, Figueredo LA, Otranto D:** Molecular identification and phylogenesis of dermatophytes isolated from rabbit farms and rabbit farm workers. *Vet Microbiol*, 154, 395-402, 2012. DOI: 10.1016/j.vetmic.2011.07.021
8. **Gross TL, Walder EJ, Ihrke PJ:** Feline and Canine Dermatophytosis. **In**, *Veterinary Dermatopathology: A Macroscopic and Microscopic Evaluation of Canine and Feline Skin Disease*. 243-245, Mosby, St Louis, 1992.
9. **Yager JA, Wilcox BP:** Dermatophytosis. **In**, *Color Atlas and Text of Surgical Pathology of the Dog and Cat*. 188-189, Mosby, St Louis, 1994.
10. **Fairley RA:** The histological lesions of *Trichophyton mentagrophytes* var *erinacei* infection in dogs. *Vet Dermatol*, 12, 119-122, 2001. DOI: 10.1046/j.1365-3164.2001.00235.x