

Protective Effects of Rutin on Acute Lung Injury Induced by Oleic Acid in Rats ^[1]

Mustafa Sinan AKTAŞ ¹  Fatih Mehmet KANDEMİR ² Mustafa ÖZKARACA ³
Başak HANEDAN ¹ Akın KIRBAŞ ¹

^[1] This study was presented in 5th Animal Health and Veterinary Medicine Congress (September 26-27, 2016) in Valencia, Spain

¹ Atatürk University, Faculty of Veterinary Medicine, Department of Internal Medicine, TR-25240 Erzurum - TURKEY

² Atatürk University, Faculty of Veterinary Medicine, Department of Biochemistry, TR-25240 Erzurum - TURKEY

³ Atatürk University, Faculty of Veterinary Medicine, Department of Pathology, TR-25240 Erzurum - TURKEY

Article Code: KVFD-2016-16977 Received: 19.10.2016 Accepted: 31.01.2017 Published Online: 13.02.2017

Citation of This Article

Aktaş MS, Kandemir FM, Özkaraça M, Hanedan B, Kırbaş A: Protective effects of rutin on acute lung injury induced by oleic acid in rats. *Kafkas Univ Vet Fak Derg*, 23 (3): 445-451, 2017. DOI: 10.9775/kvfd.2016.16977

Abstract

The purpose of this study was to explore the protective effects of different doses of rutin with the antioxidant and anti-inflammatory properties on acute lung injury (ALI) induced by oleic acid (OA) in rats. Thirty-five Sprague-Dawley male rats were randomly separated into five groups comprising control, rutin 150 mg, OA, rutin 75 mg + OA and rutin 150 mg + OA. In the rutin 75 mg + OA and rutin 150 mg + OA groups, the lung malondialdehyde level (MDA) was significantly lower than that of the OA group. In the rutin 75 mg + OA and rutin 150 mg + OA groups, the lung GPx (glutathione peroxidase), CAT (catalase) and SOD (superoxide dismutase) activities and GSH (glutathione) levels were significantly higher than those of the OA group, and significantly lower than those of the control group. iNOS expressions in the interstitial parts of the lungs were significantly lower than those of the OA group. The iNOS expression was lower in the 150 mg + OA group compared to the rutin 75 mg + OA group. It was concluded that on the ALI induced by OA, rutin had protective effects through the antioxidant and anti-inflammatory properties and that the treatment of rutin as a supportive treatment in ALI was found to be practically useful.

Keywords: Acute lung injury, Oleic acid, Oxidative stress, Rutin

Ratlarda Oleik Asit Kaynaklı Akut Akciğer Hasarı Üzerine Rutinin Koruyucu Etkileri

Özet

Bu çalışmanın amacı ratlarda rutin farklı dozlarının antioksidan ve anti-inflamatuar özellikleri yoluyla oleik asit (OA) ile oluşturulan akut akciğer hasarı (ALI) üzerine koruyucu etkilerini araştırmaktır. 35 adet Sprague-Dawley erkek rat kontrol, rutin 150 mg, OA, rutin 75 mg + OA ve rutin 150 mg + OA olmak üzere rasgele 5 gruba ayrıldı. Rutin 75 mg + OA ve rutin 150 mg + OA gruplarında akciğer malondialdehit (MDA) düzeyi OA grubununkine göre önemli düzeyde düşüktü. Rutin 75 mg + OA ve rutin 150 mg + OA gruplarında akciğer GPx (glutasyon peroksidaz), CAT (katalaz), SOD (süperoksit dismutaz) aktiviteleri ile GSH (glutasyon) düzeyleri OA grubununkilere göre önemli düzeyde yükseldi ve kontrol grubununkilere göre önemli düzeyde düşüktü. Rutin 75 mg + OA ve rutin 150 mg + OA gruplarında akciğerlerin interstisyel kısımlarında iNOS ekspresyonları OA grubunkilere göre önemli düzeyde düşüktü. OA ile oluşturulan ALI'de rutin antioksidan ve anti-inflamatuar özellikler aracılığıyla koruyucu etkilere sahip olduğu, ALI'de destekleyici tedavi amacıyla rutin uygulamasının pratik olarak yararlı olduğu tespit edildi.

Anahtar sözcükler: Akut akciğer hasarı, Oleik asit, Oksidatif stres, Rutin

INTRODUCTION

Acute lung injury (ALI) is a disease characterized by edema due to intra or extra pulmonary risk factors, hypoxemia resistant to oxygen treatment, alveolar hemorrhage, development of hyaline membrane, increase

in the alveolar wall thickness and histopathologic changes containing pulmonary inflammation ^[1], and clinically characterized by pulmonary edema and respiratory distress with an acute onset ^[2]. Sepsis, pneumonia, shock, aspiration, pancreatitis, blood transfusion, severe trauma and the inhalation of toxic gases are all factors creating



İletişim (Correspondence)



+90 442 2317222



sinanaktas@atauni.edu.tr

predisposition against ALI [1,3]. The mortality rate of this disease changes between 34-68% [1], and still has no effective pharmacological treatment [4]. For this reason, it is indicated that there is a necessity for the development of new and different treatment alternatives [5].

In ALI, an increase in the alveolar capillary permeability, inflammatory reactions such as polymorph nuclear neutrophil infiltration and proinflammatory cytokine release [1] and the release of reactive oxygen species (ROS) such as superoxide and hydroxyl radicals occur. Even though there are little amounts ROS formed in the physiological period, the formation of ROS in excess amounts may result in the peroxidation of the membrane lipids and the dysfunctioning of the biologic membranes [6]. It is indicated that ROS and hence oxidative stress have a very important role in the development of endothelial damage in ALI [7-9]. The lung tissue is protected against oxidative stress through antioxidant enzymes such as superoxide dismutase (SOD), catalase (CAT), glutathione peroxidase (GPx), and hemeoxygenase (HO)-1 [10].

Rutin (quercetin-3-rhamnosylglucoside) is a natural polyphenolic flavonoid found in buckwheat germ, citrus fruits, vegetables and herbal drinks such as wine and tea [11]. It has a wide range of biologic and pharmacologic activities such as antiinflammatory, antihypertensive, anticarcinogenic, vasoprotective, antioxidant, antidiabetic and cardioprotective [11,12]. These beneficial effects of rutin are because of its high radical scavenging activity and antioxidant capacity [13]. Various methods in order to create experimental ALI types have been developed on laboratory animals. The primary ones of these methods are lipopolysaccharide (LPS) [4], acid aspiration [14], surfactant consumption with saline lavage [15], pulmonary ischemia/reperfusion [16], cecal ligation and puncturing [5] and application of oleic acid (OA) [17]. OA applied intravascularly cause damage in pulmonary vascular endothelial cells and inflammation in the lungs [6].

The purpose of this study is to explore the protective effects of different doses of rutin with the antioxidant and anti-inflammatory properties on ALI induced by OA in rats.

MATERIAL and METHODS

Animal Material

In the presented study, 35 mature male Sprague-Dawley rats between the weights of 200-220 g were used as animal material. The rats that were subject to normal living standards (temperature: 24±1°C, humidity: 45±5% and 12 h light/dark cycle, feeding with standard laboratory food and ad libitum water) were provided by Ataturk University Medical Experimental Application and Research Center. This study was approved by Ataturk University Animal Experiments Local Ethical Committee (Desicion Number: 2016-1/15). Furthermore, the experimental procedure was

carried out in accordance with the International Guidelines for the Care and Use of Laboratory Animals.

Experimental Procedure

The rats were randomly divided into five groups and each group consisted of seven rats. The rats in Group I were given intravenous (i.v.) sterile saline once (control group). The rats in Group II were given rutin (rutin hydrate, Sigma Chemical Company, USA) orally in the doses of 150 mg/kg/day for 7 days. The rats in Group III were given i.v. 50 µl OA (Cis-9-octadecenoic acid, Sigma Aldrich, Germany) dissolved in 250 µl 1% BSA (Bovine Serum Albumin, Sigma Aldrich, Germany) through their tail veins once. The rats in Group IV were given rutin orally in the doses of 75 mg/kg/day for 7 days and on the 7th day the rats were given 50 µl OA i.v. through the tail veins once. The rats in Group V were given rutin orally in the doses of 150 mg/kg/day for 7 days and on the 7th day the rats were given 50 µl OA i.v. through the tail veins once. The rats in all of the groups were sacrificed with decapitation under sevoflurane anesthesia (Sevorane liquid 100%, Abbott Laboratory, Istanbul, Turkey) 24 h after the last application.

Analysis of Oxidants and Antioxidants

The homogenization of lung tissues was performed in a Teflon-glass homogenizer with the use of a buffer of 1.15% KCl in order to obtain a 1:10 (w/v) homogenate. The malondialdehyde (MDA) levels in the lung homogenate were measured by the thiobarbituric acid reaction according to the method of Placer et al. [18]. The lung CAT activity was measured by the decomposition of hydrogen peroxide at 240 nm according to the method of Aebi [19]. The measurement of protein concentration in the supernatant was also performed according to the method of Lowry et al. [20]. The measurement of lung SOD activity was performed by superoxide radical production via xanthine and xanthine oxidase, following the reaction of nitro blue tetrazolium and the formation of formazan dye [21]. The measurement of GSH content according to the method of Sedlak and Lindsay [22]. The GPx activity was measured according to the method of Matkovic et al. [23] and is expressed as U/g of protein in the lung tissue.

Histopathological Examination

Rats were killed by decapitation. The lungs were immediately removed, fixed in 10% neutral formalin solution for 24-48 h, then processed to obtain paraffin blocks. Paraffin-embedded blocks were routinely processed. 5-µm thick sections were stained with hematoxylin-eosin, and examined under a microscope under 20X magnification. Slides in the sections were graded as 0 (none), 1 (mild), 2 (moderate), and 3 (severe).

Immunohistochemical Examination

After deparaffinization, the slides were immersed

in antigen retrieval solution (pH 6.0) and heated in a microwave for 15 minutes to expose antigens. The sections were then dipped in a 3% H₂O₂ for 10 minutes to block endogenous peroxides. Afterwards, they were incubated at room temperature with polyclonal rabbit inducible nitric oxide synthase (iNOS) antibody (cat. no. Ab48394, dilution 1/400; Abcam, UK) for inflammation. Mouse and rabbit specific HRP/DAB detection IHC kit was used as follows: sections were incubated with goat anti-mouse antibody, then with streptavidin peroxides, and finally with 3,3' diaminobenzidine + chromogen. Slides were counterstained with hematoxylin. Immunoreactivity in the sections were graded as 0 (none), 1 (mild), 2 (moderate), and 3 (severe).

Statistical Analysis

The biochemical, histopathologic and immunohistochemical parameters were analyzed with one-way ANOVA using SPSS package program (version 20.0; SPSS, Chicago, IL). The Duncan test was used in the comparison of the groups. All data were presented in mean (\pm) standard error of means (SEM). Differences in histopathologic and immunohistochemical measured parameters among the five groups were analyzed with a nonparametric test (Kruskal-Wallis). Dual comparisons between the groups exhibiting significant values were evaluated with a Mann-Whitney U-test ($P < 0.05$).

RESULTS

The lung tissue MDA levels were significantly higher in the OA group compared to the control and rutin 150 mg groups. The lung tissue MDA levels significantly decreased in the rutin 75 mg + OA and rutin 150 mg + OA groups compared to the OA group. But there were no significant changes in the lung tissue MDA levels between the rutin 150 mg + OA group and the control group. The lung tissue MDA levels were significantly higher in the rutin 75 mg + OA group compared to the rutin 150 mg + OA group (*Table 1*).

The lung tissue GPx activity significantly decreased in the OA group compared to the control and rutin 150

mg groups. The lung tissue GPx activity significantly increased in the rutin 150 mg + OA group compared to the OA group. But there were no significant changes in the lung tissue GPx activities between the rutin 150 mg + OA group and the control group. The lung tissue GPx activities were significantly higher in the rutin 150 mg + OA group compared to the rutin 75 mg + OA group (*Table 1*).

The lung tissue GSH level significantly decreased in the OA group compared to the control and rutin 150 mg groups. The lung tissue GSH levels significantly increased in the rutin 150 mg + OA group compared to the OA group, but significantly decreased compared to the control group. There were no significant changes in the lung GSH levels between the rutin 75 mg + OA group and the rutin 150 mg + OA group (*Table 1*).

The lung tissue CAT activity significantly decreased in the OA group when compared to the control and rutin 150 mg groups. The lung tissue CAT activity significantly increased in the rutin 150 mg + OA group compared to the OA group. There were no significant changes in the lung tissue CAT activity between the rutin 150 mg + OA group and the control group. Furthermore, there were no differences in the lung tissue CAT activity between the rutin 150 mg + OA group and the rutin 75 mg + OA group (*Table 1*).

The lung tissue SOD activity significantly decreased in the OA group compared to the control and rutin 150 mg groups. The lung tissue SOD activity significantly increased in the rutin 150 mg + OA group compared to the OA group. There were no significant changes in the lung tissue SOD activity between the rutin 150 mg + OA group and the control group. There was a significant increase in the lung SOD activities in the rutin 150 mg + OA group compared to the rutin 75 mg + OA group (*Table 1*).

Histopathologic Evaluation

It was observed that the lung structures in the control and rutin 150 mg groups were normal (*Fig. 1A-B*). Severe inflammatory cell infiltrations and hemorrhagia were observed in the interstitial areas of the OA group (*Fig.*

Table 1. The MDA, GSH levels and GPx, CAT, SOD activities in the lung tissue of the rats in the groups

Parameter	Groups				
	Group I (Control)	Group II (Rutin 150 mg)	Group III (OA)	Group IV (75 mg rutin + OA)	Group V (150 mg rutin + OA)
MDA (nmol/g tissue)	51.26 \pm 1.02 ^c	55.95 \pm 1.41 ^c	146.22 \pm 3.05 ^a	63.34 \pm 1.97 ^b	53.08 \pm 0.87 ^c
GPx (U/g protein)	5.90 \pm 0.22 ^a	5.67 \pm 0.15 ^a	3.08 \pm 0.17 ^c	4.68 \pm 0.19 ^b	5.41 \pm 0.13 ^a
GSH (nmol/g tissue)	34.08 \pm 1.02 ^a	35.04 \pm 0.84 ^a	20.73 \pm 0.58 ^c	24.96 \pm 0.75 ^b	27.45 \pm 1.39 ^b
CAT (katal/g protein)	45.74 \pm 1.40 ^b	49.16 \pm 0.89 ^a	30.81 \pm 0.62 ^d	41.08 \pm 0.72 ^c	41.99 \pm 1.26 ^c
SOD (U/g protein)	26.93 \pm 0.33 ^b	30.33 \pm 0.47 ^a	17.36 \pm 0.46 ^d	22.16 \pm 1.51 ^c	26.07 \pm 0.70 ^b

MDA: malondialdehyde, SOD: superoxide dismutase, CAT: catalase, GPx: glutathione peroxidase, GSH: glutathione. ^{a,b,c,d} Means in rows with different superscripts differ significantly at $P < 0.01$. All the values are expressed as the mean \pm SEM of seven rats in each group

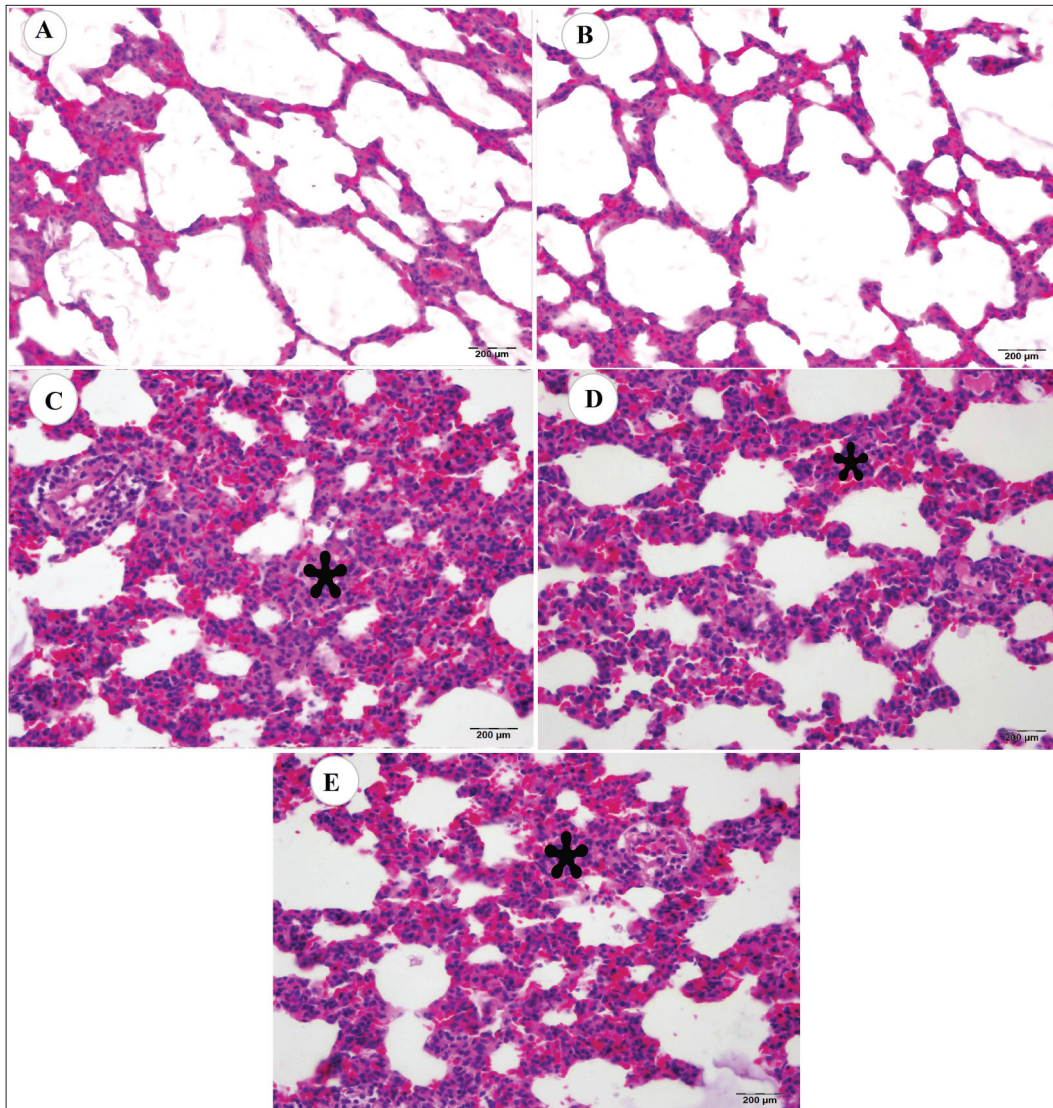


Fig 1. Normal histologic appearance in the control group (Group I) (A). Normal histologic appearance in the rutin 150 mg group (Group II) (B), Severe inflammatory cell infiltrations in the interstitial areas (*) of groups that have been treated with oleic acid (Group III) (C), Moderate inflammatory cell infiltrations in the interstitial areas (*) of the rutin 75 mg + OA group (Group IV) (D), Moderate inflammatory cell infiltrations in the interstitial areas (*) of the rutin 150 mg + OA group (Group V) (E), (H-E)

Table 2. Evaluation of the inflammatory cell infiltrations and hemorrhage in the lung tissue samples of the groups under a light microscope with x20 magnification: 0 (none), 1 (light), 2 (moderate), 3 (severe)

Histopathologic Findings	Groups				
	Group I (Control)	Group II (Rutin 150 mg)	Group III (OA)	Group IV (75 mg rutin + OA)	Group V (150 mg rutin + OA)
Inflammatory cell infiltrations and hemorrhage	0.14±0.14 ^a	0.14±0.14 ^a	2.85±0.14 ^b	2.14±0.14 ^c	2.28±0.18 ^c

All data were presented in mean (±) standard error of means (SEM) ^{a,b,c} P<0.05 versus other groups

1C). The severity of the inflammatory cell infiltrations and hemorrhage in ALI induced by OA were significantly decreased in the rutin 75 mg + OA and rutin 150 mg + OA groups (Fig. 1D-E, Table 2).

Immunohistochemical Evaluation

The lung iNOS, which is used as an inflammatory

marker, were expressed in low levels in the lungs of the rats in the control and rutin 150 mg groups (Fig. 2A-B, Table 3). The lung iNOS was severely expressed in the interstitial areas in the OA group, and the lung iNOS expression in the interstitial areas was significantly decreased in the rutin 75 mg + OA and rutin 150 mg + OA groups compared to the OA group. The lung iNOS expression was lower in the rutin

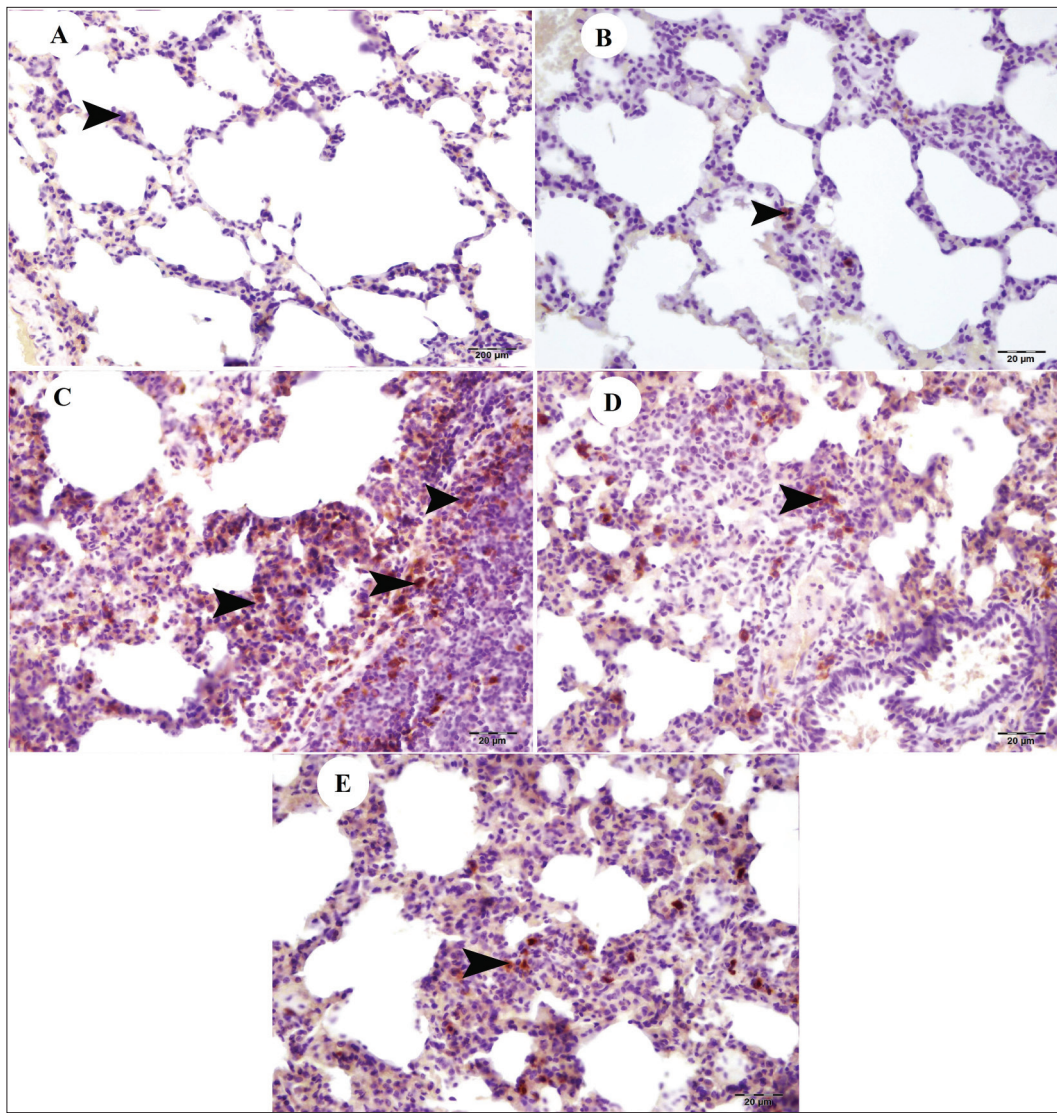


Fig 2. iNOS expressions. Low in the control group (Group I)(A), low in the rutin 150 mg group (Group II) (B), Severe in OA group (Group III) (C), Moderate in the rutin 75 mg + OA group (Group IV) (D), Low in the rutin 150 mg + OA group (Group V) (E) (arrowheads) (IHC)

Table 3. Immunopositivity of iNOS in the lung tissues of rats

Immunostaining	Groups				
	Group I (Control)	Group II (Rutin 150 mg)	Group III (OA)	Group IV (75 mg rutin + OA)	Group V (150 mg rutin + OA)
iNOS	1.00±0.21 ^a	1.14±0.14 ^a	2.85±0.14 ^b	2.14±0.14 ^c	1.42±0.20 ^d

All data were presented in mean (±) standard error of means (SEM) ^{a,b,c,d} P<0.05 versus other groups

150 mg + OA group compared to the rutin 75 mg + OA (Fig. 2C-E, Table 3).

DISCUSSION

Because the morphologic, cellular and functional changes caused by the intravenous treatment of OA are similar to those of ALI, OA treatment in experimental studies in order to research the therapeutic effects of

different agents on ALI is quite a common method [24]. There are many studies where OA is used to form ALI in many species such as rat [25], mouse [17], dog [26] and rabbit [27]. Nonenzymatic lipid peroxidation is an important point in the oxidative stress related cellular damage caused by free radicals. MDA, which is the last product of lipid peroxidation, is a good indicator of cellular damage caused by free radicals and oxidative stress [28]. Koksel et al.[25] have indicated the increased MDA levels and the development

of oxidative stress in rats with ALI induced by OA. The same results have been determined in various other studies [6,29]. In the present study in conformity with the results of Koxsel et al. [25] it was determined that the MDA level in the OA group was significantly higher than that of the control group. The MDA increase in the rat brains and kidneys caused by ischemia-reperfusion has been reported to be lessened by rutin [13,30]. Furthermore, it was determined that the increase in MDA level caused by β -amyloid 42 in BV-2 cells reduced by rutin [31]. It was found in this study that although the lung MDA level of the rutin 75 mg + OA and rutin 150 mg + OA groups significantly decreased compared to that of the OA group, it still was very high compared to that of the control group. Similarly, Yeh et al. [32] have determined that rutin has an inhibiting effect on the lipid peroxidation of rats with ALI induced by LPS.

Under normal physiological circumstances, cellular defense against oxidative damage is provided through various mechanisms and antioxidant molecules such as SOD, CAT, GSH, and GPx [33]. It is indicated that the antioxidant enzymes are consumed during ALI [34]. This result was supported in the presented study where the GSH level and the GPx, CAT and SOD activities of the lung tissue in the OA group were significantly lower compared to those in the control and rutin 150 mg groups. It is indicated that rutin is an antilipoperoxidant agent [35] and a strong free radical scavenging [36]. Rutin has been indicated to increase the levels of SOD and CAT in rats with cerebral ischemia-reperfusion [37]. Furthermore, rutin treatment has been indicated to increase the SOD, CAT and GPx activities in neurotoxicity [38], liver damage [39], renal damage [40] and testicular damage [41]. Similarly, Yeh et al. [32] have determined that rutin increases the SOD, CAT and GPx activities in rats with ALI induced by LPS. Also, Martinez et al. [42] have revealed that quercetin has anti-inflammatory effect via antioxidant activity on lung injury induced by bleomycin in hamster. Inducible nitric oxide synthase (iNOS), which is used as an inflammatory indicator, is a basic enzyme responsible for the production of high concentration nitric oxide in immune and inflammatory responses [43]. In accord with the reported studies, in the presented study there was a slight increase of iNOS expression in the lung tissue, especially in the interstitial areas, of the rats in the control and rutin 150 mg groups and there was a severe iNOS expression in the interstitial areas in the OA group treated with OA alone. In accord with the results in the presented study, Yi-Chun et al. [44] have found that rutin shows the protective effect by inhibiting neutrophil infiltration and the expression of iNOS and vascular cell adhesion molecule (VCAM)-1 in ALI model induced by LPS in mice. The studies have revealed that rutin has the protective effect via anti-inflammatory properties in ALI model [45,46]. Also, Kandemir et al. [40] have reported that iNOS is expressed in the glomeruli and mesangial cells in rats with renal damage induced by gentamicin, and that

the treatment of rutin decreases the iNOS expression and thus decreases inflammation.

As a result, it was concluded that rutin has a protective effect through its antioxidant and anti-inflammatory properties in the ALI induced by OA and that this protective effect is higher in the 150 mg dosage than the 75 mg dosage and that it would be beneficial to use rutin in the supportive treatment of ALI patients.

REFERENCES

1. Ware LB, Matthay MA: The acute respiratory distress syndrome. *N Engl J Med*, 342, 1334-1349, 2000. DOI: 10.1056/NEJM200005043421806
2. Mouratis MA, Magkrioti C, Oikonomou N, Katsifa A, Prestwich GD, Kaffe E, Aidinis V: Autotaxin and endotoxin-induced acute lung injury. *Plos One*, 10 (7):10:e0133619, 2015. DOI: 10.1371/journal.pone.0133619
3. Brun-Buisson C, Fartoukh M, Lechapt E, Honore S, Zahar JR, Cerf C, Maitre B: Contribution of blinded, protected quantitative specimens to the diagnostic and therapeutic management of ventilator-associated pneumonia. *Chest*, 128, 533-544, 2005. DOI: 10.1378/chest.128.2.533
4. Zhang Y, Liang D, Dong L, Ge X, Xu F, Chen W, Dai Y, Li H, Zou P, Yang S, Liang G: Anti-inflammatory effects of novel curcumin analogs in experimental acute lung injury. *Respir Res*, 16, 43-55, 2015. DOI: 10.1186/s12931-015-0199-1
5. Wang SY, Li ZJ, Wang X, Li WF, Lin ZF: Effect of ulinastatin on HMGB1 expression in rats with acute lung injury induced by sepsis. *Genet Mol Res*, 14, 4344-4353, 2015. DOI: 10.4238/2015.April.30.7
6. Yang C, Moriuchi H, Takase J, Ishitsuka Y, Irikura M, Irie T: Oxidative stress in early stage of acute lung injury induced with oleic acid in guinea pigs. *Biol Pharm Bull*, 26, 424-428, 2003. DOI: 10.1248/bpb.26.424
7. Tampo Y, Tsukamoto M, Yonaha M: Superoxide production from paraquat evoked by exogenous NADPH in pulmonary endothelial cells. *Free Radic Biol Med*, 27, 588-595, 1999. DOI: 10.1016/S0891-5849(99)00110-0
8. Chow CW, Abreu MTH, Suzuki T, Downey GP: Oxidative stress and acute lung injury. *Am J Respir Cell Mol Biol*, 29, 427-431, 2003. DOI: 10.1165/rcmb.F278
9. Ward PA: Oxidative stress: Acute and progressive lung injury. *Ann N Y Acad Sci*, 1203, 53-59, 2010. DOI: 10.1111/j.1749-6632.2010.05552.x
10. Kuo MY, Liao MF, Chen FL, Li YC, Yang ML, Lin RH, Kuan YH: Luteolin attenuates the pulmonary inflammatory response involves abilities of anti-oxidation and inhibition of MAPK and NF κ B pathways in mice with endotoxin-induced acute lung injury. *Food Chem Toxicol*, 49, 2660-2666, 2011. DOI: 10.1016/j.fct.2011.07.012
11. Guo R, Wei P: Studies on the antioxidant effect of rutin in the microenvironment of cationic micelles. *Microchim Acta*, 161, 233-239, 2008. DOI: 10.1007/s00604-007-0888-7
12. Sharma S, Asgar A, Javed A, Jasjeet KS, Sanjula B: Rutin: Therapeutic potential and recent advances in drug delivery. *Expert Opin Investig Drugs*, 22, 1063-1079, 2013. DOI: 10.1517/13543784.2013.805744
13. Korkmaz A, Kolankaya D: Protective effect of rutin on the ischemia/reperfusion induced damage in rat kidney. *J Surg Res*, 164, 309-315, 2010. DOI: 10.1016/j.jss.2009.03.022
14. Maniatis NA, Sfika A, Nikitopoulou I, Vassiliou AG, Magkou C, Armaganidis A, Raussos C, Kollias G, Orfanos S, Kotanidou A: Acid-induced acute lung injury in mice is associated with P44/42 and c-Jun N-terminal kinase activation and requires the function of tumor necrosis factor α receptor I. *Shock*, 38, 381-386, 2012. DOI: 10.1097/SHK.0b013e3182690ea2
15. Kamiyama J, Jesmin S, Sakuramoto H, Shimojo N, Islam M, Khatun T, Oki M, Kawano S, Mizutani T: Assessment of circulatory and pulmonary endothelin-1 levels in a lavage-induced surfactant-depleted lung injury rabbit model with repeated open endotracheal suctioning and hyperinflation. *Life Sci*, 118, 370-378, 2014. DOI: 10.1016/j.lfs.2014.04.001

16. Wu SY, Tang SE, Ko FC, Wu GC, Huang KL, Chu SJ: Valproic acid attenuates acute lung injury induced by ischemia-reperfusion in rats. *Anesthesiology*, 122, 1327-1337, 2015. DOI: 10.1097/ALN.0000000000000618
17. Dong HY, Xu M, Ji ZY, Wang YX, Dong MQ, Liu ML, Xu DQ, Zhao PT, Liu Y, Luo Y, Niu W, Zhang B, Ye J, Li ZC: Leptin attenuates lipopolysaccharide or oleic acid-induced acute lung injury in mice. *Am J Respir Cell Mol Biol*, 49, 1057-1063, 2013. DOI: 10.1165/rcmb.2012-03010C
18. Placer ZA, Cushmani LL, Johnson BC: Estimation of products of lipid peroxidation (as malondialdehyde) in biochemical systems. *Anal Biochem*, 16, 359-364, 1966. DOI: 10.1016/0003-2697(66)90167-9
19. Aebi H: Catalase *in vitro*. *Methods Enzymol*, 105, 121-126, 1984. DOI: 10.1016/S0076-6879(84)05016-3
20. Lowry OH, Rosebrough NJ, Farr AL, Randall RJ: Protein measurement with the folin phenol reagent. *J Biol Chem*, 193, 265-275, 1951.
21. Sun Y, Larry WO, Ying L: A simple method for clinical assay of superoxide dismutase. *Clin Chem*, 34 (3): 497-500, 1998.
22. Sedlak J, Lindsay RHC: Estimation of total protein bound and nonprotein sulfhydryl groups in tissue with Ellmann's reagent. *Anal Biochem*, 25, 192-205, 1968. DOI: 10.1016/0003-2697(68)90092-4
23. Matkovic B, Szabo I, Varga IS: Determination of enzyme activities in lipid peroxidation and glutathione pathways. *Lab Diagn*, 15, 248-249, 1988.
24. Golbidi S, Moriuchi H, Yang C, Irikura M, Irie T, Hamasaki N: Preventive effect of phosphoenolpyruvate on hypoxemia induced by oleic acid in guinea pigs. *Biol Pharm Bull*, 26, 336-340, 2003. DOI: 10.1248/bpb.26.336
25. Koksel O, Ozdulger A, Ercil M, Tamer L, Ercan B, Atik U, Cinel L, Cinel I, Kanik A: Effects of N-acetylcysteine on oxidant antioxidant balance in oleic acid-induced lung injury. *Exp Lung Res*, 30, 431-446, 2004. DOI: 10.1080/01902140490476319
26. Gaio E, Silva CAM, Brito F, Firmino MAP, Storck R, Freitas E: Stability of the animal model of oleic acid-induced acute lung injury. *J Bras Pneumol*, 35, 759-766, 2009. DOI: 10.1590/S1806-37132009000800007
27. Vadasz I, Morty RE, Kohstall MG, Olschewski A, Grimminger F, Seeger W, Ghofrani HA: Oleic acid inhibits alveolar fluid reabsorption. A role in acute respiratory distress syndrome. *Am J Respir Crit Care Med*, 171, 469-479, 2005. DOI: 10.1164/rccm.200407-9540C
28. Ayala A, Munoz MF, Argüelles S: Lipid Peroxidation: production, metabolism, and signaling mechanisms of malondialdehyde and 4-Hydroxy-2-Nonenal. *Oxid Med Cell Longev*, 2014, 1-31, 2014. DOI: 10.1155/2014/360438
29. Chen HI, Hsieh NK, Kao SJ, Su CF: Protective effects of propofol on acute lung injury induced by oleic acid in conscious rats. *Crit Care Med*, 36, 1214-1221, 2008. DOI: 10.1097/CCM.0b013e31816a0607
30. Annapurna A, Ansari MA, Manjunath PM: Partial role of multiple pathways in infarct size limiting effect of quercetin and rutin against cerebral ischemia-reperfusion injury in rats. *Eur Rev Med Pharmacol Sci*, 17, 491-500, 2013.
31. Wang SW, Wang YJ, Su YJ, Zhou WW, Yang SG, Zhang R, Zhao M, Li Y, Zhang Z, Zhan D, Liu R: Rutin inhibits β -amyloid aggregation and cytotoxicity, attenuates oxidative stress, and decreases the production of nitric oxide and proinflammatory cytokines. *Neurotox*, 33, 482-490, 2012. DOI: 10.1016/j.neuro.2012.03.003
32. Yeh CH, Yang JJ, Yang ML, Li YC, Kuan YH: Rutin decreases lipopolysaccharide-induced acute lung injury via inhibition of oxidative stress and the MAPK-NF- κ B pathway. *Free Rad Biol Med*, 69, 249-257, 2014. DOI: 10.1016/j.freeradbiomed.2014.01.028
33. Halliwell B: Antioxidant defense mechanism: From the beginning to the end (of the beginning). *Free Radic Res*, 31, 261-272, 1999. DOI: 10.1080/10715769900300841
34. Hosakote YM, Liu T, Castro SM, Garofalo RP, Casola A: Respiratory syncytial virus induces oxidative stress by modulating antioxidant enzymes. *Am J Respir Cell Mol Biol*, 41, 348-357, 2009. DOI: 10.1165/rcmb.2008-0330OC
35. Negre-Silvayre A, Affany A, Hariton CR: Additional antilipoperoxidant activities of alpha-tocopherol and ascorbic acid on membrane-like systems are potentiated by rutin. *Pharmacol*, 42, 262-272, 1991. DOI: 10.1159/000138807
36. Oomah BD, Mazza G: Flavonoids and antioxidant activities in buckwheat. *J Agric Food Chem*, 44, 1746-1750, 1966. DOI: 10.1021/jf9508357
37. Victor VM, Rocha M, Esplugues JV, Dela Fuente M: Role of free radicals in sepsis: antioxidant therapy. *Curr Pharm Des*, 11, 3141-3158, 2005. DOI: 10.2174/1381612054864894
38. Magalingam KB, Radhakrishnan A, Haleagrahara N: Rutin, a bioflavonoid antioxidant protects rat pheochromocytoma (PC-12) cells against 6-hydroxydopamine (6-OHDA)-induced neurotoxicity. *Int J Mol Med*, 32, 235-240, 2013. DOI: 10.3892/ijmm.2013.1375
39. Lee CC, Shen SR, Lai YJ, Wu SC: Rutin and quercetin, bioactive compounds from tartary buckwheat, prevent liver inflammatory injury. *Food Funct*, 4, 794-802, 2013. DOI: 10.1039/C3FO30389F
40. Kandemir FM, Ozkaraca M, Yildirim BA, Hanedan B, Kirbas A, Kilic K, Aktaş E, Benzer F: Rutin attenuates gentamicin-induced renal damage by reducing oxidative stress, inflammation, apoptosis, and autophagy in rats. *Ren Fail*, 37, 518-525, 2015. DOI: 10.3109/0886022X.2015.1006100
41. Abarikwu SO, Iserhienrhien BO, Badejo TA: Rutin-and selenium-attenuated cadmium-induced testicular pathophysiology in rats. *Hum Exp Toxicol*, 32, 395-406, 2013. DOI: 10.1177/0960327112472995
42. Martinez JAB, Ramos SG, Meirelles MS, Verceze AV, Rodrigues de Arantes M, Vannucchi H: Effects of quercetin on bleomycin-induced lung injury: A preliminary study. *J Bras Pneumol*, 34, 445-452, 2008. DOI: 10.1590/S1806-37132008000700003
43. Anggard E: Nitric oxide: Mediator, murderer and medicine. *Lancet*, 343, 1199-1206, 1994. DOI: 10.1016/S0140-6736(94)92405-8
44. Yi-Chun H, Hong CT, Chen ST, Lee SS, Yang ML, Lee CY, Kuo WH, Yeh CH, Kuan YH: Rutin improves endotoxin-induced acute lung injury via inhibition of iNOS and VCAM-1 expression. *Environ Toxicol*, 31, 185-191, 2016. DOI: 10.1002/tox.22033
45. Feng L, Wang D, He J, Qi D: Protective effect of rutin against lipopolysaccharide-induced acute lung injury in mice. *Nan Fang Yi Ke Da Xue Xue Bao*, 34 (9): 1282-1285, 2014.
46. Chen WY, Huang YC, Yang ML, Lee CY, Chen CJ, Yeh CH, Pan PH, Horng CT, Kuo WH, Kuan YH: Protective effect of rutin on LPS-induced acute lung injury via down-regulation of MIP-2 expression and MMP-9 activation through inhibition of Akt phosphorylation. *Int Immunopharmacol*, 22, 409-413, 2014. DOI: 10.1016/j.intimp.2014.07.026