

Ameliorative Effect of Omega-3 in Carbon Tetrachloride Toxicity

Musa KARAMAN¹  Hasan ÖZEN² Serpil DAĞ² Onur ATAKIŞI³
Gülşen ÇIĞŞAR⁴ Oktay KAYA⁵

⁽¹⁾ This study was supported by the Scientific Research Fund of Kafkas University (Project No: BAP VF 07-2014)

¹ Department of Pathology, Faculty of Veterinary Medicine, Balıkesir University, TR-10145 Balıkesir - TURKEY

² Department of Pathology, Faculty of Veterinary Medicine, Kafkas University, TR-36100 Kars - TURKEY

³ Department of Biochemistry, Faculty of Art and Science, Kafkas University, TR-36100 Kars - TURKEY

⁴ Department of Emergency, Faculty of Medicine, Kafkas University, TR-36100 Kars - TURKEY

⁵ Department of Physiology, Faculty of Medicine, Trakya University, TR-22030 Edirne - TURKEY

Article Code: KVFD-2016-15862 Received: 11.04.2016 Accepted: 11.10.2016 Published Online: 12.10.2016

Citation of This Article

Karaman M, Özen H, Dağ S, Atakışi O, Çığşar G, Kaya O: Ameliorative effect of omega-3 in carbon tetrachloride toxicity. *Kafkas Univ Vet Fak Derg*, 23, 77-85, 2017. DOI: 10.9775/kvfd.2016.15862

Abstract

Omega-3 is a polyunsaturated fatty acid known to have immunomodulatory functions. In the present study, ameliorative potential of omega-3 in experimental carbon tetrachloride (CCl₄) toxicity was investigated. Total of 40 adult male Wistar albino rats were allocated into five groups and were subcutaneously given once every two days for 6 weeks the followings: Group 1 (Control): 0.5 mL/kg serum physiologic, Group 2 (Omega): 0.5 g/kg omega-3, Group 3 (Vehicle): 0.5 mL/kg pure olive oil, Group 4 (CCl₄): 0.5 mL/kg CCl₄, Group 5 (CCl₄ + Omega): 0.5 mL/kg CCl₄ plus 0.5 g/kg omega-3. At the end of the treatments, blood samples were collected and necropsy was performed for collection of liver tissues. Serum AST, ALT, GGT, TAC, TOC, triglyceride, and visfatin levels were detected. Liver morphology and immunoreactivities against TGF- α , TGF- β , PPAR- α , and PPAR- γ were assessed. Serum AST, ALT, GGT, and TOC levels significantly increased while TAC level decreased in CCl₄ given animals as compared to the control group. No significant changes were observed in triglyceride and visfatin levels. Immunohistochemical staining revealed increased TGF- α and TGF- β expressions and decreased PPAR- α and PPAR- γ expressions in liver of CCl₄ given animals. Omega-3 supplementation has prominent effects in correcting the biochemical and immunohistochemical parameters studied as well as the tissue morphology. The results of the investigation indicated that omega-3 has ameliorative effects on the oxidative tissue degeneration and inflammatory processes induced by CCl₄ treatment in rats.

Keywords: CCl₄, Omega-3, TGF- α , TGF- β , PPAR- α , PPAR- γ

Karbon Tetraklorür Toksikasyonunda Omega-3'ün Koruyucu Etkisi

Özet

Omega-3 bağıışıklığı düzenleyici fonksiyonları olduğu bilinen çoklu doymamış bir yağ asididir. Bu çalışmada, deneysel karbon tetraklorür (CCl₄) toksikasyonunda omega-3'ün koruyucu potansiyel etkisi araştırılmıştır. Toplam 40 adet ergin erkek Wistar albino rat eşit beş gruba ayrıldı ve 6 hafta süresince her iki günde bir olmak üzere subkutan yolla deneklere tarif edilen uygulamalar yapıldı; Grup 1 (kontrol): 0.5 mL/kg serum fizyolojik, Grup 2 (Omega): 0.5 g/kg omega-3, Grup 3 (Taşııt): 0.5 mL/kg saf zeytin yağı, Grup 4 (CCl₄): 0.5 mL/kg CCl₄, Grup 5 (CCl₄ + Omega): 0.5 mL/kg CCl₄ artı 0.5 g/kg omega-3. Araştırma süresinin sonunda, kan örnekleri alınan deneklere karaciğer doku örneklerinin toplanması amacıyla nekropsi uygulandı. Serum AST, ALT, GGT, TAC, TOC, trigliserid ve visfatin seviyeleri belirlendi. Karaciğer morfolojisi incelendi ve TGF- α , TGF- β , PPAR- α ve PPAR- γ immunreaktiviteleri tespit edildi. Kontrol grubu ile karşılaştırıldığında CCl₄ verilen hayvanlarda serum AST, ALT, GGT ve TOC seviyelerinin anlamlı derecede arttığı, TAC seviyesinin ise azaldığı gözlemlendi. Trigliserid ve visfatin seviyelerinde anlamlı bir deęişikliğin olmadığı belirlendi. İmmunohistokimyasal boyamalarda CCl₄ verilen hayvanlarda TGF- α ve TGF- β immunreaktiviteleri artarken PPAR- α ve PPAR- γ immunreaktivitelerinde azalma dikkati çekti. Omega-3 takviyesinin incelenen biyokimyasal ve immunohistokimyasal parametreler üzerine olumlu etki gösterdiği belirlendi. Çalışma sonuçları omega-3'ün CCl₄ uygulanan ratlarda oluşan oksidatif doku hasarı ve yangısal süreci azaltmada etkili olduğunu göstermektedir.

Anhtar sözcükler: CCl₄, Omega-3, TGF- α , TGF- β , PPAR- α , PPAR- γ

INTRODUCTION

Liver is the primary organ in various metabolic activities. However, countless physiological and biochemical functions

as well as its anatomic localization subject the organ in development of infectious and toxic degenerations ^[1,2].

Liver may recover after acute degeneration, if not chronic inflammation and/or death may develop. The worst result



İletişim (Correspondence)



+90 543 8708684



mkaraman45@hotmail.com

of the chronic inflammation is cirrhosis. Liver cirrhosis may cause portal hypertension, hepatic encephalopathy, and organ failure that may result in death of the patient [3,4].

Carbon tetrachloride (CCl₄) is a chemical compound frequently used in experimental studies to induce liver cirrhosis in laboratory animals as a model for human. It is a transparent, non-flammable, easily vaporizable, and colorless liquid [5,6]. In mammalian body, CCl₄ is first metabolized to trichlormethyl (CCl₃) by the enzymatic reduction of cytochrome p-450 and then converted to trichlormethylperoxy radical (OCCl₃) in the presence of oxygen [5]. These reactive free radical products of CCl₄ may react with polyunsaturated fatty acids and cause the production of reactive oxygen derivatives, which triggers lipid peroxidation in biological membranes [7-9]. Oxygen radicals can induce a cascade of events that result in cellular degeneration, increased Kupffer cell activation in liver, and increased expression of some pro-fibrogenic and pro-inflammatory factors such as Tumor necrosis factor alpha (TNF-α) and Transforming growth factor beta 1 (TGF-β1) [10]. TGF-β1 functions in conversion of quiescent hepatic stellate cells into myofibroblast-like cells and suppresses degradation and stimulates production of extracellular matrix proteins [10], thereby is important in the development of hepatic fibrosis [11].

Omega-3 fatty acids are unsaturated fatty acids that have double bounds at the third carbon atom from the end of the carbon chain. Omega-3 fatty acids, which include dokozahexanoic asit (DHA), eikozapentaenoic acid (EPA) and α-linolenic acid (ALA), are the part of cellular membranes and required for normal biological functioning. DHA and EPA are members of long chained polyunsaturated fatty acids and found in fish oil in large amounts [12,13]. Studies on omega-3 fatty acids showed that they have anti-oxidant, anti-inflammatory, anti-hypertensive, and anti-apoptotic effects [14,15].

Free radicals are known to involve in degeneration of cellular molecules and hence play role in aging, cancer, arteriosclerosis, and cirrhosis. Omega-3 fatty acids were shown to partially protect against these conditions by inhibiting development of ischemia, inflammation and production of free radicals [2,16-18].

Peroxisome proliferated activated receptors (PPARs) are nuclear receptors and found in 3 isoforms, namely PPAR-α, -β, and -γ [19,20]. PPAR-α is most frequently expressed in organs rich in fat tissue such as liver, heart, skeletal muscle, brown adipose tissue and kidney. Monocytes, macrophages, lymphocytes, vascular endothelial and smooth muscle cells show expression of PPAR-α the most. While PPAR-β is expressed mostly in fat tissue, skin and brain, PPAR-γ is seen in fat tissue, large intestine, heart, kidney, pancreas and spleen [21-23]. PPARs are activated by fatty acids and their derivatives. PPAR-α is activated by leukotriene B4 while PPAR-β with prostaglandin J2 [24,25].

Visfatin is an adipokine having insulin like functions and excreted from adipose tissue. Its expression is affected by TNF-α and interleukin 6 [26]. It was shown that visfatin play roles in lipid metabolism and inflammation [27]. It was shown that PPAR-γ ligands could increase the gene expression of visfatin in macrophages [28].

In this study, the roles of TGF-α, TGF-β, PPARs and recently discovered molecule, visfatin, were investigated in an experimental hepatic fibrosis model in rats induced by CCl₄ and also the potential protective effect of omega-3. Oxidant and antioxidant capacities as well as enzymatic changes in liver tissue in relation to the tissue degeneration were investigated by immune-histopathological and biochemical means.

MATERIAL and METHODS

Animal and Treatments

The ethical approval for the research was confirmed by Kafkas University Animal Care and Use Committee (Registration Number: 2012-71). All procedures were conducted in accordance with the 'Guide for Care and Use of Laboratory Animals' published by the National Institutes of Health and the ethical guidelines of the International Association for the Study of Pain.

Forty male Wistar-Albino rats weighing 270-300 g at 3 months of age were used in the study. The rats were housed at 20±2°C and 12 h/12 h light/dark cycle through the study. Standard pellet diet and tap water were provided *ad libitum*. The animals were divided into five groups each containing 8 animals and treated once every two days during a 6-week period with subcutaneous injections of the followings: Group 1 (Control): 0.5 ml/kg serum physiologic, Group 2 (Omega): 0.5 g/kg omega-3 (18% eicosapentaenoic acid and 12% docosahexaenoic acid), Group 3 (Vehicle): 0.5 ml/kg pure olive oil, Group 4 (CCl₄): 0.5 ml/kg CCl₄ mixed 1:1 volume with olive oil, and Group 5 (CCl₄ + Omega): 0.5 ml/kg CCl₄ mixed 1:1 volume with olive oil plus 0.5 g/kg omega-3.

Biochemical Analysis

At the end of the 6-week treatment period, intracardiac blood samples were collected into the serum tubes under ether anesthesia. Serum was separated by centrifugation of the blood samples at 3000 rpm for 10 minutes. The samples were maintained at -20°C until further analyses. Serum aspartate aminotransferase (AST) (ERBA DDS), alanine aminotransferase (ALT) (ERBA DDS), gamma glutamyl transferase (GGT) (TML), triglyceride (IBL), TAC and TOC (REL Assay Diagnostics, Gaziantep-Turkey) were measured colorimetrically using a spectrophotometer (Eon Biotex, USA), serum visfatin (SUN RED CAT NO: 201-11-0472) levels were determined using an ELISA kit.

Histopathology

Animals were sacrificed by decapitation under ether anesthesia. At necropsy, liver samples were collected and fixed in 10% buffered formaldehyde solution. After routine procedures, paraffin blocks were prepared and cut at 5 μ thickness for hematoxylin and eosin staining. The liver sections were viewed under light microscope for evaluation of pathological changes.

Immunohistochemistry

Avidin biotin peroxidase method with diaminobenzidine substrate color development was used for immunohistochemical staining for PPAR- α , PPAR- γ , TGF- α , and TGF- β in liver tissue sections. Antigen retrieval was accomplished by 0.01% trypsin treatment at 37°C for 30 min. Antibody dilutions were as follow: PPAR- α (abcam ab8934) 2 μ g/mL, PPAR- γ (abcam ab19481) 4 μ g/mL, TGF- α (abcam ab112030) 5 μ g/mL, and TGF- β (abcam ab66043) 5 μ g/mL. All antibody incubations were done at room temperature for 1 h. Liver sections were finally counterstained with Mayer's hematoxylin and examined under light microscope. Immunoreactivity was evaluated based on the density of the immunostain as weak, moderate, and strong.

in situ TUNEL Method for Apoptosis

Apoptotic cell death in liver was studied by DeadEnd™ Colorimetric TUNEL System (Promega, Madison, WI, USA). Tissue sections cut at 4 μ thickness were processed through xylene and alcohol series. After several rinses in phosphate buffered saline (PBS), the sections were treated with Proteinase K solution for 30 min. Then, the sections were placed in an equilibration buffer and incubated with the reaction buffer composed of biotinylated nucleotide mix and terminal deoxynucleotidyl transferase at 37°C for 1 h. After incubation with sodium citrate solutions, endogenous peroxidase activity was blocked by 3% H₂O₂. The sections were incubated with streptavidin horseradish peroxidase solution, and color development was accomplished by 3,3-diaminobenzidine/H₂O₂. The sections were rinsed in

distilled H₂O, counterstained with 0.1% methyl green, rinsed in distilled H₂O₂, dehydrated in butanol and xylene and finally coverslipped with Permount.

Statistical Analysis

Statistical analysis were performed by the statistical package SPSS, version 10.0 (SPSS Inc., Chicago, IL, USA). Statistical analysis of data was carried out using one-way analysis of variance (ANOVA) followed by Duncan test. Results were expressed as mean \pm standard error (mean \pm SE). *P* values less than 0.05 were considered significant.

RESULTS

Biochemical Findings

The findings of biochemical investigations are summarized in *Table 1*. There were significant changes at activities of serum ALT, AST, GGT, TAC, TOC and triglycerides in the only CCl₄-treated group as compared to the control group, indicating that CCl₄ caused liver damage (*P*<0.05). No significant changes in visfatin were recorded in any of the groups studied.

Histopathological Findings

Normal liver histomorphology was observed in groups of control (*Fig. 1a*), omega, and vehicle (Figures not shown). In only CCl₄ given group, hydropic degeneration, occasional coagulation necrosis, and sinusoidal dilatation were observed. Formation of fibrosis starting from the portal regions through the parenchyma with presence of occasional necrotic hepatocytes and mononuclear cellular infiltration was evident. Interlobular areas were widened due to development of fibrosis. Pseudolobule formations were also recognizable in severely affected regions (*Fig. 1b*). The severity of the histopathological changes decreased in CCl₄ + Omega given group as compared to the only CCl₄ given group. The most recognizable findings in CCl₄ + Omega group were the fatty and hydropic degeneration of hepatocytes located close to the portal region. No fibrotic

Table 1. Serum levels of AST: Aspartate aminotransferase, ALT: Alanine aminotransferase, GGT: Gamma glutamyl transferase, TAC: Total antioxidant capacity, TOC: Total oxidant capacity, triglycerides, and visfatin in groups

Tablo 1. AST: Aspartat aminotranferaz, ALT: Alanin aminotransferaz, GGT: Gama glutamil transferaz, TAC: Total antioksidan kapasite, TOC: Total oksidan kapasite, trigliserit ve visfatin serum seviyeleri

Parameter	Control	Omega	Vehicle	CCl ₄	CCl ₄ + Omega	P value
ALT (U/L)	21.32 \pm 2.31 ^{bc}	15.60 \pm 1.97 ^c	25.88 \pm 4.28 ^{bc}	47.81 \pm 1.02 ^a	32.80 \pm 3.75 ^b	0.000
AST (U/L)	77.87 \pm 3.55 ^c	80.76 \pm 6.66 ^c	84.02 \pm 7.6 ^{bc}	118.36 \pm 6.96 ^a	99.50 \pm 4.18 ^b	0.000
GGT (U/L)	1.93 \pm 0.154 ^{bc}	1.98 \pm 0.296 ^{bc}	0.80 \pm 0.475 ^c	6.23 \pm 1.199 ^a	3.30 \pm 0.419 ^b	0.001
TAC (μ mol Trolox Eq/L)	0.96 \pm 0.03 ^a	1.005 \pm 0.02 ^a	1.002 \pm 0.05 ^a	0.66 \pm 0.04 ^c	0.822 \pm 0.04 ^b	0.000
TOC (μ mol H ₂ O ₂ Eq/L)	11.52 \pm 1.66 ^b	12.71 \pm 3.06 ^b	18.80 \pm 3.02 ^b	20.80 \pm 1.60 ^a	16.73 \pm 2.06 ^{ab}	0.037
Triglycerides (mg/dL)	104.33 \pm 6.115 ^b	107.62 \pm 5.47 ^b	132.49 \pm 12.67 ^a	103.47 \pm 3.55 ^b	109.42 \pm 6.20 ^b	0.05
Visfatin (ng/mL)	80.64 \pm 5.72	67.72 \pm 1.08	72.46 \pm 2.86	68.74 \pm 1.80	70.34 \pm 3.88	Ns

Values in a row with different superscripts differ from each other significantly (*P*<0.05)

changes were observed in any of the animals in this group. Hepatocytes located in midzonal and central areas were normal in histomorphology (Fig. 1c).

Immunohistochemistry

- **TGF- α** : In the control group, mainly weak immunoreactivity against TGF- α antibody was seen throughout the hepatic regions (Fig. 2a). Compared to the control, increased immunoreactivity was noted in liver of rats given CCl₄ only (Fig. 2b). The degree of immunoreactivity against TGF- α

antibody in CCl₄+ Omega group was near to (Fig. 2c) that observed in the control group. Immunoreactivity in omega and vehicle groups was also similar to that of the control group (Figures not shown).

- **TGF- β** : Very weak immunoreactivity against TGF- β was observed in the control group (Fig. 3a). In CCl₄ only given group, cytoplasmic immunoreactivity was observed in the hepatocytes throughout the liver sections (Fig. 3b). This immunoreactivity was stronger in hepatocytes located close to the portal regions. TGF- β immunoreactivity in CCl₄+

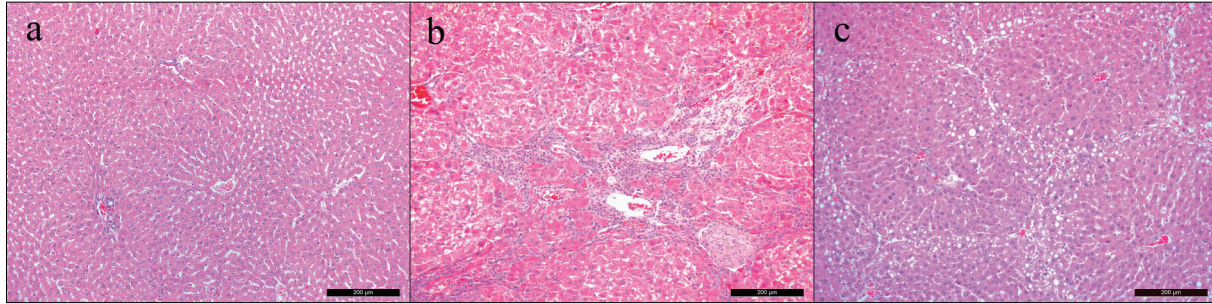


Fig 1. a) Control: Normal liver histomorphology, H&E, b) CCl₄: Hepatic fibrosis developing from the portal region through the hepatic lobules. Degenerated and occasional necrotic hepatocytes, accumulation of mononuclear cells, and some attempt for ill-formation of hepatic lobules, H&E, c) CCl₄+ Omega: Periportal fatty and hydropic degeneration, no fibrotic changes, H&E

Şekil 1. a) Kontrol: Karaciğerin normal histomorfolojisi, H&E, b) CCl₄: Portal bölgeden hepatik lobüllere doğru gelişen hepatik fibrozis. Dejenere ve nekrotik hepatositler, mononükleer hücrelerin toplanması ve bazı hatalı hepatik lobüllerin oluşma çabası, H&E, c) CCl₄+ Omega: Periportal alanda yağ ve hidropik dejenerasyonu, fibrotik değişiklikler bulunmamaktadır, H&E

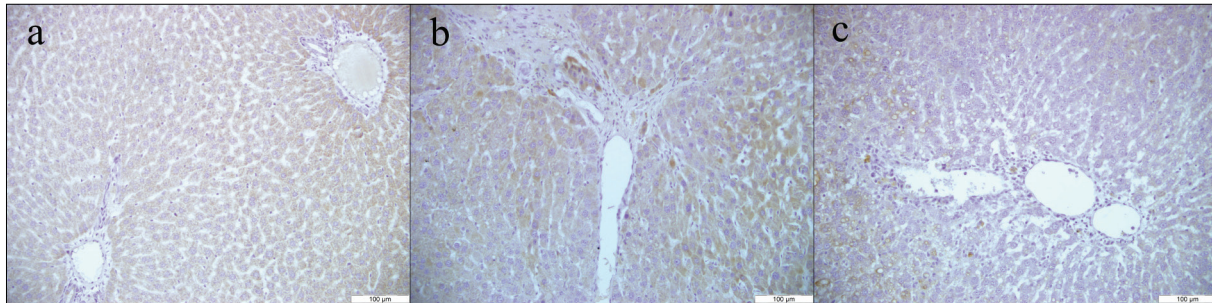


Fig 2. TGF- α immunohistochemistry; a) Control: Weak immunoreactivity, b) CCl₄: Moderate to strong immunoreactivity, c) CCl₄+ Omega: Weak immunoreactivity

Şekil 2. TGF- α immunohistokimyası; a) Kontrol: Zayıf immunoreaktivite, b) CCl₄: Ortadan güçlüye değişen derecede immunoreaktivite, c) CCl₄+ Omega: Zayıf immunoreaktivite

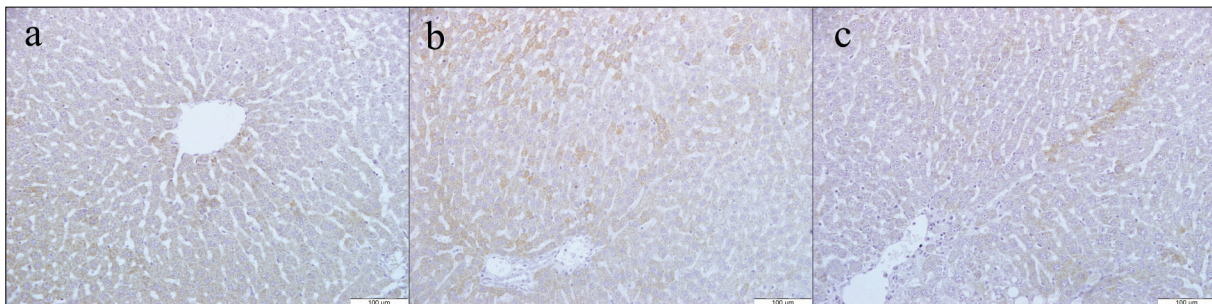


Fig 3. TGF- β immunohistochemistry; a) Control: Weak immunoreactivity, b) CCl₄: Moderate to strong immunoreactivity, c) CCl₄+ Omega: Weak immunoreactivity

Şekil 3. TGF- β immunohistokimyası; a) Kontrol: Zayıf immunoreaktivite, b) CCl₄: Ortadan güçlüye değişen derecede immunoreaktivite, c) CCl₄+ Omega: Zayıf immunoreaktivite

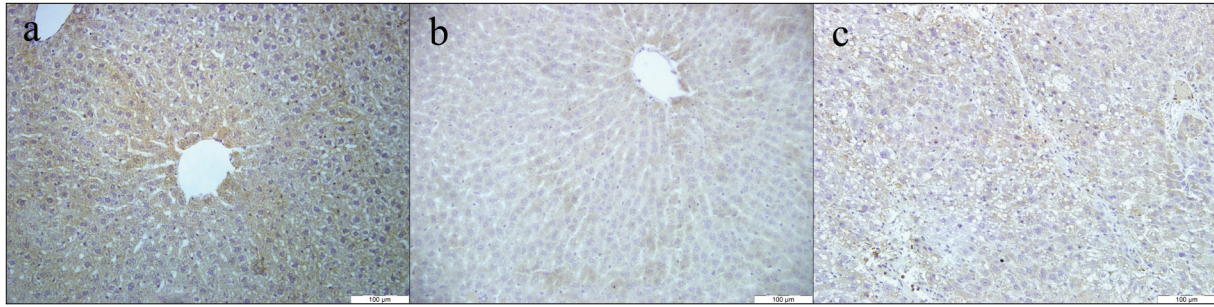


Fig 4. PPAR- α immunohistochemistry; **a)** Control: Strong immunoreactivity, **b)** CCl₄: Very weak immunoreactivity, **c)** CCl₄+ Omega: Weak to moderate immunoreactivity

Şekil 4. PPAR- α immunohistokimyası; **a)** Kontrol: Güçlü immunoreaktivite, **b)** CCl₄: Oldukça zayıf immunoreaktivite, **c)** CCl₄ + Omega: Zayıftan ortaya değişen derecede immunoreaktivite

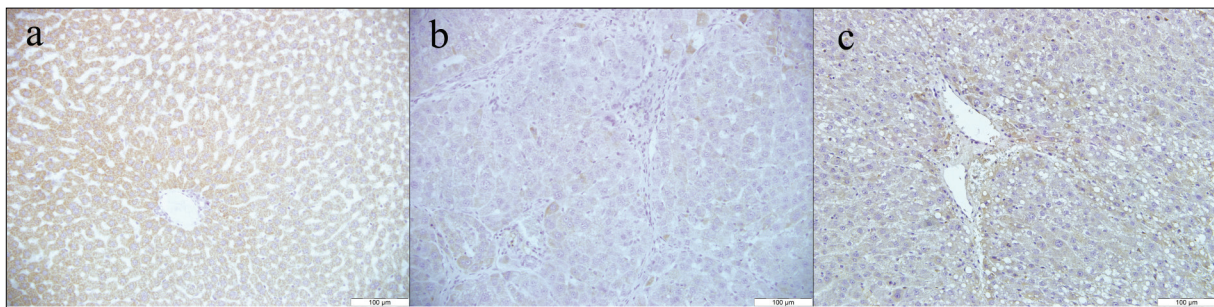


Fig 5. PPAR- γ immunohistochemistry; **a)** Control: Moderate to strong immunoreactivity, **b)** CCl₄: Very weak immunoreactivity, **c)** CCl₄ + Omega: Moderate immunoreactivity

Şekil 5. PPAR- γ immunohistokimyası; **a)** Kontrol: Oratadan güçlüye değişen derecede immunoreaktivite, **b)** CCl₄: Oldukça zayıf immunoreaktivite, **c)** CCl₄ + Omega: Orta derecede immunoreaktivite

Omega group was prominently reduced compared to the CCl₄ only given group (Fig. 3c). The pattern and density for TGF- β immunoreactivity in group 2 and 3 were similar to that of the control group (Figures not shown).

- **PPAR- α :** Strong immunoreactivity against PPAR- α was observed in the control group (Fig. 4a). Immunoreactivity was stronger in the periportal region as compared to the central region. In CCl₄ only given group, mostly no immunoreactivity was seen except in few scattered cells (Fig. 4b). Weak to moderate immunoreactivity against PPAR- α was observed in CCl₄ + Omega group (Fig. 4c). PPAR- α immunoreactivity in group 2 and 3 were similar to that of the control group (Figures not shown).

- **PPAR- γ :** Moderate to strong immunoreactivity against PPAR- γ was noted in the control group (Fig. 5a). In CCl₄ only given group, weak immunoreactivity was observed. Immunoreactivity in this group was mostly observed in the Kupffer cells though hepatocytes also showed weak immunoreactivity (Fig. 5b). Moderate immunoreaction was recognized in CCl₄ + Omega group (Fig. 5c). PPAR- γ immunoreactivity in group 2 and 3 were similar to that of the control group (Figures not shown).

Apoptosis

No apoptotic cell death was detected by *in situ* TUNEL

method in any of the groups including CCl₄ (Figures not shown).

DISCUSSION

Liver acts as the center of many important biological activities such as synthesis and/or storage of substances in the body. Hence, it might be considered that it is the most important organ in many metabolic activities. During the metabolic activation and/or detoxification of substances degenerative changes may take place resulting acute or chronic toxicity. Fatty accumulation and cirrhosis can also develop as a result of long lasting activities [1,29,30]. Despite the efforts of medical treatments, the medical management of the cases with liver degenerations might be insufficient and require other regimens [31]. The use of herbal substances and/or other non-classical medical treatments might be considered as a supplemental application [32,33]. In this study, the effect of omega-3 supplementation was assessed in the CCl₄-mediated experimental liver degeneration model in rats.

CCl₄-induced liver injury is a well-known animal model in hepatic toxicity studies [6,15,33,34]. The mode of toxicity induced by CCl₄ is that it is metabolically converted to CCl₃ by cytochrome P450, and CCl₃, under molecular oxygen rich environment, reacts with cellular proteins and poly-

unsaturated fatty acids to form more toxic trichlormethyl peroxy radicals and other oxygen radicals such as O_2^- , OH, and H_2O_2 . Adduct formation with membrane phospholipids are primarily important in cellular degeneration through development of lipid peroxidation [5]. Disrupted membrane integrity is the main cause of cellular degeneration and resulting necrosis observed microscopically. CCl_4 -induced liver degeneration and necrosis of hepatocytes were previously described by others [5,6,35-37]. In the present study, severe necrotic changes were as well observed due to CCl_4 treatment. Direct damage of lipid membranes as a result of free radicals is responsible for cellular degeneration. Increased TOC and decreased TAC levels support the notation that oxidative cellular degeneration is the cause of liver degeneration and necrosis.

Mononuclear cell infiltration and fibrosis was described in experimental CCl_4 toxicity studies [5,7,15,35,36]. Same findings were also noted in the present study. Additionally, fatty degeneration observed in many hepatocytes in CCl_4 given animals in the current study can be explained by interruption of triglyceride passage to blood and as a result their accumulation inside the cells resulting cellular vacuolation. Some studies also described apoptotic cellular death in experimental CCl_4 toxicities [38,39]. Such a cellular death was not observed in the present study. Severe cellular degeneration probably did not allow the development of apoptotic pathways as necrotic changes was the dominant cellular change in the CCl_4 given rats.

In evaluation of liver degeneration, liver function tests are commonly applied. Biochemical markers such as ALT, AST, GGT, albumin etc, can therefore provide priceless clinical clues about the development and degree of liver injury [40,41]. Upon hepatocellular degeneration release of these substances into the circulatory system increases as a result of the loss of membrane integrity. CCl_4 has been previously shown to cause increased serum levels of AST and ALT [1,32,36,42,43]. In the present study, serum ALT and AST levels were significantly higher in CCl_4 given rats as compared to the control. ALT is normally found higher in liver and kidney tissues whereas AST is higher in heart and skeletal muscles. Therefore, significant increase in serum ALT level correlates with liver injury. It has also been reported that AST level might increase in the early phase of liver degeneration and then the level could decrease with time [40,41]. In the present study increased levels of both ALT and AST clearly shows the presence of liver injury.

GGT is expressed in liver hepatocytes located close to the bile ducts, as well as renal proximal tubules, pancreas and small intestines. Serum GGT level mostly reflects the liver GGT level, and hence increased serum GGT level is usually an indicator of liver injury [40,41]. In the present study, increased serum GGT level may indicate the presence of degeneration in those hepatocytes located close to the portal regions. In histopathological observations, fibrotic changes and periportal degenerations in hepatocytes

correlates the findings of biochemical analysis. Therefore, increased serum ALT, AST, and GGT levels as well as histopathological observations indicate the presence of liver injury in CCl_4 given rats.

In estimating the presence of cellular degeneration in general, detection of reactive oxygen species is used commonly [15,33,36,43]. However, detection of individual oxidant and/or antioxidant products can be very difficult as well as time and money consuming. Besides, analyzing the individual results from different oxidant and antioxidant products can be very complicated. Therefore, measuring total oxidant and antioxidant capacities and making comparisons are much in use and practical today. Even TAC and TOC can be used in monitoring the treatment in use for a given disease or experimental study [44,45]. In the present study, TOC increased while TAC decreased in CCl_4 given animals as compared to the control. The role of oxidative stress in CCl_4 -induced hepatic toxicity has been previously shown as well [1,46,47]. On the other hand, in a CCl_4 toxicity study, unchanged TAC level has also been recorded though presence of increased TOC [48]. Omega-3 supplementation in the current investigation significantly increased the level of TAC as compared to the CCl_4 only given group. In addition, TOC level reduced, though not significantly, in the omega-3 supplemented group. These findings, together with the results of serum ALT, AST, and GGT levels, clearly indicated that omega-3 supplementation reduced the oxidative degenerative effects that are induced by CCl_4 .

Liver is a key organ in lipid metabolism and plays important roles in fatty acid uptake, conversion, oxidation, and synthesis. It has been shown that CCl_4 administration increases cholesterol and triglycerides levels [1,49-51]. In the current investigation, an increase in triglyceride level was observed only in the vehicle group in that olive oil was given to the rats. However, no significant changes were observed among the other groups. Therefore, the result of this investigation contradicts the previous studies. It has been suggested that the increase in hepatic triglyceride content in olive oil given mice might be due to the disrupted mitochondrial fatty acid oxidation [52]. This might be the case in the present study.

In regulation of lipid metabolism, adipocytokines, which are released from the adipose tissue, may be critical. They have been also shown to be responsible for differentiation of stem cells to myofibroblast-like cells, which produces large amount of extracellular matrix substances [4,31,53]. Therefore, some of the adipocytokines have been suggested to be responsible in development of hepatic fibrosis [53,54]. Visfatin, which is a newly discovered adipocytokine found in adipocytes, hepatocytes, lymphocytes, monocytes and neutrophils, was studied to investigate its relationship with liver injury in the present study. The role visfatin in acute and chronic liver degenerations and fibrosis has not been well studied before and there are some controversial results. While it has been shown that visfatin concentration

is lower in cirrhotic patients [55], in other studies no correlation was found between fibrosis and serum visfatin level [56,57]. We also did not detect any significant changes in serum visfatin level on any of the groups studied indicating that visfatin has no apparent role on the omega-3 supplementation or the liver injury induced by CCl₄.

TGF- α and TGF- β expression in liver were investigated immunohistochemically to estimate the roles of these cytokines in liver injury [15,43]. TGF- α is known to be present in healthy liver as well as many other organs. It is a strong mitogen and thought to play role in hepatocyte regeneration after hepatic injury. Harada et al. [58] stated that TGF- α expression is closely related to severity of liver dysfunction. TGF- α is able to activate hepatic stellate cells, and that triggers the development of hepatic fibrosis [59]. It has been shown that following CCl₄ treatment expression of TGF- α rapidly increases and after few days prominently decline indicating that TGF- α play role early in the liver degeneration [38]. Similar finding and continuously increased expression of TGF- β 1 was also described by Tian et al. [60]. We have detected increased TGF- α immunoreactivity in rats given only CCl₄, and the immunoreactivity was near to control group in omega-3 supplemented animals indicating that omega-3 has beneficial effects in inhibiting the degenerative effects of CCl₄.

TGF- β has been described as an important cytokine in development of hepatic fibrosis. Sources of TGF- β in liver has been described primarily to be Kupffer cells and stellate cells [61]. TGF- β is known to be the most profibrotic cytokine and its expression significantly increases in hepatic cirrhosis [57]. It has been shown in a rat model of CCl₄ toxicity that TGF- β mRNA expression significantly increases as the Kupffer cell number increase indicating that these cells are primarily responsibly in development of hepatic fibrosis [14]. In the present investigation, TGF- β immunoreactivity increased in CCl₄ given animals, and omega-3 supplementation lowered the immunoreactivity to the level that was observed in the control group.

In the present investigated, we have studied the expression of PPARs in liver tissue. All three isoforms of PPAR, - α , - β , and - γ , are known to have important regulatory roles in not only inflammatory processes but also lipid biosynthesis, glucose metabolism, cellular proliferation and differentiation [19,62]. It has been suggested that PPAR- α plays a role in hepatic steatosis, and ciprofibrate, which is a potent ligand for PPAR- α , has a potential to prevent the negative effects, indicating that PPAR- α overexpression or activation is important in amelioration of degenerative changes in liver [63]. PPAR- γ overexpression in liver has also been suggested to be important and inhibits the fibrotic changes in liver [34,64]. The number of PPAR- γ expressing cells has also been shown to decrease by CCl₄ treatment [34,42]. In the current investigation, immunohistochemical reactivity of both PPAR- α and PPAR- γ , increased in omega-3 supplemented rats compared to the only CCl₄ injected animals.

Therefore, our results correlate the findings of previous studies [42,65,66] indicating CCl₄ treatment prominently reduce the expression of PPAR- γ , and that omega-3 supplementation has beneficial effects in reducing the development of degenerative changes induced by CCl₄.

In conclusion, we have observed that intraperitoneal injection of CCl₄ at a dose of 0.5 mg/kg in rats causes fatty degeneration and necrosis as well as fibrosis especially in the periportal region in liver. Biochemical analysis for AST, ALT and GGT confirmed the hepatic injury. Decreased TAC and increased TOC levels indicated that the degenerative changes in liver were mediated by oxidative pathways. Visfatin, a recently discovered adipocytokine known to play role in fat metabolism, was shown to have no significant effect in hepatic fibrosis in the given experiment. On the other hand, increased TGF- β and decreased PPAR- α and PPAR- γ expressions were recognized to be associated with development of hepatic fibrosis in CCl₄-treated animals. Omega-3 supplementation, on the other hand was shown to normalize the above-mentioned parameters studied, indicating clearly that it has beneficial effect in amelioration of the degenerative changes induced by CCl₄. It seems that the protective effect of omega-3 is mediated primarily by inhibiting the lipid peroxidation.

REFERENCES

1. Kober H, Tatsch E, Torbitz VD, Cargnin LP, Sangoi MB, Bochi GV, da Silva AR, Barbisan F, Ribeiro EE, da Cruz IB, Moresco RN: Genoprotective and hepatoprotective effects of Guarana (*Paullinia cupana* Mart. var. *sorbilis*) on CCl₄-induced liver damage in rats. *Drug Chem Toxicol*, 39, 48-52, 2016. DOI: 10.3109/01480545.2015.1020546
2. Lee S, Kim S, Le HD, Meisel J, Strijbosch RAM, Nose V, Puder M: Reduction of hepatocellular injury after common bile duct ligation using omega-3 fatty acids. *J Pediatr Surg*, 43, 2010-2015, 2008. DOI: 10.1016/j.jpedsurg.2008.05.030
3. Berardis SI, Dawisthi Sattwika P, Najimi M, Sokal EM: Use of mesenchymal stem cells to treat liver fibrosis: Current situation and future prospects. *World J Gastroenterol*, 21, 742-758, 2015.
4. Raafat N, Abdel Aal SM, Abdo FK, El Ghonaimy NM: Mesenchymal stem cells: *In vivo* therapeutic application ameliorates carbon tetrachloride induced liver fibrosis in rats. *Int J Biochem Cell Biol*, 68, 109-118, 2015. DOI: 10.1016/j.biocel.2015.09.003
5. Manibusan MK, Odin M, Eastmond DA: Postulated carbon tetrachloride mode of action: A review. *J Environ Sci Health C Environ Carcinog Ecotoxicol Rev*, 25, 185-209, 2007. DOI: 10.1080/10590500701569398
6. Hong RT, Xu JM, Mei Q: Melatonin ameliorates experimental hepatic fibrosis induced by carbon tetrachloride in rats. *World J Gastroenterol*, 15, 1452-1458, 2009.
7. Muriel P, Alba N, Pérez-Alvarez VM, Shibayama M, Tsutsumi VK: Kupffer cells inhibition prevents hepatic lipid peroxidation and damage induced by carbon tetrachloride. *Comp Biochem Physiol C Toxicol Pharmacol*, 130, 219-226, 2001. DOI: 10.1016/S1532-0456(01)00237-X
8. Sheweita SA, Abd El-Gabar M, Bastawy M: Carbon tetrachloride-induced changes in the activity of phase II drug-metabolizing enzyme in the liver of male rats: Role of antioxidants. *Toxicology*, 165, 217-224, 2001. DOI: 10.1016/S0300-483X(01)00429-2
9. Basu S: Carbon tetrachloride-induced lipid peroxidation: Eicosanoid formation and their regulation by antioxidant nutrients. *Toxicology*, 189, 113-127, 2003. DOI: 10.1016/S0300-483X(03)00157-4
10. Nan YM, Kong LB, Ren WG, Wang RQ, Du JH, Li WC, Zhao SX,

- Zhang YG, Wu WJ, Di HL, Li Y, Yu J: Activation of peroxisome proliferator activated receptor alpha ameliorates ethanol mediated liver fibrosis in mice. *Lipids Health Dis*, 12, 1-10, 2013. DOI: 10.1186/1476-511X-12-11
11. Cheng K, Yang N, Mahato RI: TGF-beta1 gene silencing for treating liver fibrosis. *Mol Pharm*, 6, 772-779, 2009. DOI: 10.1021/mp9000469
12. Simopoulos AP: The importance of the ratio of omega-6/omega-3 essential fatty acids. *Biomed Pharmacother*, 56, 365-279, 2002. 10.1016/S0753-3322(02)00253-6
13. de Lorgeril M, Salen P: New insights into the health effects of dietary saturated and omega-6 and omega-3 polyunsaturated fatty acids. *BMC Med*, 10, 1-5, 2012, DOI: 10.1186/1741-7015-10-50
14. Pastor-Clerigues A, Marti-Bonmati E, Milara J, Almudever P, Cortijo J: Anti-inflammatory and anti-fibrotic profile of fish oil emulsions used in parenteral nutrition-associated liver disease. *PLoS One*, 9, 1-25, 2014. DOI: 10.1371/journal.pone.0115404
15. Shaaban AA, Shaker ME, Zalata KR, El-kashef HA, Ibrahim TM: Modulation of carbon tetrachloride-induced hepatic oxidative stress, injury and fibrosis by olmesartan and omega-3. *Chem Biol Interact*, 25, 81-91, 2014. DOI: 10.1016/j.cbi.2013.10.008
16. Aguilera CM, Ramirez-Tortosa CL, Quiles JL, Yago MD, Martínez-Burgos MA, Martínez-Victoria E, Gil A, Ramirez-Tortosa MC: Monounsaturated and omega-3 but not omega-6 polyunsaturated fatty acids improve hepatic fibrosis in hypercholesterolemic rabbits. *Nutrition*, 21, 63-71, 2005. DOI: 10.1016/j.nut.2004.06.029
17. Calder PC: Polyunsaturated fatty acids and inflammation. *Prostaglandins Leukot Essent Fatty Acids*, 75, 197-202, 2006. DOI: 10.1016/j.plefa.2006.05.012
18. Raptis DA, Limani P, Jang JH, Ungethüm U, Tschuor C, Graf R, Humar B, Clavien PA: GRP120 on Kupffer cells mediates hepatoprotective effects of ω -3 fatty acids. *J Hepatol*, 60, 625-632, 2014. DOI: 10.1016/j.jhep.2013.11.006
19. Issemann I, Green S: Activation of a member of the steroid hormone receptor superfamily by peroxisome proliferators. *Nature*, 347, 645-650, 1990. DOI: 10.1038/347645a0
20. Pawlak M, Lefebvre P, Staels B: Molecular mechanism of PPAR- α action and its impact on lipid metabolism, inflammation and fibrosis in non-alcoholic fatty liver disease. *J Hepatol*, 62, 720-733, 2015. DOI: 10.1016/j.jhep.2014.10.039
21. Wolfrum C, Borrmann CM, Borchers T, Spener F: Fatty acids and hypolipidemic drugs regulate peroxisome proliferator-activated receptors alpha - and gamma-mediated gene expression via liver fatty acid binding protein: A signaling path to the nucleus. *Proc Natl Acad*, 98, 2323-2328, 2001. DOI: 10.1073/pnas.051619898
22. Akbiyik F, Ray DM, Bozkaya H, Demirpence E: Ligand- and species-dependent activation of PPAR alpha. *Cell Physiol Biochem*, 14, 269-276, 2004. DOI: 10.1159/000080336
23. Tunca R, Devrim AK, Sözmen M, Dağ S, Güngör O, İpek E: The effects of gemfibrozil and ovariectomy on the peroxisome proliferator activated receptors (PPARs) in mice with experimentally induced obesity. *Kafkas Univ Vet Fak Derg*, 19, 783-792, 2013. DOI: 10.9775/kvfd.2013.8788
24. Devchand PR, Keller H, Peters JM, Vazquez M, Gonzalez FJ, Wahli W: The PPAR alpha-leukotriene B4 pathway to inflammation control. *Nature*, 384, 39-43, 1996. DOI: 10.1038/384039a0
25. Xin X, Yang S, Kowalski J, Gerritsen ME: Peroxisome proliferator-activated receptor gamma ligands are potent inhibitors of angiogenesis in vitro and in vivo. *J Biol Chem*, 274, 9116-9121, 1999. DOI: 10.1074/jbc.274.13.9116
26. Hutcheson J: Adipokines influence the inflammatory balance in autoimmunity. *Cytokine*, 75, 272-279, 2015. DOI: 10.1016/j.cyto.2015.04.004
27. Al-Suhaimi EA, Shehzad A: Leptin, resistin and visfatin: The missing link between endocrine metabolic disorders and immunity. *Eur J Med Res*, 18, 1-13, 2013. DOI: 10.1186/2047-783X-18-12
28. Mayi TH, Rigamonti E, Pattou F, Staels B, Chinetti-Gbaguidi G: Liver x Receptor (LXR) activation negatively regulates visfatin expression in macrophages. *Biochem Biophys Res Commun*, 404, 458-462, 2011. DOI: 10.1016/j.bbrc.2010.12.002
29. Lee SH, Heo SI, Li L, Lee MJ, Wang MH: Antioxidant and hepatoprotective activities of *Cirsium setidens* NAKAI against CCl₄-induced liver damage. *Am J Chin Med*, 36, 107-114, 2008. DOI: 10.1142/S0192415X0800562X
30. Kopec AK, Joshi N, Luyendyk JP: Role of hemostatic factors in hepatic injury and disease: Animal models de-liver. *J Thromb Haemost*, 14, 1337-1349, 2016. DOI: 10.1111/jth.13327
31. Thompson AJ, Patel K: Antifibrotic therapies: Will we ever get there? *Curr Gastroenterol Rep*, 12, 23-29, 2010. DOI: 10.1007/s11894-009-0080-9
32. Chang BY, Lee DS, Lee JK, Kim YC, Cho HK, Kim SY: Protective activity of kudzu (*Pueraria thunbergiana*) vine on chemically-induced hepatotoxicity: in vitro and in vivo studies. *BMC Complement Altern Med*, 16, 1-8, 2016. DOI: 10.1186/s12906-016-1023-2
33. Lu Y, Hu D, Ma S, Zhao X, Wang S, Wei G, Wang X, Wen A, Wang J: Protective effect of wedelolactone against CCl₄-induced acute liver injury in mice. *Int Immunopharmacol*, 34, 44-52, 2016. DOI: 10.1016/j.intimp.2016.02.003
34. Wang Z, Xu JP, Zheng YC, Chen W, Sun YW, Wu ZY, Luo M: Peroxisome proliferator-activated receptor gamma inhibits hepatic fibrosis in rats. *Hepatobiliary Pancreat Dis Int*, 10, 64-71, 2011. DOI: 10.1016/S1499-3872(11)60009-X
35. Jadhav VB, Thakare VN, Suralkar AA, Deshpande AD, Naik SR: Hepatoprotective activity of *Luffa acutangula* against CCl₄ and rifampicin induced liver toxicity in rats: A biochemical and histopathological evaluation. *Indian J Exp Biol*, 48, 822-829, 2010.
36. Suzek H, Celik I, Dogan A, Yildirim S: Protective effect and antioxidant role of sweetgum (*Liquidambar orientalis*) oil against carbon tetrachloride-induced hepatotoxicity and oxidative stress in rats. *Pharm Biol*, 54, 451-457, 2015. DOI: 10.3109/13880209.2015.1045086
37. Sen I, Turgut K, Ok M, Kiran MM, Güzelbekteş H, Ortatatlı M, Birdane FM, Altunok V: Effects of nutritional therapy or n-acetyl-cysteine (NAC) treatment on biochemical markers and liver histology in dogs with ccl4-induced hepatic necrosis. *Revue Med Vet*, 156, 483-490, 2005.
38. Liu J, Zhang QY, Yu LM, Liu B, Li MY, Zhu RZ: Phycocyanobilin accelerates liver regeneration and reduces mortality rate in carbon tetrachloride-induced liver injury mice. *World J Gastroenterol*, 21, 5465-5472, 2015. DOI: 10.3748/wjg.v21.i18.5465
39. Özsoy ŞY: The protective effect of kefir on carbon tetrachloride-induced histopathological changes in the livers of rats. *Kafkas Univ Vet Fak Derg*, 22, 403-408, 2016. DOI: 10.9775/kvfd.2015.14825
40. Limdi JK, Hyde GM: Evaluation of abnormal liver function tests. *Postgrad Med J*, 9, 307-312, 2003. DOI: 10.1136/pmj.79.932.307
41. Giannini EG, Testa R, Savarino V: Liver enzyme alteration: A guide for clinicians. *CMAJ*, 172, 367-379, 2005. DOI: 10.1503/cmaj.1040752
42. Guo C, Xu L, He Q, Liang T, Duan X, Li R: Anti-fibrotic effects of puerarin on CCl₄-induced hepatic fibrosis in rats possibly through the regulation of PPAR- γ expression and inhibition of PI3K/Akt pathway. *Food Chem Toxicol*, 56, 436-442, 2013. DOI: 10.1016/j.fct.2013.02.051
43. Chu X, Wang H, Jiang YM, Zhang YY, Bao YF, Zhang X, Zhang JP, Guo H, Yang F, Luan YC, Dong YS: Ameliorative effects of tannic acid on carbon tetrachloride-induced liver fibrosis in vivo and in vitro. *J Pharmacol Sci*, 130, 15-23, 2016. DOI: 10.1016/j.jphs.2015.12.002
44. Aydin M, Oktar S, Yonden Z, Ozturk OH, Yilmaz B: Direct and indirect effects of kisspeptin on liver oxidant and antioxidant systems in young male rats. *Cell Biochem Funct*, 28, 293-299, 2010. DOI: 10.1002/cbf.1656
45. Sözen S, Kisakürek M, Yildiz F, Gönültaş M, Dinçel AS: The effects of glutamine on hepatic ischemia reperfusion injury in rats. *Hippokratia*, 15, 161-166, 2011.
46. Recknagel RO, Glende EAJ, Dolak JA, Waller RL: Mechanisms of carbon tetrachloride toxicity. *Pharmacol Ther*, 43, 139-154, 1989. DOI: 10.1016/0163-7258(89)90050-8
47. Weber LW, Boll M, Stampfl A: Hepatotoxicity and mechanism of action of haloalkanes: Carbon tetrachloride as a toxicological model.

Crit Rev Toxicol, 33, 105-136, 2003. DOI: 10.1080/713611034

48. Demiroren K, Dogan Y, Kocamaz H, Ozercan IH, Ilhan S, Ustundag B, Bahcecioglu IH: Protective effects of L-carnitine, N-acetylcysteine and genistein in an experimental model of liver fibrosis. *Clin Res Hepatol Gastroenterol*, 38, 63-72, 2014. DOI: 10.1016/j.clinre.2013.08.014

49. Ince S, Keles H, Erdogan M, Hazman O, Kucukkurt I: Protective effect of boric acid against carbon tetrachloride-induced hepatotoxicity in mice. *Drug Chem Toxicol*, 35, 285-292, 2012. DOI: 10.3109/01480545.2011.607825

50. Li G, Wang XY, Suo YR, Wang HL: Protective effect of seed oil of *Herpetospermum pedunculatum* against carbon tetrachloride-induced liver injury in rats. *Saudi Med J*, 35, 981-987, 2014.

51. Yuan C, Li Z, Yi M, Wang X, Peng F, Xiao F, Chen T, Wang C, Mushtaq G, Kamal MA: Effects of polysaccharides from selenium-enriched *Pyraecanthus fortuneana* on mice liver injury. *Med Chem*, 11, 780-788, 2015.

52. Ferramosca A, Savy V, Zara V: Olive oil increases the hepatic triacylglycerol content in mice by a distinct influence on the synthesis and oxidation of fatty acids. *Biosci Biotechnol Biochem*, 72, 62-69, 2008. DOI: 10.1271/bbb.70369

53. Anty R, Lemoine M: Liver fibrogenesis and metabolic factors. *Clin Res Hepatol Gastroenterol*, 1, 10-20, 2011. DOI: 10.1016/S2210-7401(11)70003-1

54. Kukla M, Mazur W, Buldak RJ, Zwirska-Korczala K: Potential role of leptin, adiponectin and three novel adipokines-visfatin, chemerin and vaspin in chronic hepatitis. *Mol Med*, 17, 1397-1410, 2011. DOI: 10.2119/molmed.2010.00105

55. de Boer JF, Bahr MJ, Böker KH, Manns MP, Tietge UJ: Plasma levels of PBEF/Nampt/visfatin are decreased in patients with liver cirrhosis. *Am J Physiol Gastrointest Liver Physiol*, 296, G196-201, 2009. DOI: 10.1152/ajpgi.00029.2008

56. Baranova A, Jarrar MH, Stepanova M, Johnson A, Rafiq N, Gramlich T, Chandhoke V, Younossi ZM: Association of serum adipocytokines with hepatic steatosis and fibrosis in patients with chronic hepatitis C. *Digestion*, 83, 32-40, 2011.

57. Waluga M, Kukla M, Żorniak M, Kochel-Jankowska A, Kajor M, Krzemiński T, Kotulski R: Visfatin and TGF- β 1 in primary biliary cirrhosis and two other common liver diseases. *Folia Med Cracov*, 55,

59-70, 2015.

58. Harada K, Shiota G, Kawasaki H: Transforming growth factor- α and epidermal growth factor receptor in chronic liver disease and hepatocellular carcinoma. *Liver*, 19, 318-325, 1999. DOI: 10.1111/j.1478-3231.1999.tb00056.x

59. Ohyama T, Yamazaki Y, Sato K, Horiguchi N, Ichikawa T, Kakizaki S, Takagi H, Mori M: Transforming growth factor- α attenuates hepatic fibrosis: Possible involvement of matrix metalloproteinase-1. *Liver Int*, 31, 572-584, 2011. DOI: 10.1111/j.1478-3231.2011.02475.x

60. Tian XF, Ji FJ, Zang HL, Cao H: Activation of the miR-34a/SIRT1/p53 signaling pathway contributes to the progress of liver fibrosis via inducing apoptosis in hepatocytes but not in HSCs. *PLoS One*, 11, 1-14, 2016. DOI: 10.1371/journal.pone.0158657

61. Seki E, Brenner DA: Recent advancement of molecular mechanisms of liver fibrosis. *J Hepatobiliary Pancreat Sci*, 22, 512-518, 2015. DOI: 10.1002/jhbp.245

62. Abbott BD: Review of the expression of peroxisome proliferator-activated receptors alpha (PPAR alpha), beta (PPAR beta), and gamma (PPAR gamma) in rodent and human development. *Reprod Toxicol*, 27, 246-257, 2009. DOI: 10.1016/j.reprotox.2008.10.001

63. Rao MS, Papreddy K, Musunuri S, Okonkwo A: Prevention/reversal of choline deficiency-induced steatohepatitis by a peroxisome proliferator-activated receptor alpha ligand in rats. *In Vivo*, 16, 145-152, 2002.

64. Yang L, Chan CC, Kwon OS, Liu S, McGhee J, Stimpson SA, Chen LZ, Harrington WW, Symonds WT, Rockey DC: Regulation of peroxisome proliferator-activated receptor-gamma in liver fibrosis. *Am J Physiol Gastrointest Liver Physiol*, 291, G902-G911, 2006. DOI: 10.1152/ajpgi.00124.2006

65. Liu Q, Wang CY, Liu Z, Ma XS, He YH, Chen SS, Bai XY: Hydroxysafflor yellow A suppresses liver fibrosis induced by carbon tetrachloride with high-fat diet by regulating PPAR- γ /p38 MAPK signaling. *Pharm Biol*, 52, 1085-1093, 2014. DOI: 10.3109/13880209.2013.877491

66. Orfila C, Lepert JC, Alric L, Carrera G, Béraud M, Pipy B: Immunohistochemical distribution of activated nuclear factor kappa B and peroxisome proliferator-activated receptors in carbon tetrachloride-induced chronic liver injury in rats. *Histochem Cell Biol*, 123, 585-593, 2005. DOI: 10.1007/s00418-005-0785-2