

# The Effectiveness of Patellar Anti-rotational Suture Techniques on Treatment of Lateral Patellar Luxation in Calves <sup>[1]</sup>

Ali BELGE <sup>1</sup>  Rahime YAYGINGUL <sup>1</sup> Murat SARIERLER <sup>1</sup> Zeynep BOZKAN TATLI <sup>1</sup>  
Onur Ozgun DERINCEGOZ <sup>1</sup> Nuh KILIC <sup>1</sup>

<sup>[1]</sup> Part of this research was presented as an oral presentation at the 11<sup>th</sup> National Congress of Veterinary Surgery, 26<sup>th</sup>-29<sup>th</sup> June 2008, p. 20-21, Kusadası, Aydın - TURKEY

<sup>1</sup> Department of Surgery, Faculty of Veterinary Medicine, University of Adnan Menderes, TR-09016 Aydın - TURKEY

Article Code: KVFD-2016-15483 Received: 24.02.2016 Accepted: 18.05.2016 Published Online: 19.05.2016

## Abstract

In this study, it was aimed to investigate that clinical efficacy of patellar anti-rotational suture technique of luxation patellae in calves. A total of 17 Holstein calves aged between 5 days to 40 days and weighed 35 to 60 kg were subjected. All of patellar luxation cases were congenital and lateral direction. After parapatellar skin incision, subcutaneous tissues were dissected as a blunt and the joint capsules were opened in all cases. A screw (3.5 x 32 mm) was inserted where the lateral condyles and a non-absorbable suture material (size 3 or 4 silk) was passed behind the screw and around the patella and then it was tied tightly to stabilize the patella and the joint capsule was slightly narrowed. Skin and subcutaneous tissues were closed routinely. Calves started to walk without limping end of 3<sup>rd</sup> week.

**Keywords:** Lateral patellar luxation, Anti-rotational suture technique, Calf

## Buzağılarda Lateral Patellar Lukzasyon Tedavisinde Patellar Antirotasyonel Dikiş Tekniğinin Etkinliği

### Özet

Bu çalışmada, buzağılarda patellar lukzasyonun tedavisinde patellar antirotasyonel dikiş tekniğinin klinik etkinliğinin araştırılması amaçlanmıştır. Bu amaçla, 5-40 günlük yaş ve 35-60 kg canlı ağırlık aralığında değişen toplam 17 adet buzağı ele alınmıştır. Buzağılardaki patellar lukzasyonların tamamının konjenital ve lateral doğrultuda olduğu belirlenmiştir. Parapatellar deri ensizyonunu takiben, derialtı dokular küt olarak diseke edilmiş ve tüm vakalarda eklem kapsülü açılmıştır. Lateral kondüle dik olarak bir vida (3.5 x 32 mm) yerleştirilmiş, vidanın arkasından ve patellanın etrafından dolanan emilemeyen bir dikiş materyali (ipek iplik 3-4 no) sekiz şeklinde sıkıca bağlanmış daha sonra eklem kapsülü biraz daraltılmıştır. Deri ve derialtı dokular rutin şekilde kapatılmıştır. Buzağılar, üçüncü haftanın sonunda topallamadan yürümeye başlamıştır.

**Anahtar sözcükler:** Lateral patellar lukzasyon, Antirotasyonel dikiş tekniği, Buzağı

## INTRODUCTION

Patellar luxation is a common problem in small animals and it usually occurs in the medial direction in both small and large breed dogs <sup>[1-3]</sup>. In calves, although there are little number of publications on this problem and its treatment, it has been reported that it is rare in the lateral direction <sup>[4,5]</sup> or conversely, congenital patellar luxations are almost always formed in the lateral direction <sup>[6-9]</sup>.

Luxation of the patella may be congenital or acquired. Congenital causes include; coxa-varum, coxa-valgum, genu-valgum, lateral torsion which occurring in one third of the

distal femur, medial rotation of the tibia, shallow femoral trochlear groove, incorrect development of the femoral trochlear condyle <sup>[3]</sup>. However, a femoral nerve deficit associated with difficult parturition or a nerve damage that affects the quadriceps muscle group may trigger patellar luxation because of normal lateral pulling force of gluteo biceps muscle <sup>[7]</sup>. Acquired causes are indirect or direct traumas <sup>[3,7]</sup>.

The extensor (or quadriceps) mechanism of the stifle joint consists of the quadriceps, patellar tendon, patella, patellar ligament, and tibial tubercle. In healthy animals, this mechanism reaches to the middle of the knee from



**İletişim (Correspondence)**



+90 536 6381727



alibelge@hotmail.com

the proximal femur in a straight line. On the other hand, if patellar luxation develops in animals, the underlying cause is commonly malalignment of the extensor mechanism<sup>[3]</sup>.

When prevents movement of the patella on sulcus trochlea, lameness occurs. Development of the erosion and/or osteophyte formations on the edge of the sulcus trochlea and articular face of the patella and thickening of the joint capsule exacerbates the lameness<sup>[10,11]</sup>.

Displacement of the patella can be detected by clinical examination. While stifle joint is in extension position, patella is forced to luxation. Position of the patella can be determined by antero-posterior radiographic examination<sup>[4,12,13]</sup>. Also, the trochlear groove and its shape can be assessed by a tangential view of the flexed stifle (skyline imaging technique)<sup>[7]</sup>. Differential diagnosis of the patellar luxation includes avascular necrosis of the femoral head, coxofemoral luxation, and joint distortion. Prognosis is favorable for constant luxations but it is guarded for habitual luxations<sup>[3]</sup>.

Patellar luxations are classified from grade I to grade IV in small animals<sup>[11]</sup>. For farm animals it is used with slight modification<sup>[7]</sup>.

Species and age of the animal, luxation grade, accompanying complications (trochlear deformation, depth of the trochlear groove, concomitant cruciate ligament injury etc.) should be considered in determining treatment method<sup>[14]</sup>. There are many methods defined for treatment of the patellar luxation in small animals. These include; soft tissue reconstruction procedures such as overlap of lateral or medial retinaculum, fascia lata overlap, patellar and tibial anti-rotational suture ligaments, desmotomy and partial capsulectomy, quadriceps release and bone reconstruction procedures such as trochleoplasties, tibial tuberosity transposition, patellectomy, corrective osteotomies<sup>[2,3,13]</sup>.

In farm animals and horses, small number of studies has been performed about patellar luxation and there are few methods described for its treatment. These methods are lateral release and medial or lateral imbrications<sup>[7]</sup>, trochleoplasty depending on trochlear condition<sup>[7,8]</sup>, medial patellar desmotomy<sup>[15]</sup>.

In this study, it was intended that usage of the patellar anti-rotational suture ligaments used in small animals by adapting to calves and observation of healing period after surgery.

## MATERIAL and METHODS

Study materials were consisted by a total of 17 Holstein calves, 11 female and 6 male, which were presented to Veterinary Faculty Animal Hospital with clinical history of severe lameness or inability to stand up on hind limb since

birth, an ability to fully extend the stifle. Calves were 5 d to 40 d of age and weighed 35 to 60 kg.

According to anamnesis, difficulty in standing up and gait deficit has been started in all of calves just after delivery (*Table 1*). In all calves, physical, hematological and radiographical examinations were performed. In clinical and radiological examination, unilateral patellar luxation was detected in all of the calves (*Fig. 1/A*). All luxations were in lateral direction and the affected stifle joint was right in 9 calves and left in 8 calves. Also, obvious gait deficit with the calf in a unilateral crouch position was observed in all cases. Luxations were classified according to grading system for farm animals<sup>[7]</sup>.

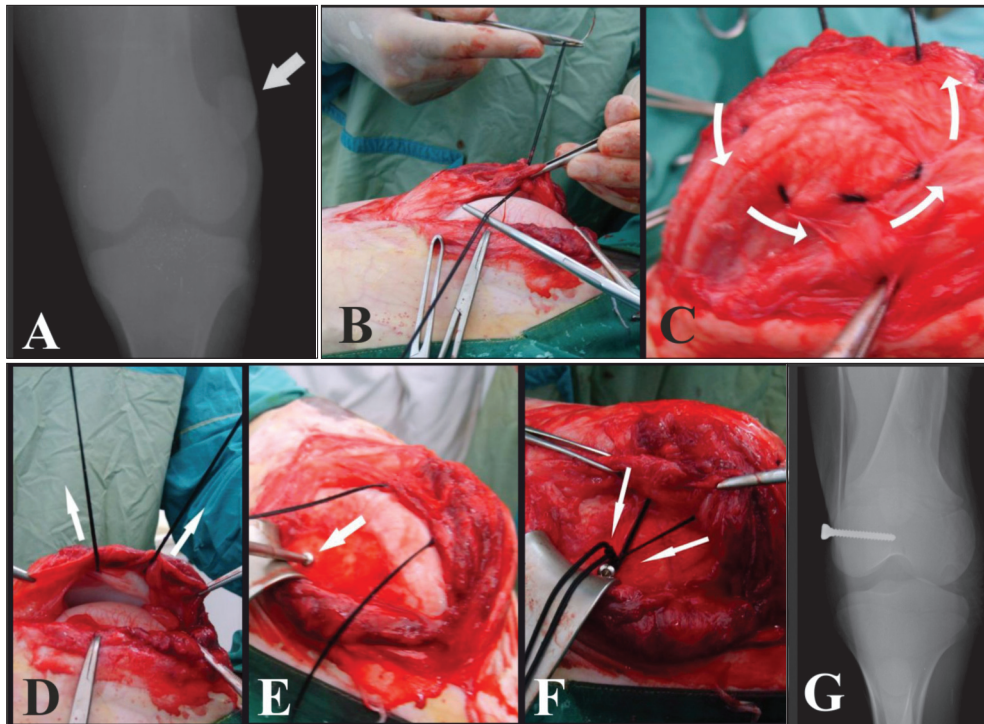
Nine calves (case number 1,4,5,6,8,9,10,12,16) had occasional patellar luxation. In these cases, the patella easily luxated manually at full extension and did not readily return to normal position when released. These cases were classified grade 2. Eight calves (case number 2,3,7,11,13,14,15,17) had permanently patellar luxation. After reposition of the patellas, they did not stay in place when the joint flexed. The depth of the trochlear groove may be different than normal. These cases were classified grade 3 (*Table 1*).

Calves underwent surgery following 12 h starving period. Anesthesia was performed with combination im xylazine HCl 0.2 mg/kg body weight (Alfazyne®, Egevet, Turkey) and ketamine HCl 1.1 mg/kg body weight (Alfamine®, Egevet, Turkey). After disinfection of the region, a 10 cm medial parapatellar skin incision was made from distal one of fourth of femur to tibial tuberosity, than the subcutaneous tissues were dissected as a blunt. The joint capsules were opened in all cases, but in 6 cases (Case No. 2, 3, 6, 7, 12, 15) although a shallow trochlear groove was seen, no intervention was made to the joint surfaces and lateral femoro-patellar ligament was not transected. A screw (3.5 x 32 mm) was inserted where the lateral fabella settled in dogs and a non-absorbable suture material (size 3 or 4 silk, Orhan Boz®, Turkey) was passed behind the screw and around the patella, then it was tied just tight enough to stabilize the patella (*Fig. 1/B, C, D, E, F*). Position of the patella was checked and the joint capsule was slightly narrowed. Skin and sub-cutaneous tissues were closed routinely. Post operative antibiotic (im, 1 mg/kg, ceftiofur HCl, Cefcloren®, Provvet, Turkey) and nonsteroidal antiinflammatory drug (im, 2.2 mg kg, flunixin meglumine, Finadyne®, Ceva-DİF, Turkey) were prescribed to the all of cases for 5 day.

## RESULTS

Age, breed, gender, weight, and clinical signs of the calves which had been operated with patellar luxation diagnosis are presented in *Table 1*.

The pulse, respiration, temperature and hematological



**Fig 1. A,** Preoperative antero-posterior radiograph of the affected leg (luxated patella are showed by arrow); **B,** Start of the circular suture; **C,** Placement of the suture material around the patella as shown by arrows; **D,** The view of suture material from articular side and stretching of the suture material in the direction of the arrows; **E,** Placement of the screw as shown by arrow; **F,** Tying of the suture material to the screw, arrows shows tightening direction; **G,** Postoperative antero-posterior radiograph of the affected leg

**Şekil 1. A,** Etkilenen bacağın antero-posterior preoperatif radyografisi (lukze olmuş patella ok ile gösterilmektedir); **B,** Sirküler dikişin başlangıcı; **C,** Oklar ile gösterildiği şekilde dikişin patella etrafına yerleştirilmesi; **D,** Dikiş materyalinin artiküler yüzeyden görünüşü ve dikiş materyalinin oklar yönünde gerdirilmesi; **E,** Ok ile gösterildiği şekilde vidanın yerleştirilmesi; **F,** Dikiş materyalinin vidaya bağlanması, gerdirme yönü okla gösterilmektedir; **G,** Etkilenen bacağın antero-posterior postoperatif radyografisi

parameters were normal. Both stifles were flexed, calves were unable to stand and when assisted adopted a crouching position. During palpation, the patella was found displaced laterally and there were atrophy muscles. The patellas were permanently luxated along with tibial torsion and misalignment of the distal tuberosity with the patellar groove and the patella could not manually reduced in grade III. The patellas were temporary luxated and the patella could manually reduce in grade II.

When was entered to the joint space, medial femoropatellar ligament was found to be flexible. Femoral condyle was nearly normal in all calves, but the trochanteric ridge was low and trochlear groove was shallow. Therefore, the patellas were not have a good, deep, secure groove to ride in and easily pulled out. There was no increase in joint fluid with exception of Case 13. The same calf had thickening of joint capsule and surrounding tissue depending on the patellar position.

In case 1, from postoperative day 7, the calf began to touch the ground with toes of the affected foot and tried to bear weight on it. It began to bear weight on the affected foot from the postoperative day 14 and was able to walk almost normal from the postoperative day 21.

Postoperatively, the calves started to touch the ground with toes of the affected foot and tried to bear weight on it within 7 day. They began to bear weight on the affected foot from the postoperative day 14 and were able to walk almost normal from the postoperative day 21.

Lameness scoring was performed at the day 15 examination. For this purpose, each of the calves was observed by investigator while an assistant made the calf walk at least 10 m, and lameness level was scored as; not exist, mild, moderate and severe (*Table 1*). According to scoring which performed at day 15, lameness level was mild in 12 calves, mild to moderate in 4 calves and moderate in 1 calf (Case no. 13). Subsequently, it was learned that 16 calves started to walk without limping at week 3 and 1 calf (Case no. 13) at week 4 (*Table 1*). Patients were followed up until the end of 3<sup>rd</sup> month with the phone call and at the end of this period the owners said that the calves have completely normal gait.

## DISCUSSION

Patellar luxations in the cattle mostly occur in dorsal direction [4,5,7,12]. According to literature, patellar luxations

**Table 1.** Information about the calves included the study**Tablo 1.** Çalışmaya dahil edilen hayvanlara ilişkin bilgiler

<sup>1</sup> CN	<sup>2</sup> B	<sup>3</sup> A	<sup>4</sup> G	<sup>5</sup> W	<sup>6</sup> SLAP	<sup>7</sup> LS	<sup>8</sup> AL	<sup>9</sup> DL	<sup>10</sup> LG	<sup>11</sup> PO-SUAL	<sup>12</sup> LS-15	<sup>13</sup> PO-WWL
1	H	5	M	45	Day 1	C	R	L	2	Day 3	ML	Week 3
2	H	5	F	45	Day 1	C	L	L	3	Day 7	MM	Week 3
3	H	5	F	40	Day 1	C	R	L	3	Day 3	MM	Week 3
4	H	6	F	35	Day 1	C	R	L	2	Day 3	ML	Week 3
5	H	9	M	40	Day 1	C	L	L	2	Day 2	ML	Week 3
6	H	10	M	45	Day 1	C	R	L	2	Day 3	ML	Week 3
7	H	11	F	35	Day 1	C	R	L	3	Day 3	ML	Week 3
8	H	8	F	40	Day 1	C	R	L	2	Day 3	ML	Week 3
9	H	5	F	40	Day 1	C	L	L	2	Day 2	ML	Week 3
10	H	6	F	45	Day 1	C	L	L	2	Day 3	ML	Week 3
11	H	9	M	50	Day 1	C	L	L	3	Day 2	MM	Week 3
12	H	10	F	35	Day 1	C	R	L	2	Day 2	ML	Week 3
13	H	40	F	60	Day 1	C	R	L	3	Day 10	MD	Week 4
14	H	15	M	40	Day 1	C	L	L	3	Day 7	MM	Week 3
15	H	10	F	35	Day 1	C	R	L	3	Day 2	ML	Week 3
16	H	12	F	40	Day 1	C	L	L	2	Day 3	ML	Week 3
17	H	7	M	45	Day 1	C	L	L	3	Day 3	ML	Week 3

<sup>1</sup>CN: Case Number; <sup>2</sup>B: Breed (H, Holstein) <sup>3</sup>A: Age (day); <sup>4</sup>G: Gender (M, Male; F, Female); <sup>5</sup>W: Weight; <sup>6</sup>SLAP: Start the Lameness After Parturition; <sup>7</sup>LS: Lameness Status (C, Constant; I; Intermittent); <sup>8</sup>AL: Affected Leg (R, Right; L, Left); <sup>9</sup>DL: Direction of the luxation (L, Lateral); <sup>10</sup>LG: Luxation Grade; <sup>11</sup>PO-SUAL: Start to use the affected leg postoperatively; <sup>12</sup>LS-15: Lameness Scoring at Day 15 (ML, Mild; MD, Moderate; MM, Mild to Moderate); <sup>13</sup>PO-WWL: Post-operative walking without limping

are rare in calves [8,16], and nearly always in lateral direction if they are congenital [6-9]. In all of 17 cases which represented our clinics with complain of lameness and diagnosed as patellar luxation, all of the luxations were determined in lateral direction.

Consistent with the literature [7,8], extremely flexed knee joint with instability and abducted hindlimbs were determined in clinical examination. Nondurable structure of the medial femora-patellar ligaments were noticed during surgery. It was learned that there were an uneventful pregnancy periods and normal delivery from histories of all calves. Based on these information, the cases were considered as congenital because of any trauma had been never happen.

The radiographs of the stifle joint revealed lateral displacement of the patella of related hind limb. The radiographs also showed a flattened and shallow trochlear groove in cases. The findings were consistent with grade II and III patellar luxation [11] and also with the previous reports on congenital lateral patellar luxation in calves [7,11].

Surgical correction of the patellar luxation required realignment of the extension mechanism and stabilization of the patella in the femoral trochlea. Narrowing of the joint capsule (capsuloraphy), sulcoplasty in young animals (trochleoplasty), fixation from the fabella to the patellar ligament (patelloplasty), wedge osteotomy in adult small

animals (wedge resection), transposition of the tibial tuberosity areused individually or in combination for treatment of patellar luxations [7,8,15].

While a little number of publication was encountered on treatment of patellar luxation in calves, compared to dogs much smaller number treatment methods were found for calves in classical literature [6-9]. Lateral release and medial or lateral imbrications can be applied separately or in combination and also these methods can be combined with one of the trochleoplasty methods when trochlear groove is shallow. According to the literature about both small and large animal, trochlear groove is not very distinct after just after delivery and it becomes deeper during growth of the animal when the patella is in it [2,3,7]. Therefore young animals with lateral patella luxation will not have a ready-made trochlear groove. Patellar luxation causes tightening of the capsular tissues on the side of luxation. In a study with 2 calves, which one is 3 months old and other one is 1 months old, trochleoplasty was performed for patellar luxation treatment and the method was successful for both cases [8]. However, ossification of the trochlea in calves is complemented by 3 months of age [7].

Kilic et al.[9] treated congenital bilateral patellar luxations in 16 calves by using transposition of partial patellar tendon and m. vastus lateralis [9]. They declared that an organic material usage may be ideal option when

considering growth periods of the calves. In this study, there was no complication during long-term follow-up period of patellar anti-rotational suture ligaments and capsulorrhaphy. Also, because of the eldest calf was 40 d old, ossification of the trochlea was not yet completed. Therefore, even is the trochlear groove was shallow, it was thought that the presence of the patella in its place after reduction would provide deepening of the groove. Hence, any intraarticular intervention was not performed, only the joint capsule was slightly narrowed by opening for to support the reduction.

An additional medial support to the retinaculum was constructed by placing a non-absorbable suture around the screw and anchoring it through the patellar ligament to encircle the patella on all sides. This suture reinforced the patella-fabellar ligament and should maintain tension on the patella throughout the normal range of movement.

The suture was not placed through the tendon of origin of the gastrocnemius. Care was taken to ensure that the suture material does not come directly into contact with the articular cartilage. Medial retinacular overlap was performed at the same time.

Also there are no reported or estimated risks of complication of the patellar anti-rotational suture ligaments technique, while lateral or medial trochlea become more susceptible to breakage in trochleoplasty procedure if too much abaxial bone is removed out <sup>[7]</sup>.

Medial patellar desmotomy technique which is applied for treatment horses with persistent or intermittent upward patellar fixation may predispose horses to distal fragmentation of the patella due to increased stress on the middle patellar ligament <sup>[13,15]</sup>. Patellar anti-rotational suture ligaments technique can be used in these cases by using lateral condylar screw placement without patellar fragmentation risk. Also, especially in smaller weight animals with a grade IV luxation, tibial crest repositioning for to increase the line of tension of the quadriceps axial to the femoropatellar joint can also be performed. Avoidance of tibial crest transposition can be reasonable for heavier animals because of the complications rate of this procedure (i.e. implant failure and/or nonunion) <sup>[7]</sup>.

For the patellar anti-rotational suture ligaments technique, which is mainly applied to small animals, it has been declared that fibrous tissue formation around the suture and realignment of soft tissues will maintain the position of the patella even if suture material has been ruptured or loosened <sup>[2]</sup>. When planning procedure applied, it was thought that fibrous tissue formation can keep the patella in its position regardless of the animal's weight. Despite the increase in weight there was no problem in the

animals which were followed up to the third month after the operation.

As a result, it was concluded that the patellar luxation is not rare problem in calves. This study suggests that grade II and III lateral patellar luxation in calves can be satisfactorily treated with patellar anti-rotational suture technique in combination with capsuloplasty along medial retinacular reinforcement of the joint capsule without sulcoplasty. If technique is performed early in the course of the disease, and the affected animal may regain the normal functions of limb in a short time.

## REFERENCES

- Dueland RT:** Orthopedic disorders of the stifle. In, Birchard SJ, Sherding Robert G (Eds): Saunders Manual of Small Animal Practice. 1031-1034, Saunders, Philadelphia, 1994.
- Read RA:** Rational treatment options for medial patellar luxation. *Waltham Focus*, 9, 28-31, 1999.
- Piermattei DL, Flo GL, De Champ C:** Handbook of Small Animal Orthopedics and Fracture Repair. 4<sup>th</sup> ed., 562-583, Saunders, Philadelphia, 2006.
- Shivaprakash BV, Usturge SM:** Observations on upward fixation of patella in cattle and buffaloes review of 350 cases. *Buffalo Bull*, 23, 58-63, 2004.
- Meungthong N, Jenajaroen K, Sukjaroen R, Cherdchutham W:** Dorsal patellar luxation management in the beef cow. Proceedings Chulalongkorn University Veterinary Science Annual Conference, 92, 2007.
- Meagher DM:** Bilateral patellar luxation in calves. *Can Vet J*, 15, 201-202, 1974.
- Ducharme NG:** Surgery of the calf musculoskeletal system. In, Fubini S, Ducharme N (Eds): Farm Animal Surgery. 497-501, Elsevier, Missouri, 2004.
- Kim NS, Alam MR, Lee JI, Park YJ, Choi IH:** Trochleoplasty in lateral patellar luxation in two calves. *J Vet Med Sci*, 67, 723-725, 2005. DOI: 10.1292/jvms.67.723//
- Kilic E, Ozaydin I, Aksoy O, Ozturk S:** The treatment of congenital bilateral lateral patellar luxation seen in calves by transposition of partial patellar tendon and m. vastus lateralis. *Kafkas Univ Vet Fak Derg*, 14, 185-190, 2008 (In Turkish). DOI: 10.9775/kvfd.2008.42-A
- Greenough PR, Mac Callum FJ, Weaver AD:** Patellar luxation. In, Greenough PR, Mac Callum FJ, Weaver AD (Eds): Lameness in Cattle. 260-263, Lippincott, Philadelphia, 1972.
- Denny HR, Butterworth SJ:** A Guide to Canine and Feline Orthopaedic Surgery. 4<sup>th</sup> ed., 512-553, Blackwell Science, Oxford, 2000.
- Hanson RR, Peyton LC:** Surgical correction of intermittent upward fixation of the patella in a Brahman cow. *Can Vet J*, 28, 675-677, 1987.
- Singh AK, Gangwar AK, Devi KS, Singh HN:** Studies on incidence and evaluation of the closed medial patellar desmotomy in lateral recumbency in bovines. *Vet World*, 8, 221-224, 2015. DOI: 10.14202/vetworld.2015.221-224
- Vasseur PB:** Stifle joint. In, Slatter D (Ed): Textbook of Small Animal Surgery. 3<sup>th</sup> ed., 2122-2126, Elsevier, Philadelphia, 2003.
- Kramer J:** Medial patellar desmotomy. In, Wilson DA, Kramer J, Constantinescu GM (Eds): Manual of Equine Field Surgery. 76-79, Saunders-Elsevier, St Louis, Missouri, 2006.
- Engelbert TA, Tate LP Jr, Richardson DC, Honore EK, Little ED:** Lateral patellar luxation in miniature horses. *Vet Surg*, 22, 293-297, 1993. DOI: 10.1111/j.1532-950X.1993.tb00401.x