

Dermoid Cyst Penetrating the Abdominal Cavity in a Persian Cat ^[1]

Volkan İPEK ¹  Ersin CANPOLAT ²

^[1] This case report was presented at VI. National Veterinary Pathology Congress (with international participation), 19-23 September, Kuşadası/Aydın, 2012

¹ Department of Pathology, Faculty of Veterinary Medicine, Uludağ University, TR-16059 Bursa - TURKEY

² Armilla Veterinary Health Center, TR-16080, Bursa - TURKEY

Article Code: KVFD-2015-14876 Received: 16.12.2015 Accepted: 09.02.2016 Published Online: 09.02.2016

Abstract

This report describes a case of dermoid cyst localized subcutaneously in the abdominal region, 2 cm to the right of linea alba in a six-year-old, neutered male Persian cat admitted with complaints of painful defecation and abdominal licking. A laparotomy was performed and the mass was seen to have penetrated the periton and extended into the abdominal space with a stalk located among the abdominal muscles and aponeuroses. Macroscopically, the oval shaped mass was approximately 3 cm in diameter, was capsulated with a grayish white tissue, had a smooth surface, and soft consistency. The cut surface of the mass contained abundant hair. Histopathologically, the mass was encapsulated with fibrous tissue. Beneath the fibrous capsule, dermal structures such as mature hair follicles, sweat glands, and sebaceous glands were observed. In the center of the mass, stratified squamous epithelium was observed lining the luminal surface of the cyst. The cyst cavity was filled with flacks of keratin and hair shafts.

Keywords: Dermoid cyst, Persian cat, Abdominal region, Pain

Bir İran Kedisinde Abdominal Boşlukla İlişkili Dermoid Kist

Özet

Bu raporda kliniğe ağırlı dışkılama ve abdominal yalama şikayeti ile getirilen, 6 yaşlı, kısırlaştırılmış, erkek bir İran kedisinde abdominal bölgede, linea albanın 2 cm sağında gözlenen, deri altı yerleşimli bir dermoid kist olgusu tanımlanmıştır. Laparatomide kitlenin peritona penetre olduğu ve abdominal kaslar ile aponevrozlar arasında bulunan bir sap ile abdominal boşluğa uzandığı görüldü. Makroskopik incelemede, oval şekilli kitle yaklaşık 3 cm çapında, kapsüllü, grimsi beyaz renkte, düzgün yüzeye sahip ve yumuşak kıvamlıydı. Kitlenin kesit yüzünde bol miktarda kıl mevcuttu. Histopatolojik incelemede, kitle fibröz kapsül ile sarılıydı ve kapsül altında olgun kıl follikülleri, ter bezleri ve sebasöz bezler mevcuttu. Lüminal yüzeyi çok katlı yassı epitelle döşeli olan kist boşluğunun, keratin parçaları ve kıl gövdeleri ile dolu olduğu görüldü.

Anahtar sözcükler: Dermoid kist, İran kedisi, Abdominal bölge, Ağrı

INTRODUCTION

Dermoid cyst is a rare congenital or acquired tumor like developmental anomaly and has been reported in dogs and cats ^[1-5]. The term dermoid cyst generically includes three different formations, namely epidermoid cyst, "true" dermoid cyst, and teratoid cyst ^[6]. Both epidermoid and dermoid cysts are surrounded by stratified squamous epithelium, however dermoid cysts contain hair follicles, sweat glands, and sebaceous glands as additional distinctive features ^[6,7]. Teratoid cyst, on the other hand, is a cystic form of teratoma and contains ectodermal, mesodermal, and endodermal structures ^[6]. Dermoid cyst

usually forms as a result of embryonal fissures' closure defects ^[2,8], but a traumatic origin has also been suggested ^[2]. There are limited numbers of reports about dermoid cysts in cats ^[2,3-5,9]. In this case report, we evaluated a periton-penetrating subcutaneous dermoid cyst occurring in the abdominal region of a Persian cat.

CASE HISTORY

A six-year-old, neutered male Persian cat was admitted to a private veterinary health center with complaints of painful defecation and abdominal licking. A subcutaneous mass was palpated in the abdominal region, approximately



İletişim (Correspondence)



+90 224 2940863 Fax: +90 224 2941202



volkanipek@uludag.edu.tr

2 cm to the right of linea alba, and radiography was performed. Radiologic evaluation revealed an approximately three cm sized mass in connection with the abdominal muscles and abdominal cavity. A laparotomy was performed. The mass was seen to have penetrated the periton and extended into the abdominal space with a stalk located among the musculus rectus abdominis and aponeuroses of other abdominal muscles. The mass was well-capsulated and the intestinal serosal vessels in contact with the mass were congested. Following the excision, the mass was submitted for pathological examination.

Macroscopically, the oval shaped mass was approximately 3 cm in diameter (long axis), was capsulated with a grayish white tissue, had a smooth surface and soft consistency. The cut surface of the mass contained abundant hair (Fig. 1). Tissue samples were taken into formalin and they were sectioned at 5 micrometer thickness after following routine tissue processing procedures. Histopathologically, the mass was encapsulated with fibrous tissue. Beneath

the fibrous capsule, dermal structures such as mature hair follicles, sweat glands, and sebaceous glands were observed (Fig. 2). In the center of the mass, stratified squamous epithelium (Fig. 3) was observed lining the luminal surface of the cyst. The cyst cavity was filled with flacks of keratin and hair shafts. No inflammation was observed.

DISCUSSION

In veterinary medicine, dermoid cyst is most frequently seen in dog breeds including Rhodesian Ridgeback, Siberian Husky, Shih Tzu, Boxer, and Kerry Blue [2,4,8]. Rhodesian Ridgeback has been reported to have a genetic tendency to dermoid cyst formation [1,2,4,10]. Dermoid cyst is a rare formation in cats and according to the authors' knowledge there are only a few reports about dermoid cysts and dermoid sinuses. In these reports, dermoid cysts and sinuses were seen in various locations such as dorsal

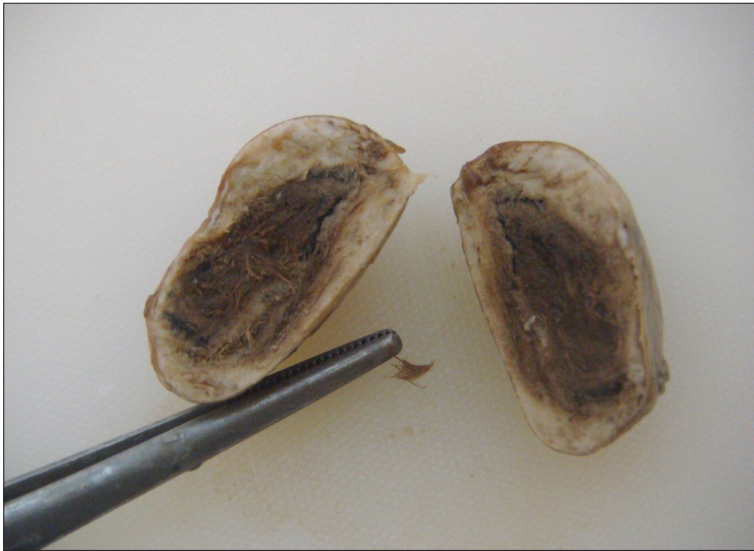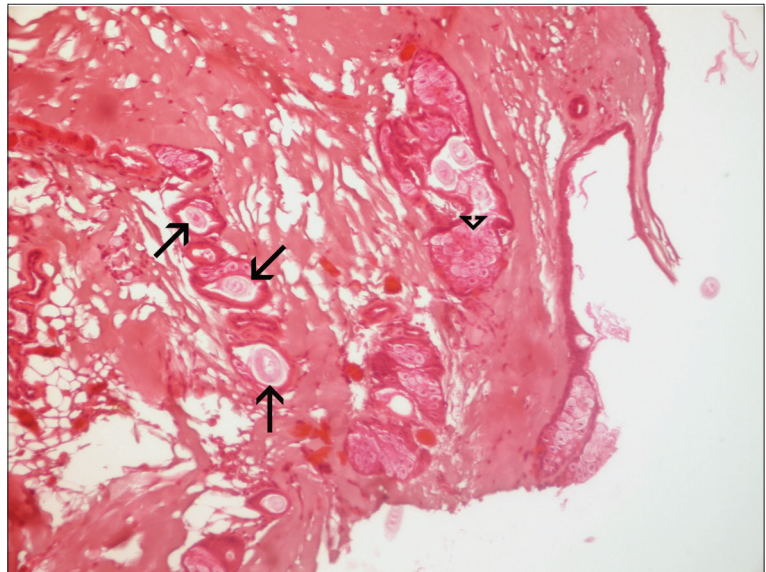


Fig 1. Cut surface of the mass contained abundant hair

Şekil 1. Kitlenin kesit yüzünde bol miktarda kıl varlığı

Fig 2. Mature hair follicles (arrows) and sebaceous glands (arrowhead), Hematoxylin-eosin, x200

Şekil 2. Olgun kıl follikülleri (oklar) ve sebasöz bezler (ok başı), Hematoksilen-eozin, 200x



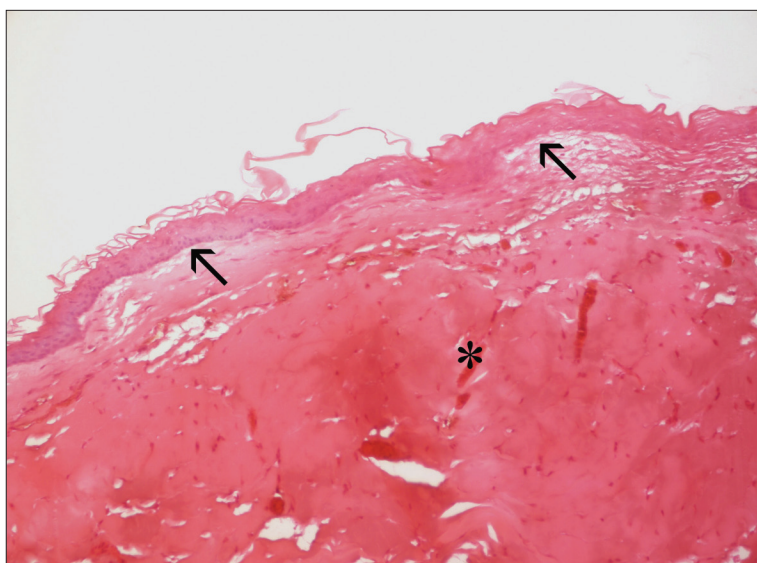


Fig 3. Keratinized stratified squamous epithelium lining the cyst wall (*arrow*) and dermis (*asterisk*), Hematoxylin-eosin, x200

Şekil 3. Keratinize çok katlı yassı epitel ile örtülü kist duvarı (*ok*) ve dermis (*asterisk*), Hematoksilen-eozin, 200x

midline, sublumbar area, flank area, in the thyroid glands, and intracranially [2,3-5,9,11]. While there is a significant predisposition for certain dog breeds, the number of reported cases in cats is too limited to suggest any such correlation.

Dermoid cysts occur as solitary or multiple [4,8], and are most commonly found on the dorsal midline of the head or along the vertebral column [2,12]. They are lined with stratified epithelium and generally contain hair, keratin, and sebum; there are hair follicles, sebaceous and apocrine glands related to the cyst wall [2,6,8]. In our case, there was a solitary cyst and the animal owner noticed the mass approximately one month prior to referral. The cyst was lined with keratinized stratified epithelium; there were hair follicles, sebaceous and sweat glands under the epithelium; and cyst cavity was filled with hair and keratin.

Clinically dermoid cysts resemble follicular cysts [2] and the differentiation is done upon the observation of fully formed hair shafts on cut surface in dermoid cysts [12]. Another similar structure is the dermoid sinus, which has a connection with skin surface as a distinctive feature [1,13], but the two terms have also been used synonymously [6,9]. In our case a diagnosis of dermoid cyst was made as no connection to the skin surface was observed and the cyst cavity contained hair.

Etiology of dermoid cyst is controversial. While some authors believe that dermoid cyst is a developmental anomaly forming as a result of a defect in neural tube split from the skin during embryogenesis [14] or epidermal closure defect along embryonic fissures that isolate an island of ectoderm in the dermis or subcutis [2], others classify it as a type of teratoma [15] or an acquired structure [6]. In our case, there was no clear evidence of a developmental or hereditary origin; the cat was middle-aged with no known history of the lesion at birth and he did not have a

traumatic history either. However it was known that the cat had been treated for chronic, generalized *Microsporum canis* infection, affecting also the abdominal region, 2.5 years ago. There is no information about any relationship between cyst formation and the mentioned infection.

Clinical symptoms vary depending on the site of lesion and serious problems may develop in some cases [3,9]. We believe that painful defecation might have occurred as a result of the compression of the cyst to the intestines in our case as evidenced by the congested veins of the intestine in contact with the cyst. Painful defecation was also completely resolved following the operation. Although risk of postoperative herniation has been reported following the removal of dermoid cysts in abdominal region of cats [4], we did not encounter such a problem in this case.

Penetration of dermoid cyst into the abdominal cavity is an unreported finding. In a previous report, dermoid cysts were observed located within the abdominal muscles in the sublumbar and left flank area in two cats, but there was no indication of penetration into the abdominal cavity [4]. A stalk located within the abdominal muscles and aponeuroses established the connection between the subcutis and the mass in the abdominal space in our case.

In conclusion, to the best of the authors' knowledge, this is the first case of a dermoid cyst reported in a Persian cat. Intrusion of the abdominal cavity with painful defecation is an unexpected, previously unreported finding. We recommend the veterinarians who encounter cats with complaints of painful defecation and/or mass present in the abdominal region to consider dermoid cyst in the differential diagnosis.

ACKNOWLEDGMENT

The authors are grateful to Dr. İ. Taci CANGÜL for assistance in the scientific and language edition.

REFERENCES

1. **Tshamala M, Moens Y:** True dermoid cyst in a Rhodesian Ridgeback. *J Small Anim Pract*, 41 (8): 352-353, 2000.
2. **Akhtardanesh B, Kheirandish R, Azari O:** Dermoid cyst in a domestic shorthair cat. *Asian Pac J Trop Biomed*, 2, 247-249, 2012. DOI: 10.1016/S2221-1691(12)60051-3
3. **Henderson JP, Pearson GR, Smerdon TN:** Dermoid cyst of the spinal cord associated with ataxia in a cat. *J Small Anim Pract*, 34, 402-404, 1993. DOI: 10.1111/j.1748-5827.1993.tb02734.x
4. **Rochat MC, Campbell GA, Panciera RJ:** Dermoid cysts in cats: Two cases and a review of the literature. *J Vet Diagn Invest*, 8 (4): 505-507, 1996.
5. **Chenier S, Quesnel A, Girard C:** Intracranial teratoma and dermoid cyst in a kitten. *J Vet Diagn Invest*, 10, 381-384, 1998. DOI: 10.1177/104063879801000417
6. **Oryan A, Hashemnia M, Mohammadalipour A:** Dermoid cyst in camel: A case report and brief literature review. *Comp Clin Pathol*, 21, 555-558, 2012. DOI: 10.1007/s00580-010-1128-9
7. **Hansmann F, Herder V, Ernst H, Baumgartner W:** Spinal epidermoid cyst in a SJL mouse: Case report and literature review. *J Comp Pathol*, 145, 373-377, 2011. DOI: 10.1016/j.jcpa.2011.03.002
8. **Alam MM, Rahman MM:** A three years retrospective study on the nature and cause of ocular dermoids in cross-bred calves. *Open Vet J*, 2 (1): 10-14, 2012.
9. **Tong T, Simpson DJ:** Spinal dermoid sinus in a Burmese cat with paraparesis. *Aust Vet J*, 87 (11): 450-454, 2009. DOI: 10.1111/j.1751-0813.2009.00487.x
10. **Mann GE, Stration J:** Dermoid sinus in the Rhodesian ridgeback. *J Small Anim Pract*, 7, 631-642, 1966. DOI: 10.1111/j.1748-5827.1966.tb04388.x
11. **Kiviranta AM, Lappalainen AK, Hagner K, Jokinen T:** Dermoid sinus and spina bifida in three dogs and a cat. *J Small Anim Pract*, 52, 319-324, 2011. DOI: 10.1111/j.1748-5827.2011.01062.x
12. **Villalobos A:** Tumors of the Skin and Soft Tissues. In, Kahn CM (Ed): The Merck Veterinary Manual. 10th ed., 863-864, Whitehouse Station, New Jersey, Merck & Co. Inc., 2010.
13. **Hillyer LL, Jackson AP, Quinn GC, Day MJ:** Epidermal (infundibular) and dermoid cysts in the dorsal midline of a three-year-old thoroughbred-cross gelding. *Vet Dermatol*, 14, 205-209, 2003. DOI: 10.1046/j.1365-3164.2003.00345.x
14. **Howard-Martin M, Bowles MH:** Intracranial dermoid cyst in a dog. *J Am Vet Med Assoc*, 192 (2): 215-216, 1988.
15. **Kountakis SE, Minotti AM, Maillard A, Stiernberg CM:** Teratomas of the head and neck. *Am J Otolaryngol*, 15 (4): 292-296, 1994.