

## Why Systematic Examination is Important in Diagnosis of Eye Diseases? Lacrimal Punctal Atresia of a Dog Treated When He Reaches the Age of 15 Months (Göz Hastalıklarının Tanısında Sistematik Muayene Neden Önemlidir? Bir Köpekte Ancak 15 Aylık İken Tedavi Edilebilen Atresia Punkta Lakrimalis Olgusu)

Sırrı AVKİ<sup>1</sup> ✍️ Kürşad YİĞİTARSLAN<sup>1</sup>

<sup>1</sup> Mehmet Akif Ersoy University, Faculty of Veterinary Medicine, Department of Surgery, TR-15030 Burdur - TURKEY

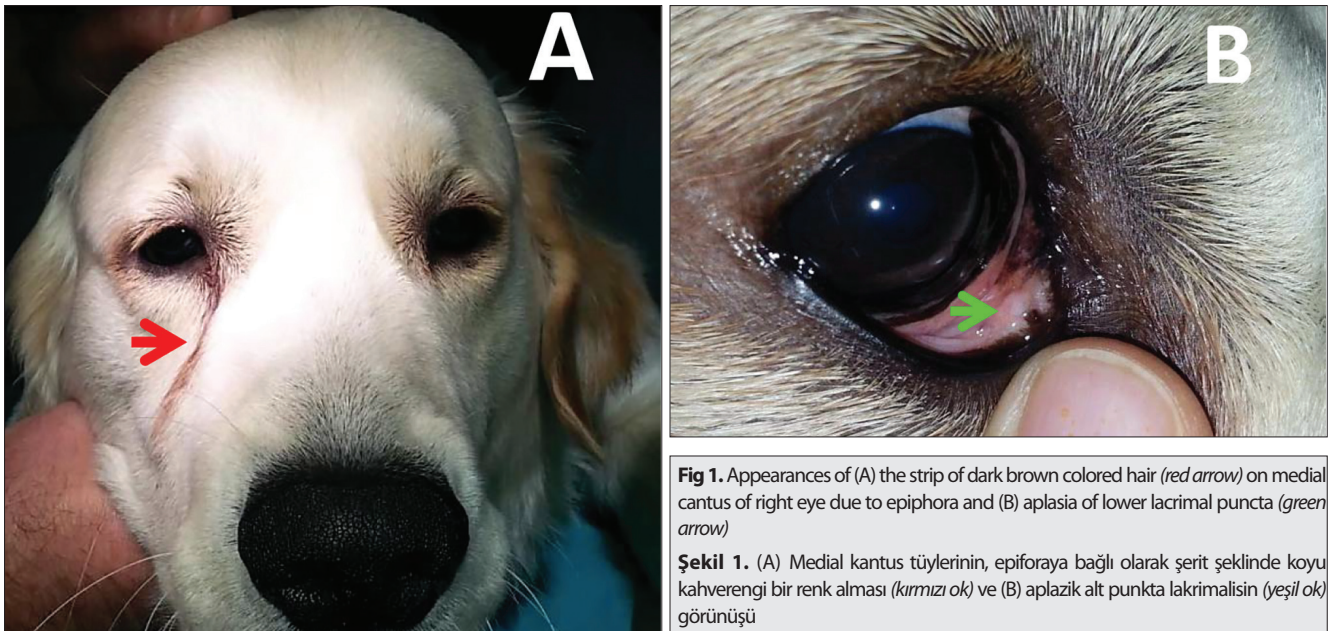
Article Code: KVFD-2015-14404 Published Online: 01.10.2015

Dear Editor,

“Punctal atresia” or “imperforate lacrimal puncta” is the most frequently diagnosed congenital anomaly of canine nasolacrimal drainage system. The most affected breeds are American Cocker Spaniels, Bedlington Terriers, Golden Retrievers, Poodles and Samoyeds. It can affect the superior, inferior, or both puncta, and it may be either unilateral or bilateral. Although superior (upper) punctal atresia is asymptomatic, a dramatic epiphora is present in inferior (lower) punctal atresia. The diagnosis is confirmed by detailed observation with a magnifying loupe or operating microscope, nasolacrimal duct cannulation and Jones test (appearance of fluorescein stain in nasal punctum after dropped into ipsilateral eye). In most cases atresia consists of a layer of conjunctiva over the punctal lumen, therefore nasolacrimal flushing through the upper punctum with a gentle pressure will cause the conjunctiva over the lower canaliculus to bulge. Surgical excision of this ballooning conjunctiva and cannulating the canaliculi to assure a patent duct during healing are main steps of treatment<sup>[1-3]</sup>.

A 15 months old male Golden Retriever dog was brought to the MAKU Animal Hospital on October 2013 with complaint of chronic epiphora in right eye. As it was learned from the patient's story, the complaint was present since he born, and treatment attempts of 3 different veterinarians (1: conjunctivitis follicularis; 2: allergic conjunctivitis and 3: bacterial conjunctivitis) give any improvement. The overall health status was good on physical examination but constant tear drainage over medial canthus and a strip of dark brown colored hair on this area (Fig. 1A) was obvious. Any inflammatory changes were recorded neither in cornea nor conjunctiva. The main Schirmer test value of the affected eye was 17.8 mm/min and signs such as blepharospasm, photophobia or ocular pain were absent. During the observations with a magnifying loupe, the absence of inferior lacrimal puncta was noticed (Fig. 1B). With the negative result in Jones test with 2% fluorescein stain, the case was diagnosed as right inferior lacrimal punctal atresia.

The dog was anesthetized to reestablish tear inflow of the congenitally occluded puncta surgically. Nasolacrimal



**Fig 1.** Appearances of (A) the strip of dark brown colored hair (red arrow) on medial canthus of right eye due to epiphora and (B) aplasia of lower lacrimal puncta (green arrow)

**Şekil 1.** (A) Medial kantus tüylerinin, epiforaya bağlı olarak şerit şeklinde koyu kahverengi bir renk alması (kırmızı ok) ve (B) aplazik alt punkta lakrimalisin (yeşil ok) görünüşü



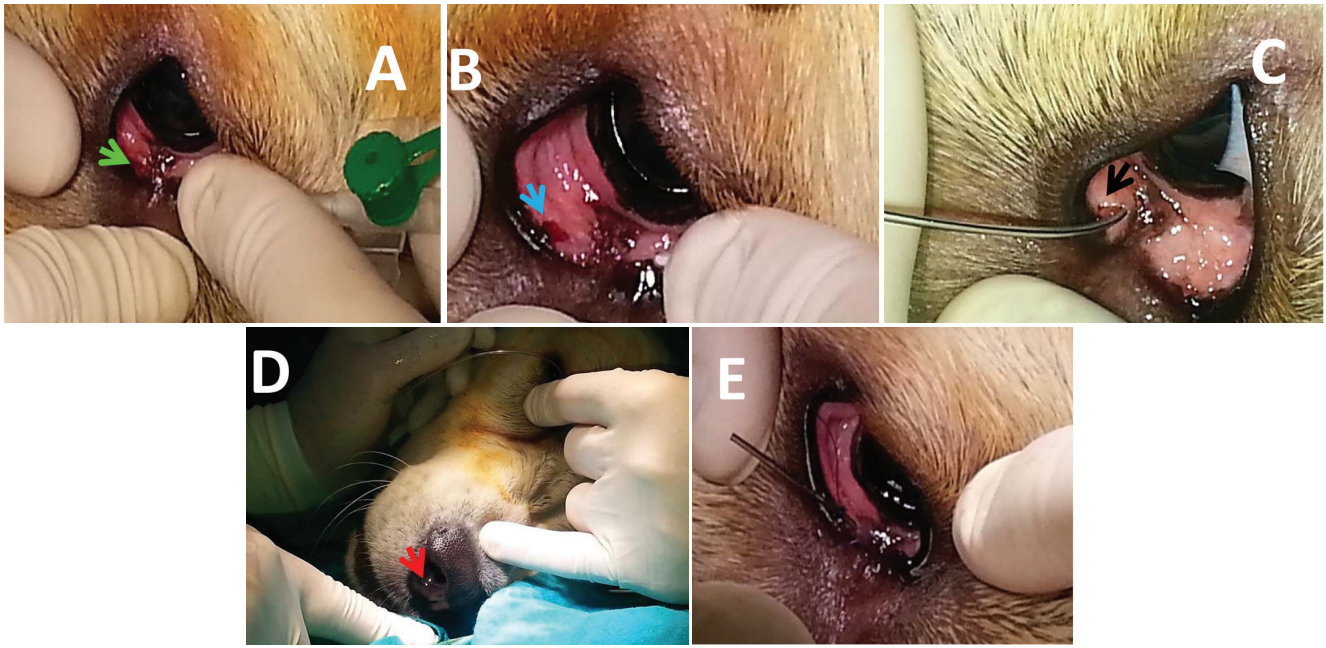
İletişim (Correspondence)



+90 248 2132102

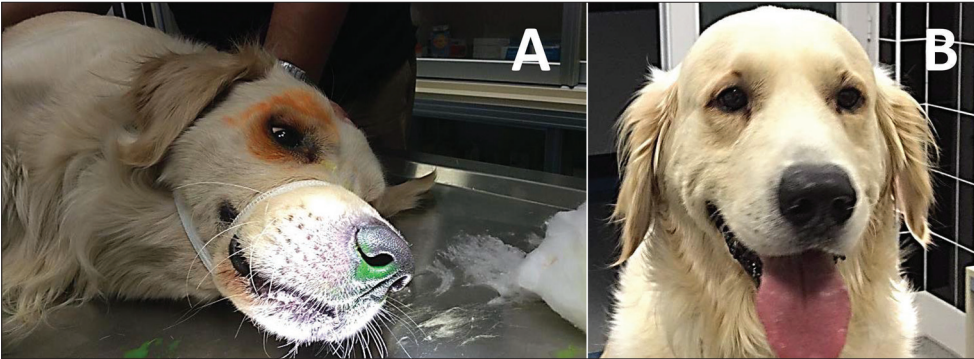


sirriavki@hotmail.com



**Fig 2.** Appearances of (A) nasolacrimal flush performed through the superior lacrimal punctum results with ballooning of the conjunctiva over the punctal atresia (green arrow); (B) circularly excised ballooning conjunctiva (blue arrow); (C) catheterized excision entrance with a silicon tube (black arrow); (D) tip of silicon tube passed through ductus nasolacrimalis and reached to nasal puncta (red arrow) and (E) upper end of silicon catheter bend and sutured over the margin of lower eyelid

**Şekil 2.** (A) Üst lakrimalis'ten yapılan lavajın atrezik punkta üzerindeki konjunktivada yol açtığı balonlaşma (yeşil ok); (B) balonlaşan konjunktivanın sirküler eksizyonu (mavi ok); (C) silikon bir kateter ile yerleştirilen eksizyon girişi (siyah ok); (D) ductus nazolakrimalisten ilerletilen ve punkta nazalise ulaşan (kırmızı ok) silikon kateterin ucu ve (E) alt göz kapağı kenarına bükülerek dikilen silikon kateterin görünüşleri



**Fig 3.** Appearances of (A) Jones test with 2% fluorescein resulted in staining nasal puncta and (B) disappeared discoloration of medial cantus hair

**Şekil 3.** (A) %2'lik fluorescein ile yapılan Jones testinde punkta nazalisin boyanması ve (B) medial kantus tüylerinde ortadan kalkan renk değişikliğinin görünüşleri

flush was performed through the upper lacrimal punctum via an 18 gauge angiocat and saline solution. Upon the positive pressure of injected saline solution, a slight ballooning of the conjunctiva over the punctal atresia was observed (Fig. 2A). The ballooning conjunctiva was circularly excised with a fine scissors (Fig. 2B). A silicon catheter was inserted through the excision entrance and advanced until the tip was appears in right nasal puncta (Fig. 2C-D). The upper end of silicon catheter was bend over the margin of lower eyelid and sutured with 3 simple sutures parallel to eyelashes (Fig. 2E). The affected eye was then treated with a topical antibiotic solution for 7 days. An Elizabeth collar was applied to ensure the inserted catheter in place for 3 weeks. After 3 weeks the catheter was removed and the patency of nasolacrimal duct was controlled periodically. In controls following 1.5 years the opening of lower canaliculi was intact, Jones test was positive (Fig. 3A), and discoloration in medial cantus hair was disappeared (Fig. 3B).

The adventure of this dog since birth with his right eye teaches our colleagues 3 important lessons: 1- A complete or systematical examination is important in diagnosis of eye diseases. Otherwise we may overlook a simple disorder and waste time with wrong therapies. 2- Puppies with chronic tear discharge but any ocular inflammation must be controlled for nasolacrimal drainage system anomalies. 3- Jones test seems to be an efficacious tool for nasolacrimal duct patency.

## REFERENCES

1. Avki S: Oftalmik muayene ve tanı. In, Sırrı Avki (Ed): Temel Veteriner Oftalmoloji. 3-45, Medipres Yayıncılık, Malatya, 2012.
2. Avki S: Köpeklerde gözyaşı ve nazolakrimal sistemlerinin hastalık ve operasyonları. In, Sırrı Avki (Ed): Temel Veteriner Oftalmoloji. 107-130, Medipres Yayıncılık, Malatya, 2012.
3. Slatter DH: Fundamentals of Veterinary Ophtalmology. 323-346, WB Saunders Company, Philadelphia, 1981.