

A Rare Complication of the Postpartum Period in a Dog: Vaginal Evisceration

Güneş ERDOĞAN¹  Eyyüp Hakan UÇAR¹ Büşra KİBAR²
Cevdet PEKER¹ Tuğra AKKUŞ¹

¹ Department of Obstetrics and Gynecology, Faculty of Veterinary Medicine, Adnan Menderes University, TR-09100 Aydın - TURKEY

² Department of Surgery, Faculty of Veterinary Medicine, Adnan Menderes University, TR-09100 Aydın - TURKEY

Article Code: KVFD-2015-14373 Received: 11.09.2015 Accepted: 13.11.2015 Published Online: 13.11.2015

Abstract

Transvaginal intestinal evisceration was observed in a 4-year-old bitch had given birth to four puppies ten days ago, normally. For treatment, median laparotomy was performed and intestinal loops were reduced via intra-abdominal traction. Intestinal anastomosis was performed on the necrotic part of bowel and the vaginal tear was sutured. According to owner's request, the bitch underwent ovariohysterectomy. The dog was recovered without any complications. The absence of the main etiological factors in this case, suggests the presence of different factors that need to be investigated in the aetiology of the disease. To our knowledge, this case represents the first report of the successful management of transvaginal evisceration in pet practice.

Keywords: Vaginal tear, Evisceration, Dog

Köpekte Nadir Görülen Bir Postpartum Dönem Komplikasyonu: Vaginal Eviserasyon

Özet

On gün önce normal yolla 4 yavru doğurmuş olan 4 yaşlı bir köpekte transvaginal barsak eviserasyonu görüldü. Tedavi amacıyla median laparotomi uygulandı ve barsak segmenti abdomenden içeriye çekilerek red işlemi gerçekleştirildi. Dışarı çıkan barsak segmentinin nekrotik kısmında anastomoz uygulandı ve vaginal yırtık dikildi. Hasta sahibinin isteği üzerine ovariohisterektomi operasyonu ile hasta kısırlaştırıldı. Köpek herhangi bir komplikasyon oluşmadan iyileşti. Bu hastada vaginal rupturun bilinen nedenlerinin bulunmaması, hastalığın etiolojisinde araştırılması gereken farklı etmenlerin varlığını düşündürmektedir. Bildiğimiz kadarıyla, bu olgu sunumu pet hekimliğinde başarıyla sağaltılmış ilk transvaginal eviserasyon raporudur.

Anahtar sözcükler: Vaginal yırtık, Eviserasyon, Köpek

INTRODUCTION

Obstetric injuries involving the rupture of the genital tract in animals has been seen in periparturient stage, usually during dystocia and also it need the acute surgery. Although the prevalence of obstetric injuries in dogs is not known exactly, the manual interventions^[1], improper use of oxytocic drugs^[2] and also oversized fetuses^[3,4] are reported as high risk factors. According to previously articles, it is seen that a large portion of ruptures have been localized on the uterine wall. Meanwhile, limited reports about the complications of the vaginal tear following dystocia in dog^[5-7] have been reported. Although the surgical approaches were performed immediately in both

cases, postoperative prognosis was reported as the poor, with high mortality. Therefore, it can be seen that the limited knowledge about the predisposing factors and therapy of this rare emergency condition.

In this case report, the clinical and operative findings of the transvaginal small intestinal evisceration treated successfully was presented in a dog, 10 days after normal parturition.

CASE HISTORY

A 4-year-old female hound dog was referred to our clinic due to intestinal evisceration becoming in last hour.



İletişim (Correspondence)



+90 256 22470700/119, Fax: +90 256 22470720



gunesems@yahoo.com

In patient history, it was recorded that the dog had given birth to four healthy normal-sized puppies ten days ago, normally. Parturition had taken place without any challenge and lasted about six hours. During the subsequent ten days, no complication had been observed.

On physical examination, the dog was recorded as severely underweight (15 kg), depressed with pain and dehydrated. It was clearly seen that the intestinal loops protruding from the rima vulva (Fig. 1). Moreover, a part of small intestine turned to colour in dark purple and was recorded in high risk of necrosis as shown Fig. 2. In vaginal digital examination, the localization of the vaginal tear could not be detected. At first, the intestinal loops were washed with 0.9% saline solution and also a venous blood sample was taken for haematological analysis. Also, fluid therapy was initiated using lactated Ringers intravenously (iv). Test results were normally except the severe leucocytosis (WBC=24.10x10⁹/l, RBC=5.65x10¹²/l HGB=12.8 g/dl, HCT=37.6%). Regarding to the intestinal rupture risk at the manual reposition, median laparotomy was performed

immediately. While under general anaesthesia with 7 mg/kg propofol (Propofol, Abbot®, Turkey) and 2% isoflurane (Isoflurane®, Adeka, Turkey) the intestinal loops were reduced via carefully intra-abdominal traction. The affected portion of the intestines was resected and a bowel anastomosis was performed using 2-0 Polyglactin 910 (Vicryl®, Ethicon, UK) thread with Schimiden and Lembert sutures as shown Fig. 3. Moreover, the vaginal tear, the cause of this evisceration was detected on the left side of vagina (9 centimetres from cervix) and it was repaired with 2-0 Polyglactin 910 (Vicryl®, Ethicon, UK) thread with simple continuous sutures (Fig. 4). The abdominal cavity was flushed with warm 0.9% saline solution and intestines were repositioned in carefully. According to owner's request, the patient was spayed with ovariectomy before abdominal closure. Postoperatively, cephalosporin (Sefazol®, Mustafa Nevzat, Turkey) was given for 7 days (30 mg/kg, IM) every 12 h. Also, first four days was prescribed only fluid therapy by IV. Throughout four days was used every 12 h 50 ml of 5% dextrose, lactated Ringer 75 ml, 0.9% NaCl 250 ml, and Metronidazole (Flagyl®, Eczacıbaşı, Turkey) (25 mg/kg). Next seven days was given water and diluted canine A/D

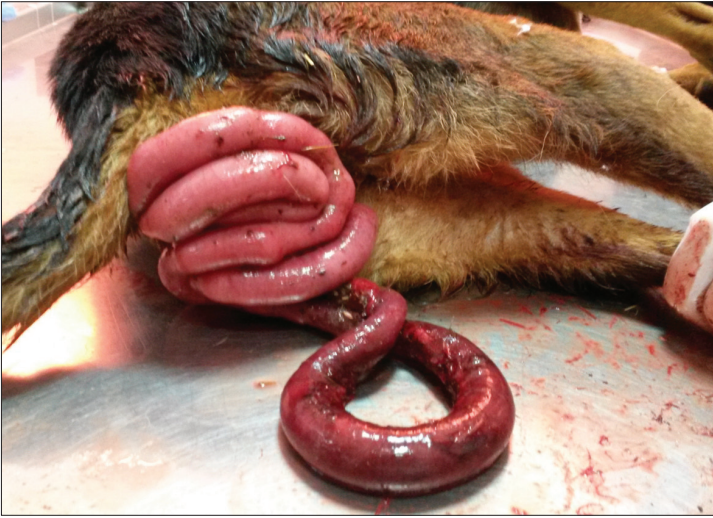

Fig 1. Macroscopic appearance of transvaginal bowel evisceration

Şekil 1. Transvaginal barsak eviserasyonunun makroskopik görünümü

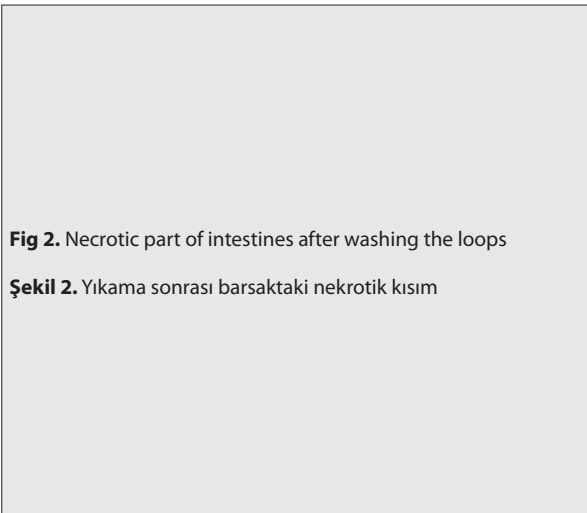
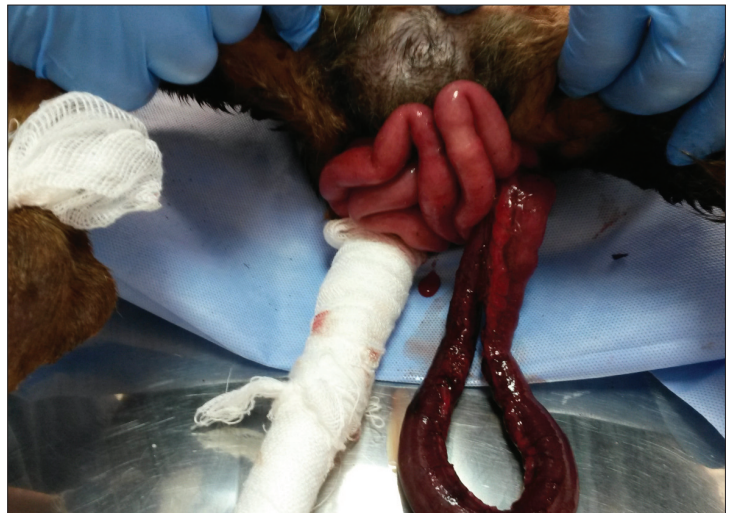

Fig 2. Necrotic part of intestines after washing the loops

Şekil 2. Yıkama sonrası barsaktaki nekrotik kısım



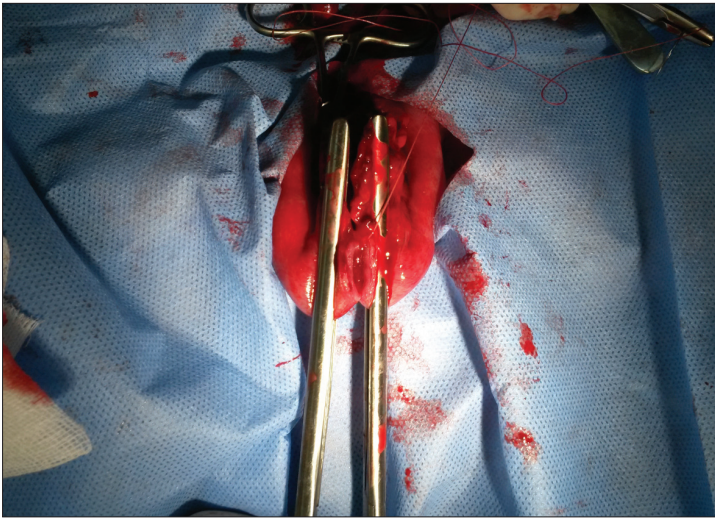


Fig 3. Termino-terminal anastomosis procedure

Şekil 3. Uçuca anastomoz uygulaması

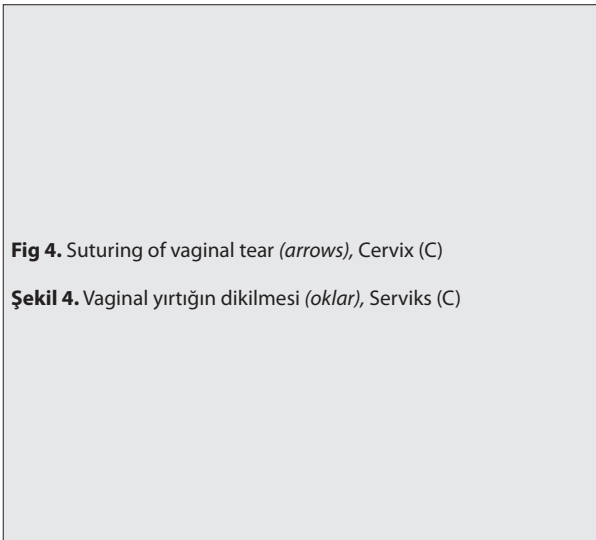
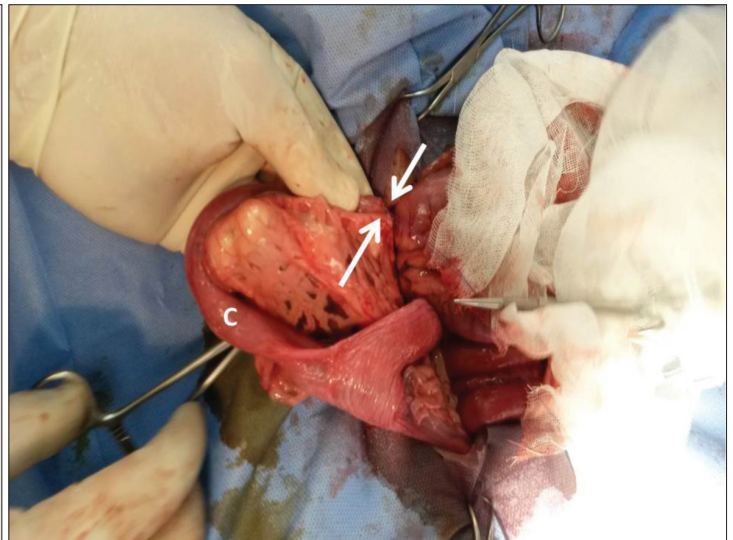


Fig 4. Suturing of vaginal tear (arrows), Cervix (C)

Şekil 4. Vaginal yırtığının dikilmesi (oklar), Serviks (C)



prescription diet. Next seven days was given macerated canine diet was started slowly a normal feeding.

Neither general complications nor vaginal discharge occurred with surgery throughout the three days. The results of the haematological analysis were recorded normally (WBC=13.30x10⁹/l, RBC=5.3x10¹²/l, HGB=11.7 g/dl, HCT=36.4%) at postoperatively 72 h. One week later, the dog had recovered completely. At the examination after six months postoperatively, dog was normal and had no complication originated from gastrointestinal and genital organs. The dog had got weight and was in good general condition.

DISCUSSION

Vaginal evisceration characterized by internal organs prolapsing transvaginally is a rare emergency surgical condition [8-10]. Depending on women's sexual stage, this condition is associated with pelvic prolapse, previous pelvic surgery, especially vaginal hysterectomy, and

also traumatic coitus [11]. To date, more than 100 vaginal evisceration cases has been previously reported in literature [10], but only few reports in veterinary medicine. Vaginal bowel evisceration cases have been recorded in several farm animals [12-14] and dogs [5,15]. But to summarize the predisposing factors is not possible due to low incidence. At breeding, the penetration of the penis to the vaginal fornix can result to this condition in two mares [13]. And also, it was reported that the similar complication in a dog following the forceful separation at mating [14]. Meanwhile, another report is associated with pregnancy and parturition. Scott [13] warned that evisceration of intestines through a tear in the dorsal vaginal wall occurs spontaneously in heavily pregnant ewes during the last month of gestation with the incidence between 2 and 5 per cent. Regarding to our presentation, two similar cases have been reported in dogs with transvaginal evisceration after parturition [5,6]. In the first case, a perineal mass containing intestinal loops, bladder and uterine horns was observed immediately after delivery of oversized fetuses resulted from tenesmus and/or due to oversized fetuses [5].

In the second case, it was observed that the vaginal rupture with bladder retroflexion and evisceration 45 days after delivery. However although the surgical treatment including ovariohysterectomy and partial vaginectomy was performed, both dogs were not survived. According to author's, deaths were attributed to the patient's poor general condition and septic shock, respectively.

In the present case, the sizes of puppies were normal and have no clinical signs related to foetal dystocia. After ten days parturition, all puppies were living without any health problem. However straining due to constipation is well-known as a risk factor for vaginal ruptures^[10], there was no history about manual intervention in delivery, constipation, accidental trauma etc. according to owner's report. Therefore, this condition suggests the presence of different factors that need to be investigated in the aetiology of the disease.

The suggested surgical option is a combined abdominal-vaginal approach especially in complicated cases^[11]. In this case presented, the similar surgical technique was used successfully, combined with resection the necrotic part of intestine. Regarding to the poor reducibility and high rupture risk of damaged intestinal walls, only manual reduction of loops should not be performed. Following the resection of necrotic parts ex-situ, vaginal bowel traction with abdominal laparotomy can be performed.

In human medicine, pelvic organ prolapses are described in detail under the heading "pelvic floor disorders". Normally, pelvic floor components surrounding them keep the pelvic organs in place. In reconstructive pelvic surgery, numerous surgical methods with and without graft materials have been used in pelvic support tissue according to localization of the defect^[16,17]. However, the pelvic defect repair has been performed simpler in cases of pelvic organ prolapse in dogs. In our opinion, this difference can be related to the body's posture and pelvic organ localization. Pelvic organs are positioned horizontally in dogs but vertically in human body. Regarding to this different pelvic position and the need of resistance to gravity, more complex surgical approaches are inevitable in women with similar disorders. In this case, after reposition of ileum and suturing of vaginal wall, routine abdominal closure technique was performed. Likewise, no need was seen to use graft in this operation.

In obstetric injuries, many factors can be determinant for postoperative prognosis. As previously reported, poor general condition and shock have negative impact on the patient's survival^[5]. Despite being severely underweight condition in dog was not a problem in this case. In beside of patient's condition, some authors pointed that the low ambient temperature could be a negatively factor on the patient's prognosis^[5,18]. But the dog was referred the our hospital in a day where the temperature 23 Celsius degrees averagely in April-2015, therefore no complication related

to low temperature was observed after treatment. Also it was not seen any complications throughout six months after operation.

In conclusion, it was presented that a case of transvaginal evisceration, which was seen on the postpartum tenth day, and was successfully treated surgically without any complication. Given the preoperative and postoperative findings in this case, it should be considered that the patient's survival can be increased by proper surgical treatment in this rare condition.

REFERENCES

- Humm KR, Adamantos SE, Benigni L, Armitage-Chan EA, Brockman DJ, Chan DL:** Uterine rupture and septic peritonitis following dystocia and assisted delivery in a Great Dane bitch. *J Am Anim Hosp Assoc*, 46, 353-357, 2010. DOI: 10.5326/0460353
- Jackson PGG:** Postparturient problems in dog and cat. In, Jackson PGG (Ed): Handbook of Veterinary Obstetrics. 2nd ed., 233-237, W.B. Saunders Company, Philadelphia, 2004.
- Linde-Forsberg C and Eneroth A:** Parturition. In, Simpson GM (Ed): Manual of Small Animal Reproduction and Neonatology. 127-142, British Small Anim Vet Assoc, Gloucester, UK, 1998.
- Hajurka J, Macak V, Hura V, Statova L, Hajurka R:** Spontaneous rupture of uterus in the bitch at parturition with evisceration of pupy intestine - A case report. *Vet Med Czech*, 50, 85-88, 2005.
- Prassinis NN, Adamama-Moraitou KK, Ververidis HN, Anagnostou TL, Kladakis SE:** Vaginal rupture and evisceration in a dog. *Acta Vet Hung*, 58, 309-315, 2010. DOI: 10.1556/AVet.58.2010.3.4
- Coutinho BH, Labat E, Coutinho Junior AS, Curti MC, Pirollo J, de Oliveira MLR, de Souza MSB:** Retroflexion and evisceration of the urinary bladder due to rupture of the genital organs in bitch. *Ciencia Rural*, 43, 318-321, 2013. DOI: 10.1590/S0103-84782013000200020
- Mandell DC, Drobatz KI:** Urinary bladder herniation through a vaginal tear in a Rottweiler with dystocia. *J Vet Emerg Crit Care*, 10, 173-175, 2000. DOI: 10.1111/j.1476-4431.2000.tb00008.x
- Parra RS, Rocha JJR, Feres O:** Spontaneous transvaginal small bowel evisceration: A case report. *Clinics*, 65, 559-561, 2010. DOI: 10.1590/S1807-59322010000500015
- Erdemoglu E, Guneyeli İ, Güney M:** Abdominal histerektomi sonrası vaginal evisceration. *J Turk Soc Obstet Gynecol*, 2, 149-152, 2011.
- Girgin M, Kanat BH, Ayten R, Cetinkaya Z:** Demanslı bir hastada self-mutilasyona bağlı vaginal evisceration: Bir olgu sunumu. *Kafkas Tıp Bil Derg*, 3, 106-108, 2013. DOI: 10.5505/kjms.2013.70299
- Croak AJ, Gebhart JB, Klingele CJ, Schoreder G, Lee RA, Podratz KC:** Characteristics of patients with vaginal rupture and evisceration. *Obstet & Gynecol*, 103, 572-576, 2004. DOI: 10.1097/01.AOG.0000115507.26155.45
- Tulleners EP:** Avulsion of the jejunum, with vaginal evisceration in a cow. *J Am Vet Med Assoc*, 184, 195-196, 1984.
- Tulleners EP, Richardson DW, Reid BV:** Vaginal evisceration of the small intestine in three mares. *J Am Vet Med Assoc* 186, 385-387, 1985.
- Scott PR:** Reproductive system. In, Scott PR (Ed): Sheep Medicine. 2nd ed., 45, CRC Press, Taylor & Francis Group; 2015.
- Robinson RW:** Intestinal prolapse through the vagina in a Beagle. *Vet Med Small Anim Clinic*, 73, 1412-1413, 1978.
- Miklos JR, Moore RD, Kohli N:** Laparoscopic surgery for pelvic support defects. *Curr Opin Obstet Gynecol*, 14, 387-395, 2002.
- Canaz E, Ark HC, Alkış I, Han A, Ölmez H:** Pelvik organ prolapsusu: Anatomik temeller ve cerrahi yaklaşım. *Jopp Derg*, 5, 47-61, 2013. DOI: 10.5222/JOPP.2013.047
- Mosdol G:** Spontaneous vaginal rupture in pregnant ewes. *Vet Rec*, 144, 38-41, 1999. DOI: 10.1136/vr.144.2.38