

## Anorectal Malformation with Colovesical and Colourethral Fistula in Two Calves

Ahmet ÖZAK <sup>1</sup>  H. Özlem NİSBET <sup>1</sup> Cenk YARDIMCI <sup>1</sup> Yonca B. KABAK <sup>2</sup>

<sup>1</sup> Department of Surgery, Faculty of Veterinary Medicine, Ondokuz Mayıs University, TR-55139 Samsun - TURKEY

<sup>2</sup> Department of Pathology, Faculty of Veterinary Medicine, Ondokuz Mayıs University, TR-55139 Samsun - TURKEY

KVFD-2014-12166 Received: 17.08.2014 Accepted: 24.12.2014 Published Online: 07.01.2015

### Abstract

This paper reports the evaluation of anorectal malformations with two different fistula in two calves. During clinical examination atresia ani and meconium coming from preputium was observed in both calves. Distention of intestines was viewed in radiological examination. Surgical treatment had been preferred in both calves. During surgery it was observed that colon was connected to the bladder with tube-like formation in calf 1. In calf 2 colo-urethral fistula was detected during necropsy. The clinical, surgical and necropsy findings of anorectal malformations with colovesical and colourethral fistula in two calves has been reported for the first time. As a conclusion, the localization of the fistula and the condition of the animal could affect results of surgical treatment.

**Keywords:** Anorectal malformation, Colovesical, Colourethral fistula, Calf

## İki Buzağıda Karşılaşın Anorektal Malformasyon İle Birlikte Gözlenen Kolovesikal ve Kolouretral Fistül Olgusu

### Özet

Bu makalede iki ayrı buzağıda iki farklı fistülü bulunan anorektal malformasyonun değerlendirilmesi sunulmuştur. Her iki buzağının klinik muayenesi sırasında atresia ani ve mekonyumun prepsiyumdan geldiği belirlendi. Radyografik muayenede ise bağırsakların genişlediği gözlemlendi. Her iki buzağının operatif tedavisine karar verildi. Birinci buzağının operasyonunda kolonun tüp şeklinde bir yapı ile idrar kesesine bağlandığı belirlendi. İkinci buzağıda ise kolonun urertraya fistülleştiği nekropsisi sırasında anlaşıldı. Kolovesikal ve kolouretral fistüle sahip iki buzağının klinik, cerrahi ve nekropsisi bulguları ilk defa sunulmaktadır. Sonuç olarak, fistülün lokalizasyonu ve hayvanın genel durumu cerrahi tedavinin sonucunu etkileyebilmektedir.

**Anahtar sözcükler:** Anorektal malformasyon, kolovesikal, kolouretral fistül, buzağı

### INTRODUCTION

Congenital defects, abnormalities of structure or function present at birth, may be caused by genetic or environmental factors, or a combination of both, however, in many cases, the causes are unknown. Developmental defects may be lethal, semi-lethal, or compatible with life, causing esthetic defects or may have no effect on the animal <sup>[1,2]</sup>. Congenital intestinal malformations occur frequently in cattle. There are several types, each with its own prognosis. Atresia ani and atresia recti are hereditary malformations, which occur often in calves and sometimes in sheep <sup>[3]</sup>. Urogenital anomalies are most commonly induced as a consequence of cloacal membrane defects during embryogenesis <sup>[4]</sup>. Atresia ani or recti with recto-vaginal (recto-vestibular) fistula are reported in calves as

necropsy findings <sup>[1,4-6]</sup>, however, there are several studies reporting the surgical treatment of atresia ani with recto-vaginal fistula in alpaca and calves <sup>[3,7,8]</sup>.

The aim of this study is to report the surgical treatment results and prognosis of anorectal malformation with colovesical and colourethral fistulas in two calves. According to authors' knowledge, these type anomalies have not ever been reported.

### CASE HISTORY

#### Calf 1

The calf was referred to our clinics with a complaint of defecation. In clinical evaluation of two-day-old male Simental breed calf, lack of anal opening and meconium



İletişim (Correspondence)



+90 532 7203366



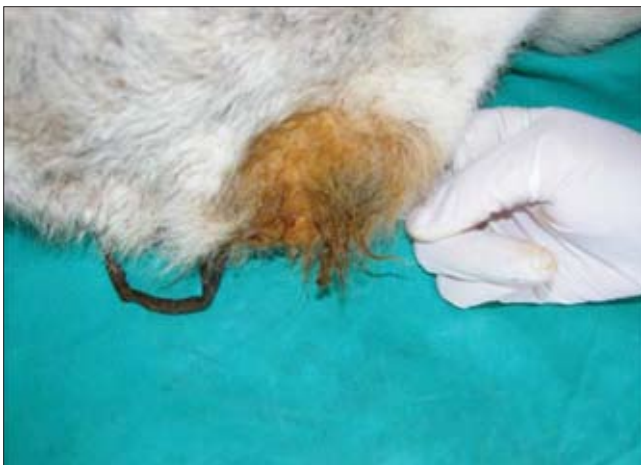aozak@hotmail.com

coming from the prepuce were observed (Fig. 1). In radiographic examination only gas and feces were detected. Complete blood cell count and blood serum biochemical analysis were normal. However, urinalysis released feces particles, leucocyte and protein. General anesthesia was induced using isoflurane (2-3%) in oxygen delivered through a mask held over the nose and mouth, and maintained with isoflurane in oxygen through an endotracheal tube. A 16 gauge catheter was placed to jugular vein for intraoperative fluid therapy and postoperative medication. Trimethoprim Sülfadimetilprimidin 40 mg/kg (Triprim, Interhas, Ankara, Turkey) and flunixin meglumine 1.1 mg/kg (Fundamin, Bavet, Istanbul, Turkey) were administered before surgery. Epidural anesthesia was performed with bupivacaine 0.2 ml/kg (Marcaine, Astra Zeneca, Istanbul, Turkey) at the level of the sacrococcygeal space. Surgery was performed by median laparotomy. The colon was connected to the bladder in tube-like formation (Fig. 2). Two sutures were placed and after transection of the connection, the end of openings was sutured separately in routine manner. Right flank colostomy was performed, because distance between anus and colon was not appropriate to connect colon to the perineal region.

During the first 24 h following surgery, except defecation incontinence, the calf was seen to defecate normally. Three and six months following surgery, the calf was healthy and well growing, however, the esthetic appearance of colostomy was not seemed well.

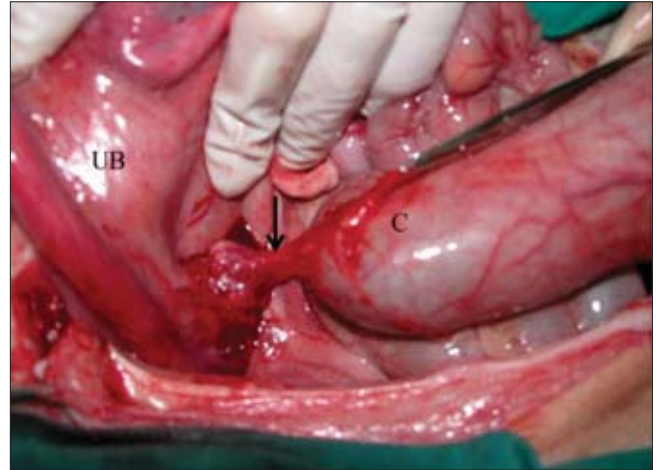
### Calf 2

In clinical evaluation of one-day-old male Simental breed calf, lack of anal opening and meconium coming from the prepuce and tenesmus were observed. In radiography of the abdomen megacolon and enlargement of secum with gas were detected. Complete blood cell count and blood serum biochemical analysis were normal. Same anesthesia procedure of calf one was used in calf two.



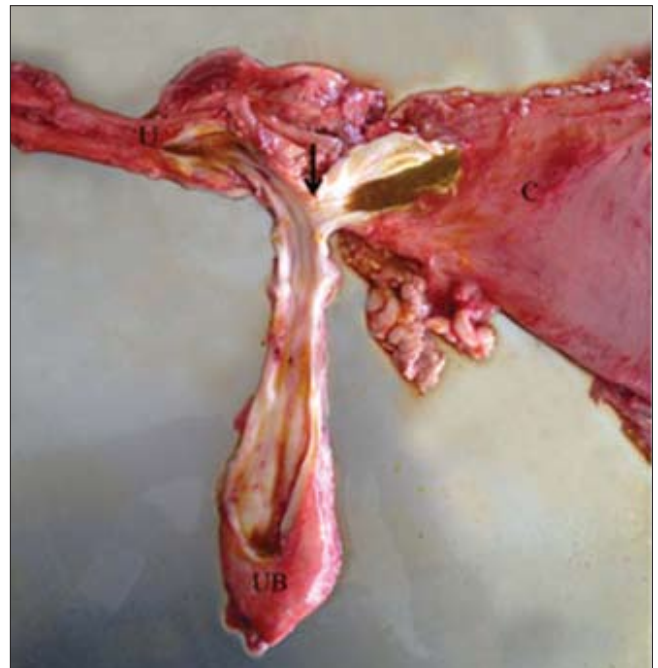
**Fig 1.** In case one, the meconium was seen in and around the prepuce  
**Şekil 1.** Birinci olguda prepüsyumun içinde ve etrafında mekonyum görülmekte

Trimethoprim Sülfadimetilprimidin 40 mg/kg (Triprim, Interhas, Ankara, Turkey) and flunixin meglumine 1.1 mg/kg (Fundamin, Bavet, Istanbul, Turkey) were administered before surgery. Epidural anesthesia was performed with bupivacaine 0.2 ml/kg (Marcaine, Astra Zeneca, Istanbul, Turkey) at the level of the sacrococcygeal space. Surgery was performed by median laparotomy. During exploration of abdomen, secum and large intestines were full of gas, especially ascending colon was enlarged and full of



**Fig 2.** Connection of colon to urinary bladder with tube-like formation. C- Colon, UB- Urinary bladder, arrow: Tube-like formation connecting colon and urinary baldder

**Şekil 2.** Kolonun ıdrar kesesine tüp şeklinde bir bağlantıyla bağlanması. C- Kolon, UB- İdrar kesesi, Ok: Kolon ve ıdrar kesesini bağlatınsını sağlayan tüp



**Fig 3.** The appearance of connection colon to the urethra. C- Colon, UB- Urinary Bladder, U- Urethra, Arrow: connection site

**Şekil 3.** Kolonun üretraya bağlantısının görünümü. C- Kolon, UB- İdrar Kesesi, U- Üretra, Ok: birleşim yeri

meconium. The urinary bladder was incised and urinary catheter was applied from urinary bladder through urethra. Although, urinary bladder was empty catheter was filled with meconium when the catheter passed through the urethra. During surgery cardiac arrest was occurred, despite cardiopulmonary resuscitation calf was died. According to necropsy finding colon was opened to urethra with a small fistula (Fig. 3).

## DISCUSSION

Intestinal atresia is considered to be associated with interruption of the blood supply to a localized segment of embryonic intestine resulting in atrophy, disappearance of the affected segment, or failure of the affected to undergo further development [9,10]. Stenosis and atresia of the lumen are the most common congenital malformations of the gastrointestinal tract in most species. These malformations can occur at any level and are usually single rather than multiple abnormalities [11]. Failure of the urorectal fold to properly divide into the embryonic cloaca, can lead to the persistence of cloacal remnant. This malformation is usually associated with atresia ani and in these cases the terminal rectum joins the dorsal aspect of either the caudal vagina or the vestibule and thus, rectovagina or rectovestibular fistula is formed [8]. In case one, atresia ani-recti and opening of the colon to the urinary bladder, which has not been reported before, were diagnosed.

Several literatures, which usually necropsy findings are presented, have been reported the anorectal malformations with multiple disorders [1,4-6,12-14]. Successful surgical treatment of anorectal malformation with recto-vaginal (recto-vestibular) fistula is reported only in two case reports [7,8]. According to the authors' knowledge, successful surgical treatment results of anorectal malformation with multiple disorders in calves have not been presented before. Survival is largely dependent on the calf's condition at referral and on the intestinal segment affected [12]. The main causes of survival after surgical treatments were; early surgical intervention and normal general condition at referral. It is believed that general condition was not deteriorated due to evacuation of feces by the fistula. Correction of atresia ani may not be warranted in animals with severe multiple deformities [12]. Fistula that accompanies anorectal malformations was not severe deformities; moreover these positively affected the condition of the calves.

The surgical treatment of atresia ani implies the achievement of a patent opening the intestinal tract in the perineal region. Several surgical methods have been used to correct atresia coli or jejuna. Steenhaut recommended right flank colostomy if the entire colon and rectum are

involved. Postoperative complications such as prolapsed of the colon and unacceptable esthetic results limited the feasible application of the procedure [15]. Flank colostomy was preferred, because it was impossible to attach the colon to the perineal region. The only major complication in flank colostomy was the esthetic appearance as mentioned in the literature [2,15].

If economic value is considered, surgical treatment choice can be preferred in anorectal malformation with fistulas. Early surgical repair, general condition and localization of the fistula are the effective points of the prognosis. However, further retrospective studies should be performed to confirm this statement.

## REFERENCES

1. **Ghanem M, Yoshida C, Isobe N, Nakao T, Yamashiro H, Kubota H, Miyake Y, Nakada K:** Atresia ani with diphallos and separate scrota in a calf: A case report. *Theriogenology*, 61, 1205-1513, 2004. DOI: 10.1016/j.theriogenology.2003.04.002
2. **Gokçe AP, Besaltı Ö, Özak A, Tong S, Yagcı B:** Buzağılarda atresia kolinin operatif sağaltımı: 11 Olgu (1996-1998). *Vet Cerrahi Derg*, 3-4, 9-13, 1999.
3. **Özaydın İ, Kılıç E, Aksoy Ö, Cihan M, Güngör E:** Bir buzağıda üçlü malformasyon; atresia ani, rektouretral fistül ve pygomelia. *Kafkas Univ Vet Fak Derg*, 12, 189-191, 2006.
4. **Jeong WI, Lee CS, Ryu SY, Williams BH, Jee YH, Jung CY, Park SJ, Jeong DH, Lee SK, Jeong YS:** Renal and ureteral fusion in a calf with atresia ani. *J Vet Med Sci*, 65, 413-414, 2003. DOI: 10.1292/jvms.65.413
5. **Kilic N, Sarierler M:** Congenital intestinal atresia in calves: 61 cases (1999-2003). *Revue Med Vet*, 155, 381-384, 2004.
6. **Kılıç E, Özaydın İ, Aksoy Ö, Yayla S:** Üç buzağıda karşılaşılan çoklu ürogenital sistem anomalisi. *Kafkas Univ Vet Fak Derg*, 12, 193-197, 2006.
7. **Carraro DB, Dart AJ, Hudson NP, Dart CM, Hodgson DR:** Surgical correction of anorectal atresia and rectovaginal fistula in an alpaca cria. *Aust Vet J*, 74, 352-354, 1996. DOI: 10.1111/j.1751-0813.1996.tb15443.x
8. **Del Campo CH, Vits L, Del Campo MR, Ferguson JG:** A case of atresia ani with rectovestibular fistulae in an alpaca (*L. pacos*). *Dtsch Tierärz Wochenschr*, 100, 495-497, 1993.
9. **Jubb TF:** Intestinal atresia in Friesian calves. *Aust Vet J*, 67, 382, 1990. DOI: 10.1111/j.1751-0813.1990.tb07419.x
10. **Smith DF, Ducharme NG, Fubini SL, Donawick WJ, Erb HN:** Clinical management and surgical repair of atresia coli in calves: 66 cases (1977-1988). *J Am Vet Med Assoc*, 199, 1185-1190, 1991.
11. **Noden DM, De Lahunta A:** The Embryology of the Domestic Animal: Developmental Mechanism and Malformations. Baltimore, USA, Williams and Wilkins, 1985.
12. **Dreyfuss DJ, Tulleners EP:** Intestinal atresia in calves: 22 cases (1978-1988). *J Am Vet Med Assoc*, 195, 508-513, 1989.
13. **Ghanem ME, Yoshida C, Nishibori M, Nakao T, Yamashiro H:** A case of freemartin with atresia recti and ani in Japanese Black calf. *Anim Reprod Sci*, 85, 193-199, 2005. DOI: 10.1016/j.anireprosci.2004.04.044
14. **Forzán MJ, McClure JT:** Congenital aganglionosis in a 3-day-old Holstein calf. *Can Vet J*, 46, 342-344, 2005.
15. **Steenhaut M, De Moor A, Verschooten F, Desmet P:** Intestinal malformations in calves and their surgical correction. *Vet Rec*, 98, 131-133, 1976. DOI: 10.1136/vr.98.7.131