

A Case Report: Colic Due to Jejuno-jejunal Intussusception in A Mare

Ali C. ONMAZ *  Ulrike SCHUMANN ** Rene van den HOVEN ** Ayhan ATASEVER ***

- * Department of Internal Medicine, Faculty of Veterinary Medicine, University of Erciyes, TR-38039 Kayseri - TURKEY
** Department of Small Animals and Horses, Equine Clinic, Section Internal and Infection Medicine, Veterinary University of Vienna, 1210 Vienna - AUSTRIA
*** Department of Pathology, Faculty of Veterinary Medicine, University of Erciyes, TR-38039 Kayseri - TURKEY

Makale Kodu (Article Code): KVFD-2012-7808

Summary

This paper reports the clinical findings, the results of diagnostic imaging, the medical management, and the results of necropsy of a 2 year old Arabian mare suffering from jejuno-jejunal intussusception. Determining clinical parameters for the in-live diagnosis were the characteristic bull's eye appearance of a part of the small intestine at ultrasonography, tubular structures found at transrectal palpation and the abnormal peritoneal fluid obtained by abdominocentesis.

Keywords: Mare, Colic, Jejuno-jejunal intussusceptions

Olgu Sunumu: Bir Kısırakta Jejuno-jejunal Invaginasyon Nedeniyle Oluşan Kolik

Özet

Bu olgu sunumunda, jejuno-jejunal invaginasyonlu 2 yaşlı Arap ırkı bir kısırakta klinik bulgular, tanısal görüntüleme, medikal yönetim ve otopsi sonuçları bildirildi. Anlık teşhis için belirlenen klinik parametreler; ultrasonografide ince barsakların bir kısmının karakteristik boğa gözü görünümünde olması, rektal palpasyonda tubuler yapıların bulunması ve abdominosentez ile elde edilen anormal peritoneal sıvının belirlenmesi idi.

Anahtar sözcükler: Kısırak, Kolik, Jejuno-jejunal invaginasyon

INTRODUCTION

Intestinal intussusceptions are uncommon in horses. But, it must be considered in the differential diagnosis of horses with acute or chronic pain¹. The more common forms of intussusceptions in horses are jejuno-jejunal, ileal-ileal or ileocecal². The length of intestine that case become invaginated (the intussusceptum) into the more distal segment of intestine (the intussusciens) ranges from a few centimeters to as much as a meter. There is no breed and sex predisposition but horses younger than 3 years are affected relatively more than older animals³⁻⁵. Diarrhea, worm infections and polyps may predispose the horses for this condition^{1,2,6,7}. Horses may be predisposed to intussusception because of enteritis, rapid dietary changes, parasitism, mesenteric arteritis, abdominal surgery, intraluminal foreign

bodies and intramural masses^{1,2,8}. Jejuno-jejunal intussusception was found to be the cause of colic in only 7 of 310 (2.26%) horses⁹. Horses with intestinal intussusceptions exhibit signs of acute intestinal obstruction or have a chronic disease, characterized by abdominal pain, reduced appetite, weight loss, intermittent fever, soft feces and pyrexia¹⁰.

The diagnosis and treatment of this disease can be extremely difficult¹⁰. History, clinical and clinicopathologic examinations are important in the diagnosis of intussusceptions. A diagnosis may be made by ultrasonography or rectal palpation, but exploratory laparotomy is the predominant method¹¹. Trans-abdominal ultrasonography is a potentially useful for diagnosing intussusceptions¹²⁻¹⁴. The



İletişim (Correspondence)



+90 352 3399484/29628



aconmaz@erciyes.edu.tr

main goals for treating horses with colic include relieving pain, correcting physiologic imbalance and stimulating or maintaining intestinal transit. Primary treatments are aimed at decompressing the gastrointestinal tract, treating dehydration or shock, correcting electrolyte imbalances, stimulating intestinal motility¹⁵. Treatment of intussusception always requires surgical intervention¹⁶. The prognosis of the small intestine intussusception depends on many factors, including the length of the bowel affected, duration of the lesion and variability of the bowel¹⁷. The longer the intussusception is present and the intestine compromised, the worse the prognosis^{8,9}.

This paper presents a case of a jejuno-jejunal intussusception in a mare that was diagnosed with the use of ultrasonography. This condition, that is relatively simple to diagnose by ultrasonography, should be taken into account in the examination and differential diagnosis of severe colic's symptoms in young horses.

CASE HISTORY

A 2 year old Arabian mare was presented at the equine clinic of Veterinary University of Vienna for severe colic symptoms. Clinical signs included episodes of mild to severe abdominal pain. The horse had a rectal temperature of 37.8°C, the respiratory rate was 20/min and the breathing pattern was costo-abdominal, heart rate was rhythmic but its frequency was increased to 82 beats per minute (bpm) (Table 1), the mucous membranes were slightly cyanotic. Various small excoriations were present on head, the rump and legs. Severe abdominal distension was observed. Abdominal auscultation revealed reduced borborygmy indicating decreased peristaltic. Blood gas analysis showed a blood pH of 7.41 with base excess (BE) of 6.4 mmol/L, hypokalemia (3.2 mmol/L) and high plasma bicarbonate (31.7 mmol/L). These parameters are given in Table 1.

The mare was intravenously treated with 0.5-1.0 mg/kg BW xylazine (2%); metamizol-sodium 0.2 mg/kg BW; N-butylscopolammonium bromide 25 mg/kg BW and flunixin meglumine 1.1 mg/kg BW to reduce pain. Effort was made to restore the circulation with intravenous infusion of 0.9% NaCl (1 L/h for 1 h, IV).

Table 1. Parameters of mare associated with clinical sings

Tablo 1. Kısağın klinik bulguları ile ilgili parametreler

| Parameters | Value of Mare | Reference Range |
|-----------------------------|---------------|-----------------|
| Blood pH | 7.41 | 7.32-7.44 |
| Base excess (mmol/L) | 6.4 | -2.5-2.5 |
| Potassium (mmol/L) | 3.2 | 3.5-4.5 |
| Plasma bicarbonate (mmol/L) | 31.7 | 20-28 |
| Rectal Temperature | 37.8°C | 37.3-38.2 |
| Respiratory rate (min) | 20 | 10-14 |
| Heart frequency (bpm) | 82 | 30-40 |

At rectal examination the characteristic loops of distended small intestine were identified, the invagination however could not be reached. The peritoneal fluid obtained by paracentesis in the midline was light orange-colored, very cloudy, had an elevated total protein levels (2.8 g/dL), a nearly normal specific gravity (1.022) and an elevated lactate level (2.4 mmol/L). These parameters are summarized in Table 2.

Trans-abdominal ultrasound was performed with a 3.5 MHz sector transducer. In the ventral abdomen, severe peritoneal effusion was observed. Several loops of distended small intestine with thickened walls and weak peristaltic were seen. The characteristic "bull eyed" like structure suggesting small bowel intussusception was seen (Fig. 1).

The clinical and ultrasonographic findings combined with the results of the peritoneal fluid analysis supported the diagnosis of intussusception of the small intestine. Surgical treatment was declined by the owner and the mare was euthanized.

At gross pathology dilated jejunal loops and hemorrhagic spots on them were apperent. After the opening of the abdominal cavity, a jejuno-jejunal intussusception, 30 cm tract of small intestine, was noticed (Fig. 2).

The portion of the invaginated jejunum revealed signs of transmural necrosis and large hemorrhagic areas (Fig. 3). Intense hyperemia, acute catarrhal enteritis and severe

Table 2. Parameters of peritoneal fluid obtained by paracentesis from mare
Tablo 2. Kısraktan parasetezis ile elde edilen peritoneal sıvı parametreleri

| Parameters | Value of Mare | Reference Range |
|-----------------------------|---------------|-----------------|
| Total protein levels (g/dL) | 2.8 | <2.5 |
| Specific gravity | 1.022 | <1.020 |
| Lactate level (mmol/L) | 2.4 | ≥1.2 |

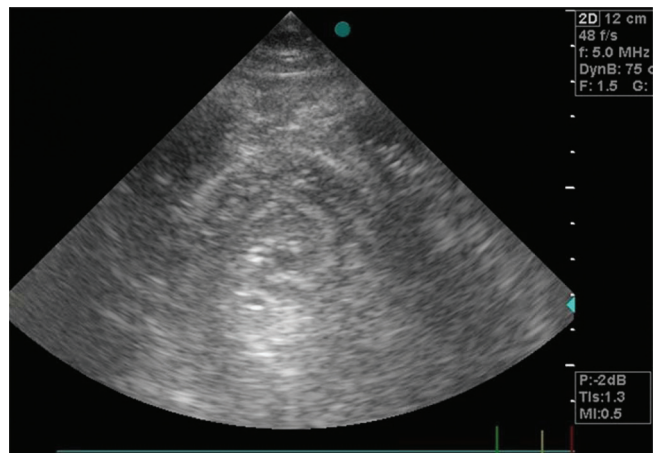


Fig 1. Ultrasonographic appearance of the jejuno-jejunal intussusception (Bull's eye)

Şekil 1. Jejuno-jejunal invaginasyonun ultrasonografik görünümü (Boğa gözü)

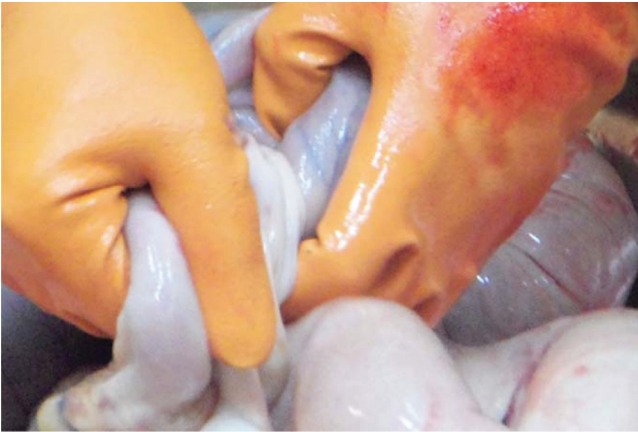

Fig 2. The anatomical macroscopic view of the jejunum-jejunal intussusceptions

Şekil 2. Jejunum-jejunal invaginasyonun anatomik makroskopik görünümü

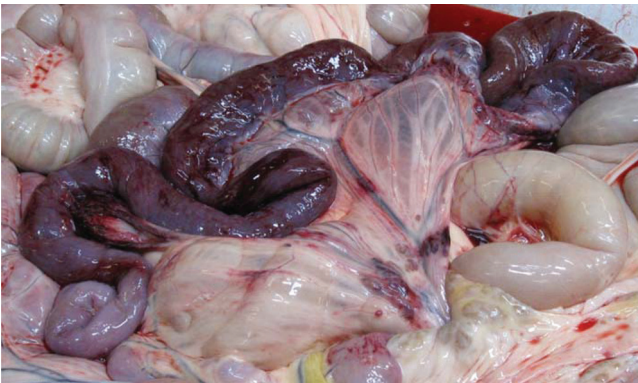

Fig 3. The invaginated part of the bowel

Şekil 3. İnvagine olan bağırsak bölümü

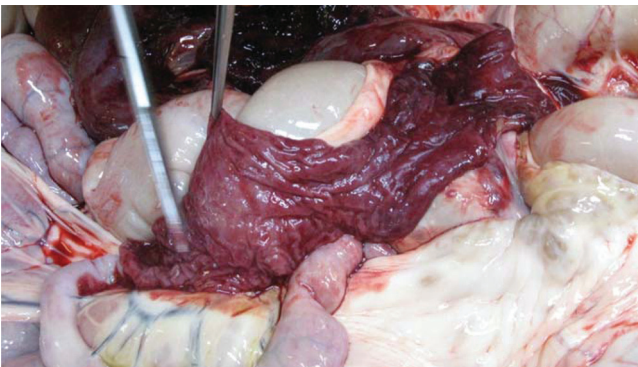


Fig 4. The macroscopic view of the lumen of the invaginated tract after the cross section

Şekil 4. Enine kesitten sonra invagine olan bağırsak lümeninin makroskopik görünümü

necrosis affected the portion of small intestine preceding the intussusception (Fig. 4).

DISCUSSION

Different types of intussusception are recognized in horse such as enteric, ileoileal, ileoceocolic, cecocolic and

colocolic. Usually the ileum is involved at or close to, the ileocaecal junction^{9,18}. Jejunum-jejunal intussusceptions are less frequently encountered and hence its incidence is very low (2.26%) in horses⁹.

Clinical signs are extremely variable depending on the degree of compromise or obstruction of the affected portion of the gut. Pain may range from intermittent mild to severe. Pain may be so uncontrollable that immediate surgical intervention is required^{9,10,19,20}. In addition diarrhea and fever may be seen occasionally.

In this case, the horse had mild respiratory compromise, tachycardia, mild cyanosis likely an increased intra-abdominal pressure, a partial ileus and hypokalemic metabolic alkalosis. Hematological and blood biochemical data may be normal, as was shown by Vieitez et al.²¹ in foal with jejunum-jejunal intussusceptions. On the other hand clear hematological and biochemical abnormalities are commonly seen. The findings of the current case are similar to those described by Albanese et al.²² and Lin et al.²³

In the present case, the young Arabian mare was presented at our clinic for severe colic symptoms. With the rectal findings and echography results the diagnosis was not difficult to make. Since intussusception is a relatively uncommon cause of colic in young or adult horses¹, this disorder may be overlooked if horses are not carefully examined.

Intussusceptions are believed to arise either as a result of segmental motility disorder or as a result of local changes in the intestinal wall²⁴. Regarding the latter, a special case is the jejunum-jejunal intussusception that is reported as a complication of jejunum-jejunal anastomosis by researchers²⁵⁻²⁷.

In humans and many animal species, transabdominal ultrasonography is an excellent diagnostic procedure to diagnose many abdominal disorders. Bell and Textor²⁸ suggested that transabdominal ultrasound was extremely useful for diagnosing horses with caeco-colic or caeco-caecal intussusceptions (10/12 and 4/5 horses that were scanned, respectively). The ultrasonographic characterization of intussusception has been given for men²⁹, foals¹², adult cattle³⁰, cats³¹, and dogs³². Bell and Textor²⁸ could diagnose only 54% of the caecal intussusceptions by rectal palpation and/or by ultrasonography. So, in roughly half of the cases the diagnosis cannot be made by clinical examination and only at explorative surgery a definitive diagnosis can be made.

At a longitudinal sonographic view a sandwich-like appearance of the alternating loops of bowel, with a loop-within-a loop appearance is seen. Fluid distention of the more proximal small intestine may be detected, usually with normal or nearly normal wall thickness and little or no peristaltic activity^{12,30,33}. If a "target" or "bull's eye" lesion is observed, the diagnosis is definitive^{12,13}. In this case, the ultrasonographic appearance of the intussusception corresponds to those previously described papers using a 3.5 MHz

transducer^{30,33}. The rectal findings in this case were not conclusive but indicated a strangulative small intestinal problem and the final diagnosis was relative simply made by the pathognomic "bull's eye" aspect seen at ultrasonography, which indicated small bowel intussusception.

REFERENCES

- Auer JA, Stick JA:** Equine Surgery. Small Intestine and Large Intestine. 3rd ed., pp. 415-417, 443-446, WB Saunders Co, Philadelphia, 2006.
- Cribb NC, Coté NM, Bouré LP, Peregrine AS:** Acute small intestinal obstruction associated with *Parascaris equorum* infection in young horses: 25 cases (1985-2004). *New Zeal Vet J*, 54 (6): 338-343, 2006.
- Ford TS, Freeman DE, Ross MW, Richardson DW, Martin BB, Madison JB:** Ileocecal intussusception in horses: 26 cases (1981-1988). *J Am Vet Med Assoc*, 19, 121-126, 1990.
- Greet TRC:** Ileal intussusception in 16 young thoroughbreds. *Equine Vet J*, 24 (2): 81-83, 1992.
- Boswell JC, Schramme MC, Gains M:** Jejunojejunal intussusception after an end-to-end jejunojejunal anastomosis in a horse. *Equine Vet Educ*, 12 (6): 303-306, 2000.
- Chandler KJ, Collins MC, Love S:** Efficacy of a five-day course of fenbendazole in benzimidazole-resistant cyathostomes. *Vet Rec*, 147, 661-662, 2000.
- Gore T, Gore P, Giffin GM:** Horse Owner's Veterinary Handbook. 3rd ed., pp. 41-49, Wiley Publishing Inc, Hoboken, New Jersey, 2008.
- Gift L, Gaughan E, DeBowes R, Pintchuk P, Nickels F, Foreman J:** Jejunal intussusception in adult horses: 11 cases (1981-1991). *J Am Vet Med Assoc*, 202, 110-112, 1993.
- Edwards GB:** Surgical management of intussusception in the horse. *Equine Vet J*, 18, 313-321, 1986.
- Edwards GB:** The clinical presentation and diagnosis of caecal obstruction in the horse. *Equine Vet Educ*, 4, 237-240, 1992.
- Nelson BB, Brounts SH:** Intussusception in horses. *Compend Contin Educ Vet*, 34 (7): 1-5, 2012.
- Bernard WV, Reef VB, Reime JM, Humber KA, Orsini JA:** Ultrasonographic diagnosis of small-intestinal intussusception in three foals. *J Am Vet Med Assoc*, 194, 395-397, 1989.
- Reef VB:** Adult abdominal ultrasonography. In, *Equine Diagnostic Ultrasound*. pp. 322-324, WB Saunders Co, Philadelphia, 1998.
- Braun U:** Ultrasonography in gastrointestinal disease in cattle. *Vet J*, 166, 112-124, 2003.
- White NA:** Colic treatment and post-colic nutrition. *Adv Equine Nutrition*, 4, 327-345, 2009.
- Dabareiner RM, White NA:** Diseases and surgery of cecum. *Vet Clin North Am: Equine Pract*, 13, 303-315, 1997.
- Colahan PT, Merritt AM, Moore JN, Mayhew IG:** Alimentary system. In, *Equine and Surgery*. 5th ed., pp. 722-723, 739-742, St Louis, Mosby, 1999.
- Tennant B, Wheat JD, Meager DM:** Observations on the causes and incidence of acute intestinal obstruction in the horse. *Proc Am Ass Equine Practnrs*, 18, 251-258, 1972.
- Gaughan EM, Hackett RP:** Cecocolic intussusceptions in horses: 11 cases (1979-1989). *J Am Vet Med Ass*, 197 (10): 1373-1375, 1990.
- Martin BB, Jr Freeman DE, Ross MW, Richardson DW, Johnston JK, Orsini JA:** Cecocolic and cecocolic intussusceptions in horses: 30 cases (1976-1996). *J Am Vet Med Assoc*, 214 (1): 80-84, 1999.
- Vieitez V, Martin-Cuervo M, Jimenez J, Rosa C, Pastor N, Ezquerro LJ:** Jejunojejunal intussusception following umbilical herniorrhaphy in a foal. *XVII International Congress of the Spanish Society of Veterinary Surgery*, Spain, 06 October, 2009.
- Albanese V, Credille B, Ellis A:** A case of a colocolic intussusception in a horse. *Equine Vet Educ*, 23 (6): 281-285, 2011.
- Lin CC, Chuang ST, Hsuan SL, Huang WG:** Jejunojejunal intussusception and colonic impaction in a 12-day-old orphan foal. *J Equine Vet Sci*, 28 (8): 473-475, 2008.
- Doran R, Allen D, Orsini JA:** Small intestine. In, *Auer JA (Ed): Equine Surgery*. pp. 360-378, WB, Saunders Co, Philadelphia, 1992.
- Lowe JE:** Intussusception in three ponies following experimental enterotomy. *Cornell Vet*, 58, 288-292, 1968.
- Huskamp B:** The diagnosis and treatment of acute abdominal conditions in the horse. *Proceedings of the Equine Colic Research Symposium, September 28-30, Athens, Georgia*, pp. 261-273, 1982.
- Frankeny RL, Wilson DA, Messer NT, Campbell-Beggs C:** Jejunal intussusception: A complication of functional end-to-end stapled anastomoses in two ponies. *Vet Surg*, 24, 515-517, 1995.
- Bell RJW, Textor JA:** Caecal intussusceptions in horses: A New Zealand perspective. *Aust Vet J*, 88 (7): 272-276, 2010.
- Byrne AT, Geoghegan T, Govender P, Lyburn ID, Colhoun E, Torreggiani WC:** The imaging of intussusception. *Clin Radiol*, 60, 39-46, 2005.
- Braun U, Marmier O, Pusterla N:** Ultrasonographic examination of the small intestine of cows with ileus of the duodenum, jejunum or ileum. *Vet Rec*, 137, 209-215, 1995.
- Patsikas MN, Papazoglou LG, Papaioannou NG, Savvas I, Kazakos GM, Dessiris AK:** Ultrasonographic findings of intestinal intussusception in seven cats. *J Feline Med Surg*, 5, 335-343, 2003.
- Lamb CR, Mantis P:** Ultrasonographic features of intestinal intussusception in 10 dogs. *J Small Anim Pract*, 39, 437-441, 1998.
- Fontaine-Rodgers G, Rodgers DH:** Diagnosis of small intestinal intussusception by transabdominal ultrasonography in 2 adult horses. *Can Vet J*, 42, 378-380, 2001.