

## Canine Distemper Virus Infection in A Terrier Dog with Pyotraumatic Dermatitis (Pyotravmatik Dermatitisi Bir Köpekte Canine Distemper İnfeksiyonu)

M. Kazım BÖRKÜ \* Ali Evren HAYDARDEDEOĞLU \*  Ekrem Çağatay ÇOLAKOĞLU \*  
Hadi ALİHOSSEİNİ \* Ahmet BAYDIN \* Tuba Çiğdem OĞUZOĞLU \*\*

\* Department of Internal Medicine, Faculty of Veterinary, Ankara University, TR-06110 Dışkapı, Ankara - TURKEY

\*\* Department of Virology, Faculty of Veterinary, Ankara University, TR-06110 Dışkapı, Ankara - TURKEY

Makale Kodu (Article Code): KVFD-2012-7452

### Dear Editor

We would like to report interesting case of pyotraumatic dermatitis with Canine Distemper infection in a dog.

Canine distemper virus (CDV), which is closely related to measles virus and rinderpest virus, two other members of the genus *Morbillivirus* of the *Paramyxoviridae* family, is devastating, highly contagious pathogen that occurs worldwide <sup>1,2</sup>. The host spectrum of CDV comprises dogs and many other carnivores <sup>3,4</sup>. The variety of clinical signs noticed among CDV infection in dogs resembles the multisystemic clinical picture of the disease <sup>5,6</sup>. The virus may produce skin lesion in some animals. As a consequence of general debility, some of the dogs, and especially very young puppies may represent with widespread impetigo. Skin lesions involving vesicular and pustular dermatitis may be noticed among infected dogs <sup>5,6</sup>. Pustular dermatitis was observed among 95% of Nigerian dogs experimentally infected with CDV <sup>5</sup>.

A variety of clinical parameters and different types of assays have been suggested for use for the definitive antemortem diagnosis of distemper. However, due to the unpredictable and variable course of distemper, length of viremia, organ manifestation, and a lack of or delayed humoral and cellular immune responses, the final diagnosis for most animals remains uncertain. Various specimens including conjunctival and vaginal imprints, urinary epithelium cells, skin and stomachbiopsy specimens, cells from tracheal washings, blood smears, and cerebrospinal fluid (CSF) taps have been used for an etiological diagnosis <sup>3</sup>.

A 3 year-old intact male dog was referred to small animal clinic of Ankara University, department of internal

medicine with complaints of recurrent sore surface over the truncal region with severe pruritus based on the owner's observations. In the clinical examination traumatized moist lesion on the truncal region was confirmed (*Fig. 1-2*). Routine blood work involving hematological and serum biochemical values were within reference ranges. The bacteriological and mycological cultures from lesional sites revealed *Staphylococcus aureus*. Moist pyodermitis was confirmed by results of histopathological examination. Initial referral 4 weeks admission to our clinic, the referring veterinary surgeon had made treatment involving antibiotics and vitamin applications (dose and duration was unknown, as the referring veterinary surgeon showed no response to telephone calls). Initial treatment at the present authors clinic involved cephalexine at a dosage of 22 mg/kg perorally q 12 h for 2 weeks and chlorhexidine bath for 3 weeks period. Due to previous unresponsive medical therapy applications and previously prescribed medications, and according to the authors prior experience, hence taking regard to differential diagnosis, the authors interest was aroused against possible involvement of viral etiology. Therefore we made virological examination by using Reverse Transcription - Polymerase Chain Reaction (RT-PCR) technique <sup>7</sup> determining Canine Distemper virus (CDV) (*Fig. 3*).

For appropriate management of CDV infection patients requires accurate clinical assessment, assimilating pertinent diagnostic information, and instituting prompt and suitable treatment. A number of diagnostic tests can be performed, including complete blood count, serum biochemistry profile and RT-PCR analysis very important. The aim of the present article was to highlight the importance of ulcerative pyotraumatic dermatitis that



### İletişim (Correspondence)

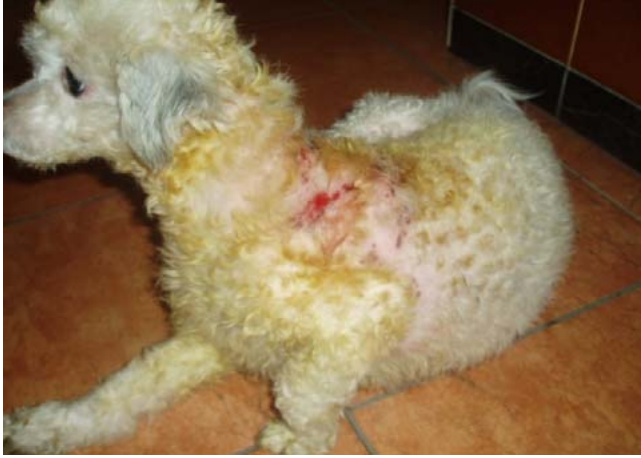

+90 533 2240572



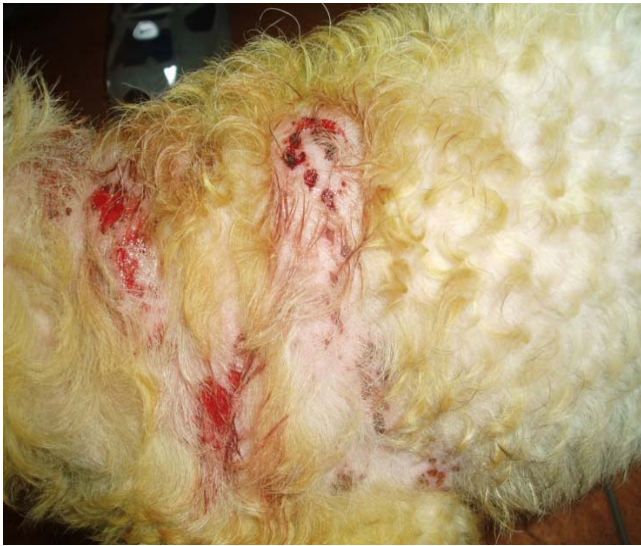ahaydardedeoglu@hotmail.com

should be taken into account with accompanying CDV infection, in cases with unresponsive medical treatments involving antibiotics and antiseptics.



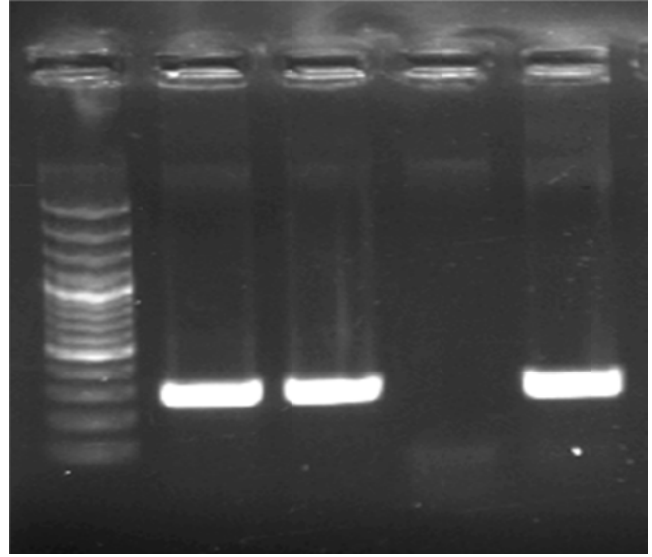
**Fig 1.** Pyotraumatic dermatitis on the truncal region terrier dog

**Şekil 1.** Terier köpekte trunkal bölgedeki pyotavmatik dermatitis



**Fig 2.** Severe pruritic area

**Şekil 2.** Şiddetli kaşıntılı bölge



**Fig 3.** Specific PCR products of CDV (236bp) use of HF1-HR2 primer pair. M: DNA Ladder 100 bp (Fermentas, Lithuania), Line 1 and 2: Blood samples, Line 3: Negative control, Line 4: Positive control

**Şekil 3.** HF1-HR2 primer çifti kullanılarak elde edilen CDV için spesifik PCR ürünü (236bp) M: 100 bp'lik DNA merdiveni (Fermentas, Litvanya) Çizgi 1 ve 2: Kan örnekleri, Çizgi 3: Negatif kontrol çizgi 4: Pozitif kontrol

## REFERENCES

- Blixenkronne-Møller M:** Biological properties of phocine distempervirus and canine distemper virus. *Acta Pathol Microbiol Immunol Scand*, 101 (Suppl.): 1-53, 1993.
- Pringle CR:** Paramyxoviridae. *Arch Virol*, 144 (Suppl. 2): 421-429, 1999.
- Aldinger S, Baumgartner W, Van Moll P, Orvell C:** *In vivo* and *in vitro* expression of canine distemper viral proteins in dogs and nondomestic carnivores. *Arch Virol*, 132, 421-428, 1993.
- Appel M:** Canine distemper virus, In, Appel MJG (Ed): *Virus Infections of Carnivores*. pp. 133-159, Elsevier Science Publishers, Amsterdam, The Netherlands, 1987.
- Ezeibe MCO:** Clinical manifestations of canine distemper Nigerian dogs infected with local isolate of canine distemper virus. *Nigerian Vet J*, 24 (1): 44-47, 2003.
- Woma TY, Moritz van Vuuren:** Isolation of canine distemper viruses from domestic dogs in South Africa using Vero, DogSLAM cells and its application to diagnosis *African J Microbiol Res*, 3 (3): 111-118, 2009.
- Ozkul A, Sancak AA, Gungor E, Burgu I:** Determination and phylogenetic analysis of canine distemper virus in dogs with nervous symptoms in Turkey. *Acta Veterinaria Hungarica*, 52(1):125-32, 2004.