

Interlocking Nail Stabilization of Canine Femoral Fractures; Clinical Experience and Results of the Nineteen Cases ^{[1] [2]}

Barış KÜRÜM * 

[1] This study are summarized from the thesis of the author

[2] This study was previously presented at a scientific meeting of IX. Veterinary Surgery Congress, Antalya, TURKEY, 2008 and the summery of the study was pressed in abstracts book

* Kırıkkale Üniversitesi, Veteriner Fakültesi, Cerrahi Anabilim Dalı, TR-71451 Kırıkkale - TÜRKİYE

Makale Kodu (Article Code): KVFD-2012-6958

Summary

In this study Interlocking nails were used in order to fixate the canine femoral fractures and to examine the effects of the implants on fracture healing, clinically and radiographically in 19 dogs. The material of the study consisted 19 dogs of medium-large size, which were brought to Ankara University, Faculty of Veterinary Medicine, Department of Orthopedics and Traumatology because of injuries due to various trauma and consequent diaphyseal femur fractures clinically and radiologically. Following general anaesthesia, the broken extremity was operated, a total of 20 interlocking pins of different sizes were placed. Among the pins used with an appropriate diameter and length, 10 were 8-199 mm, 4 were 8-185 mm, 2 were 8-172, 1 was 8-165, 2 were 6-172 mm and another was 6-160 mm, respectively. In order to lock these pins 46, 3.5 mm diameter screws, with different length were used. It was observed that 1 screw in proximal and 1 screw in distal region, didn't hold in the holes of the pins. Statical nailing was performed in all cases but one. Cases were clinically examined for weight bearing and extremity usage and radiologically, the callus tissue development was monitored. As a result; the idea was that interlocking nailing technique was an alternative to plates by creating enough rigidity, to fixate 1/3 diaphyseal femoral fractures in medium and medium-large breed dogs.

Keywords: Interlocking nailing, Femur fracture, Fixation techniques, Canine, Dog

Köpeklerde Femur Kırıklarında Interlocking Çivisi Uygulamaları; Ondokuz Olguda Klinik Deneyim ve Sonuçlar

Özet

Bu çalışmada köpeklerde femur kırıklarında interlocking çivileme sistemi kullanılarak implantın kırık iyileşmesine olan etkileri ve kullanım kolaylığı klinik ve radyolojik olarak değerlendirilmiştir. Çalışmanın materyalini Ankara Üniversitesi Veteriner Fakültesi Ortopedi ve Travmatoloji Kliniği'ne getirilen ve yapılan klinik-radyolojik kontrollerde femur kırığı saptanan 19 adet orta-büyük ırktan köpek oluşturmuştur. Hastaların kırıkları genel anestezi ve rutin operatif hazırlıkları tamamlandıktan sonra, toplam 20 adet, uygun çap ve uzunlukta interlocking çivileri ile onarılmıştır. Çalışmada 10 adet 8 mm çap 199 mm uzunlukta, 4 adet 8 mm çap 185 mm uzunlukta, 2 adet 8 mm çap 172 mm uzunlukta, 1 adet 8 mm çap 165 mm uzunlukta, 2 adet 6 mm çap 172 mm uzunlukta ve bir adet 6 mm çap 160 mm uzunlukta çivi kullanılmıştır. Bu çiviler toplam 46 adet 3.5 mm çaplı farklı uzunluklarda vidalar ile sabitlenmiştir. 44 vida yerini bulurken 1 distal ve 1 proksimal vida çivi üzerindeki deliği tutmamış ve korteks ile çivi arasından geçmiştir. Bir olgu hariç tüm olgularda statik çivileme yapılmıştır. Olgular postoperatif dönemde klinik ve radyolojik olarak takip edilerek ekstremitelerini kullanma durumları ile kallus formasyonu izlenmiştir. Sonuç olarak interlocking çivileme sisteminin femur diafiz kırıklarında plaklara alternatif olarak kullanılabilecek gerekli stabiliteyi sağlayan bir alternatif olabileceği kanısına varılmıştır.

Anahtar sözcükler: Interlocking çivileme, Femur kırığı, Kırık fiksasyon teknikleri, Köpek

INTRODUCTION

Femur, which is the long proximal bone of the hindlimb, carries the body weight and pushes the body in forward

direction when moving. Fracture of the femur, results with the disability of the extremity. Several types of fixation systems



İletişim (Correspondence)



+90 318 3573301/3322



bkurum74@yahoo.com

have been developed and utilized for the repair of femoral fractures; however a perfect fixation technique has not been developed yet.

Every year, new implants and fixators are provided to the orthopedists for the treatment of patients with fractured bones. However, some of the implant and fixators are adopted and utilized while some pass out of use.

Today, due to ethical rules and changing trends, new implant systems are more frequently tested in laboratories. It is, in fact, true that valuable findings are obtained from these studies. What should not be forgotten is, a fixation system would hardly find an area of application or could be utilized only very limitedly no matter how ideal fixation it provided, in case its application and postoperative care is difficult and also the device being expensive.

A relatively newly emerged implant system to be used in veterinary orthopedics is Veterinary Interlocking Nailing System. Interlocking nailing is a system constituting of an IM pin with screw holes on that is placed in medullary canal of the bone and locked in/fixated with screws crossing cortex-pin-cortex, i.e. some kind of IM plates. Interlocking nailing is effective for neutralizing all peripheral destructive stresses (shearing, bending, traction, torsion and compression)¹. In interlocking nailing, the pin placed at neutral axis shows resistance to bending forces just as IM pins, while locking in of the system with the screws provides maximum resistance to rotation, compression, shear and traction stresses². Furthermore, interlocking nailing technique provides an additional advantage compared to bone plates, by establishing a greater moment of inertia².

Interlocking nailing technique has been developed by Küntscher in 1968³ and was followed by the development and utilization of different types of interlocking nails. Of these nail varieties, Huckstep system that required open reduction and exposed screw holes via an external guide had been found suitable for veterinary medicine and had come into use after some modifications^{4,5}.

All fractures between smaller trochanter and femoral condyles can be stabilized by an interlocking nail regardless of the fracture's configuration and degree of segmentation. Fractures of this area which is primarily under the stress of rotational and bending loads can be securely fixated by Interlocking Nailing Technique^{6,7}. These fractures are oblique, long spiral, segmental and communitive fractures of femur⁷.

Interlocking nailing technique has started to be referred as a treatment of fractures in cats and dogs during the last two decades and it is reported by various authors that the utilization of interlocking nails in femur, humerus and tibia fractures in dogs had positive results⁸⁻¹⁴. Some researchers have been used the same system for femoral fracture of the cats¹⁴⁻¹⁸. The very same system has been used in the treatment of a femoral fracture in a turkey by Langley-Hobbs *et al.*¹⁹

and by McClure *et al.*²⁰ in femurs of 6 foals which have undergone experimental transversal femoral osteotomy.

It is purposed in this study, the utilization of "Interlocking Nailing System", which is a internal fracture fixation technique whose name started being mentioned for the last two decades, in segmental femur fractures of medium and large size dogs and reporting of the obtained clinical results to the veterinary practice.

MATERIAL and METHODS

Nineteen medium and large size dogs, which have been brought to Ankara University, Faculty of Veterinary Medicine, Department of Orthopedics and Traumatology for traumatic injuries of various reasons and which have been diagnosed with diaphyseal femur fracture following clinical/radiological examination, were included in this study.

For the fixation of femur fractures, 4th generation interlocking nailing set produced by Eickemeyer® (Eickemeyer® GERMANY) for veterinary use, has been utilized (*Fig. 1*. Interlocking Nailing System). Nails of the aforementioned set are made of 316L stainless steel in 6 and 8 mm diameters by the manufacturer. 6 mm nails range from 149 to 172 mm and 8 mm nails from 160 to 199 mm. There is one screw hole at the proximal of the nail and two other holes at the distal with 11 mm distance to each other. Distal endings of the nails are in trokar end shape. A process located distally on the nail is designed for the attachment of the guide. The very same process is also used for holding with the drill when placing the nail. For locking the nails in, AO/ASIF cortical screws of 3.5 mm diameter and 16-32 mm length are used.

Guide showing the screw holes is fixed on to the nail by the attachment apparatus. The distance between attachment apparatus and the nail is maintained due to sliding nature of the apparatus and then fixed. Drill-guide is used during the opening of screw holes, and guide apparatus of the screws is used for the placement of the screws.

Medial lateral and anterior posterior radiographs of both of the femurs of all cases were obtained. In unilateral fractures, radiographs of intact femurs have been used in order to measure femur's diaphyseal length and medullary width. In addition, with the measurements performed on these radiographs, the relation between the fracture line and the screw holes to be opened was assessed.

General anesthesia was maintained by 2 mg/kg xylazine hydrochloride (Alfazyne 2%, EgeVet, İzmir/Turkey) IM following sedation that was maintained by 10 mg/kg ketamin hydrochloride (Alfamine 10%, EgeVet/Turkey) IM. After induction of general anesthesia, the region was shaved and the patient was positioned on its fractured extremity in lateral recumbency and asepsis was maintained by benzalcoholium chloride (Zefireks, Biosel İstanbul/Turkey), povidone iodine (Biokadin, Biokan, İstanbul/Turkey),

and alcohol respectively. Area of interest was limited by surgical clothes and thus, prepared for surgery.

Lateral surgical approach on femur was used ²¹ (Fig. 2A,B). Following the exposition of femur and fracture line, medullary canal of the proximal fragment was opened by a drill tip of the same diameter with the nail to be used. Interlocking nail was placed in the proximal fragment in retrograde direction and pulled out from the hole opened by the drill's tip. The nail was pulled until the fracture line proximally with the use of the drill. When the reduction of

the fracture was completed, the nail was then placed in the distal fragment by launching with the drill. At this step, guide for the screw holes was attached to the nail and holes at appropriate levels were opened (Fig. 2C, D). With the screw depth scaler required screw lengths were defined at the screw holes (Fig. 2E). The system was then locked in by inserting the screws (Fig. 2F, G, H).

Anteroposterior and mediolateral radiographs were taken postoperatively in order to view the results of the procedure. 22.000 IU/kg of penicillin G (Devapen, Deva

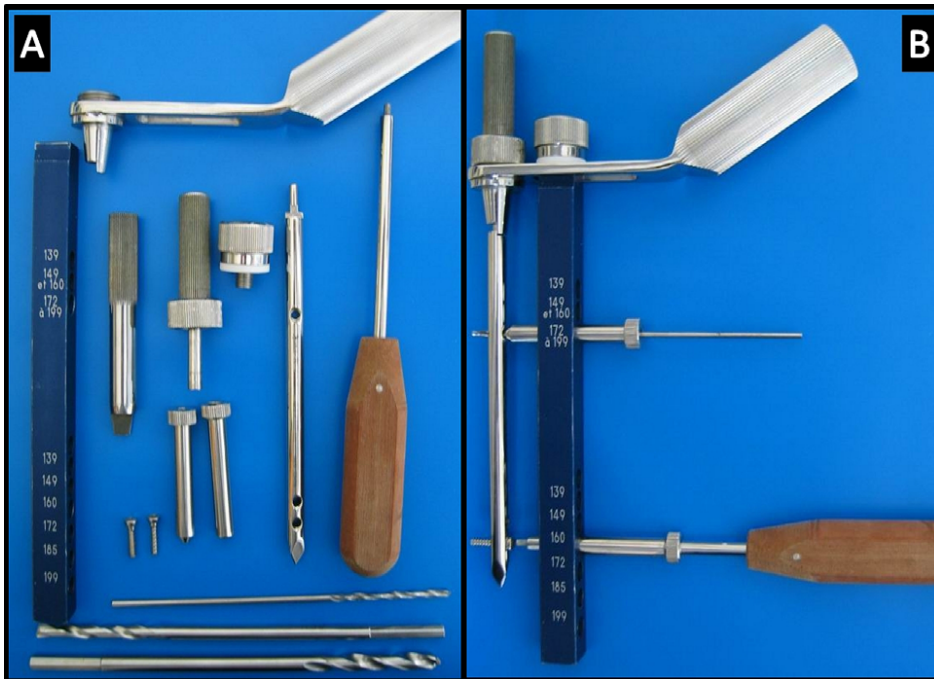
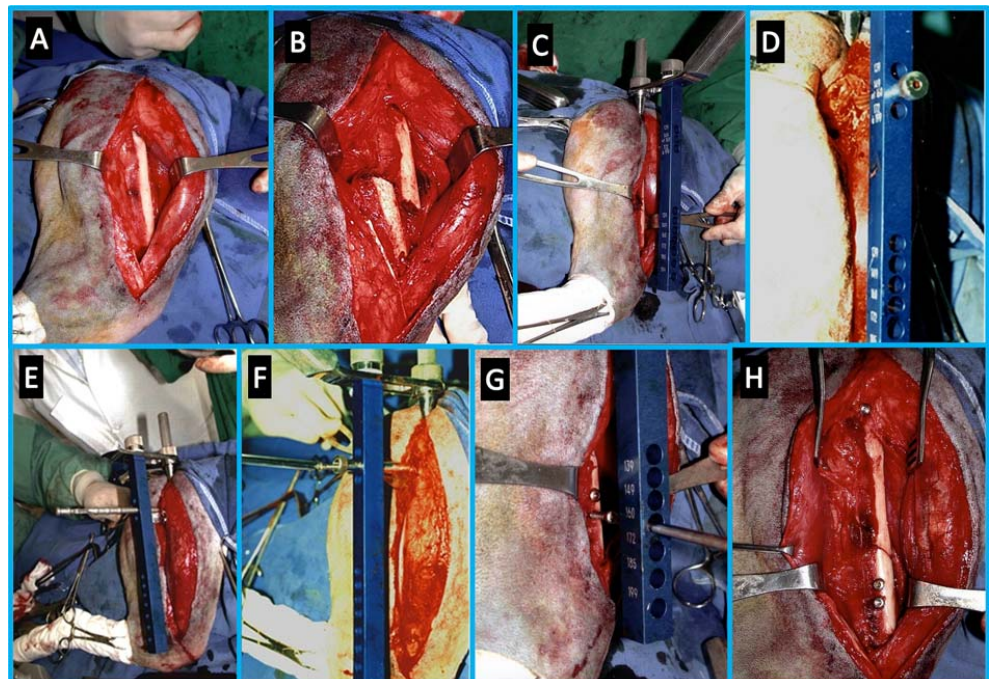


Fig 1. The 4th generation interlocking nailing equipment which was used in operations

Şekil 1. Operasyonlarda kullanılan dördüncü nesil kilitli intramedüller çivileme seti

Fig 2. A and B- Lateral surgical approach on femur, C and D- Guide for the screw holes was attached to the nail and holes at appropriate levels were opened, E- With the screw depth scaler, required screw lengths were defined at the screw holes, F, G and H- The system was then locked in by inserting the screws

Şekil 2. A ve B- Femura lateralden ulaşım, C ve D- Rehber, kilitli intramedüller çiviyeye bağlandı ve uygun seviyelerden vida delikleri açıldı, E- Kullanılacak vidaların boyunu belirlemek amacıyla, vida derinlik ölçer ile ölçüm yapıldı, F, G ve H- Sistem vidaların yerleştirilmesi ile kilitlendi



Co. İstanbul/Turkey) was administered intraoperatively for preventing microbial contamination and this procedure was continued for three more days.

Initial clinical and radiographical examinations of all cases were carried out on postoperative 10th day. During these controls owners were asked for the first time which the patient used its extremity. Second radiological examinations were carried out on 20th day postoperatively. On these second postoperative controls, the patients were asked to lift the front limbs and thus causing the dog to walk on its two hind legs. In this way, the extremity that was applied with interlocking nail could be checked for weight bearing during stepping. Additionally, both of the hind limbs were palpated by the vet while the front legs were lifted by the owner in order to perform weight bearing test. Following checks were performed on the 6th week (40-50th day), 12th week and 24th weeks. In these controls, movement range of knee joint, state of weight bearing and the way that the patient walked and sit were checked, whereas state of the fracture line and fixation, callus tissue density and quality was assessed by radiological examinations.

RESULTS

Of 19 dogs that were included in this study, 12 were female, 7 were male; regarding races, 6 were mixed, 2 were Husky, 4 were Kangal (Anatolian Shepherd), 2 were Rottweiler, 1 was Pointer and 4 were German Shepherd (Fig. 3A).

11 of the fractures were located in the middle third, 4 in the distal third and 5 in the proximal third of diaphysis (Fig. 3B). Seven transversal, 10 oblique, 2 spiral and one segmental fracture were detected (Fig. 3C). Ten 8-199 mm nails, four 8-185 mm nails, two 8-172 mm nails, one 8-165 mm

nail, two 6-172 mm nails and one 6-160 mm nail were used in the procedures (Fig. 3D). For locking in of the nails, a total of forty-six 3.5 mm screws of various lengths were used. In 8 fixations of 20 (cases no. 2, 6, 7, 8, 9, 12, 13, and 16) serclage wires were used in order to support the anatomic reduction of bone fragments.

Of total 20 fractures, 9 were on right and 11 were on left extremities. One case (case no.1) had bilateral femur fraction (Fig. 4).

In one case coxofemoral luxation was already developed accompanying femur fracture (case no.8), and as for case no. 12, ischial tuberosity was fractured together with femur.

When preoperative radiographs were examined, it was found that case no. 7 had in its hip joint of the extremity that the fracture happened and case no. 4 had in its both knee joints, arthritic changes.

Initial time for the cases to use their extremity: The time for this use and weight bearing could not be detected for four cases (cases no. 5, 6, 11, and 16) which were to be kept at kennels during postoperative period. 7 of the other 15 cases (cases no. 3, 4, 7, 13, 14, 17, and 18) started using their extremities in postoperative three days, 6 of them (cases no. 2, 5, 9, 12, 15, and 19) between 4-8th days and one case (case no.8) in 12th day. Case no. one with bilateral fracture started to use its right extremity in 6th day and the left one on 9th day. All cases were treated with static nailing except for one case (case no. 3). For the case (case no. 3) which underwent dynamic nailing, a 8/165 mm interlocking nail was placed tightly in the medullary canal of the distal fragment, proximal screw was locked in and no screws were used in distal end. 3 cases (cases no. 3, 10, 13) were not examined after the initial control on 10th day when the stitches were

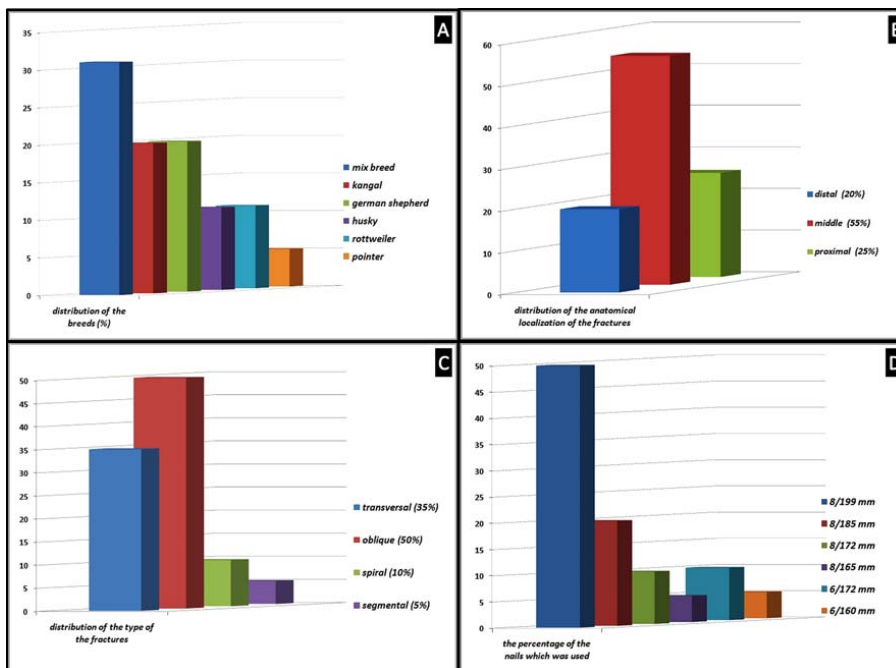


Fig 3. A- Distribution of the breeds which were operated, B- Distribution of the anatomical localization of the fractures, C- Distribution of the type of the fractures, D- The distribution of the nails according to diameter and length

Şekil 3. A- Ameliyat edilen olguların ırklara göre dağılımı, B- Kırıkların anatomik lokalizasyonlarının dağılımı, C- Kırık tiplerinin dağılımı, D- Kullanılan çivilerin çap ve uzunluklarına göre dağılımı

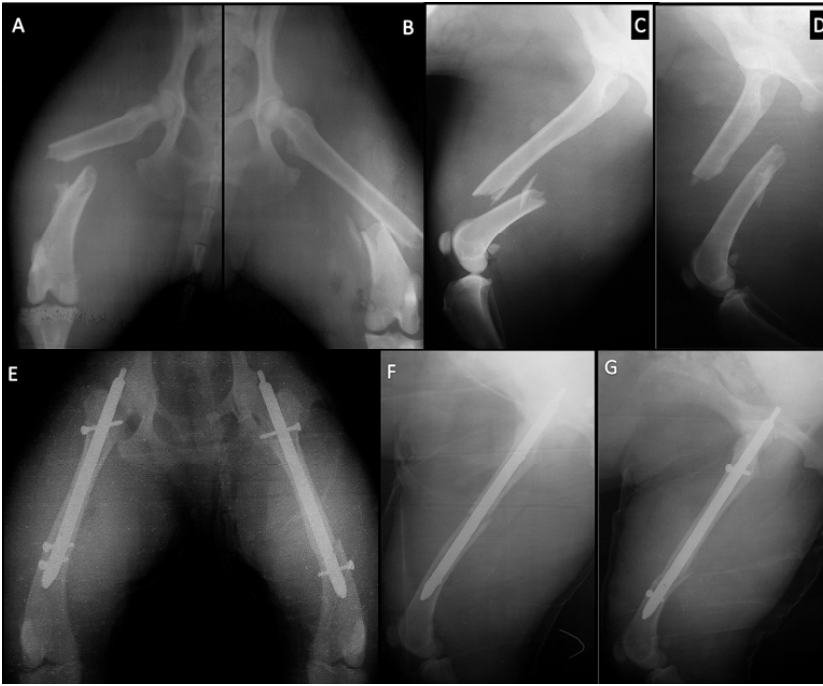
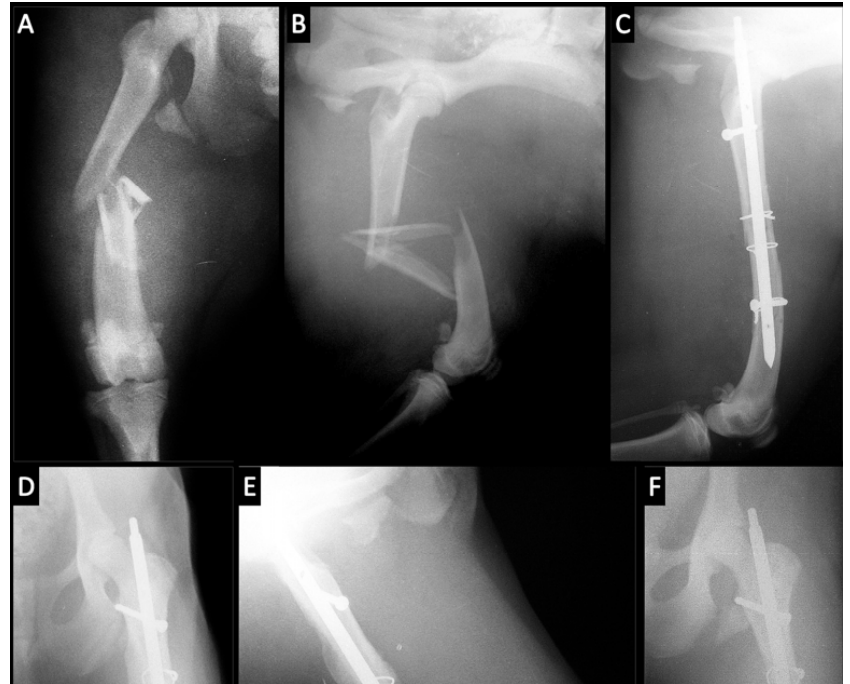
Fig 4. (Case 1), A- Preoperative antero-posterior radiograph of the left femur, B- Preoperative antero-posterior radiograph of the right femur, C- Preoperative medio-lateral radiograph of the right femur, D- Preoperative medio-lateral radiograph of the left femur, E- Postoperative antero-posterior radiograph of the left and right femur, F- Postoperative medio-lateral radiograph of the left femur, G- Postoperative medio-lateral radiograph of the right femur

Şekil 4. Olgu 1'in operasyon öncesi ve sonrası radyografileri, A- Sol femurun preoperatif antero-posterior radyografik görünümü, B- Sağ femurun preoperatif antero-posterior radyografik görünümü, C- Sağ femurun preoperatif medio-lateral radyografik görünümü, D- Sol femurun preoperatif medio-lateral radyografik görünümü, E- Sol ve sağ femurun postoperatif antero-posterior radyografik görünümü, F- Sol femurun postoperatif medio-lateral radyografik görünümü, G- Sağ femurun postoperatif medio-lateral radyografik görünümü

Fig 5. (Case 17), A- Preoperative radiological antero-posterior view of the femur, B- Preoperative radiological medio-lateral view of the femur, C- Postoperative radiological medio-lateral view of the femur, D- Postoperative radiological antero-posterior view of the femur, E- Postoperative radiological antero-posterior view of the femur in 6th week, F- Postoperative radiological medio-lateral view of the left femur in 6th week

Şekil 5. (Olgu 17), A- Femurun preoperatif antero-posterior radyografik görünümü, B- Femurun preoperatif medio-lateral radyografik görünümü, C- Femurun postoperatif medio-lateral radyografik görünümü, D- Femurun postoperatif antero-posterior radyografik görünümü, E- Postoperatif 6. haftadaki antero-posterior radyografik görünüm, F- Postoperatif 6. haftadaki medio-lateral radyografik görünüm



removed. Owners of these dogs reported that they were fine and walking around during telephone contacts.

Cases no. 4 and 14 which were bad tempered did not permit clinical weight bearing test. As for cases no. 5, 6, 11, 16 which were kept at kennels, could not be tested on appropriate time (20.-25th day) since they were not taken to examination regularly. For cases no. 7, 9, 17, and 18 it was detected that they could bear all of their body weight on their IL nailed extremities without discomfort and they could stand on these extremities for a while. As for cases 2, 12, 15, and 19 it was detected that they could bear their body

weight on the considered extremity, however they were not comfortable with that and they immediately wanted to change with the other intact leg. Case no. 8 preferred to bear on the intact extremity since the same extremity was treated with IL nailing accompanied by excision arthroplasty. It was detected in case no.1 whose both extremities were fractured, that it could use the right leg more comfortably.

Hip and knee joint functioning ranges were also evaluated beginning from the second postoperative examination. Measurements and manipulations showed that all cases were capable of moving without any restriction except for

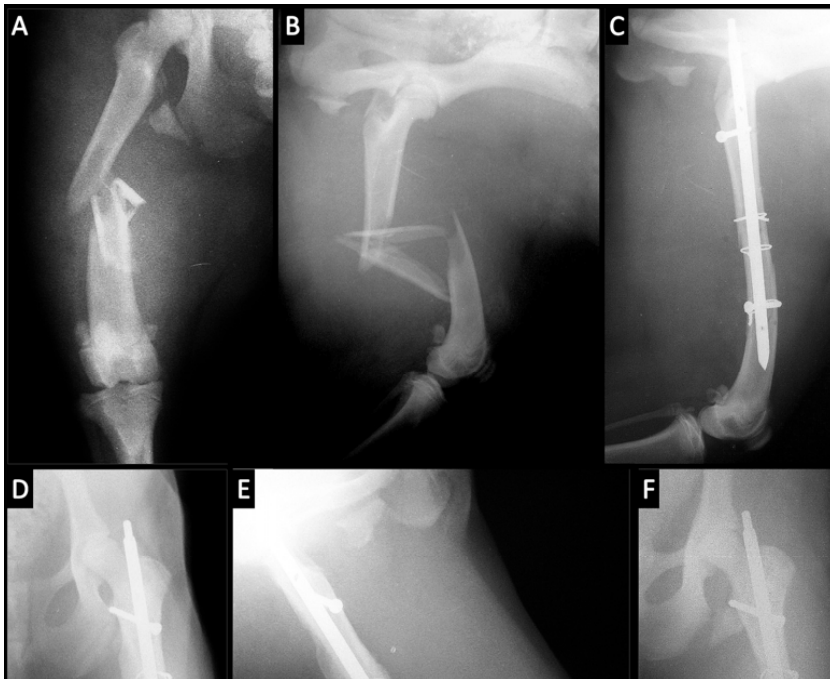

Fig 6. (Case 16), **A-** Preoperative radiological antero-posterior view of the femur, **B-** Preoperative radiological medio-lateral view of the femur, **C-** Postoperative radiological antero-posterior view of the femur, **D-** Postoperative radiological medio-lateral view of the femur, **E-** The hole of the nail is empty because the screw did not pass the hole, **F-** There is extensive callus around the femoral diaphysis

Şekil 6. (Olgu 16), **A-** Femurun preoperatif antero-posterior radyografik görünümü, **B-** Femurun preoperatif medio-lateral radyografik görünümü, **C-** Femurun postoperatif antero-posterior radyografik görünümü, **D-** Femurun postoperatif medio-lateral radyografik görünümü, **E-** Distal vidanın boşa gittiğini gösteren medio-lateral radyografi, **F-** Femurun çevresindeki taşkın kallus dokusu görülmektedir

case number 8 that underwent excision arthroplasty and case number 4 which arthritis developed in its knee. None of the cases had muscle or joint contractures developed.

In cases no. 6 and 16 that were kept at kennel there was slight and superficial skin infection, whereas the rest of the cases recovered without complication. None of the cases developed bone infection. In one case (case no.15) subdermal serosity accumulated and swelling developed due to over length of the interlocking nail at the proximal end. This complication has been overcome following the removal of the nail by the knitting of the bone.

Postoperative initial radiographs were immediately taken after operation and fixation was evaluated. Particularly, adaptation of the screws and screw holes on the nail was evaluated in these radiographs. In case no.12, the proximal screw (Fig. 5) and in case no.2 distal screw was seen to be loose (Fig. 6). In case no.12, sinking at the fracture line was observed in radiographs on postoperative 20th day. Approximately 1 cm of shortening has occurred in the extremity.

Series of radiographs were repeated on 10th day when the stitches were removed and on 20th day when second controls were made. On 10th day, stability of fixation was evaluated comparatively with initial postoperative radiographs. No changes were detected regarding stability in none of the cases. As for the radiographs taken on 20th day, primarily the amount and quality of callus was assessed. By the radiographs taken afterwards, fracture healing was followed. In none of the cases absence or delay of knitting was seen. In all cases, clinical fracture healing was completed around 20th day. In cases 2, 14, and 18, excessive callus tissue was observed.

In some of the cases (1, 7, 14, and 15) which fracture healing completion was supported by radiological findings, the

interlocking nail was removed. The nails were not removed in other cases.

DISCUSSION

Approximately half of all long bone fractures in dogs and cats involve the femur, a rate more than double that of other bones²². Femur fractures constitute 20-25% of all the fractures in cats and dogs²³.

Unstable fractures of femoral shaft happen frequently in dogs and relevant studies in order to stabilize these sorts of fractures are continued for years in veterinary orthopedics. Today, methods used for fracture treatment are divided in two main classes: external fixators and internal fixation. These two different classes have their pros and cons when compared.

External fixators are generally considered as less traumatic since the fracture line does not require to be opened. However, postoperative care is more difficult and the risk of carrying infectious agents through the pins from outside (skin) to inside (bone) is present²⁴. Also because of the closeness of the abdomen to the proximal femur and bulky surrounding muscles limit the use of coaptation and external fixation methods for femoral fracture²⁵. Single implant type that enables fracture healing with primary callus formation is plates. Plates provide stabilization through buttress effect. The plate is placed on the bone like a bridge and stabilizes the fracture line²⁶. Compression, bending and torsion stresses and all combinations of these are neutralized by the plate during fracture healing^{27,28}. Plates neutralize and bear the entire load on the extremity as reported²⁶, on the other hand, it is required that the bone and implant sharing the load on the extremity in order to stimulate bone healing²⁹. However, the interlocking nail

was shown to share the load on the extremity equally with the bone by ³⁰. Other disadvantage of the plate is that it disturbs vascularization of the cortical surface it is applied on ³¹. Oppositely, interlocking nail does not impair the cortical surface and does not decrease blood flow - although it fills the medullary space almost completely - more than 8% ³².

There is no reaming in veterinary application of interlocking nails, but still medullary vascularization is damaged during insertion of the nail. We avoided reaming as much as possible, considering the damage it could cause. But in some cases we had to open the medullary canal with a same size drill before placement, because diameters of medullary canal and the nail were almost equal it was possible for the nail to cause fissures of the cortex. We consider that reaming should be avoided since it could severely impair intramedullary vascularization. Self restoration of endosteal vascularization can take several weeks which is -considering that clinical fracture healing takes 3 weeks-quite long ³³.

In veterinary medicine Steinmann's pins with circular cross section are preferred among all types of intramedullary pins. Steinmann's pins are easy to insert and remove after fracture healing. These types of pins ensure axial alignment of bone fragments, and neutralize the bending stress at the fracture line to some extent ³⁴. They are however, ineffective in neutralizing all destructive stresses such as shearing, compression, and rotation and may delay functional use of the extremity ³⁵. It is reported by that fixations with circular cross sectioned pins might require supplementary fixation procedures such as application of serclage or intercompression screws ³⁵. The most important difference between interlocking nailing and conventional circular cross sectioned pins is, when static nailing is performed, interlocking nailing system neutralizes all destructive stresses and prevents shortening through avoiding compression of the fragments ¹.

Interlocking nailing is not most rigid fixation technique among the ones used today however, it is considered to be more advantageous from biological, biomechanical, technical and functional aspects. It is reported by Duhatois ¹⁷ that it was a biological advantage that it required a smaller surgical opening and less dissection. Yet we had to make wider incisions in order to maintain sufficient exposure and provide convenient implantation in 20 femurs we operated. In addition, the proximity of screw holes to proximal and distal ends of the nail required this kind of wider incisions. This situation lead to a result conflicting with the idea that interlocking nails might be implanted with less soft tissue incision compared to plates.

Since interlocking nails are not placed on cortex, they give less damage to periosteal circulation ³⁶. It is fixed by smaller number of screw compared to bone plates so it constitutes fewer stress enforcing points and decreases the risk of implant-induced new fracture formation ³⁷. Furthermore, it would certainly be financially advantageous for the owner

since fewer screws are required.

Interlocking nail-bone complex has distinct biomechanical advantages to bone-plate, intramedullary pin-bone and external fixator-bone complexes particularly in communitive fractures, in addition to this biomechanical superiorities of interlocking nail-bone complex to plate-bone complex such as greater torsional resistance, bending endurance and fatigue values are also revealed ^{12,28,38}.

Due to closely located screw holes on plates, in communitive fractures it is difficult to find intact cortical area to apply the plate. In this case, the rigidity provided by the plate would be questionable ³⁹. On the contrary, an interlocking nail with screw holes close to the proximal and distal ends would be the only solution to be placed easily. We have too, experienced that the placement of interlocking nails in fractures with mid third of the shaft segmented, was in fact very simple when basic principles of the system were followed. We have also observed that maintaining the original bone length was easy with this system particularly in communitive fractures.

Another point, which was barely mentioned in literature, was the length of the procedure. For the first cases in our study, mean duration of the surgery was almost equal to time spent in plate application. Procedure time decreased in time, as we gained more experience however, it never got shorter enough to apply a Steinmann's pin. This is explained by necessity of further dissection required by this system and need of special attention when inserting the screws. Therefore, the most important property of this system is the locking in of the screws. However, if careful attention is not paid, it is possible to define the levels and directions for the screws wrongly. Likewise Duhatois ¹⁷ reported that 10 (4%) of the 228 screws (mean number of screws per case: 1, 88) inserted were positioned faulty, namely the nail inside the medullary canal was not crossing the screw holes. It was also put forth by the same author that faulty positioning was more likely to be made in distal screw holes.

In our study, we have used 46 screws for 20 femur fractures. We detected that we were unable to position 2 of these screws (one distal and one proximal) and we have inserted the screws wrongly in postoperative radiographs. The interlocking nail and the kit was one of state of the art versions. It was stated by the manufacturer in the catalogue that nail-guide coupling was extremely rigid and thus the probability of faulty guiding was minimized. We have however, observed during procedures that, even complete nail-guide coupling was achieved, very small shifts between the axles of either the guide or the nail resulted in misdirection of the screws. When the holes on the interlocking nail are examined, it can be seen that the holes on the guide side of the nail are designed in cone shape so that they can capture the screw and pass through the canal in cases where the screw direction is wrong. However, in spite of these precautions, a screw may be

wrongly directed and miss the screw hole even it is applied from the level shown by the guide.

In segmented femur fractures, stabilization is maintained by intramedullary pins where fixation of distal and proximal main fragments in original bone length by retrograde technique is followed by insertion of small fragments like a puzzle and then complete anatomic reduction is tried to be maintained through fixation by cerclage⁴⁰. Segmented fractures where interlocking nail is applied also require cerclage placement for complete anatomic reduction. We have too, used cerclage wires in 8 cases to maintain complete anatomic reduction.

We suggest in the light of our study that, considering reduction, immobilization, and functional healing time provided in diaphyseal femur fractures with interlocking nailing, this technique can be a successful alternative to other osteosynthesis methods, particularly in indicated fracture types.

Our principal impression of this study is that fixation with interlocking nail can be alternatively used instead of bone plates in segmented and unstable fractures of every kind on femur's shaft. It should also be noticed that the system was not very easy to be applied and required the assistance of an experienced operator for further success. However, it is reported in literature that a disadvantage of misleading the screws existed no matter how much attention and care is paid. Despite that, interlocking nailing system can satisfy both the physician and the patient in case of a flawless fixation is achieved.

REFERENCES

- Kinast C, Freigg R, Perren SM:** Biomechanics of the interlocking nail. *Arch Orthop Trauma Surg*, 109, 197-204, 1990.
- Bernard A, Diop A, Maurel N, Viguier E:** An invitro biomechanical study of bone plate and intelocking nail in a canine diaphyseal femoral fracture model. *Vet Surg*, 30, 397-408, 2001.
- Bohler L, Bohler J:** Kutscher's medullary nailing. *J Bone Joint Surg Am*, 31A, 295-305, 1949.
- Huckstep RL:** Intramedullary compression nail The intramedullary compression nail for difficult femoral fractures. **In**, Selington D (Ed): *Concepts in Intramedullary Nailing*. pp. 315-347, Orlando, FL, Grune& Stratton, 1985.
- Huckstep RL:** The Huckstep intramedullary compression nail. Indication tecnique and results. *Clin Orthop*, 212, 48-61, 1986.
- Klemm KW, Börner M:** Interlocking nailing of complex fractures of the femur and tibia. *Clin Orthop*, 212, 89-100, 1986.
- Johnson KA, Huckstep RL, Francis DJ:** Healing of comminuted femoral fractures stabilized with an interlocking intramedullary nail. *Proceeding of 15th Annual Veterinary Orthopedic Society Breckenridge*. p. 33, 1988.
- Dueland RT, Johnson KA:** Interlocking nail fixation of diaphyseal fractures in the dog. A multicenter study 1991-92 cases. *Vet Surg*, 22, 337, 1993.
- Muir P, Parker RB:** Interlocking intramedullary nailing stabilization of a diaphyseal tibial fracture. *J Small Anim Pract*, 34, 26-30, 1993.
- Durall I, Diaz MC, Morales I:** Interlocking nail stabilization of humeral fractures. Initial experience in 7 clinical cases. *Vet Comp Orthop Traumatol*, 7, 3-8, 1994.
- Durall I, Diaz MC:** Early experience with the use of an interlocking nail for the repair of canine femoral shaft fractures. *Vet Surg*, 25, 397-406, 1996.
- Dueland RT, Berglund L, Vanderby R, Chao EYS:** Structural properties of interlocking nails, canine femora, and femur-interlocking nail constructs. *Vet Surg*, 25, 386-396, 1996.
- Dueland RT, Johnson KA, Roe SC, Engen MH, Lesser AS:** Interlocking nail treatment of diaphyseal long-bone fractures in dogs. *JAVMA*, 214 (1): 59-66, 1999.
- Endo K, Nakamura K, Maeda H, Matsushita T:** Interlocking intramedullary nail method for the treatment of femoral and tibial fractures in cats and small dogs. *J Vet Med Sci*, 60, 119-122, 1999.
- Larin A, Eich CS, Parker RB, Stubbs WP:** Repair of diaphyseal femoral fractures in cats using interlocking intramedullary nails: 12 cases 1996-2000. *JAVMA*, 219 (8): 1098-1104, 2001.
- Horstman CL, Beale BS:** Long fracture repair using the interlocking nail in a minimally invasive surgical procedure in cats and dogs: 65 cases (1994-2001). *Vet Comp Orthop Traumatol*, 15, A6, 2002.
- Duhautois B:** Use of interlocking nails for diaphyseal fractures in dogs and cats: 121 cases. *Vet Surg*, 32, 8-20, 2003.
- Çaptuğ Ö, Bilgili H:** Treatment of long bone fractures by interlocking nailing fixation technique in 5 cats. *Vet Cerrahi Derg*, 12, 36-44, 2006.
- Langley-Hobbs SJ, Friend E:** Interlocking nail repair of fractured femur in a turkey. *Vet Rec*, 150, 247-248, 2002.
- McClure SR, Watkins JP, Ashman RB:** *In vivo* evaluation of intramedullary interlocking nail fixation of transverse femoral osteotomies in foals. *Vet Surg*, 27, 29-36, 1998.
- Piermattei DL, Greeley RG:** *An Atlas of Surgical Approaches to the Bones and Joints of the Dog and Cat*. pp. 270-271, S.W. Saunders, Philadelphia, 2003.
- Unger M, Montavon PM, Heim UF:** Classification of fractures of the long bones in the dog and cat: introduction and clinical application. *Vet Comp Orthop Traumatol*, 3, 41-50, 1990.
- Whitehair JG, Wasseur PB:** Fractures of the femur. *Vet Clin North Am: Small Anim Pract*, 22, 149-159, 1992.
- Egger EL:** External skeletal fixation. **In**, Slatter D (Ed): *Text Book of Small Animal Surgery*. pp. 1641-1656, WB Saunders, Philadelphia, 1993.
- Simpson DJ, Lewis DD:** Fractures of the femur. **In**, Slatter D (Ed): *Text Book of Small Animal Surgery*. pp. 2059-2090, WB Saunders, Philadelphia, 1993.
- Roe S:** Internal fracture fixation. **In**, Slatter D (Ed): *Text Book of Small Animal Surgery*. pp. 1798-1818, WB Saunders, Philadelphia, 1993.
- Perren SM:** The biomechanics and biology of internal fixation using plates and nails. *Orthopedics*, 12, 21-35, 1989.
- Bernarde A, Diop A, Maurel N, Viguier E:** An *in vitro* biomechanical study of bone plate and intelocking nail in a canine diaphyseal femoral fracture model. *Vet Surg*, 30, 397-408, 2001.
- Rubin CT, Lanyon LE:** Osteoregulatory nature of mechanical stimuli: Function as a determinant for adaptive remodeling in bone. *J Orthop Res*, 5, 300-310, 1987
- Russel TA, Taylor JC, LaVelle DG:** Mechanical characterization of femoral interlocking intramedullary nailing system. *J Orthop Trauma* 5, 332-340, 1991.
- Perren SM:** The biomechanics and biology of internal fixation using plates and nails. *Orthopedics*, 12, 21-35, 1989.
- Rand JA, An KN, Chao EYS:** A comparison of the effect of open intramedullary nailing and compression plate fixation on fracture-site blood flow and fracture union. *J Bone Joint Surg*, 63-A, 427-442, 1981.
- Rhinelandier FW:** Effects of intramedullary nailing on the normal blood supply of diaphyseal cortex. *J Orthop Trauma*, 12, 1203-1207, 1997.
- McLaughlin R:** Internal fixation: Intramedullary pins, cerclage wires and interlocking nails. *Vet Clin North Am: Small Anim Pract*, 29 (5): 1097-1117, 1999.
- Kyle RF:** Biomechanics of intramedullary fracture fixation. *Orthop*, 8, 1356-1359, 1985.
- Rand JA, An KN, Chao EYS:** A comparison of the effect of open intramedullary nailing and compression plate fixation on fracture-site blood flow and fracture union. *J Bone Joint Surg*, 63-A, 427-442, 1981.
- Rosson J, Egan J, Shearer J:** Bone weakness after the removal of plates and screws *J Bone Joint Surg*, 73B, 283-286, 1991.
- Muir P, Johnson KA, Markel MD:** Area moment of inertia for comparison of implant cross-sectional geometry and bending stiffness *Vet Comp Orthop Traumatol*, 8, 146-152, 1995.
- Beaupre GS, Carter DR, Dueland RT:** A biomechanical assesment of plate fixation with insufficient bony support. *J Orthop Res*, 6, 721-729, 1998.
- DeYoung DJ, Curtis WP:** Methods of internal fracture fixation. **In**, Slatter DH (Ed): *Textbook of Small Animal Surgery*. 2nd ed., Vol. 2, pp. 1610-1631, WB Saunders Co. Philadelphia, 1998.