

Ventricular Septal Defect and Pulmonic Stenosis in a Dog (Bir Köpekte Ventriküler Septal Defekt ve Pulmonik Stenozis)

Zeki YILMAZ^{1,a} Pınar LEVENT¹ Ahmet SARIL¹
Akiko UEMURA^{2,b} Meriç KOCATÜRK^{1,c} Ryou TANAKA^{2,d}

¹ Department of Internal Medicine, Faculty of Veterinary Medicine, Bursa Uludag University, TR-16059 Bursa - TURKEY

² Veterinary Surgery, Department of Veterinary Medicine, Faculty of Agriculture, Tokyo University of Agriculture and Technology, Tokyo, 183-8509, JAPAN

^a ORCID: 0000-0001-9836-0749; ^b ORCID: 0000-0003-2671-5074; ^c ORCID: 0000-0002-2849-1222; ^d ORCID:0000-0001-9948-6490

Article Code: KVFD-2019-22616 Published Online: 12.06.2019

How to Cite This Article

Yilmaz Z, Levent P, Saril A, Uemura A, Kocatürk M, Tanaka R: Ventricular septal defect and pulmonic stenosis in a dog. *Kafkas Univ Vet Fak Derg*, 25 (5): 729-730, 2019. DOI: 10.9775/kvfd.2019.22616

Dear Editor,

Ventricular septal defect (VSD) is characterized by an abnormal communication between left (LV) and right ventricles (RV) with left-to-right and than right-to-left cardiac shunts^[1,2]. Pulmonic stenosis (PS) is a congenital heart defect of the semilunar valve between the RV and the pulmonary artery (PA). When the leaflets of PA valves are thickened and/or the annulus is narrowed, these findings give rise to PS causing very mild to severe obstruction of the blood flow from heart to the lungs^[2]. PS may also be associated with other congenital defects such as VSD and aortic stenosis (AS). Dogs with small VSD and/or mild PS have a normal lifespan without clinical signs. In dog with large VSD, in the physical examination, loud cardiac murmur, exercise intolerance, and severe panting can be observed. However, dogs with severe PS may have exercise-induced syncope, arrhythmias or heart failure^[1]. These observations show that timing in the diagnosis of congenital heart defects is important on whether medical therapy and/or surgical approach could be suggested. Thus, we have described here the presence of two congenital cardiac defects (VSD and PS), and their diagnostic algorithm by use of conventional diagnostic techniques with three-dimensional computed tomographic angiography (3D-CTA) in a dog.

A Doberman Pincher dog (5 years, female, and 7.1 kg) was referred for further examination of heart diseases from a small animal clinic to Animal Hospital (Faculty of Veterinary Medicine, Bursa Uludag University) with a history of exercise intolerance during strenuous exercise for 2.5 months. Before admission, the patient was treated with furosemide for 7 days due to suspicious of pulmonary oedema. Body temperature (38.5°C), capillary refilling time (<2 sec) and respiratory rates (22/min.) were within reference ranges. Colour of mucous membranes was normal, and external lymph nodes and abdominal palpation were unremarkable. Soft systolic cardiac murmur - grade 1/6 was auscultated over left 3-5 intercostal spaces. Thoracic

radiography showed PA bulging with a normal lung tissue appearance suggestive for aorta-pulmonary window (APW), patent ductus arteriosus (PDA) or PS. ECG examination showed qrS complex and sinus tachycardia (150 bpm). Complete blood cell counts and serum biochemistry profile were non-specific. Serum BUN (29.4 mg/dL) was observed at maximum level of its reference (10-30 mg/dL) and serum Na level (141 mEq/L) was of its lower reference level (141-152 mEq/L) due to furosemide administration. Serum cardiac troponin I was 0.06 ng/mL (reference: <0.07 ng/mL), as well.

Standard echocardiographic images showed that LV related geometric (LV dimension and thickness of inter-ventricular septum and LV post-wall) and functional measurements (fractional shortening - FS% and ejection fraction - EF%) were within reference ranges. Two-dimensional left atrium (LA) to aortic root (Ao) ratio was 1.2, and Ao to PA ratio was 1.4, suggestive for narrowing PA. There was also post-stenotic dilation of main PA. Colour Doppler showed a severe turbulence just below the PA valve, and CW Doppler indicated the presence of PS based on the high PA velocity (4.48 m/s) and pressure gradient (PG: 80.1 mmHg) (Fig. 1). Based on the PG, PS has been defined as mild (<50 mmHg), moderate (50-80 mmHg) and severe (>80 mmHg)^[2]. In this dog, PS was further classified as a valvular type B due to hypoplastic pulmonic valve annulus and thickening of valvular leaflets^[1,2]. PDA and APW were rule-out the differential diagnosis list because there were not continuous type machinery murmur in thoracic auscultation, typical ECG abnormalities (tall R wave and P-mitrale) and continuous systolic and diastolic pulmonary flows with CW Doppler echocardiography^[1].

A small VSD was identified due to less than 1/3rd of Ao diameter (0.6 cm vs 1.4 cm). The severity of VSD is mainly determined by the size of VSD and PG between ventricles. A small VSD (restrictive) causes a louder murmur and higher PG (usually around maximum velocity of 5 m/s and PG of 80 mmHg)



İletişim (Correspondence)



+90 224 2940809



zyilmaz@uludag.edu.tr

because LV systemic pressure is five times larger than RV pressure (around 100 mmHg to 20 mmHg, respectively) which is also the reason of left to right shunt than right to left shunt in small defects [1]. Thus, the possible reason why we observed the soft and lower intensity murmur and measured low intensity velocity (2.9 m/s) and PG (35.8 mmHg) of ductal flow (Fig. 2) in this dog is that shunt rate of VSD might be controlled by RV pressure overload arising from PS, as reported previously [3]. In this case, Qp:Qs ratio was 2.1, in compatible with left to right shunt. VSD is considered as small (restrictive), moderate (moderately restrictive), or large (nonrestrictive) if Qp:Qs was <1.5, between 1.5 and 2.5, and >2.5, respectively [4]. Thus, since VSD peak velocity was measured between 2.5 m/s and 4.0 m/s with lower PG of 25-60 mmHg, moderately restrictive VSD could be possible in this case. Perimembraneous VSD and PS were confirmed by use of 3D-CTA (Fig. 3), as reported in a previous case [5]. Based on the diastolic (mitral and tricuspid inflows - E/A ratio and E/e' septal) and systolic indices (LV - FS%, EF%, ejection time and pre-ejection period), diastolic and systolic dysfunctions were not possible yet in this dog.

For this patient, medical support did not suggested because there were not a cardiac dysfunction and chamber enlargement due to moderate PS and small VSD. The dog was re-examined two times in 3-month intervals, and did not need still any

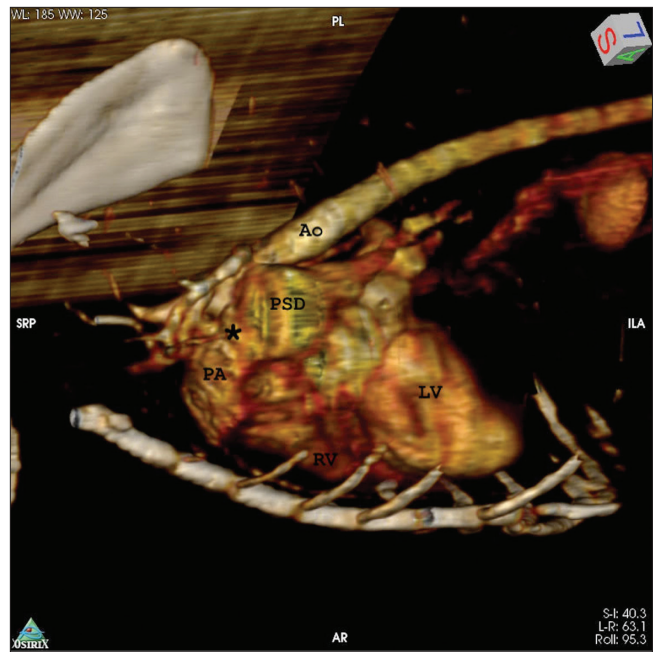


Fig 3. 3D-CTA showed the pulmonic stenosis (asterix) and post-stenotic dilation (PSD) of pulmonary artery (PA). Ao: Aorta, LV: Left ventricle, RV: Right ventricle

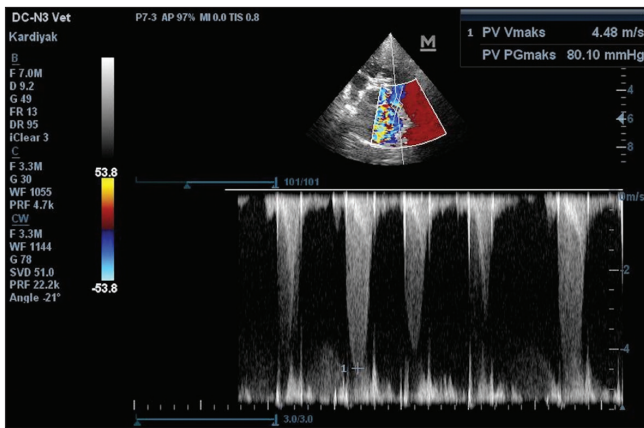


Fig 1. Right parasternal short axis view, CW Doppler indicated pulmonic stenosis (Vmax: 4.48 m/s and pressure gradient: 80.1 mmHg)

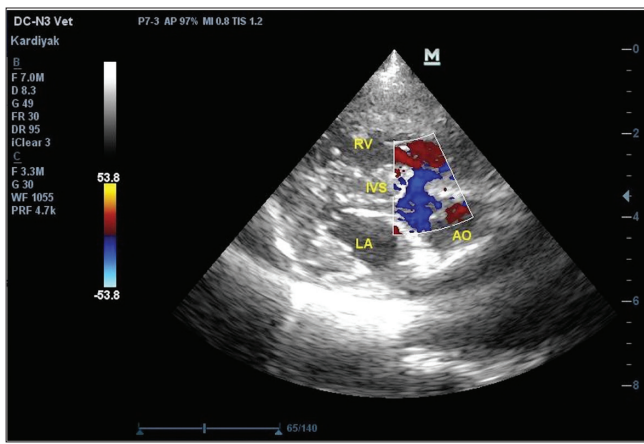


Fig 2. Right parasternal long axis 5 chamber view and color Doppler indicated a defect just below the aortic valve, in compatible with perimembraneous ventricular septal defect (VSD)

medication. The possible mechanism of the non-clinical signs in this dog is that PS could be prevent left heart failure caused by VSD [3]. In dogs with clinical symptoms and having a cardiac remodelling due to PS, medical support such as pimobendan, sildenafil or bosentan is used to reduce PA hypertension [1,5]. In severe cases of PS, balloon valvuloplasty is performed as well. Dogs with mild VSD should be monitored without medication if the patients do not show the clinical signs because it could be closed spontaneously in time. If not, VSD can cause left heart failure, and then classical drug therapy should be initiated. VSD could be improved by surgical approaches [1].

In conclusion, radiography only provides information regarding the size and shape of the silhouette of the heart but angiocardiology (3D-CTA) could be used to see vasculatures, stenosis, shunts and multiple congenital cardiac defects in dogs. Doppler echocardiography is superior to describe severity of PS, compared to 3D-CTA. Medical support should only be thought if the patients have shown clinical signs related with VSD and PS.

REFERENCES

1. Smith FWK, Oyama MA, Tilley LP, Sleeper MM: Manuel of Canine and Feline Cardiology. 5th ed., Elsevier, 2016.
2. Chetboul V, Bussadori C, Madron E: Clinical echocardiography of the dog and cat. Elsevier, USA, 2016.
3. Yamane T, Awazu T, Watanabe N, Ishibahsi T, Fujii Y, Watanabe T, Wakao Y: Ventricular septal defect with pulmonary valvular stenosis in a dog. *Adv Anim Cardiol*, 34 (1): 25-30, 2001. DOI: 10.11276/jsvc.34.25
4. Bomassi E, Misbach C, Tissier R, Gouni V, Trehiou-Sechi E, Petit AM, Desmyter A, Damoiseaux C, Pouchelon JL, Chetboul V: Signalment, clinical features, echocardiographic findings, and outcome of dogs and cats with ventricular septal defects: 109 cases (1992-2013). *J Am Vet Med Assoc*, 247 (2): 166-175, 2015. DOI: 10.2460/javma.247.2.166
5. Yilmaz Z, Kocatürk M, Levent P, Sarılı A, Salcı H, Sağı S: Eisenmenger's syndrome in a cat with ventricular septal defect. *Kafkas Univ Vet Fak Derg*, 24 (5): 781-782, 2018. DOI: 10.9775/kvfd.2018.20421