

# The Effect of Ticagrelor on Ischemia-Reperfusion Injury of Kidney: Is the Pleiotropic Effect a Valid Factor?

Murat BAĞCIOĞLU<sup>1</sup>  Ramazan KOCAASLAN<sup>1</sup>  
Mehmet USLU<sup>1</sup> Gülname FINDIK GÜVENDİ<sup>2</sup>

<sup>1</sup> Kafkas University, Faculty of Medicine, Urology Department, TR-36000 Kars - TURKEY

<sup>2</sup> Kafkas University, Faculty of Medicine, Pathology Department, TR-36000 Kars - TURKEY

Article Code: KVFD-2017-17988 Received: 17.05.2017 Accepted: 28.08.2017 Published Online: 30.08.2017

## Citation of This Article

**Bağcıoğlu M, Kocaaslan R, Uslu M, Fındık Güvendi G:** The effect of ticagrelor on ischemia-reperfusion injury of kidney: Is the pleiotropic effect a valid factor? *Kafkas Univ Vet Fak Derg*, 23 (6): 917-924, 2017. DOI: 10.9775/kvfd.2017.17988

## Abstract

The goal of this study was to determine the protective effect of ticagrelor against ischemia-reperfusion injury in the kidney of rats via histological examination, biochemical parameters, and immunohistochemical analysis. Thirty male rats were randomized into five groups. The animals received ticagrelor 5 mg/kg, 10 mg/kg and 20 mg/kg or normal saline 0.1 mL/kg (control) orally before the procedure. The sham group only had laparotomy. An ischemia-reperfusion injury was done by clamping the renal hilus. There was less malonaldehyde assay (MDA) in ticagrelor groups than the control group, and this decrease was statistically significant ( $P=0.001$  in all ticagrelor received groups). The glutathione peroxidase (GPx) and glutathione reductase (GR) were elevated in ticagrelor groups at all doses. Similar findings were observed in all treatment groups. The 5 mg ticagrelor treated group had no changes in glomerules and tubules relative to the control group via histology. Dilated tubular structures were similar to the sham group-both at 10 and 20 mg ticagrelor. Caspas-3 and NF-KB activity was similar in ticagrelor treated groups to sham group. Our study showed that ticagrelor is an effective agent to protect kidney from renal ischemia-reperfusion injury. Ticagrelor may protect the tissues by reducing the concentration of reactive oxygen species and inducing the antioxidant system-especially with the pleiotropic effect.

**Keywords:** Kidney, Ischemia, Reperfusion, Injury, Ticagrelor

# Böbrekte İskemi-Reperfüzyon Hasarında Ticagrelor'un Etkisi: Pleiotropik Etki Geçerli Bir Faktör mü?

## Özet

Bu çalışmada, ticagrelor'un ratların böbreğinde oluşturulan iskemi-reperfüzyon hasarına karşı koruyucu etkisinin histolojik, biyokimyasal ve immünohistokimyasal yöntemler kullanılarak tanımlanması amaçlanmıştır. Bu amaçla, 30 erkek rat rastgele olarak 5 gruba ayrılmıştır. Bu hayvanlara, yapılacak işlemlerden önce ticagrelor 5 mg/kg, 10 mg/kg ve 20 mg/kg dozlarında, kontrol grubuna da 0.1 mL/kg serum fizyolojik oral olarak verilmiştir. Sham grubunda ise sadece laparotomi yapılmıştır. İskemi-reperfüzyon hasarı renal hilusun klemplenmesi yoluyla yapılmıştır. Ticagrelor verilen gruplarda saptanan malondialdehit (MDA) düzeyinin kontrol grubundan daha az olduğu ve bu düşüklüğün istatistiksel olarak anlamlı olduğu tespit edildi (tüm ticagrelor grupları için  $P=0.001$ ). Glutasyonperoksidaz (GPx) ve glutasyonredüktaz (GR) düzeylerinde ticagrelor verilen tüm gruplarda artmış olarak bulundu. Histopatolojik incelemelerde, tedavi verilen tüm gruplarda benzer sonuçlar gözlemlendi. Ancak 5 mg ticagrelor verilen grupta glomerul ve tübül yapısında kontrol grubu arasında fark olmadığı belirlendi. 10 ve 20 mg ticagrelor verilen gruplarda, sham grubuna benzer özellikte dilate tübül yapıları olduğu gözlemlendi. Caspas-3 ve NF-KB aktiviteleri ticagrelor verilen gruplarda sham grubuna benzer özelliklerdeydi. Çalışmamız, ticagrelorun böbreğin iskemi-reperfüzyon hasarına karşı korunmasında etkili bir ajan olduğunu göstermiştir. Ticagrelor, pleiotropik etkisiyle reaktif oksijen türlerinin konsantrasyonunu azaltarak ve antioksidan sistemi aktive ederek dokuları koruyabilir.

**Anahtar sözcükler:** Böbrek, İskemi, Reperfüzyon, Hasar, Ticagrelor

## INTRODUCTION

Partial nephrectomy is a complex procedure performed in the practice of urologic oncology. The most important part of this procedure is cross-clamping of the renal vessels.

This maneuver results in ischemia, while declamping after completing the procedure causes reperfusion. The rapid release of oxygen free radicals and inflammatory mediators-especially polymorphonuclear leukocytes-induce both systemic and local damage with reperfusion<sup>[1,2]</sup>. These



### İletişim (Correspondence)



+90 506 2020066



dr.muratbagcioglu@hotmail.com

products may lead to complications due to systemic inflammatory response such as multiorgan failure and even death [3]. The lungs, heart, and kidneys are distant organs that are especially damaged after ischemia and reperfusion.

Ticagrelor is one of the second group of non-thienopyridine derivatives such as elinogrel and cangrelor. It is a direct-acting antagonist of P2Y<sub>12</sub>, which is a purinergic receptor for adenosine diphosphate (ADP) expressed by platelets. P2Y<sub>12</sub> plays an important role in thrombosis and homeostasis and defects in P2Y<sub>12</sub> result in bleeding due to its role in ADP-induced platelet aggregation [4-6]. Due to these effects, ticagrelor is widely used to prevent stroke and acute coronary syndrome [7].

There is a significant debate that adenosine-related complexes also have extra-platelet effects, i.e., pleiotropic effects. The best explanation is that unlike platelets, P2Y<sub>12</sub> receptors are found in many cells including leukocytes, vascular smooth muscle cells, macrophages, microglial, specific subregions of the brain, and dendritic cells. This increases the number of potential effects of ticagrelor [8-12]. Furthermore, the "pleiotropic effects" of ticagrelor may also occur due to different mechanisms other than interaction with the P2Y<sub>12</sub> receptor [13].

ADP plasma levels increase after injury, inflammation, and ischemia-reperfusion [14]. Ticagrelor inhibits uptake of adenosine into the cell, and subsequent to this, elevated levels of endogenous adenosine decrease levels of inflammatory markers [15,16].

To the best of our knowledge, there is no previous study in the literature about the protective effects of ticagrelor on renal injury. The aim of our study was to determine the protective effect of ticagrelor against ischemia-reperfusion injury in the kidney of rats via histological examination and biochemical parameters.

## **MATERIAL and METHODS**

Our study was approved by the Animal Experiments Local Ethics Committee at Kafkas University (KAÜ-HADYEK 2015-072). Thirty, male Sprague-Dawley rats weighing 350-400 g were randomly divided into five groups. The animals were initially anesthetized with intraperitoneal ketamine HCl 20 mg/kg (Ketalar, Parke-Davis, Detroit, USA), then propofol 80 mg/kg induction, and 3 mg/kg/min propofol infusion was done, and administered ticagrelor (BRILINTA, Astra Zeneca, Södertälje, Sweden) at doses of 5 mg/kg, 10 mg/kg, and 20 mg/kg or 0.1 mL/kg normal saline orally via gastric gavage before the procedure. All groups had laparotomy: a ischemia-reperfusion injury was induced by clamping the renal hilus through a midline incision on the approach to the left kidney. Then, atraumatic vascular clamps were applied to the renal vessels for 2 h. The clamps were removed afterwards for 4 h of reperfusion.

At the end of these procedures, the animals were sacrificed with lethal injection of thiopental (Pentothal Sodium, Fako, Turkey). After sacrifice, the left kidneys of the animals were extracted and washed with 0.9% saline solution before both histopathological and biochemical analysis (malonaldehyde assay (MDA), glutathione reductase (GR) and glutathione peroxidase assays (GPx)).

### **Biochemical Analysis**

Liquid nitrogen was used to freeze kidney tissues, and the tissues were stored at -80°C. Tissue sections were prepared and dried under vacuum overnight at 20°C. Freeze-dried sections were stored at -20°C until biochemical analysis. MDA, GPx, and GR levels were performed with enzyme-linked immunosorbant assays. The levels of these oxidant and antioxidant enzymes in renal tissues were measured using a Biotin double antibody sandwich technology (Bioassay Technology Laboratory, Shanghai, China). The MDA concentrations were expressed as nmol/mL, and the concentrations of GPx and GR were expressed as ng/mL.

### **Histological Analysis**

Histopathological and immunohistochemical examination of kidney tissue samples were completed after being fixed in 10% tamponed formaline for 72 h. Sections were prepared after fixation with bright field microscopic techniques, and a microtome (Leica RM2125RT) was used to obtain 5-micron-thick kidney section. The sections were stained with PAS and Masson triple coating.

The scores for the kidney were measured semi-quantitatively. Parameters including histopathological changes such as tubular dilatation, cast formation, loss of tubular brush border, congestion, cellular degeneration, and atrophic tubules were used for scoring. Evaluation was done at 400X magnification. The parameters were evaluated in five randomly selected areas in each section of the kidney. Five assessments were made for each selected area for each parameter and averaged to obtain scores from 0 to 4. The scoring was (0) normal, (1) mild, (2) moderate, (3) severe, and (4) extremely severe.

### **Immunohistochemical Analysis**

To observe the nephroprotective effects, caspase-3 levels and NF-KB (p65) were analyzed with immunohistochemistry. Immunohistochemical staining for NF-KB and caspase-3 was performed with a VENTANA BenchMark GX System (Ventana Medical Systems, Inc.), which is a Universal DAB Detection Kit with ultraview. The antibody for caspase-3 staining was a rabbit polyclonal caspase-3 primary antibody (ab4051; abcam) used at 1:50 for 32 min at 37°C. The primary antibody for NF-KB staining was a mouse monoclonal NF-KB (p65) (sc-8008; Santa Cruz) used at 1:80 dilution at the same time and temperature. After the slides were incubated with the diluted antibody,

they were exposed to Ventana. DAB was used as the chromogen, and hematoxylin was the counter stain. These sections were photographed with a light photomicroscope (Olympus BX 43) and digital camera (Olympus, DP21) for light microscopy studies. The staining intensity of immunopositive cells was examined in five random high-power fields (200X) per section with cellSens software (Olympus).

Semi-quantitative scoring for NF-KB and caspase-3 activities was made according to several parameters. These were evaluated according to the degree of nuclear and cytoplasmic staining in the proximal, distal, and medulla collecting tubules as well as the glomerule. According to the staining intensity, the sections were graded as follows: 0 (none), 1 (mild), 2 (moderate), 3 (severe), or 4 (extremely severe).

### Statistical Analysis

All data were statistically evaluated using the Mann-Whitney U test. The significance of the differences was accepted as p at the 5% level.

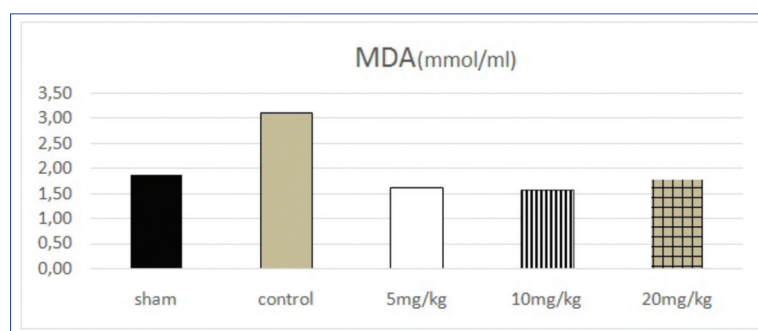
## RESULTS

### Biochemical Results

MDA is a marker of free-radical-mediated lipid peroxidation. There was less lipid peroxidation product in the animals that received ticagrelor than the control group, and this decrease was statistically significant ( $P=0.001$  in all 5 mg/kg, 10 mg/kg, and 20 mg/kg groups). Fig. 1 presents the results for MDA assays in renal tissues. GPx and GR are antioxidant enzymes, and our results showed that both GPx and GR were elevated in all groups that received ticagrelor ( $P=0.000$  in 5 mg/kg, 10 mg/kg, and 20 mg/kg groups). Fig. 2 and Fig. 3 show the GPx and GR assays in renal tissues. MDA, GPx, and GR levels were not significantly different among the animals administered ticagrelor at 5 mg/kg, 10 mg/kg, and 20 mg/kg (Table 1).

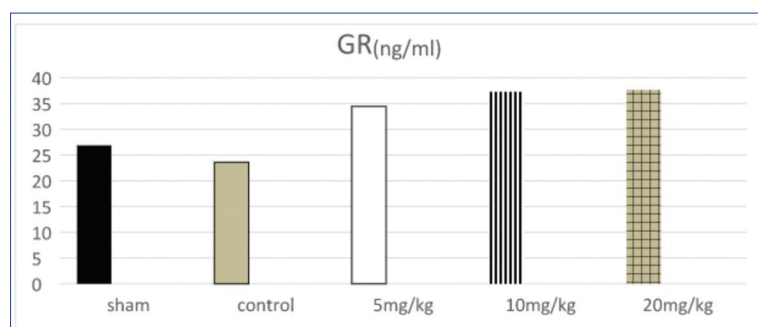
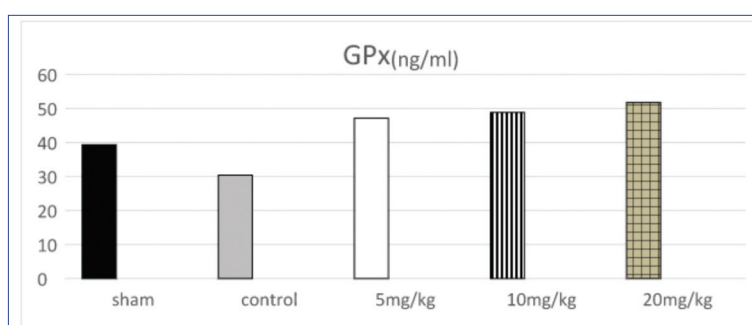
### Histological Results

In the control group, minimal cortical and medullary congestion was observed while no obvious morphological changes were observed (Fig. 4C, Fig. 5C) in the sham group.



**Fig 1.** The effect of ticagrelor pretreatment on MDA levels after renal vessel clamping and renal ischemia reperfusion injury in rats. The animals received 0.9% saline solution (control), ticagrelor 5 mg/kg, 10 mg/kg and 20 mg/kg; sham group represents the manipulated animals

**Fig 2.** GPx. Effect of pretreatment with ticagrelor on renal injury after abdominal aorta ischemia reperfusion injury in rats. The animals received 0.9% saline solution (control), ticagrelor 5 mg/kg, 10 mg/kg, and 20 mg/kg; sham group represents the manipulated animals



**Fig 3.** GR levels. Effect of pretreatment with ticagrelor on renal injury after abdominal aorta ischemia reperfusion injury in rats. The animals received 0.9% saline solution (control), ticagrelor 5 mg/kg, 10 mg/kg, and 20 mg/kg; sham group represents the manipulated animals

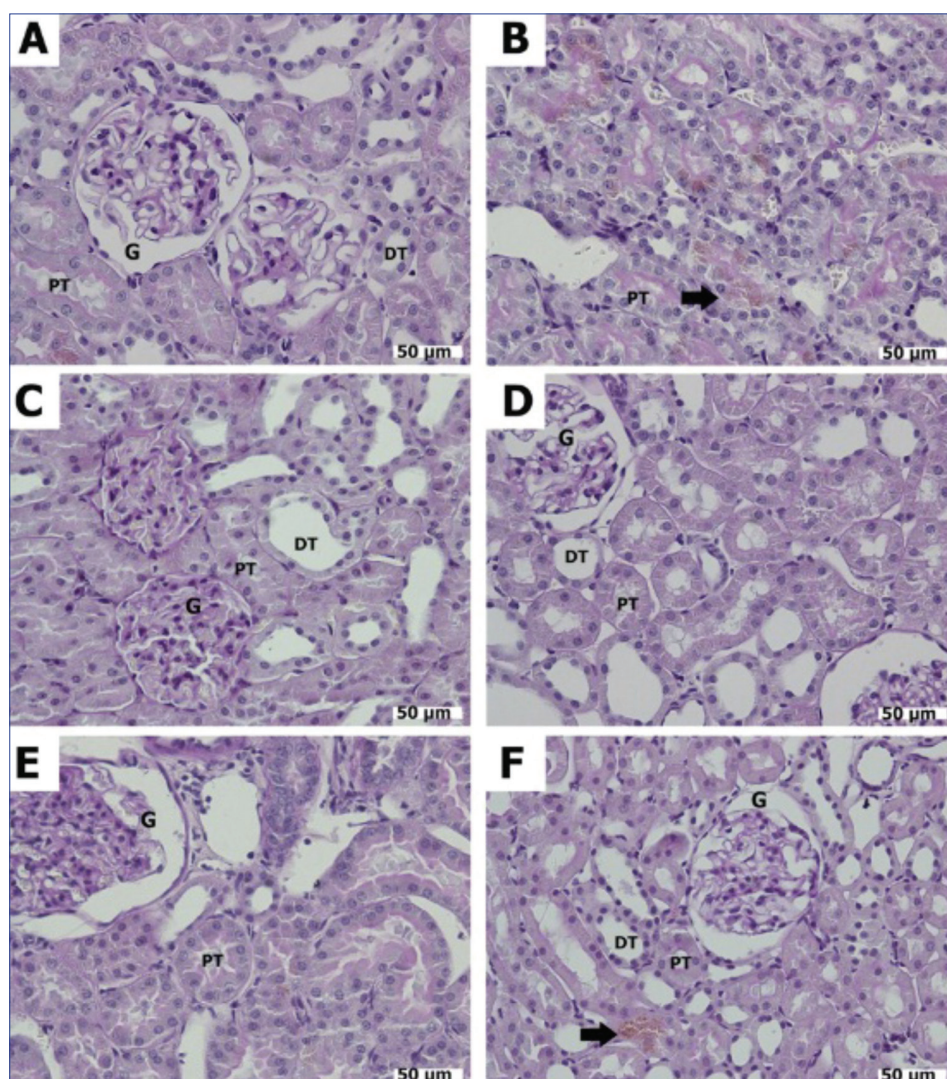
| Parameters    | Ticagrelor Doses |            |            | P  |
|---------------|------------------|------------|------------|--|
|               | 5 mg/kg          | 10 mg/kg   | 20 mg/kg   |  |
| MDA (nmol/mL) | 1.61±0.60        | 1.58±0.41  | 1.74±0.49  | 0.926 <sup>a</sup><br>0.680 <sup>b</sup><br>0.547 <sup>c</sup> |
| GPx (ng/mL)   | 47.16±2.91       | 48.82±2.38 | 51.79±4.84 | 0.306 <sup>a</sup><br>0.073 <sup>b</sup><br>0.208 <sup>c</sup> |
| GR (ng/mL)    | 34.43±2.55       | 37.29±5.08 | 37.65±4.03 | 0.245 <sup>a</sup><br>0.130 <sup>b</sup><br>0.897 <sup>c</sup> |

<sup>a</sup> level of significance between 5 mg/kg dose of ticagrelor and 10 mg/kg dose,  
<sup>b</sup> level of significance between 5 mg/kg dose of ticagrelor and 20 mg/kg dose,  
<sup>c</sup> level of significance between 10 mg/kg dose of ticagrelor and 20 mg/kg dose

groups, although the 5 mg ticagrelor treated group (Fig. 4D, Fig. 5D) showed no changes in glomerules and/or tubules compared to the control group. Dilated tubular structures were similar to the sham group and were noted in both 10 and 20 mg ticagrelor treatment groups (Fig. 4, Fig. 5)

### Immunohistochemical Results

When caspase-3 activity was examined in the control group's renal cortex, the proximal and distal tubule cells had a nuclear immune reaction. The caspase-3 activity was more intense in the nucleus of proximal tubule cells; it was moderate in the distal tubules. The cytoplasm of the proximal tubule cells had a mild immune reaction; there was no immune reaction in the distal tubules.



**Fig 4.** The histological appearance of renal tissue obtained from subjects belonging to the experimental group. While the view of kidney sections of group C was normal, the sham (A-B) group had areas with hemosiderin (black arrows) in kidney sections. In other treatment groups (D: 5 mg ticagrelor, E: 10 mg ticagrelor, F: 20 mg ticagrelor) dilations in the Bowman capsule were observed (Dye: PAS; Mag: 40X, A-B: Sham Group, C: Control Group, D: 5 mg Group, E: 10 mg Group, and F: 20 mg Group; G: Glomerules, DT: Distal Tubule, PT: Proximal Tubule, black arrow: hemosiderin area)

In the sham group, we observed a higher filtration range (Fig. 4, Fig. 5B). Both glomerular capillaries and Bowman ranges showed significant dilatation. Cast formation (Fig. 5B) was most intense in this group. Based on these evaluation criteria, some effects were found and shown in Table 2. Similar findings were observed in all treatment

Collector tubules in the medulla were slightly positive. Glomerular, vascular smooth muscle, and transitional epithelium showed no immune reactions. The immune activity was more intense-especially in neighboring regions of the cortex through the medulla (Fig. 6A). In general, other groups have similar findings as the control group,

and we indicate the differences between the groups as follows (Table 3).

In the sham group, the medullar area with collecting

**Table 2.** Histopathological scores of groups ((0) normal, (1) mild, (2) moderate, (3) severe, (4) extremely severe)

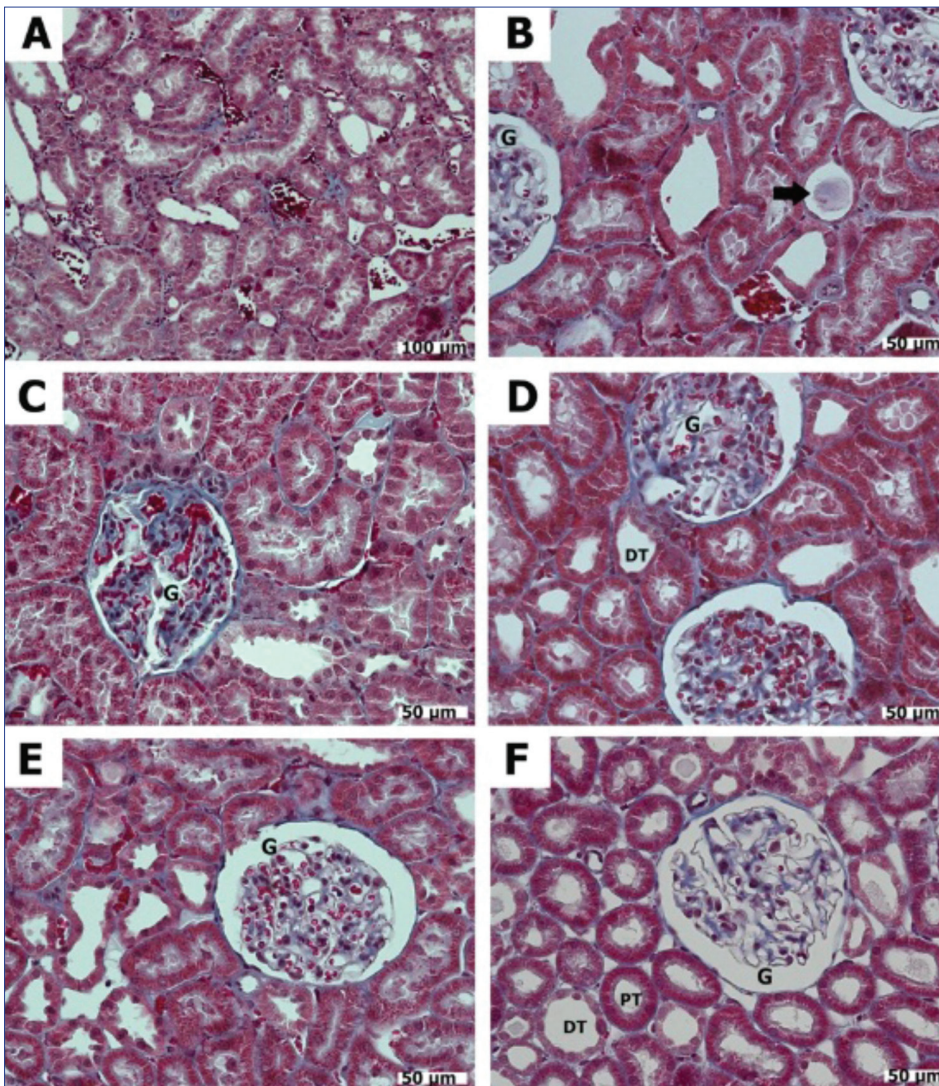
| PAS & Triple                 | Control Group | Sham Group | 5 mg Ticagrelor | 10 mg Ticagrelor | 20 mg Ticagrelor |
|------------------------------|---------------|------------|-----------------|------------------|------------------|
| Loss of tubular brush border | 1             | 2          | 1               | 2                | 2                |
| Tubular dilatation           | 1             | 2          | 2               | 2                | 2                |
| Cellular degeneration        | 1             | 2          | 1               | 1                | 2                |
| Congestion                   | 0             | 1          | 1               | 1                | 1                |
| Cast formation               | 0             | 3          | 1               | 1                | 1                |
| Atrophic tubules             | 0             | 1          | 0               | 1                | 1                |
| Total score                  | 3             | 11         | 6               | 7                | 9                |

tubules was slightly positive. The 5, 10, and 20 mg groups were similar to the sham group (Fig. 6). The NF-KB activity in the renal cortex was observed differently in the renal cortex, proximal, and distal tubules. The proximal tubule had a granular appearance, and there was a severe cytoplasmic view. Distal tubule immunostaining observed homogeneity and mild intensity in the cytoplasm.

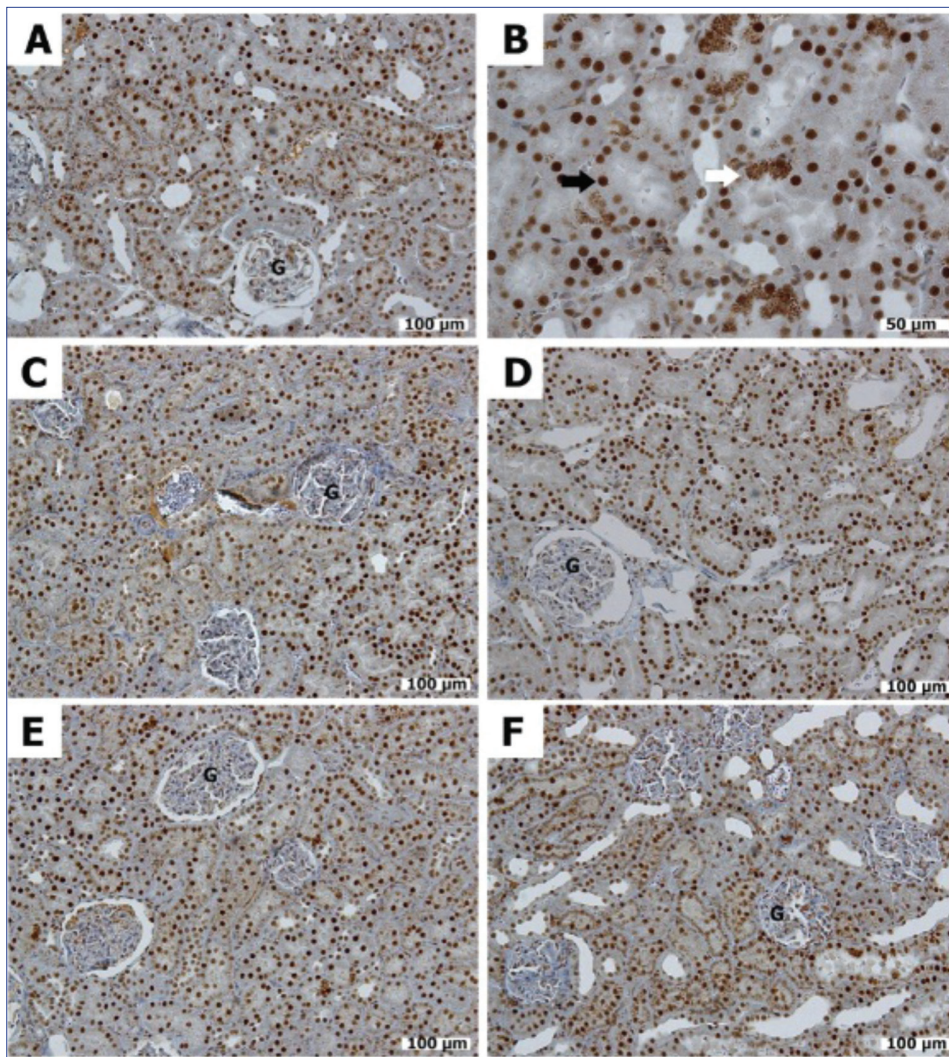
Collector tubules in the medulla area were slightly positive (Fig. 7C). The sham group and control groups had a positive immune response (Fig. 7A,B). Some distal tubules had obvious cytoplasmic NF-KB activity. In the 5 mg group, while NF-KB activity was observed in the glomeruli, some DT cytoplasmic NF-KB activity was also seen. The 5, 10 and 20 mg groups were similar to the sham group (Fig. 7); immunohistochemical values are given as intensity scores (Table 3).

## DISCUSSION

Free oxygen radicals and reactive oxygen species cause ischemia-reperfusion injury and the effects on many tissues



**Fig 5.** The histological appearance of renal tissue obtained from subjects belonging to the experimental group. Dilatations were observed in the filtration range of kidney sections, additionally cast formations were observed (black arrow) in the sham group (A-B). While control group (C) had normal appearance, 5 mg (D), 10 mg (E) and 20 mg (F) ticagrelor treatment groups had ischemic results such as loss of tubulin in the microvilli brushes, and dilated tubules observed (Dye: TRIPLE; A-B: Sham Group, C: Control Group, D: 5 mg Group, E: 10 mg Group, and F: 20 mg Group, G: Glomerules, DT: Distal Tubule, PT: Proximal Tubule, black arrow: cast formation)



**Fig 6.** View of caspase-3 immune activity in kidneys. In all groups, the tubules' nuclear caspase activity is seen with different concentrations (*black arrow*);sham (*white arrow*) and 25 mg group intensive cyto-plasmic reactions (*white arrow*) were also observed (Dye: Caspase-3; A-B: Sham Group, C: Control Group, D: 5 mg Group, E: 10 mg Group, and F: 20 mg Group, *black arrow*: nuclear Caspase-3 activity, *white arrow*: cytoplasmic Caspase-3 activity, G: Glomerules)

**Table 3.** Results of Caspase-3 and NF-KB activation ((0) normal, (1) mild, (2) moderate, (3) severe, (4) extremely severe)

| Caspase-3 Staining | Control Group | Sham Group | 5 mg Ticagrelor | 10 mg Ticagrelor | 20 mg Ticagrelor |
|--------------------|---------------|------------|-----------------|------------------|------------------|
| Proximal tubules   | 4             | 3          | 4               | 4                | 3                |
| Distal tubules     | 1             | 1          | 1               | 1                | 1                |
| Glomerule          | 0             | 1          | 0               | 0                | 1                |
| Medulla            | 1             | 2          | 1               | 1                | 2                |
| Total score        | 6             | 7          | 6               | 6                | 7                |
| NF-KB              |               |            |                 |                  |                  |
| Proximal tubules   | 2             | 1          | 1               | 1                | 0                |
| Distal tubules     | 1             | 2          | 1               | 1                | 2                |
| Glomerule          | 1             | 3          | 2               | 3                | 3                |
| Medulla            | 2             | 2          | 2               | 2                | 2                |
| Total score        | 6             | 8          | 6               | 7                | 7                |

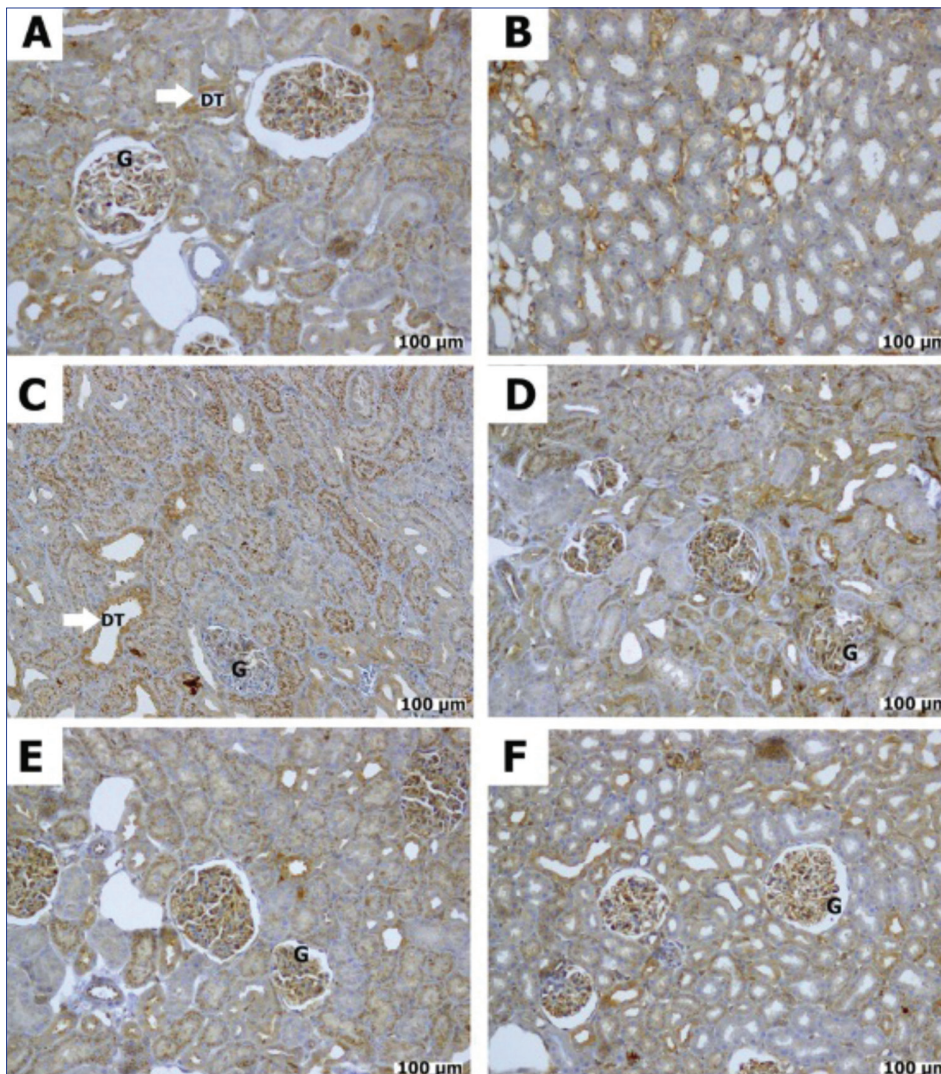
are well-known [17,18]. These effects include changes in the level of ATP depletion, oxidative phosphorylation, increases in the level of intracellular calcium, and protein

kinase activation. The release of nucleases, lipase proteases, and phosphatases can damage the cell's integrity and function [19].

Reperfusion of ischemic tissue can stimulate the production of reactive oxygen species [20], which can lead to pre-oxidation of cellular structures and components such as nucleic acids, proteins, and lipids [21]. Kidney ischemia-reperfusion injury -together with a reduction in antioxidant defense- is associated with oxidative stress in the kidney [22-24].

Nitric oxide synthase inhibitors, statins, betacarotene, erythropoietin, ascorbic acid, phenolic acid, antioxidants, and antioxidant enzyme mimetics have all been shown to have potential positive effects that protect renal function and reduce kidney ischemia-reperfusion injury [23-26].

The use of ticagrelor increases adenosine levels. Adenosine accumulation during ischemia and inflammation protects tissue from damage. In ischemic tissue, adenosine accumulates because of inhibited adenosine kinase. In inflamed tissue, adenosine consists of adenine nucleotides that are delivered from numerous cells including mast



**Fig 7.** Kidney tissue NF-KB immune activity. No immune glomerular activity was seen in the control (c) group, otherwise severe NF-KB activity was observed in the sham (A-B) and other treatment groups (D-F) (Dye: NF-KB; A-B: Sham Group, C: Control Group, D: 5 mg Group, E: 10 mg Group, and F: 20 mg Group, Mag: 20x, white arrow: cytoplasmic Caspase-3 activity, G: Glomerule, DT: Distal Tubule)

cells, endothelium, and platelets. This is only one of the pleiotropic effects of this drug. Thus, it is better to indicate the pleiotropic effects of ticagrelor [27].

The P2Y<sub>12</sub> receptor antagonists exhibit a wide range of actions beyond their primary anti-aggregation functions that is the primary indication [28]. They modulate inflammation, improve endothelial function, and prevent vasoconstriction while offering adenosine-like and post-conditioning-like effects. This offers an extra gain benefit for patients treated with the P2Y<sub>12</sub> blocker ticagrelor. This motivated us to use ticagrelor to prevent or reverse ischemia-reperfusion kidney damage. To the best of our knowledge, this is the first study to evaluate ticagrelor in kidney injury. Thus, we can not compare it to other studies. There are many well-known studies of other drugs and their effects on ischemia-reperfusion injuries.

In our study, the animals that received ticagrelor had significantly less MDA than the control group. The antioxidant enzymes of both GPx and GR were elevated in groups administered ticagrelor at all doses ( $P=0.000$  in 5 mg/kg, 10 mg/kg and 20 mg/kg groups). This shows that

ticagrelor protects kidney tissue from ischemia-reperfusion injury and oxidative stress. MDA, GPx, and GR levels were not significantly different between the ticagrelor animals at 3 different doses. In our study, the protective effect of ticagrelor was independent of the doses in terms of biochemistry.

The histopathological findings have a limited similarity with the degree of lipid peroxidation and biochemical results. Tubular dilatation, which was observed in the ticagrelor treatment groups, may stem from precipitated proteins that obstruct tubules and raise the intratubular pressure. This is consistent with the results from animal models that showed increased intratubular pressure in ischemic injury [29]. Histopathological findings also confirmed the protective action of ticagrelor, but this was dose-dependent. In the ticagrelor group, the damage was less severe than in the control group. The immunohistochemical results also showed the nephroprotective effect of this drug. Ticagrelor may protect renal tissue with its pleiotropic effect or through some other mechanism. Accordingly, our biochemical findings showed that the administration of

ticagrelor protects kidneys from ischemia-reperfusion injuries.

Our study showed that ticagrelor is an effective agent to protect kidneys from renal ischemia-reperfusion injury. Ticagrelor may protect the tissues by reducing the concentration of reactive oxygen species and inducing the antioxidant system especially with its pleiotropic effects. However, further studies are needed to understand the possible mechanisms by which ticagrelor can prevent kidney ischemia-reperfusion injury.

## ACKNOWLEDGEMENT

We are grateful to Ismail Can, Assistant Professor of Histology and Embryology at Kafkas University Faculty of Medicine, for assistance with histological and immunohistochemical analyses.

## REFERENCES

- Klausner JM, Paterson IS, Valeri R, Hechtman HB:** Limb ischemia induced increase in permeability is mediated by leukocytes and leukotrienes. *Ann Surg*, 208, 755-760, 1988.
- Klausner JM, Paterson IS, Kozbik L, Valeri R, Shepro D, Hetchman HB:** Oxygen free radicals mediate ischemia-induced lung injury. *Surgery*, 105, 192-199, 1989.
- Gyurkovics E, Aranyi P, Stagnol R, Onody P, Ferreira G, Lotz G, Kupcsulik P, Szijarto A:** Postconditioning of the lower limb protection against reperfusion syndrome. *J Surg Res*, 169, 139-147, 2011. DOI: 10.1016/j.jss.2009.10.014
- Carvalho AC, Guillaumon AT, Cintra Ede A, Figueiredo LC, Moreira MM, Araújo S:** Plasmatic vasopressin in patients undergoing conventional infra-renal abdominal aorta aneurysm repair. *Rev Bras Cir Cardiovasc*, 26, 404-412, 2011. DOI: 10.5935/1678-9741.20110015
- Cattaneo M, Schulz R, Nylander S:** Adenosine-mediated effects of ticagrelor. *J Am Coll Cardiol*, 63, 2503-2509, 2014. DOI: 10.1016/j.jacc.2014.03.031
- Cattaneo M:** The platelet P2Y12 receptor for adenosine diphosphate: Congenital and drug-induced defects. *Blood*, 117, 2102-2112, 2011. DOI: 10.1182/blood-2010-08-263111
- Wallentin L, Becker RC, Budaj A, Cannon CP, Emanuelsson H, Held C, Horrow J, Husted S, James S, Katus H, Mahaffey KW, Scirica BM, Skene A, Steg PG, Storey RF, Harrington RA, PLATO Investigators, Freij A, Thorsén M:** Ticagrelor versus clopidogrel in patients with acute coronary syndromes. *N Engl J Med*, 361, 1045-1057, 2009. DOI: 10.1056/NEJMoa0904327
- Diehl P, Olivier C, Halscheid C, Helbing T, Bode C, Moser M:** Clopidogrel affects leukocyte dependent platelet aggregation by P2Y12 expressing leukocytes. *Basic Res Cardiol*, 105, 379-387, 2010. DOI: 10.1007/s00395-009-0073-8
- Högberg C, Svensson H, Gustafsson R, Eyjolfsson A, Erlinge D:** The reversible oral P2Y12 antagonist AZD6140 inhibits ADP-induced contractions in murine and human vasculature. *Int J Cardiol*, 142, 187-192, 2010. DOI: 10.1016/j.ijcard.2008.12.091
- Kronlage M, Song J, Sorokin L, Isfort K, Schwerdtle T, Leipziger J, Robaye B, Conley PB, Kim HC, Sargin S, Schön P, Schwab A, Hanley PJ:** Autocrine purinergic receptor signalling is essential for macrophage chemotaxis. *Sci Signal*, 3, ra55, 2010. DOI: 10.1126/scisignal.2000588
- Haynes SE, Hollopeter G, Yang G, Kurpius D, Dailey ME, Gan WB, Julius D:** The P2Y12 receptor regulates microglial activation by extracellular nucleotides. *Nat Neurosci*, 9, 1512-1519, 2006. DOI: 10.1038/nn1805
- Ben Addi A, Cammarata D, Conley PB, Boeynaems JM, Robaye B:** Role of the P2Y12 receptor in the modulation of murine dendritic cell function by ADP. *J Immunol*, 185, 5900-5906, 2010. DOI: 10.4049/jimmunol.0901799
- Gachet C:** P2Y12 receptors in platelets and other hematopoietic and non-hematopoietic cells. *Purinergic Signal*, 8, 609-619, 2012. DOI: 10.1007/s11302-012-9303-x
- Csóka B, Németh ZH, Rosenberger P, Eltzhig HK, Spolarics Z, Pacher P, Selmeczy Z, Kosco B, Himer L, Vizi ES, Blackburn MR, Deitch EA, Hasko G:** A2B adenosine receptors protect against sepsis-induced mortality by dampening excessive inflammation. *J Immunol*, 185, 542-550, 2010. DOI: 10.4049/jimmunol.0901295
- Armstrong A, Summers C, Ewart L, Nylander S, Sidaway JE, van Giezen JJ:** Characterization of the adenosine pharmacology of ticagrelor reveals therapeutically relevant inhibition of equilibrative nucleoside transporter 1. *J Cardiovasc Pharmacol Ther*, 19, 209-219, 2014. DOI: 10.1177/1074248413511693
- Van Giezen JJ, Sidaway J, Glaves P, Kirk I, Björkman JA:** Ticagrelor inhibits adenosine uptake *in vitro* and enhances adenosine-mediated hyperemia responses in a canine model. *J Cardiovasc Pharmacol Ther*, 17, 164-172, 2012. DOI: 10.1177/1074248411410883
- Chander V, Chopra K:** Renal protective effect of molsidomine and L-arginine in ischemia-reperfusion induced injury in rats. *J Surg Res*, 128, 132-139, 2005. DOI: 10.1016/j.jss.2005.04.023
- Sekhona CS, Sekhon BK, Singh I, Orak JK, Singh AK:** Attenuation of renal ischemia/reperfusion injury by a triple drug combination therapy. *J Nephrol*, 16, 63-74, 2003.
- Bulkley GB:** Free radical-mediated reperfusion injury: A selective review. *Br J Cancer Suppl*, 8, 66-73, 1987.
- Karaman A, Turkmen E, Gursul C, Tas E, Fadillioglu E:** Prevention of renal ischemia/reperfusion-induced injury in rats by leflunomide. *Int J Urol*, 13, 1434-1441, 2006. DOI: 10.1111/j.1442-2042.2006.01592.x
- Tugtepe H, Sener G, Biyikli NK, Yuksel M, Cetinel S, Gedik N, Yegen BC:** The protective effect of oxytocin on renal ischemia/reperfusion injury in rats. *Regul Pept*, 140, 101-108, 2007. DOI: 10.1016/j.regpep.2006.11.026
- Sener G, Sehirlil O, Velioğlu-Ogunc A, Cetinel S, Gedik N, Caner M, Sakarcan A, Yegen BC:** Montelukast protects against renal ischemia/reperfusion injury in rats. *Pharmacol Res*, 54, 65-71, 2006. DOI: 10.1016/j.phrs.2006.02.007
- Hosseini F, Naseri MK, Badavi M, Ghaffari MA, Shahbazian H, Rashidi I:** Effect of beta carotene on lipid peroxidation and antioxidant status following renal ischemia/reperfusion injury in rat. *Scand J Clin Lab Invest*, 70, 259-263, 2010. DOI: 10.3109/00365511003777810
- Chatterjee PK:** Novel pharmacological approaches to the treatment of renal ischemia-reperfusion injury: A comprehensive review. *Naunyn Schmiedeberg's Arch Pharmacol*, 376, 1-43, 2007. DOI: 10.1007/s00210-007-0183-5
- Korkmaz A, Kolankaya D:** The protective effects of ascorbic acid against renal ischemia-reperfusion injury in male rats. *Ren Fail*, 31, 36-43, 2009. DOI: 10.1080/08860220802546271
- Bozkurt Y, Fırat U, Atar M, Sancaktutar AA, Pembegül N, Soylemez H, Yuksel H, Alp H, Bodakçı MN, Hatipoğlu NK, Buyukbas S:** The protective effect of ellagic acid against renal ischemia-reperfusion injury in male rats. *Kafkas Univ Vet Fak Derg*, 18 (5): 823-828, 2012. DOI: 10.9775/kvfd.2012.6517
- Linden J:** Molecular approach to adenosine receptors: Receptor-mediated mechanisms of tissue protection. *Annu Rev Pharmacol Toxicol*, 41, 775-87, 2001. DOI: 10.1146/annurev.pharmtox.41.1.775
- Adamski P, Kozinski M, Ostrowska M, Fabiszak T, Navarese EP, Paciorek P, Grzesk G, Kubica J:** Overview of pleiotropic effects of platelet P2Y12 receptor inhibitors. *TrombHaemost*, 112 (2): 224-242, 2014. DOI: 10.1160/TH13-11-0915
- Porter KA:** The kidney. In: Summers WC (Ed): Systemic Pathology. Vol 8, 3<sup>rd</sup> edn., 491-498, Churchill-Livingstone, London, 1992.