

## The Effect of Low Level Green LASER on Autologous Full-Thickness Free Skin Graft in Rats

Hamidreza FATTAHIAN<sup>1</sup>  Soudeh ANSARI<sup>1</sup> Pejman MORTAZAVI<sup>2</sup>

<sup>1</sup> Department of Clinical Science, Faculty of Specialized Veterinary Science, Science and Research Branch, Islamic Azad University, Tehran - IRAN

<sup>2</sup> Department of Pathobiology, Faculty of Specialized Veterinary Science, Science and Research Branch, Islamic Azad University, Tehran - IRAN

KVFD-2015-13976 Received: 03.07.2015 Accepted: 16.09.2015 Published Online: 29.09.2015

### Abstract

The effect of green LED laser on free full-thickness autologous skin graft was tested in rats. Ten adult male Wistar rats were divided into two groups of in each group as test (Low level green LED laser irradiation) and the control group. A full-thickness square incision with the sides of three centimeters was created at the dorsal region of animals. Then, the skin was removed and replaced with a rotation of 90 degrees and sutured. Green LED irradiation (1 J/cm<sup>2</sup>, 60 s, and 532 nm) was performed immediately in the test group daily over a period of 6 days post-operatively. Biopsy taking was recorded on determined days. The results showed that the laser with the amount of has ability to maintain tissue autograft in the surgical site. Macroscopic and microscopic studies showed that the graft tissue in the control group showed significantly (P>0.05) shrinkage and fibrosis.

**Keywords:** Autologous, Full-thickness graft, Low level green LED LASER, Rat, Skin

## Sıçanlarda Tam-Katmanlı Otolog Serbest Deri Greftine Düşük Seviye Yeşil LAZER'in Etkisi

### Özet

Tam katmanlı otolog deri grefti üzerine yeşil LED lazerin etkisi sıçanlarda test edildi. On adet yetişkin erkek Wistar sıçan düşük seviye yeşil LED lazer radyasyon grubu ve kontrol grubu olmak üzere iki gruba ayrıldı. Tüm kalınlıkta kenarları 3 cm olan bir kare insizyon hayvanların dorsal kısmında oluşturuldu. Sonrasında, deri uzaklaştırıldı ve 90 derece döndürülerek yerine tekrar dikildi. Yeşil LED radyasyonu (1 J/cm<sup>2</sup>, 60 s, ve 532 nm) operasyon sonrası 6 gün boyunca her gün test grubuna uygulandı. Biyopsiler cerrahi işlemin 3, 5, 7 ve 14. günlerde alınarak patoloji laboratuvarına gönderildi. Greftin boyutu aynı günlerde kaydedildi. Sonuçlar lazerin cerrahi müdahale bölgesinde doku otogreftini sağladığını gösterdi. Makroskopik ve mikroskopik çalışmalar kontrol grubunda greft dokusunun anlamlı derecede (P>0.05) çekme ve fibroze uğradığını ortaya koydu.

**Anahtar sözcükler:** Otolog, Tüm kalınlıklı greft, Düşük doz yeşil LED LAZER, Sıçan, Deri

### INTRODUCTION

Skin is the largest apparatus that its function is protection body from mechanical damage and chemical exposure. This organ experiences most damage such as loss of and regeneration throughout its life. Surgical treatment and plastic surgery has been used to resolve the defect and restoration its function and is the choice treatment. Besides acceptable results of each method, they are not free of complication. For many decades, researchers had various trail to achieve good results in resolving severe

and large skin injury. As previously mentioned, the use of skin flap and free graft have a positive role in acceptable appearance. The two common main postoperatively complications are ischemia and necrosis for reason such unsuitable bed and incorrect preparation of graft<sup>[1,2]</sup>. Seroma formation (SF) and shrinkage of transplant tissue are the major surgical complications specifically on non-fresh recipient bed<sup>[1-4]</sup>. One of ways to bypass these likely post-operatively complications is trying to prepared meshed full-thickness and partial thickness skin grafts and placed on the bed with the aim of removing the negative role of



#### İletişim (Correspondence)



+98 212 2357598, Cell phone: +98 912 2194580, Fax: +98 212 2357597



hamidrezafattahian@yahoo.com

SF between bed and grafts and help adhere graft on bed. More attempts in solving SF are stab incision in the center of skin graft. The scar has the lack acceptable appearance [1]. Another problem in the use of full-thickness skin graft is shrinkage and size reduction in the wound healing process which is highly inappropriate and unacceptable effect on aesthetic plastic surgery [2].

Positive role of laser with wavelengths lower than 800 nm on wound healing and acceleration of repair phase in animal model has been claimed by many investigators, but the effect of laser on autologous skin graft has not been studied so far. The stimulation of wound healing, anti-inflammatory and activation of vasodilation effects of low level laser known well in recent years [5]. Researcher of the present study profit by laser properties to investigate the role of green LED light laser radiation on autologous-graft in rat.

## MATERIAL and METHODS

The study was approved by the Ethics Committee on Animal Research of the number of Ethics IAEC 3-12/5.

Ten male Wistar rats with the average weighting  $430 \pm 25$  g in the same life-style conditions of temperature, humidity, water and food were randomly divided into two groups of five animals tested (green LED laser) and control (no green LED laser radiation) and placed in separate cages. Rats were anesthetized by a combination of ketamine hydrochloride (75 mg/kg) (Alfasan, Woerden-Holland) and Medetomidine hydrochloride (10 mg/kg) (Syva, Avda-Spain) intraperitoneally. After clipping, surgical scrub and preparation of the surgical area, the rats were laid on sternal recumbency. After drawing a square with the sides of 3 cm by using sterile pen and ruler, the full-thickness incision was created using a sterile scalpel # 11 (Fig. 1).

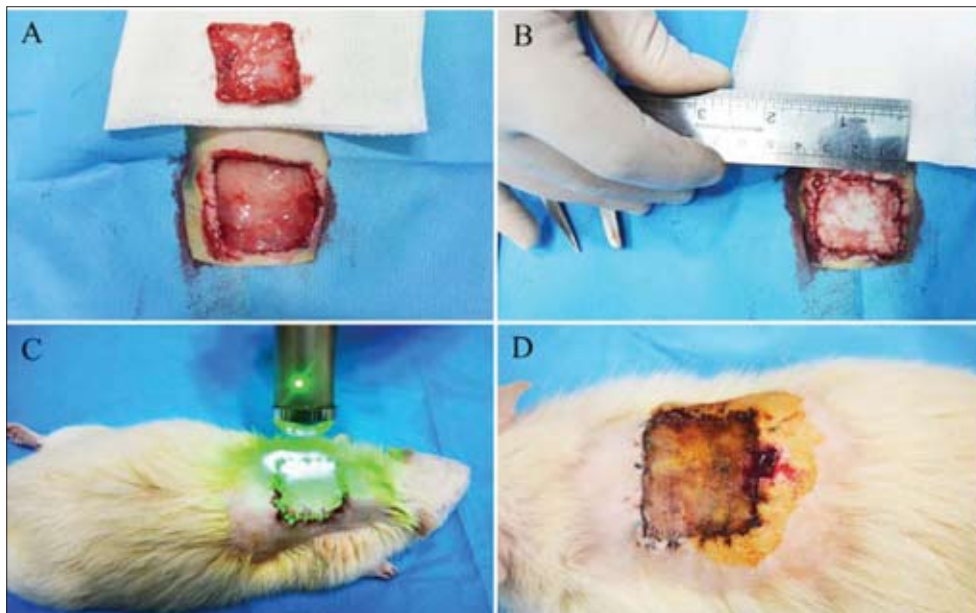
The skin was separated from the bed by dissecting with Metzenbaum scissor and it was placed on the 90-degree rotation. It was sutured by simple suture pattern with nylon number 4-0 (Fig. 1). All animals received a daily dose of Enrofloxacin (5 mg/kg, SC)(Hipra, Avda-Spain) as an antibiotic and Meloxicam (2 mg/kg, SC)(Razak, Karaj-Iran) as an analgesic subcutaneously for 3 days, postoperatively.

In the test group, green LED light (1 J/cm<sup>2</sup>, 60 s, and 532 nm) Mustang 2000 (Russia) laser radiation was considered immediately post-operatively daily over a period of 6 days. Radiation pattern was circular from the edges of the autologous skin into the center (Fig. 1). In control group, animals received no radiation. Under anesthetic and aseptic condition, biopsy samples taken from the center of each side of the transplanted tissue as a 0.4' 0.8 cm rectangle shape on the days 3, 5, 7 and 14 after surgery in both control and experimental groups (Fig. 1). The samples were fixed in 10% buffered formalin and prepared for microscopic evaluation. All four sides of the square were measured by ruler on days 3, 5, 7 and 14 and recorded in the respective tables to compare the macroscopic changes between two groups. At the end of the study, none of the rats were euthanized.

### Statistical Analysis

*Macroscopical study of graft:* The statistical results of macroscopic changes according to the normal distribution and homogeneity of variance data was evaluated by non-parametric Mann-whitney U test with SPSS software version 22. The statistical analysis was performed between two groups in 5% significance level.

*Histopathological study of graft:* The statistical results of histopathology were performed with non-parametric Mann-whitney U test to comparison between groups using SPSS version 22.



**Fig 1.** A- The full-thickness incision and removed skin; B- Skin suturing; C- Laser radiation; D- Sample biopsy

**Şekil 1.** A- Tüm katmanlı insizyon ve uzaklaştırılmış deri; B- Deri dikişi; C- Lazer radyasyonu; D- Örnek biyopsi

## RESULTS

### Macroscopical Results of Transplantation

Based on clinical and macroscopic evaluations, SF was not observed at the distance between the bed and graft. Transplantation area was calculated in the day of 3, 5, 7 and 14 in all rats in two groups. The difference of transplant sizes of day (3 and 5), (3 and 7), (3, 14) and (5 and 7) were analyzed. So that the difference in days of (3, 14), and (5, 7) after transplantation was significant between the groups ( $P=0.05$ ). But the transplant level between days (3, 5) and (3, 7) did not show significant difference ( $P>0.05$ ).

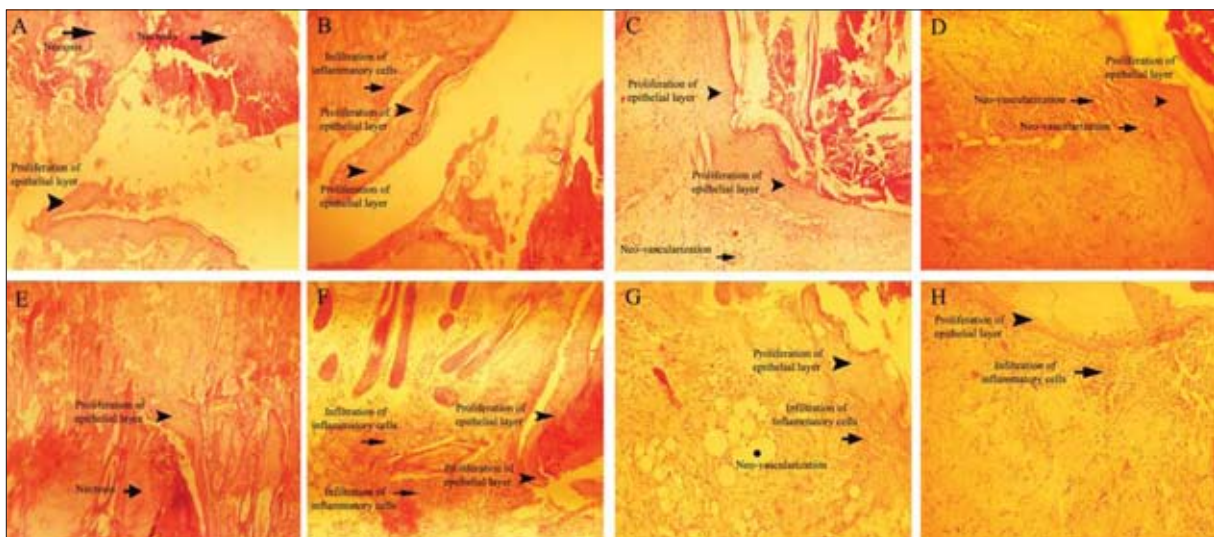
### Histopathological Results of Transplantation

According to the reference table [6] and our pathological study, the amount of migration and thickness of keratinized layer at days 3 and 5 in the control group and at day 3 in test group were observed less than 50%. However, the migration of the tissue at days 5, 7 and 14 increased in the comparison with the control group but there was no statistically significant difference in the analysis ( $P>0.05$ ). Infiltration of inflammatory cells on days 3 and 5 were reported average (between 50 and 75%) but at the end of the study on day 7 and 14 reduced to 25%. The rate of infiltration substantially on days 5, 7 and 14 had increased (more than 75%). Fibroblast was observed mild (surrounding tissue) on day 3, and in the granulation tissue on days 5 and 7 which increased in the control group on day 14. The presence of fibroblasts in granulation tissue was the same in the test group as compared to the control group on day 3. Despite of increasing of fibroblast on days 5, 7 and 14, the difference was not significant between

two groups ( $P>0.05$ ). Vascular regeneration increased on days 5, 7 and 14 in the test group and only on day 14 in the control group and was not significant ( $P>0.05$ ). The amount of collagen maturation increased in the test group to control group on day 14, although the difference was not significant (Fig. 2). Statistical analysis of pathological finding revealed that green LED lasers on fibroblast migration ( $P=0.06$ ) and keratinized layer ( $P=0.07$ ) not significant in the comparison to the control group, although it was very close to the significance level (Fig. 3).

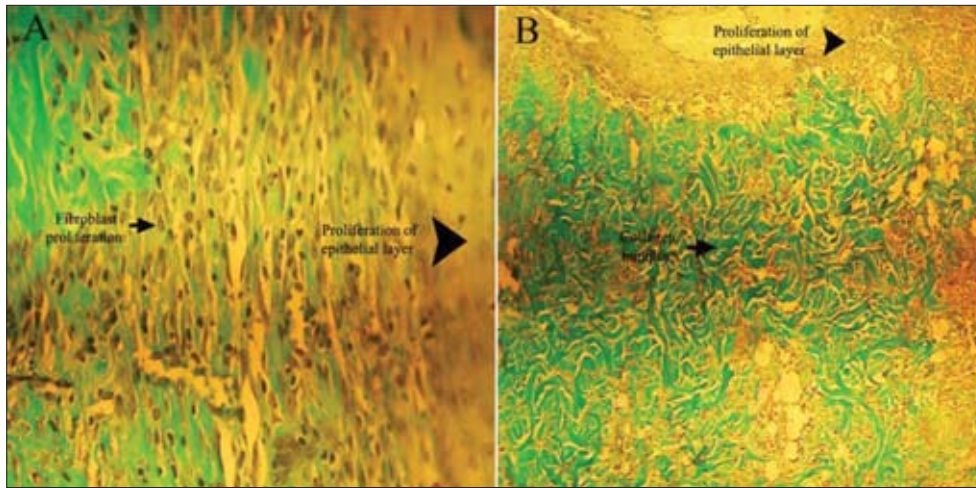
## DISCUSSION

The healing process of large defect is very problematic and clinicians and researchers have paid attention to manage of this old and powerful competitor in plastic surgery field. This defect threatens people and animals life and mortality rate is high in who suffer from the defect. Hence, for many years from past to now, the majority of researches have concentrated in solving and bypassing the problem in their investigations. In this way, using of full-thickness autografts are as one of the most practical and choice method of treatment of these lesions that accelerates healing of lesions and makes appropriate and acceptable appearance. Some factors such as SF affected on tissue adhesion and graft separation is predictable [1]. Surgeons used some methods like stab incision in the center of transplantation to diminish such post-operation complication of free skin graft. Formation of seroma is not only problem in the use of full-thickness and partial thickness skin graft, fibrosis and shrinkage of skin on its bed are other skin problems in literature [1]. So, seeking the ancillary method to optimize the result is important.



**Fig 2.** H&E staining of control group and test group. Representative histology from biopsy in days 3, 5, 7 and 14 after surgery. A- Day 3, control group, B- Day 5, control group, C- Day 7, control group, D- Day 14, control group, E- Day 3, test group, F- Day 5, test group, G- Day 7, test group, H- Day 14, test group (A-H  $\times 10$ )

**Şekil 2.** Kontrol ve test gruplarında H&E boyanması. Cerrahi sonrası 3, 5, 7 ve 14. günlerde biyopsi örneklerinin histolojik görüntüsü. A- 3. gün, kontrol grubu, B- 5. gün, kontrol grubu, C- 7. gün, kontrol grubu, D-14. gün, kontrol grubu, E- 3. gün, test grubu, F- 5. gün, test grubu, G- 7. gün, test grubu, H- 14. gün, test grubu (A-H  $\times 10$ )



**Fig 3.** Trichrome staining of control group and test group. Representative histology from biopsy in day 14 after surgery. A- Day 14, control group, B- Day 14, test group (A, B  $\times 10$ )

**Şekil 3.** Kontrol ve test gruplarında Trikróm boyanması. Cerrahi sonrası 14. günde biyopsilerin histolojik görüntüsü. A- 14. gün, kontrol grubu, B- 14. gün, test grubu (A, B  $\times 10$ )

As noted earlier, laser it was used in the present study to preserve, survive and taking free skin autograft in its bed with the aim of finding a way in using full-thickness skin graft with green LED laser treatment. Tissue contamination and infection are two causes of SF and separate graft from its bed. Absence of SF between the bed and transplant tissue in present study in both control and test groups, skin graft was taken to the bed. In many patients of medical and veterinary hospital especially in burns, bed discharge and contamination following the necrotic tissue are as a barrier in connection of graft to bed [1,2]. In laser studies and its properties on wound healing, both factors including wave length and density are important role. The changes of these factors will have different results in prescribed time of laser. Shrinkage of wound with presence of granulation tissue and fibrosis has two edges condition of wound and scar tissue formation [1,2]. Many studies have focused on the role of laser on the fate of the transplanted skin. Machneva et al.[7] were reported 33% reduction in the size of the wound and preservation of transplant tissue with low level green LED laser in comparison with 39% reduction with low level red laser [7]. The authors of present study showed the role of green LED laser in prevention of wound size reduction and maintaining size of graft was significant which agrees with research of Machneva et al.[7] result. That also found that increasing the density twice of their previous study caused 20 percent reduction in wound and transplant tissue size on day 15 after transplantation and no further reduce in course of wound healing process that verified our present study.

Rodrigo et al.[8] have shown that using of infrared laser with wave length of 850 nm, have significant influence on increasing the chance of transplant acceptance on day 3 and however, its effects decreased in proceeding until day 14 compared to day 3 that agrees with Fekrazad et al.[5] results. Walsh et al.[9] showed that the amount of vascular regeneration and facilitating infiltration of white blood cells to the wound increases at a wave length of 830 nm [9]. The results of this investigation, contrary to research of Moore et al.[10] which reported that the wave length of

810 nm is an inhibitory role in proliferation of fibroblasts. They showed the effect of wave length of 665-675 nm as proliferative stimulator [10]. Another study by Nasirian et al.[11] showed that laser with a wave length of 630 nm and 0.5 J/cm<sup>2</sup> power can be significantly increased vascular regeneration process, the proliferation of fibroblasts and collagen compared to control group. The researchers of the study also showed that the infrared laser with the wave length of 850 nm and 0.5 J/cm<sup>2</sup> power have significant difference in comparison with wave length of 630 nm and 0.5 J/cm<sup>2</sup> power in terms of all parameters [11]. The researchers of current study revealed that green LED laser with a wave length of 532 nm increased the vascular regeneration, inflammatory cell infiltration, amount of keratinized layer formation and its thickness, fibroblast migration, amount of collagen and its maturation rate compared to the control group, but this increase is not significant. All data agrees to Fekrazad et al.[5] study. Another study was conducted by Fattahian et al.[12] showed that infrared laser with wave length of 850 nm and 1 J/cm<sup>2</sup> power was more effective compared to red laser with wave length of 635 nm and 1 J/cm<sup>2</sup> power on all mentioned factors such as new vascularization, proliferation of fibroblasts, production of collagen and keratinized layer in epithelial tissue [12], which agree with the results of present study and using of green LED laser with wave length of 532 nm and 1 J/cm<sup>2</sup> power. Our study cleared laser that suitable macroscopic and microscopic changes after full-thickness autologous transplantation.

Based on our study, it can be mentioned that green LED light laser therapy besides having significant prevention in wound and maintenance of transplant tissue size. Significant increase in new vascularization, proliferation of fibroblasts, collagen production, leukocyte migration and generation of keratinized layer in epithelial tissue were seen.

Therefore, it could be claimed that low level laser is likely practical solution in elimination of post-operative complication such as shrinkage and size reduction and viability and preserving of skin on bed in rat model.

## REFERENCES

1. **Swaim SF:** Skin graft. In, Slatter D (Ed): Textbook of Small Animal Surgery. 3<sup>rd</sup> ed., Vol. 1. 321-338, Saunders, Philadelphia, 2003.
2. **Pavletic MM:** Atlas of Small Animal Wound Management and Reconstructive Surgery. 3<sup>rd</sup> ed., 404-430, Wiley-Blackwell, London, 2010.
3. **Fossum TW, Dewey CW, Horn CV, Johnson AL, MacPhail CM, Radlinsky MG, Schulz KS, Willard MD:** Small Animal Surgery. 4<sup>th</sup> ed., 252-256, Elsevier Mosby, St. Louis, 2013.
4. **Bohling MW, Swaim SF:** Skin grafts. In, Tobias KM, Johnston SA (Eds): Veterinary Surgery Small Animal. Vol. 2. 1270-1290, Elsevier Saunders, Missouri, 2012.
5. **Fekrazad R, Chiniforush N, Bouraima SA, Valipour M, Aslani M, Zare M, Ashtiani Safari O:** Low level laser therapy in management of complications after intra oral surgeries. *J Lasers Med Sci*, 3 (4): 135-140, 2012.
6. **Gal P, Kilik R, Mokry M, Vidinsky B, Vasilenko T, Mozes S, Bobrov N, Tomori Z, Bober J, Lenhardt L:** Simple method of open skin wound healing model in corticosteroid-treated and diabetic rats: Standardization of semi-quantitative and quantitative histological assessments. *Vet Med*, 53 (12): 652-659, 2008.
7. **Machneva TV, Protopopov DM, Vladimirov IuA, Osipov AN:** A study of the effect of low-intensity laser radiation of the blue, green, and red spectral regions on the healing of experimental skin wounds in rats. *Biofizika*, 53 (5): 894-901, 2008.
8. **Rodrigo SM, Cunha A, Pozza DH, Blaya DS, Moraes JF, Weber JB, de Oliveira MG:** Analysis of the systemic effect of red and infrared laser therapy on wound repair. *Photomed Laser Surg*, 27, 929-935, 2009. DOI: 10.1089/pho.2008.2306
9. **Walsh LJ, Trinchieri G, Waldorf HA, Whitaker D, Murphy GF:** Human dermal mast cells contain and release tumor necrosis factor-which induces endothelial leukocyte adhesion molecule-1. *Proc Natl Acad Sci*, 88, 4220-4224, 1991. DOI: 10.1073/pnas.88.10.4220
10. **Moore P, Ridgway TD, Higbee RG, Howard EW, Lucroy MD:** Effect of wavelength on low-intensity laser irradiation-stimulated cell proliferation in vitro. *Lasers Surg Med*, 36, 8-12, 2005. DOI: 10.1002/lsm.20117
11. **Nasirian N, Nasirian A:** Effect of low level laser therapy on the surgical wound healing in hamster. *IJP*, 7 (4): 236-240, 2012.
12. **Fattahian HR, Nasirian A, Mortazavi P:** The role of red and infrared low level laser therapy on unmeshed full-thickness free skin autograft in rabbits: As an animal model. *Kafkas Univ Vet Fak Derg*, 19, 829-836, 2013. DOI: 10.9775/kvfd.2013.8902