

Evaluation of Early and Late Period Results of Polyester Film Use for the Repair of Ventral Hernias: An Experimental Study on Rabbit Models ^[1]

Engin KILIÇ ^{1,a} Sadık YAYLA ^{1,b} Vedat BARAN ^{1,c} Berna ERSÖZ KANAY ^{2,d}
Celal Şahin ERMUTLU ^{1,e} Kemal KILIÇ ^{3,f} Mustafa GÖK ^{4,g} Serpil DAĞ ^{5,h}

^[1] This study was presented orally in the 14th National Veterinary Surgery Congress, October 23-26, 2014, Antalya, Turkey

¹ Kafkas University, Faculty of Veterinary Medicine, Department of Surgery, TR-36100 Kars - TURKEY

² Dicle University, Faculty of Veterinary Medicine, Department of Surgery, TR-21280 Diyarbakır - TURKEY

³ Tuzla State Hospital, Clinic of General Surgery, TR-34947 İstanbul - TURKEY

⁴ Adnan Menderes University, Faculty of Medicine, Department of Radiology, TR-09010 Aydın - TURKEY

⁵ Kafkas University, Faculty of Veterinary Medicine, Department of Pathology, TR-36100 Kars - TURKEY

^a ORCID: 0000-0001-8126-3918; ^b ORCID: 0000-0001-6734-421X; ^c ORCID: 0000-0003-3466-5345; ^d ORCID: 0000-0001-5165-0618

^e ORCID: 0000-0002-8923-7682; ^f ORCID: 0000-0003-1070-6886; ^g ORCID: 0000-0001-7021-0984; ^h ORCID: 0000-0001-7667-689X

Article ID: KVFD-2018-21322 Received: 08.11.2018 Accepted: 01.03.2019 Published Online: 01.03.2019

How to Cite This Article

KILIÇ E, Yayla S, Baran V, Ersöz Kanay B, Ermutlu CŞ, Kılıç K, Gök M, Dağ S: Evaluation of early and late period results of polyester film use for the repair of ventral hernias: An experimental study on rabbit models. *Kafkas Univ Vet Fak Derg*, 25 (4): 559-565, 2019. DOI: 10.9775/kvfd.2018.21322

Abstract

The purpose of this study is to assess clinical, MR, USG and histopathological findings of early and later results of polyester film use in experimental ventral hernia model in rabbits. In this study, 16 New Zealand rabbits were divided into 2 groups of 8 rabbits each. After xylazine HCl usage as a sedative, the surgery is conducted under general anaesthesia by ketamine HCl. Upon median skin incision, a 2 cm diameter round defect on linea alba level was formed in rabbits lying in the supine position. The defect was repaired with 4 cm diameter polyester film which had been prepared beforehand in the shape of a disc. After clinical follow up of 15 days for rabbits in group I and 60 days for group II, USG and MR images were taken, by re-laparotomy the presence and extent of peritoneal adhesion was examined visually. All data from the study were statistically assessed via Minitab-16 package program. Tissue samples from the graft area were stained through hematoxylin-eosin and Crossman's triple dye and assessed by usage of light microscope. During histopathological examination, it was observed repair by fibrous tissue in the area where surgery was performed for all the animals in 15 day group. Neither foreign body giant cell reaction nor necrosis was observed in two groups. When clinical, USG, MR findings along with re-laparotomy, macroscopic and histopathological results are taken into account, it was seen that polyester film bore successful results with regards to ventral hernia therapy in rabbits. Based on the data provided by this study, it is decided that the mentioned material should be tried for large hernia defect repair in domestic animals.

Keywords: Graft, Ventral hernia repair, Polyester film, Rabbit

Ventral Hernilerin Onarımında Polyester Film Kullanımının Erken ve İleri Dönem Sonuçlarının Değerlendirilmesi: Tavşan Modellerinde Deneysel Bir Çalışma

Öz

Bu çalışmada, tavşanlarda deneysel olarak oluşturulan ventral herni modelinde, polyester film kullanımının erken ve ileri dönem klinik, MR, USG ve histopatolojik sonuçlarının değerlendirilmesi amaçlanmıştır. Çalışmada kullanılan 16 adet Yeni Zelandalı tavşanı 8'erli 2 gruba ayrıldı. Operasyonlar xylazin HCl sedasyonunu izleyerek ketamin HCl ile elde edilen genel anestezi altında gerçekleştirildi. Operasyon masasına sırtüstü pozisyonda yatırılan tavşanlara median deri ensizyonu yapıldıktan sonra linea alba düzeyinde 2 cm çaplı daire şeklinde bir defekt oluşturuldu. Defekt önceden disk şeklinde hazırlanan 4 cm çaplı daire şeklindeki polyester film ile onarıldı. I. Gruptaki tavşanların 15, II. gruptakilerin ise 60 günlük klinik takibin sonunda USG ve MR görüntüleri alındıktan sonra bu tavşanlara relaparotomi uygulanarak peritoneal adezyon varlığı görsel olarak değerlendirildi. Çalışmadan elde edilen tüm veriler Minitab-16 paket programı kullanılarak istatistiksel olarak değerlendirildi. Greft uygulanan bölgeye ait doku örnekleri Hematoksilin-Eozin (HE) ve Crossman'ın üçlü boyama yöntemi ile boyanarak ışık mikroskopunda değerlendirildi. Histopatolojik incelemede 15 günlük gruptaki hayvanların tamamında uygulama yapılan alanda fibröz doku ile onarım gözlemlendi. Ayrıca her iki grupta da yabancı cisim dev hücre reaksiyonu ve nekroz oluşumu gözlemlenmedi. Klinik, USG ve MR bulguları ile relaparotomik makroskopik ve histopatolojik sonuçlar polyester filmin tavşanlarda ventral herni sağaltımında başarılı sonuçlar verdiğini ortaya koymuştur. Sonuç olarak çalışmadan elde edilen veriler dikkate alındığında bu materyalin evcil hayvanlarda görülen geniş defektli fıtıkların onarımında kullanılabilirliği sonucuna varıldı.

Anahtar sözcükler: Greft, Ventral herni onarımı, Polyester film, Tavşan



İletişim (Correspondence)



+90 546 2626007



sahinermutlu@hotmail.com

INTRODUCTION

Ventral hernias are hereditary or acquired as a result of various reasons. Hernias occurring following abdominal surgical interventions have an important place within the acquired ones ^[1,2]. Regardless of the reason, the treatment option is operation and primary repair should be considered first. However, in cases where the tissue is not strong enough or the hernia hole is too large, various graft materials are used for support ^[3-5]. Nonabsorbable meshes such as polyester, silicone, polyester weave, polyvnyl weave, and polypropylene are used while absorbable materials such as polyglactin 910, polyglactic acid can also be preferred for this purpose ^[6-8]. Nowadays, polytetra filament mesh, sepra-mesh, marlex, prolene, surgipro, mersilene, and goro-tex are amongst the most preferred materials ^[4,8-14]. All these graft materials can have superior characteristics over each other while in practice, the choice of graft material can change to begin with according to the habit of the operator, the general characteristics and the cost of the material. In hernioplasties, adhesion is the most commonly encountered complication along with foreign body reaction, inflammation, fibrosis, calcification, thrombosis, seroma, graft migration, chronic pain, and infection ^[1,4,14-17]. An ideal graft material is desired to not interact with the tissue fluids, be inert, not cause inflammation and foreign body reaction, be resistant against mechanical tension, not be carcinogenic, not cause allergy or hypersensitivity, be producible in needed sizes and forms, be easily sterilisable, and be economical ^[1,2,4,18].

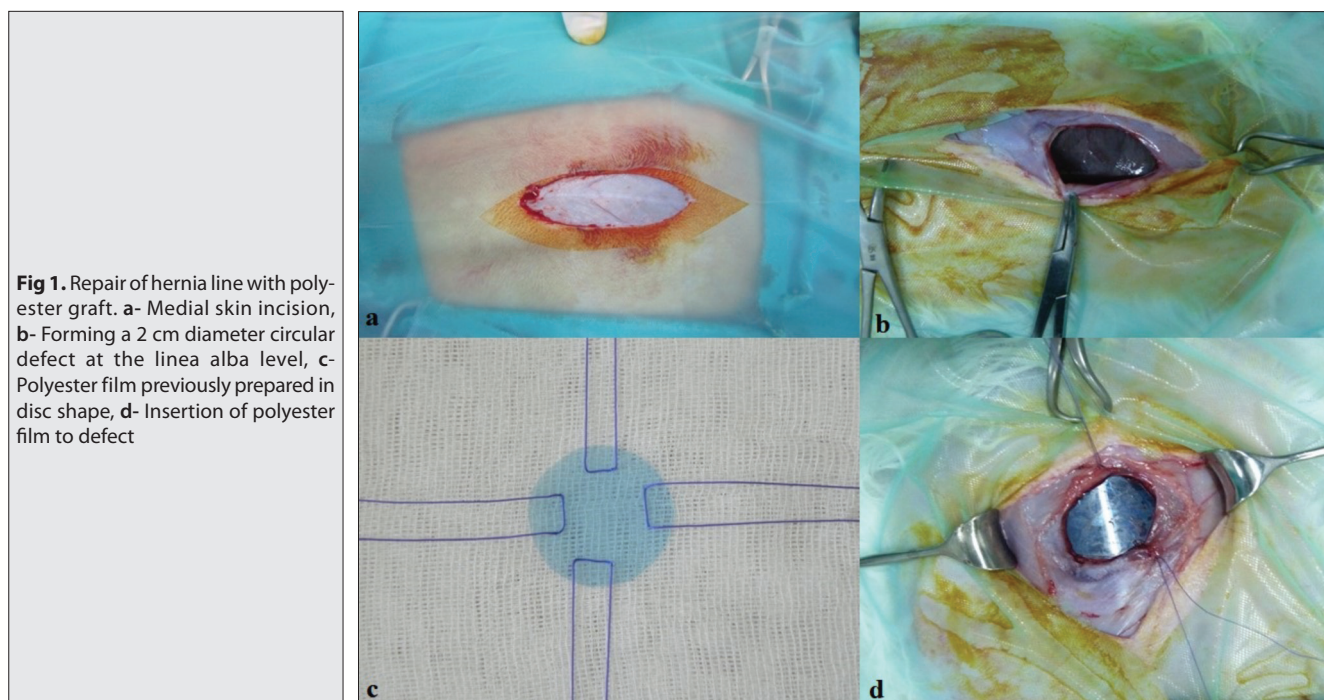
In this study, the objective was to clinically, radiologically (MRI, USG), and histopathologically examine the early and late period results of the use of x-ray film (polyester film),

which has almost no cost, in ventral hernia models formed experimentally in rabbits and to evaluate this used material regarding its compatibility with general characteristics of a graft material.

MATERIAL and METHODS

After obtaining the Dicle University Animal Experiments Local Ethics Committee approval (DÜHADEK-2013-16), the animal material of the study which started as planned was formed by 16 adult male rabbits (*New Zealand*) weighing average 3450 g (3120-3860 g). The rabbits were separated into two groups consisting of 8 rabbits each as Group I to be monitored for 15 days (to see if the peritoneal wall is fully closed) and Group II to be monitored for 60 days (for evaluation of late-term results). Rabbits were fed with standard rabbit pellet feed and water *ad-libitum* until the end of the study. Before the beginning of the experiments, the rabbits' adaptation to the environment was provided for one week. During the adaptation period and throughout the experiment, the rabbits were kept in light for 12 h and in darkness for 12 h at 20-22°C constant temperature and 45-55% humidity rate.

For the operations, following xylazine HCl (10 mg/kg, IM, Rompun® 2%, Bayer, Germany) sedation, dissociative anaesthesia produced by ketamine HCl (30 mg/kg, IM, Ketazol® 10%, Richterfarma, Australia) was preferred. After shaving and disinfecting the abdominal region, the region was prepared aseptically. The rabbits were placed on the operation table in dorsal position and medial skin incision was performed (*Fig. 1 a*). Afterwards a 2 cm diameter circle shaped defect was formed at the linea alba level (*Fig. 1 b*). The defect was repaired in-lay with a 4 cm diameter round



shaped polyester film (Fuji medical X-Ray film) previously prepared in disc shape (Fig. 1 c,d). The polyester film used as the graft material was acquired by scratching the previously used x-ray film until revealing the support layer and then subjecting to the sterilization process with ethylene oxide (Fig. 2). The x-ray film left in a 1% benzalkonium chloride (Zefiran forte, İlsan-İltaş, Turkey) solution for 30 min. Then the film (polyester graft) was scraped with the spatula until only the support layer remained. Disc-shaped grafts with a diameter of 5 cm were obtained and these were sterilized by ethylene oxide. The area was routinely closed, and each rabbit was kept in their own separate cages. In order to provide postoperative analgesia, metamizole sodium (30 mg/kg, IM, Novalgin-Sanofi, Turkey) was applied for 3 days and in order to provide prophylaxis cephazolin sodium (20 mg/kg, IM, Ilespor 250 mg, İbrahim Etem Ulugay İlaç Sanayi Türk A.Ş., Turkey) was applied for the same period of time. The care of the operation areas of the rabbits was given

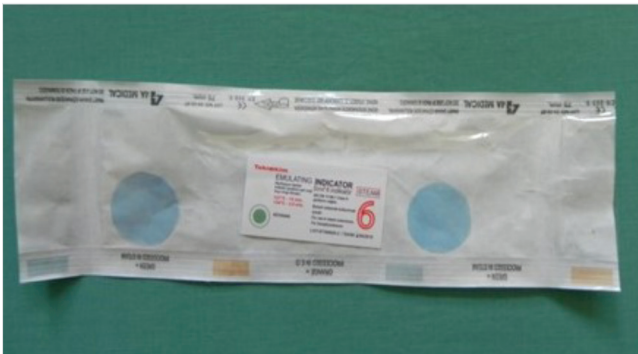

Fig 2. Sterilized polyester graft with ethylene oxide

daily and their feed-water intake was monitored. USG (Toshiba Aplio XG Ultrasound Scanner, Japan, 1-8 MHz) and MRI (Magnetom Essenza, 1.5 Tesla MR Scanner, Siemens, Healthcare, Erlangen Germany) images of the rabbits in Group I were taken at the end of the clinical follow up of 15 days while the images of the rabbits in Group II were taken at the end of the clinical follow-up of 60 days. Relaparotomy was performed on the rabbits and abdominal cavity was reached with an incision of approximately 5 cm diameter from 1 cm lateral of the graft and firstly the peritoneal surface of the graft was evaluated in terms of adhesion (Fig. 3). Existence of peritoneal adhesion and its degree was recorded according to Jenkins et al.^[19] visual adhesion scale. After necessary tissue samples (5 cm diameter from 1 cm lateral of the graft) were taken for histopathologic examination, the laparotomy gaps of the rabbits were closed with the same method and similar care and feeding conditions were provided in the postoperative period for their survival. Tissue samples of the grafted region were fixed in 10% buffered formalin. Paraffin blocks of the tissues were prepared following routine laboratory procedures. The sections of 5 µm thickness taken from these blocks were stained with Hematoxylin-Eosine (HE) and Crossman triple staining method and evaluated under light microscope (Luna 1970). The sections stained with Crossman triple staining method were examined in terms of fibrous tissue formation and organization. The sections stained with HE were evaluated in terms of leucocyte infiltration, foreign body giant cells, fibrosis, capillarization, and necrosis. In the samples taken for histopathological examination, the graft material was stripped from the tissues in order to prevent any problems that might occur during the tissue

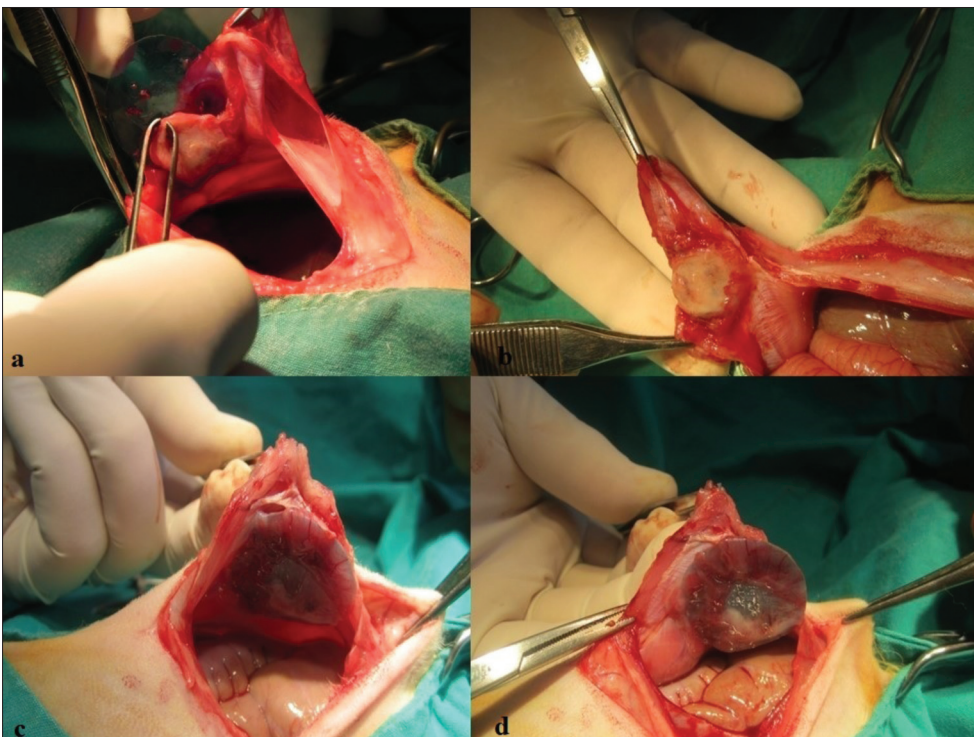


Fig 3. Macroscopic evaluation of the peritoneal surface of the graft. a- Removal of the graft from the pouch between the peritoneum and the abdominal muscles, Group II; b- Peritoneal graft site, Group II; c- The peritoneum completely covered the abdominal surface of the graft, Group I; d- No adhesion between graft and abdominal organs, Group I

administration procedures. All data acquired from the study were statistically evaluated by the use of Minitab-16 package programme.

RESULTS

During the daily routine follow-up of the rabbits, there were no problems encountered such as serositis, haematoma, and increase in body temperature. It was observed that 6 h after waking up from anaesthesia, the rabbits were willing in feed and water intake and were able to move inside the cage with comfort. In the ultrasonographic examination conducted on the 15th day, it was observed that in all of the rabbits in Group I, the graft kept its position, there was an increase of thickness in cutaneous and subcutaneous tissues. It was detected that there was a clear difference between Group I and II in terms of tissue thicknesses. In the MRI results of Group I, it was observed in the transverse

fat saturated (fat-sat) T1AG and the sagittal fat saturated (fat-sat) T1AG that there was an increase of thickness in cutaneous and subcutaneous tissues (compatible with granulation tissue) in the area the graft was placed. It was observed especially in the fat saturated images that this granulation tissue did not extend to the mesenteric fat tissue (Fig. 4). A minimal level of thickness increase was observed in the cutaneous and subcutaneous tissues in the graft applied region of Group II in the MRI results. But, these thickness increases were not measured. It was observed that the granulation tissue became thinner and did not extend to the mesenteric fatty tissue or abdominal fascia (Fig. 5). In the macroscopic evaluation of the hernia region, adhesion was not observed in any of the rabbits in Group I and II (Table 1). It was detected by only observation that the surface of the graft material facing the abdominal cavity was covered with peritoneum compatible layer. It was observed that the surface of the peritoneal membrane covering the graft

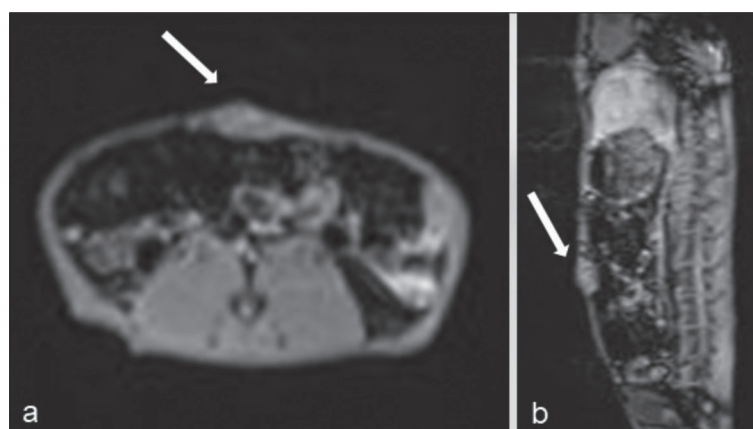


Fig 4. MRI of one case in Group I. **a-** Transverse fat-suppressed T1AG; **b-** Saggital fat-suppressed T1AG

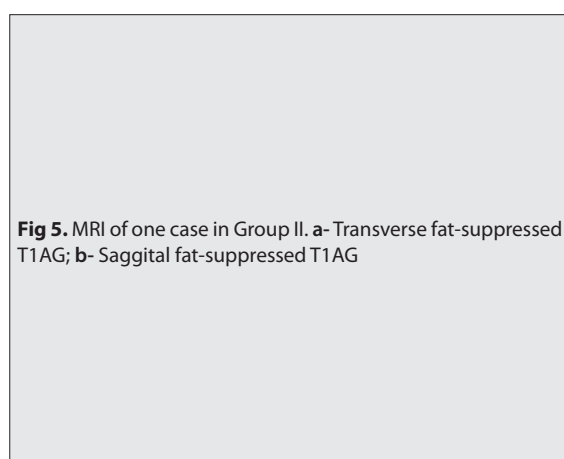


Fig 5. MRI of one case in Group II. **a-** Transverse fat-suppressed T1AG; **b-** Saggital fat-suppressed T1AG

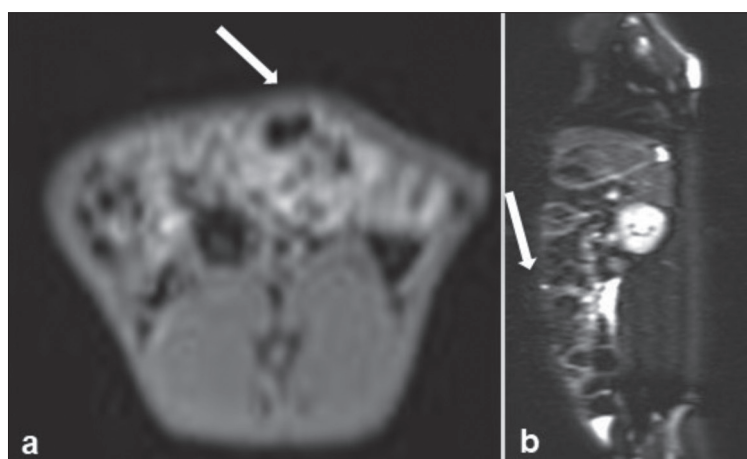


Table 1. Distribution of adhesion grades in group I and group II

Adhesion Grades		Group I	Group II
No adhesion	0	n: 8	n: 8
Adhesion allocated with mild blunt dissection	1	n: -	n: -
Adhesion allocated with aggressive blunt dissection	2	n: -	n: -
Adhesion allocated with sharp dissection	3	n: -	n: -

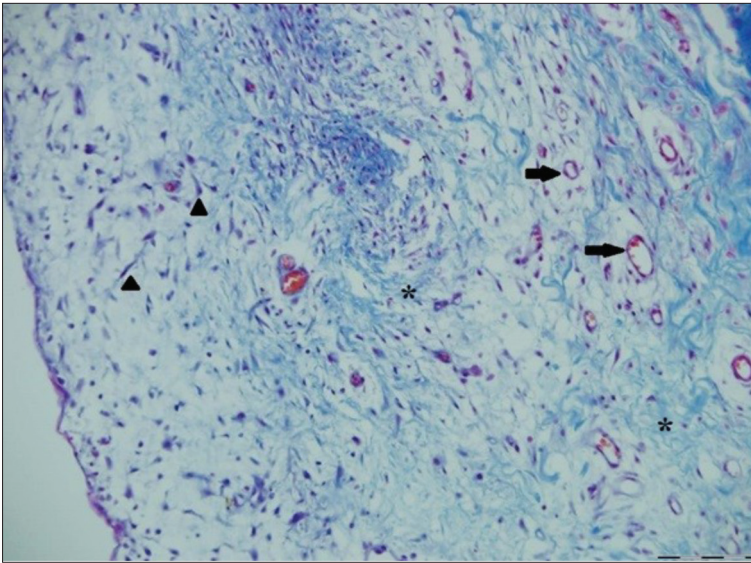


Fig 6. Histopathologic evaluation of a case in Group I. Collagen fibers (*stars*), vascularization (*arrows*), Fibroblast/fibrocytes (*arrowheads*), Crosmann's triple stain, Bar: 100 μ m

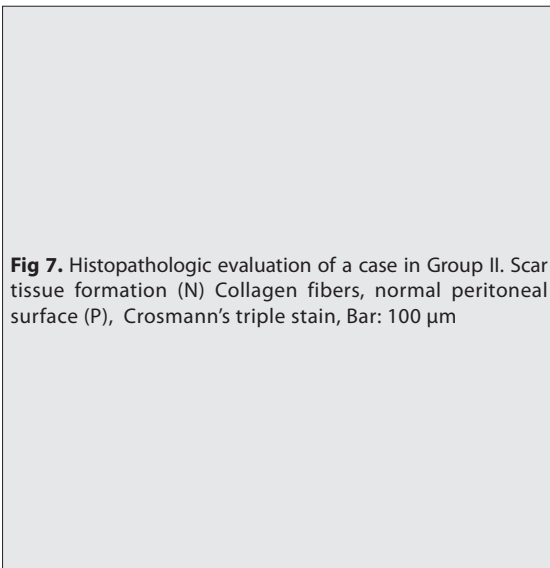
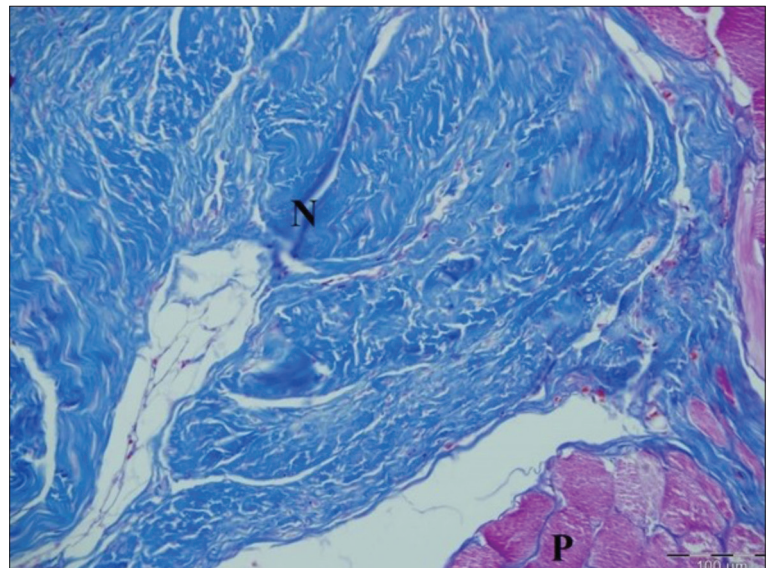


Fig 7. Histopathologic evaluation of a case in Group II. Scar tissue formation (N) Collagen fibers, normal peritoneal surface (P), Crosmann's triple stain, Bar: 100 μ m



was smooth. According to the visual adhesion scoring, adhesion level in all cases was recorded as "0".

In the histopathologic examination of the tissue samples taken from the abdominal wall of the area where the graft is applied, it was observed that the graft was covered with fibrous tissue in all of the animals in the 15-day group. New capillary formations, many fibroblasts and fibrocytes, collagen fibres and a small number of mononuclear cell infiltration was observed in the forming granulation tissue (*Fig. 6*). Foreign body giant cell reaction and necrosis were not observed in any of the rabbits. Organization characterized with fibrous tissue formation was observed in the application region in Group II of the study. Vascularization, decrease in cellularity, and increase in collagen fibres were observed in the application region of the rabbits in this group. Similar to the other group, there were no foreign body giant cell reaction and necrosis observed in this group as well (*Fig. 7*).

DISCUSSION

Regardless of the reason, operation is mandatory for the treatment of ventral hernias [18,20]. In cases where primary repair is inadequate, herniorrhaphy can be performed using various graft materials with organic or synthetic characteristics [12,17]. For this purpose, for many years until today, many graft materials have been used by different researchers. Although some improvements can be provided in the general characteristics of the graft materials parallel to the scientific and technological developments, it is difficult today to talk about a graft material with ideal characteristics. Studies regarding introducing different graft materials into clinical practice by taking into consideration postoperative complications are continuing today as well. In this study, the polyester support layer acquired by separating from the top, emulsion, and bottom layers of the idle, used x-ray films were used as graft material. It was aimed to contribute to veterinary medicine

a new graft material by evaluating together the early and late period clinical, MRI, USG, and histopathologic results of polyester film use for the purpose of hernioplasty. One of the most important complications developing after hernioplasty operations is foreign body reaction [4,10,14]. Not encountering any foreign body reactions in and around the hernia region with graft application during the postoperative examinations and histopathologic examinations of all the rabbits (n=16) in Groups I and II evaluated in the context of the presented study has given us hope that the polyester films are biocompatible and can be used in clinical cases safely after being subjected to an appropriate sterilization operation.

In the postoperative process following hernioplasty operations, it has been reported that complications can develop such as inflammation, fibrosis, calcification, thrombosis, seroma, graft migration, chronic pain, and infection [4,21-23]. Complications such as seroma, inflammation were not encountered in the wound region during the daily clinical examinations of the rabbits from the first day until the end of the study. It was determined that the graft kept its first applied position in the USG and MRI examinations and it was detected that the granulation tissue was relatively thick on the 15th day but the granulation tissue became thinner on the 60th day. Calcification or fibrosis were not observed in the area during re-laparotomy. These complications reported to have developed in some cases where ventral hernias are repaired with graft [1,11] were not encountered in any of the rabbits included in the study. This result was interpreted that a used polyester film may be in inert structure.

It has been reported that adhesions are at the top of the most prevalently encountered complications in hernioplasty operations [11,24] and adhesions can cause many negative results from infertility to death [5]. It is known that adhesions can develop with the effect of evaporation even in the cases where just the abdomen is opened without any surgical intervention to intraabdominal organs [3,22,25,26]. Thus, it is suggested for the incision line to be kept as limited as possible during laparotomy operations and to humidify intraabdominal organs throughout the operation. Physiologically, the lubrication of the peritoneal cavity is provided with peritoneum fluid. Since most of the synthetic and organic graft materials used for hernioplasty have a permeable structure, peritoneum fluid and inflammation cells required for healing leak through the hernia line to the subcutaneous region or outside the skin. As a result of the contamination forming related to this, fibrosis and adhesion form between the graft, the surrounding tissues, and the abdominal organs. Adhesion was not encountered at the examination during relaparotomy performed both on the 15th day of the study and the 60th day of the study. Histopathologic results also showed that there was no inflammatory reaction which can provide basis for adhesion. It is considered that the polyester film

used in-lay not being permeable, its surface being smooth, and it being biocompatible were effective in the non-development of adhesion.

During the relaparotomy conducted both on the 15th day and the 60th day, it was observed that the surface of the graft material facing the abdominal cavity was covered with a thin, shiny, and smooth layer in all cases. The studies showed that this area is closed in a short time with the peritoneal epithelisation mechanism regardless of the size of the peritoneal loss. It was detected with the histopathologic evaluation of the presented study that the thin membrane covering the graft was of normal peritoneum structure.

An ideal graft material is desired to be inert, not interact with tissue fluids, not cause inflammatory and foreign body reactions, not be carcinogenic, not cause allergy and hypersensitivity, be resistant against mechanical tensions, be produced in required forms, and be sterilisable [2,18,23,26].

There are different sizes of commercial forms of x-ray films such as 13-18, 18-24, 24-30, 30-40, 35-35 cm [11]. Thus, it can be said that the polyester film prepared by cutting before the operation or during the operation in appropriate sizes according to the size of the hernia hole provides an advantage. Since the hernia size was formed as determined in the experimentally planned study, the graft materials were prepared in advance by cutting them to the appropriate size (5 cm). Moreover, suture materials were attached in four different directions to the prepared graft material in advance and application ease was provided. In the meantime, it was observed that the spearhead needles damage the grafts during suturing as the film is of semi-rigid structure and at the same time, since the line the needle passes through is of sharp characteristics, it can damage the thread. From this experience, it is suggested that the needles to be used in grafting should be tubular body needles.

It has been reported that there are different graft materials in the polyester structure such as mersilene, paritex, dacron, biomesh used in the treatment of hernia. However, all of these materials need to go through some processing to be converted into graft. These processes also require a certain amount of cost. In this material, which we prefer as autograft, there is no such cost.

A statistical comparison was not performed since adhesion was not observed in any of the cases (n=16) used for the study during the re-laparotomies performed for adhesion scoring.

In conclusion, when clinical, MRI, USG, and histopathologic results are evaluated together, since it was reached the opinion that the polyester film meets most of the expected characteristics from an ideal graft material in experimental ventral hernia model, it gave hope to the researchers that

the same material can be safely used in the clinical cases as well.

AUTHORS' CONTRIBUTION

EK, ÇŞE, VB designed and executed the study, SY, BEK, KK did study sampling, MG did radiological examination, SY arranged and analyzed the statistical data, SD processed the samples, and histopathological examination, EK and ÇŞE wrote the manuscript. All authors reviewed and approved the manuscript for submission.

REFERENCES

- Durmuş AS, Han MC, Yaman İ:** Usage of autogenous fascia lata graft of treatment of experimental large defected abdominal hernias in dogs. *FÜ Sağ Bil Derg*, 21 (4): 153-157, 2007.
- Emir S, Sözen S, Yazar FM, Özkan Z, Çetinküner S, Özdaş S, Aziret M:** The safety and the feasibility of mesh use in incarcerated inguinal hernia repair: A clinical study. *Kafkas J Med Sci* 2 (1): 15-20, 2012. DOI: 10.5505/kjms.2012.57338
- Cihan M, Aksoy Ö, Özaydın İ, Özba B, Baran V:** General evaluation of umbilical lesions in calves: 322 cases (1996-2005). *Kafkas Univ Vet Fak Derg*, 12 (2): 141-145, 2006.
- Çakmak A, Çirpanlı Y, Bilensoy E, Yorgancı K, Çalış S, Sarıbaş Z, Kaynaroğlu V:** Antibacterial activity of triclosan chitosan coated graft on hernia graft infection model. *Int J Pharm*, 381, 214-219, 2009. DOI: 10.1016/j.ijpharm.2009.05.059
- Kuterdem E:** Synthetic mesh grafts and their specifications in hernia repair. *Turk J Surg*, 21 (2): 51-54, 2005.
- Ansaloni L, Catena F, D'Alessandro L:** Prospective randomized, double blind, controlled trial comparing Lichtenstein's repair of inguinal hernia with polypropylene mesh versus surgisis gold soft tissue graft: Preliminary results. *Acta Bio Med*, 74 (2): 10-14, 2003.
- Badyak S, Kokini K, Tullius B, Simmons-Bryd A, Morff R:** Morphologic study of small intestinal submucosa as a body wall repair device. *J Surg Res*, 103, 190-202, 2002.
- Öğünç D:** Repair of acquired abdominal wall defects. *Turk J Traum Emerg Surg*, 6 (1): 14-17, 2000.
- Catena F, Ansaloni L, Leone A, De Cataldis A, Gagliardi S, Gazzotti F, Peruzzi S, Agrusti S, D'Alessandro L, Taffurelli M:** Lichtenstein repair of inguinal hernia with Surgisis inguinal hernia matrix soft-tissue graft in immunodepressed patients. *Hernia*, 9, 29-31, 2005. DOI: 10.1007/s10029-004-0273-y
- Catena F, Ansaloni L, Gazzotti F, Gagliardi S, Di Saverio S, D'Alessandro L, Pinna AD:** Use of porcine dermal collagen graft (Permacol) for hernia repair in contaminated fields. *Hernia*, 11, 57-60, 2007. DOI: 10.1007/s10029-006-0171-6
- Kılıç K, Kılıç N, Kılıç E, Yayla S, Ermutlu ÇŞ, Özaydın İ, Peker K, Dağ S:** A comparison of the efficacy of dimethyl sulfoxide (dms) and synovial fluid in the prevention of peritoneal adhesions: Experimental rabbit model. *Kafkas Univ Vet Fak Derg*, 19 (Suppl-A): A27-A32, 2013. DOI: 10.9775/kvfd.2012.7511
- Gönüllü D, Köksoy FN:** The prosthetic materials in hernia repair. *JAREM*, 5, 1-5, 2015. DOI: 10.5152/jarem.2015.577
- Koç Y, Çiftçi MK, İzci C, Türkütant SS, Arıcan M:** Clinical and histopatological investigations on repairing large defected hernias by synthetic tulle. *Eurasian J Vet Sci*, 8 (1): 37-43, 1992.
- Yerdel MA, Akin EB, Dolalan S, Türkçapar AG, Pehlivan M, Geçim İE, Kuterdem E:** Effect of single-dose prophylactic ampicillin and sulbactam on wound infection after tension-free inguinal hernia repair with polypropylene mesh: The randomized, double-blind, prospective trial. *Ann Surg*, 233 (1): 26-33, 2001.
- Altan S, Alkan F, Koç Y, Tur İ:** An important complication in ruminants: Incisional hernias. *Dicle Univ Vet Fak Derg*, 2 (3): 44-49, 2015.
- Belge A, Bakır B, Atasoy N, Alkan İ:** Umbilical lesions in calves. *YYÜ Vet Fak Derg*, 7 (1-2): 14-17, 1996.
- Stremitzer S, Bachleitner-Hofmann T, Gradl B, Gruenbeck M, Bachleitner-Hofmann B, Mittlboeck M, Bergmann M:** Mesh graft infection following abdominal hernia repair: Risk factor evaluation and strategies of mesh graft preservation. A retrospective analysis of 476 operations. *World J Surg*, 34, 1702-1709, 2010. DOI: 10.1007/s00268-010-0543-z
- Samsar E, Akin F:** Özel Cerrahi. 189-218, Medipres, Ankara, 2002.
- Jenkins SD, Klamer TW, Parteka JJ, Condon RE:** A Comparison of prosthetic materials used to repair abdominal wall defects. *Surgery*, 94, 392-398, 1983.
- Fabian TC, Croce MA, Pritchard FE, Minard G, Hickerson W, Howell RL, Schurr MJ, Kudsk KA:** Planned ventral hernia. Staged management for acute abdominal wall defects. *Ann Surg*, 219 (6): 643-653, 1994.
- Görgül OS:** Veteriner Özel Cerrahi. 227-254, Medipres, Ankara, 2012.
- Kahramanca Ş, Kaya O, Azılı C, Celep B, Gökçe E, Küçükpınar T:** Does topical rifampicin reduce the risk of surgical field infection in hernia repair? *Turk J Surg*, 29, 54-58, 2013. DOI: 10.5152/UCD.2013.35
- Özaydın İ, Kilic E, Özba B, Cihan M:** A new technique for the operative treatment of umbilical lesions (umbilical hernia, urachal fistula, omphalophlebitis and omphaloarteritis) in bull calves. *Kafkas Univ Vet Fak Derg*, 4 (1-2): 55-61, 1998.
- Kaya C, Idiz UO, Bozkurt E, Yazıcı P, Demir U, Mihanlı M:** The routine use of mesh and the role of appendectomy for the Amyand's hernia cases. *Med Bull Sisli Etfal Hosp*, 50 (4): 315-318, 2016.
- Sahoo S, DeLozier KR, Erdemir A, Derwin KA:** Clinically relevant mechanical testing of hernia graft constructs. *J Mec Behav Biomed Mater*, 41, 177-188, 2015. DOI: 10.1016/j.jmbbm.2014.10.011
- Pekcan Z, Besalti O, Sirin YS, Caliskan M:** Clinical and surgical evaluation of perineal hernia in dogs: 41 Cases. *Kafkas Univ Vet Fak Derg*, 16 (4): 573-578, 2010. DOI: 10.9775/kvfd.2009.1149