

RESEARCH ARTICLE

Antioxidant and Anti-Inflammatory Effects of Nicotinamide Adenine Dinucleotide (NAD⁺) Against Acute Hepatorenal Oxidative Injury in An Experimental Sepsis Model ^[1]

Songul DOGANAY ^{1,a (*)} Ozcan BUDAK ^{2,b} Arzu SAHIN ^{3,c} Nurten BAHTIYAR ^{4,d}

^[1] A part of this study was presented as an oral presentation at the 46th National Physiology Congress, 08-10 October, 2021, On-line, Türkiye

¹ Sakarya University, Faculty of Medicine, Department of Physiology, TR-54000 Sakarya - TÜRKİYE

² Sakarya University, Faculty of Medicine, Department of Histology and Embryology, TR-54000 Sakarya - TÜRKİYE

³ Usak University, Faculty of Medicine, Department of Physiology, TR-64000 Usak - TÜRKİYE

⁴ Istanbul University-Cerrahpasa, Cerrahpasa Faculty of Medicine, Department of Biophysics, TR-34098 Istanbul - TÜRKİYE
ORCID: ^a 0000-0002-1730-1331; ^b 0000-0002-2617-3175; ^c 0000-0002-8789-4582; ^d 0000-0003-2420-8415

Article ID: KVFD-2021-26609 Received: 06.10.2021 Accepted: 10.01.2022 Published Online: 14.01.2022

Abstract

The aim of this study is to determine the antioxidant and anti-inflammatory effects of Nicotinamide Adenine Dinucleotide (NAD⁺) in preventing multi-organ damage caused by sepsis. Twenty-eight male Wistar-albino rats were randomly divided into four groups. The study groups comprised Sham group, sepsis group (CLP), sepsis + 100 mg/kg NAD⁺ (CLP+N100) and sepsis + 300 mg/kg NAD⁺ group (CLP+N300). Sepsis was induced by the cecum ligation perforation (CLP) method. NAD⁺ was administered intraperitoneally for five days before cecum perforation and 6 h after operation. Serum, liver and kidney tissues were taken from the rats 24 h after the operation. MDA, GSH, CAT, TNF- α , IL-6, IL-1 β , and caspase-3 parameters were measured in tissue samples with biochemical and immunohistochemical methods. In the histopathological and immunohistochemical examination, increases in TNF- α , IL-6, IL-1 β , and caspase-3 expressions were observed in the liver and kidney tissues of the CLP group and severe damage was seen in tissue morphology (P<0.001). Hepatorenal injury was significantly decreased in the treatment groups. Sepsis increased MDA levels in all tissues, but significantly decreased GSH and CAT activities. While NAD⁺ administration significantly increased GSH and CAT activity in the liver and kidney tissues, it caused a significant decrease in MDA levels. This study shows that nicotinamide may be a potent therapeutic agent for the treatment of sepsis.

Keywords: Anti-inflammation, Hepatorenal injury, Nicotinamide, Oxidative stress, Sepsis

DeneySEL Sepsis Modelinde Nikotinamid Adenin Dinükleotidin (NAD⁺) Akut Hepatorenal Oksidatif Hasara Karşı Antioksidan ve Anti-inflamatuar Etkileri

Öz

Bu çalışmada amaç, sepsisin neden olduğu çoklu organ hasarını önlemede Nikotinamid Adenin Dinükleotid'in (NAD⁺) antioksidan ve anti-inflamatuar etkilerini belirlemektir. 28 erkek Wistar-albino sıçan rast gele yedişerli dört gruba ayrıldı. Çalışma grupları; Sham grubu, sepsis grubu (CLP), sepsis + 100 mg nikotinamid uygulama grubu (CLP+N100) ve sepsis + 300 mg nikotinamid uygulama grubu (CLP+N300) şeklinde oluşturuldu. NAD⁺ çekum perforasyonundan önce beş gün boyunca ve operasyondan 6 saat sonra intraperitoneal yoldan verildi. Operasyondan 24 saat sonra ratlardan serum, karaciğer ve böbrek dokuları alındı. Alınan doku örneklerinde MDA, GSH, CAT, TNF- α , IL-6, IL-1 β , kaspaz-3 parametreleri biyokimyasal ve immünohistokimyasal metod kullanılarak ölçüldü. Histopatolojik ve immünohistokimyasal incelemede, CLP grubunun karaciğer ve böbrek dokularında TNF- α , IL-6, IL-1 β ve kaspaz-3 ekspresyonlarında artışlar gözlemlendi ve doku morfolojisinde ciddi hasar görüldü (P<0.001). Tedavi gruplarında hepatorenal hasar anlamlı olarak azaldı. Sepsis, tüm dokularda MDA seviyelerini arttırdı, ancak GSH ve CAT aktivitelerini önemli ölçüde azalttı. NAD⁺ uygulaması dokularda GSH ve CAT aktivitesini önemli ölçüde artırırken, MDA düzeylerinde anlamlı düşüşe neden oldu. Bu çalışmadan elde edilen veriler; sepsisin tedavisinde Nikotinamidin güçlü bir terapatik ajan olabileceğini göstermektedir.

Anahtar sözcükler: Anti-inflamasyon, Hepatorenal hasar, Nikotinamid, Sepsis, Oksidatif stres

How to cite this article?

Doganay S, Budak O, Sahin A, Bahtiyar N: Antioxidant and anti-inflammatory effects of nicotinamide adenine dinucleotide (NAD⁺) against acute hepatorenal oxidative injury in an experimental sepsis model. *Kafkas Univ Vet Fak Derg*, 28 (1): 121-130, 2022.
DOI: 10.9775/kvfd.2021.26609

(*) Corresponding Author

Tel: +90 264 295 4321 Cellular phone: +90 530 952 3295

E-mail: songuldoganay@sakarya.edu.tr (S. Doganay)



This article is licensed under a Creative Commons Attribution-NonCommercial 4.0 International License (CC BY-NC 4.0)

INTRODUCTION

Sepsis causes many changes such as increased microvascular permeability, acute lung damage, coagulation disorders, hypovolemia, decreased myocardial contractility, hypoxia, and decreased systemic vascular resistance, resulting in respiratory, renal, hepatic, cardiovascular and endocrine organ dysfunctions [1,2]. It was determined that sepsis activates the complement system through its endotoxic effect, thus basophil and mast cells are stimulated and some vasoactive mediators are secreted from these cells [3]. The increased inflammatory response in sepsis is maintained by pro-inflammatory cytokines such as TNF- α , IL-6, and IL-1 β produced by monocytes in response to infection or endotoxins. Pro-inflammatory cytokines cause endothelial breakdown and microvascular damage [4,5]. Endotoxin, TNF- α , IL-1 β , leukotrienes, nitric oxide (NO) and toxic oxygen radicals that are released from neutrophils and lysosomal enzymes increase endothelial permeability. Increased endothelial permeability and endothelial damage facilitates extravasation and formation of microthrombi. As a result, organ perfusion deteriorates and organ failure develops [6]. In sepsis, reactive oxygen species (ROS) directly induce cytotoxicity in organs, causing changes in cell signaling pathways. ROS products are destroyed by a complex antioxidant defense system consisting of enzymatic antioxidants such as glutathione peroxidase (GPx), catalase (CAT), and superoxide dismutase and various non-enzymatic antioxidants such as melatonin, albumin, bilirubin, transferrin, ceruloplasmin, and uric acid [7]. For this reason, in studies about the treatment of sepsis conducted in recent years, it was reported that the prevention of ROS formation also reduces tissue and organ damage caused by sepsis in addition to reducing cytokine release, as well as reducing the mortality rate [8].

Nicotinamide adenine dinucleotide (NAD⁺) is an important cofactor for most enzymes in cells that oxidize substrates and are itself reduced to NADH. Conversely, NADPH often acts as a cofactor for enzymes that degrade substrates. NAD⁺ is a hydride acceptor that, along with its reduced form NADH is vital to the redox reactions in metabolic processes. Under physiological conditions, NAD⁺ production and consumption in cells is kept in a constant balance. Therefore, NAD⁺ homeostasis has key roles in cellular catabolism and anabolism [9]. With its NAD⁺ metabolite, nicotinamide is involved in many important biological events, including energy production, fatty acids, cholesterol and steroid synthesis, signal transduction, and preservation of genome integrity. NAD⁺ is also required for DNA repair and ADP-ribosylation of proteins [10]. Immune system dysfunction of NAD⁺, known for its anti-inflammatory and antioxidant properties, was reported to be a potent cytoprotectant blocking early apoptotic phosphatidylserine exposure and late nuclear DNA degradation, during disorders including diabetes and aging-related diseases [11]. Although various medical treatments were attempted for the treatment

of sepsis, there is still no adequate treatment to prevent multiple organ damage. However, more effective treatment protocols can be developed by explaining the mechanisms associated with sepsis. In our study, we aimed to investigate the anti-oxidant and anti-inflammatory role of NAD⁺ in sepsis induced by cecal ligation and perforation in preventing damage to serum, liver and kidney tissue with biochemical and histopathological methods.

MATERIAL AND METHODS

Ethical Approval

This study was conducted at Sakarya University Animal Laboratory and Research Centre (SUDATEM). The experimental protocols were carried out in accordance with international guidelines, after obtaining approval from the University Animal Care and Use Ethics Committee (protocol number: 05/08/2020-43).

Experimental Procedure and Animals

All rats were kept in wire cages under standard laboratory conditions (08.00-20.00 light/dark light cycle, warm 22 \pm 2°C humidity 50-60%). All rats were fed with standard pellet feed and tap water before the study. They were only allowed water for 12 h before and after the operation. Ketamine HCl (Ketalar[®], 50 mg/mL, Pfizer, Istanbul) and xylazine HCl (Rompun[®] 2%, Bayer, Istanbul) were used for anesthesia and NAD⁺ (Sigma Chemical East ellsworth rd. Item no; N0636, USA) was used as antioxidant agent.

Twenty-eight Wistar-Albino adult male rats with an average weight of 270 \pm 30 grams were used in the study. The rats were randomly divided into 4 groups (each group n=7).

Sham group: The rats in this group were operated under anesthesia, but CLP was not performed. One mL 0.9% NaCl was given intraperitoneally (i.p.) for 5 days before the operation and 6 h after the operation.

CLP group: Sepsis was induced using the CLP method under general anesthesia. One mL 0.9% i.p. NaCl was given for 5 days before the operation and 6 h after the operation.

CLP + N100 group: Sepsis was induced using the CLP method under general anesthesia as in the CLP group. In addition, the rats in this group were given Nicotinamide i.p. at a dose of 100 mg/kg, after dissolution in 0.9% NaCl for 5 days before the CLP procedure and 6 h after the operation [12].

CLP+N300 group: Sepsis was induced using the CLP method under general anesthesia as in the CLP group. Nicotinamide was given i.p. after dissolution in 0.9% NaCl at a dose of 300 mg/kg for 5 days before the CLP procedure and 6 h after the operation [12].

Animal Sepsis Model Induced by Cecal Ligation and Perforation

The CLP model applied in the study was performed in

accordance with the method previously reported by Cadirci et al.^[13] Sepsis was induced in rats using the CLP-induced sepsis model. All rats were anesthetized intraperitoneally (i.p) with ketamine HCl (50 mg/kg) and Xylazine HCl (15 mg/kg). Anesthetized rats were placed on the operating table in supine position. The abdominal area was shaved and washed with povidone iodine. The cecum was isolated with a 2 cm incision from the abdominal region of the rats to reach the peritoneum. Ascending colon contents were pushed down to fill the cecum. After the cecum was tied under the ileocecal valve using 3/0 silk thread, it was pierced with an 18'G needle (2 holes) and the cecum was placed inside the abdomen. The abdomen was closed using 3/0 silk thread. After the surgical procedure, 1% lidocaine solution was applied to the incision areas of rats as an analgesic to reduce pain stress. Animals were fasted after surgery, but were allowed to take water after 6 h postoperative.

All rats were sacrificed with high-dose blood collection while under general anesthesia 24 h after the operation. Liver, kidney and serum samples were obtained. For serum, the blood taken into a 5 mL sterile syringe was placed in a red-capped serum tube and centrifuged at 2500 rpm for 10 min at +4°C. Tissue and serum samples examined for biochemical parameters were stored at -20°C until laboratory analysis.

Determination of MDA, GSH Levels and CAT Activity

Liver and kidney tissues (100 mg) were washed with 0.9% NaCl solution and then centrifuged (+4°C, 3000g, 10 min). Then, 10% tissue homogenates were prepared by mixing cold 1.15% KCl with 0.01 M sodium potassium phosphate (pH=7.4) solution. Homogenates were centrifuged (10.000xg) for 20 min at +4°C. Protein was measured from the obtained supernatants using the Lowry method^[14]. Later, MDA, GSH levels and CAT activity were measured in liver and kidney supernatants and serum. Determination of MDA, which is one of the final products of lipid peroxidation, was made using Buege's method^[15], and results are given as nM/mg. Determination of reduced glutathione (GSH) concentration was performed using Agergaard's method^[16], and results are given as μM/mg. CAT activity was determined using Hadwan's method^[17], and results are given as U/mg.

Histopathological Evaluation

Liver and kidney tissues were fixed in 10% neutral buffered formaldehyde for 72 h and washed in tap water for 1 day. Then, the samples were passed through alcohol series and the dehydration process was applied. The tissues were made transparent with xylol and embedded in paraffin blocks. Sections of 4 microns were taken and stained with hematoxylin eosin (H&E). Photographs were taken during examination under a light microscope (Olympus CX31-Japan). Histopathological evaluations of liver tissue in terms of sinusoidal congestion, necrosis and vacuolization

were performed using the semi-numerical modified scoring system of Suzuki^[18]. The scale for kidney injury designed to semi-quantitatively evaluate kidney tissue sections (tubular necrosis, cytoplasmic vacuolization, tubular dilatation and interstitial hemorrhage) was used^[19].

Immunohistochemical Analysis

After the deparaffinization of the tissues placed on a slide with "Poly-L-Lysine", 4 μm thick sections from tissues fixed in neutral formaldehyde solution were boiled in a citrate buffer for antigen retrieval for 20 min in a microwave oven. After being allowed to cool to room temperature, they were washed with phosphate buffer solution (PBS). For endogenous peroxidase inactivation, they were incubated with 3% hydrogenperoxide (H₂O₂) for 20 min after PBS bath. After cooling, TNF-α (sc-52746, Santa Cruz, USA), IL-6 (sc-32296, Santa Cruz, USA), IL-1β (sc-52012, Santa Cruz, USA), caspase-3 (sc-56053, Santa Cruz, USA) primary antibodies were used as primary antibody and the rat and rabbit specific HRP/DAB detection IHC kit was used as secondary antibody. Immunopositivity in samples was evaluated after counterstaining with hematoxylin by giving a semi-quantitative number for positive cells.

Scoring of Immunoreactivity

The immunohistochemical staining results were evaluated with the most common method used semi-quantitative H scoring in mouse models. The percentage of positive cells was graded as follows: no stained cells (Grade 0), 1-25% stained cells (Grade 1), 26-50% stained cells (Grade 2), 51-75% stained cells (Grade 3), and 76-100% stained cells (Grade 4) in the representative area. The immunostaining intensity was scored as 1+ (weak), 2+ (moderate), 3+ (intense) and 4+ (strong/intense). For this, at least 500 cells were counted. The total score was calculated using the following formula: total score = [percentage of positive cells] x [immunostaining intensity]^[20]. The evaluation was made in at least five areas with an inverted microscopic lens (x400 objective). Results were expressed as a percentage.

Statistical Analysis

Statistical analyses were performed using the SPSS 24.0 package program (SPSS Inc. and Lead Tech. Inc. Chicago, USA). Numerical data are given as mean ± standard deviation (SD). The Kolmogorov-Smirnov test was used to check normal distribution of data. In comparison of more than two variables, one-way ANOVA and Kruskal Wallis test were used according to normality. In evaluating the significance within the group, TUKEY HSD was used for variables where variances were homogeneous, and Tamhane's T2 test was used for non-homogeneous variables. Histopathological and immunohistochemical parameters were evaluated semi-quantitatively and the number of positive cells were evaluated statistically. Results with P<0.05 were considered significant.

RESULTS

Biochemical Analysis

Fig. 1 presents in the tissue MDA levels. Sepsis induced by CLP caused an increase in MDA levels, which is an indicator of lipid peroxidation. The level of MDA in tissues increased significantly in the CLP group compared to the Sham, and treatment groups. While serum MDA level increased significantly in the CLP group compared to the sham group (P=0.016), there was no significant difference in comparison with the treatment groups (P>0.05). Liver MDA levels were significantly lower in the CLP+N300 group compared to the Sham and CLP groups (P=0.001, P=0.023, respectively). Kidney tissue MDA levels were significantly lower in the treatment groups compared to the Sham and CLP groups (P<0.05).

GSH levels of tissues in the experimental groups are presented in Fig. 2. GSH levels in the tissues decreased in the CLP group, and NAD treatment increased GSH levels. However, this increase was statistically significant between groups only for the kidney. There was a statistically significant decrease in renal GSH levels in the CLP group compared to the Sham and treatment groups (P=0.001, P=0.008, P=0.012, respectively).

CAT levels decreased in serum, liver and kidney tissues

with sepsis induced by CLP (Fig. 3). While high-dose NAD⁺ treatment significantly increased CAT levels, especially in the liver and kidney (P<0.001 for both), this effect was not significant in serum. When CAT levels in the liver and kidney tissues were compared in the CLP group and the treatment groups, a significant significance was found between the groups (liver, P=0.005, P=0.000, kidney, respectively; P=0.007, P=0.001). NAD⁺ administration significantly increased CAT levels in the liver and kidney (respectively, P=0.014, P=0.003) in the treatment groups compared to the Sham group.

Histological and Immunohistochemical Evaluation

Histopathological findings for the groups are given in Table 1. When liver tissue sections were evaluated in terms of sinusoidal congestion, necrosis and vacuolization, all scores were significantly higher in the CLP group than Sham, CLP+N100 and CLP+N300 groups (for all P=0.001). The liver samples of the treatment groups had nearly normal parenchyma morphological structure (Fig. 4). There was common sinusoidal congestion, necrosis and vacuolization observed in the CLP group. Necrosis was significantly reduced in the CLP+N100 group, and there was no necrotic area in the CLP+N300 group. In the CLP+N100 and CLP+N300 groups, more normal cell contours were observed, but there was no significant difference between the CLP+N100 and CLP+N300 group (Fig. 4).

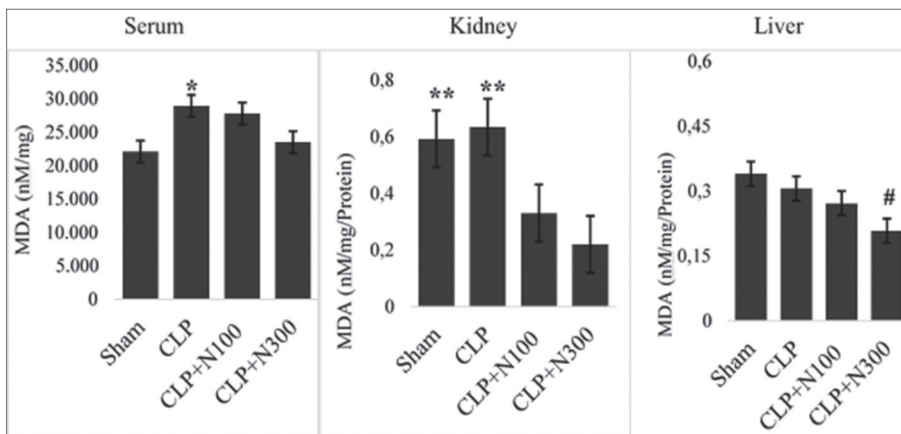
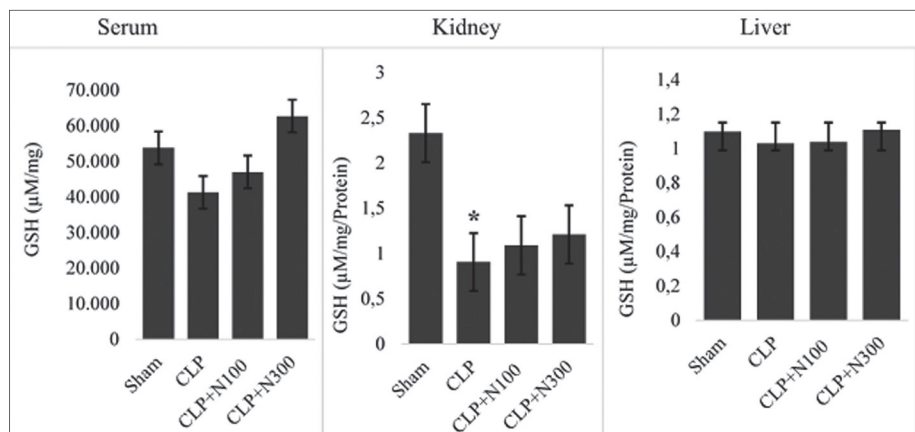
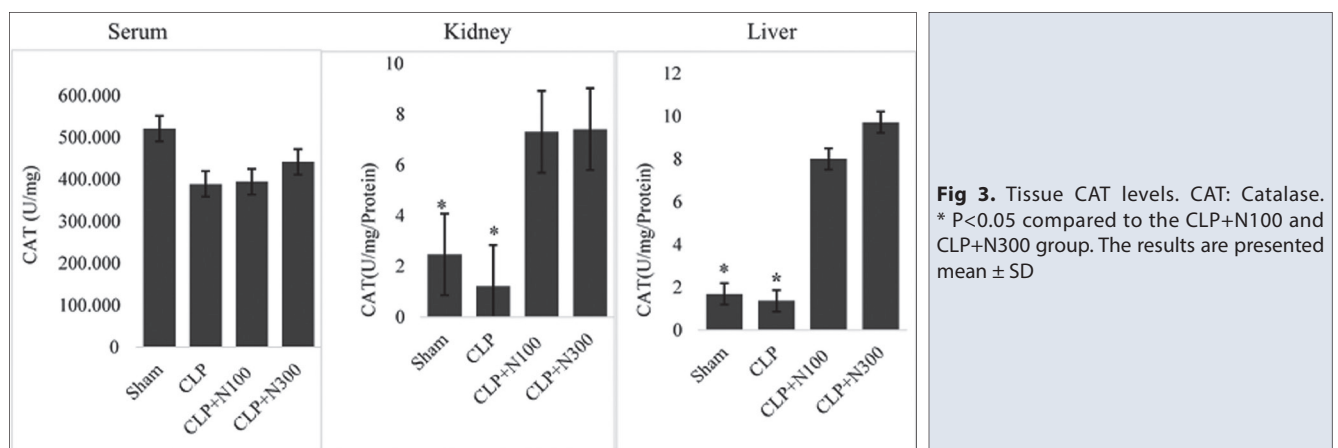


Fig 1. Tissue MDA Levels. MDA: Malondialdehyde; * P<0.05 compared to the Sham group; ** P<0.05 compared to the CLP+N100 and CLP+N300 group; # P<0.05 compared to the Sham and CLP group. The results are presented mean ± SD

Fig 2. Tissue GSH Levels. GSH: Glutathione. *P<0.05 compared to the Sham, CLP+N100 and CLP+N300 group. The results are presented mean ± SD



**Table 1.** Comparison of histopathological scores of experimental groups

Groups/Parameters		Sham	CLP	CLP+N100	CLP+N300	P Value
Liver	Sinusoidal Congestion	0 (1)	2 (1)*	0 (1)	0 (1)	0.001
	Necrosis	0 (1)	2 (1)*	0 (1)	0 (0)	0.002
	Vacuolization	0 (1)	2 (1)*	0 (1)	0 (0)	0.001
Kidney	Tubular Necrosis	0 (1)	2 (1)*	1 (1)	1 (1)	0.001
	Cytoplasmic Vacuolization	0 (1)	2 (0)*	1 (1)	0 (1)	0.000
	Tubular Dilation and Interstitial Hemorrhage	0 (0)	3 (1)*	1 (1)	0 (1)	0.000

The results are presented median (Inter Interquartile Range) (n=7). * $P < 0.05$ as compared to the Sham and treatment groups

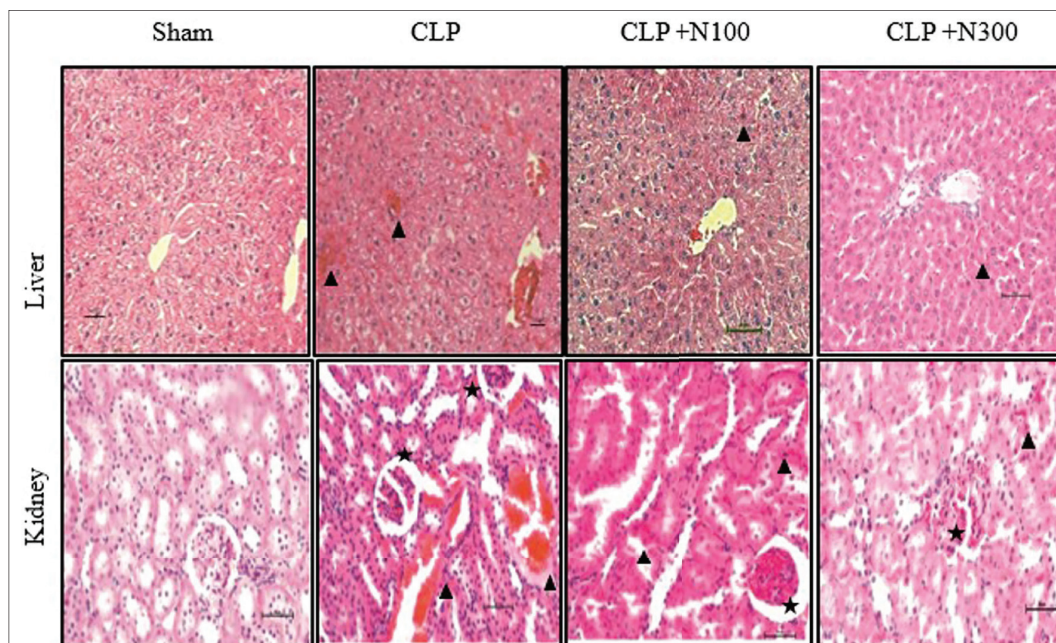


Fig 4. Microscopic images of liver and kidney samples belonging to the sham, untreated and treated sepsis groups after H&E staining. *Liver tissue:* Sham group normal liver parenchyma morphology; sinusoidal congestion and hemorrhage and damaged hepatocytes (arrowhead) are seen in the CLP group. Sinusoidal congestion and hemorrhage and a decrease in damaged hepatocytes (arrowhead) are observed in the sepsis groups receiving treatment. *Kidney tissue:* Normal kidney morphology in the sham group; in the CLP group, Bowman's space enlargement and glomerular congestion (*), vascular congestion and hemorrhage and damage to the tubule epithelium (arrowhead) are seen. In the treatment groups, Bowman's space enlargement and glomerular congestion (*), vascular congestion and hemorrhage, and a significant reduction in tubular epithelium damage (arrowhead) are observed. H&E, 200X, 50 scale bar

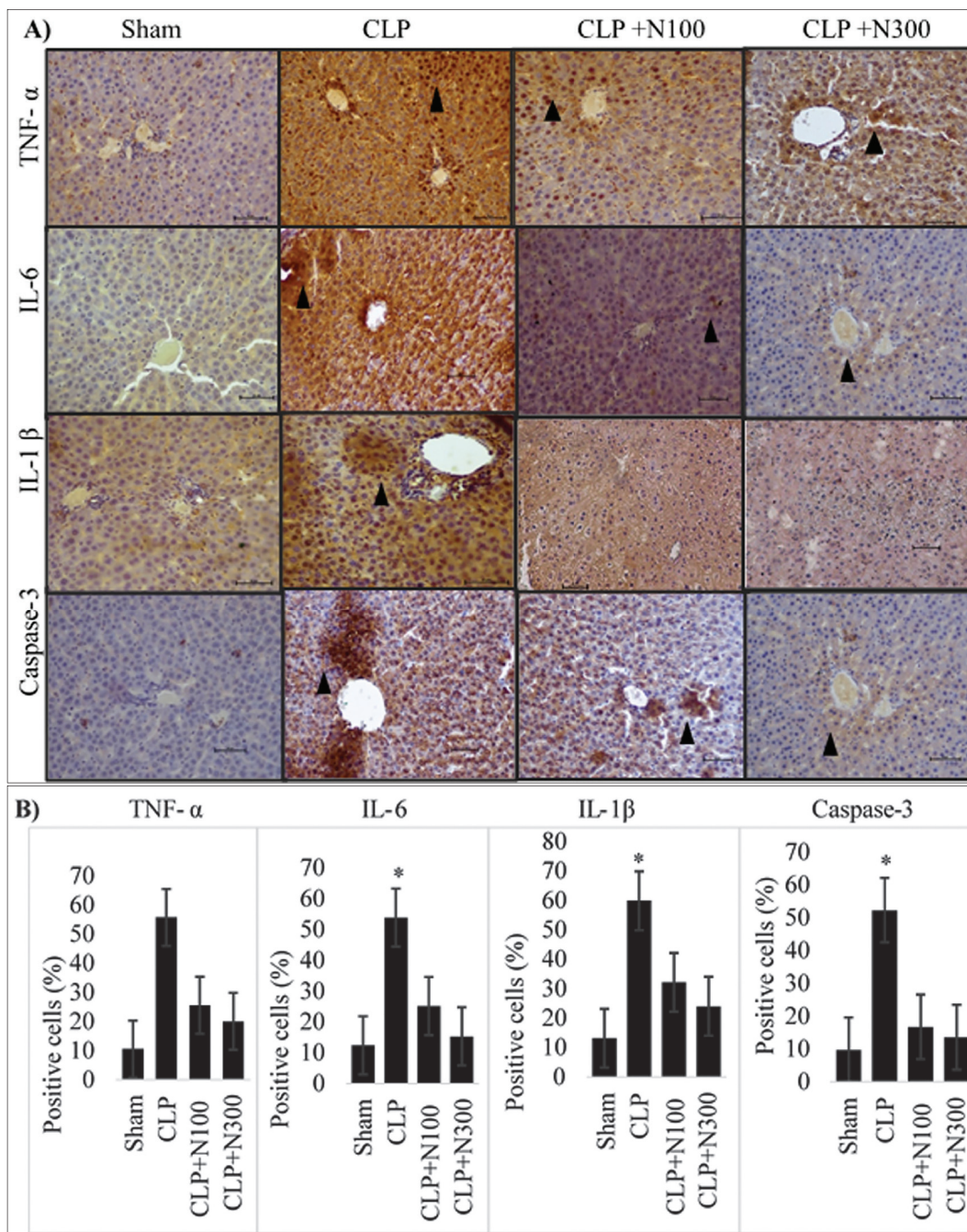


Fig 5. Liver tissue. Sham group, TNF- α , IL-6, IL-1 β and caspase-3 normal percentage of positive cells and expression. In the CLP group increased TNF- α , IL-6, IL-1 β , and caspase-3 expression (A) (arrowhead) and percentage of positive cells (B), while these reduced in the treated CLP+N100 and CLP+N300 sepsis groups *P<0.001 compared to the Sham and treatment groups. IHC, 200X, 50 scale bar

In the histopathological evaluation of the kidney samples, tubular necrosis, cytoplasmic vacuolization and tubular dilation and interstitial hemorrhage were evaluated as CLP-induced morphological kidney damage markers. Tubular necrosis, cytoplasmic vacuolization and tubular dilation and interstitial hemorrhage scores were significantly increased in the CLP group compared to the Sham and treatment groups (for all P=0.001). NAD treatment caused tubular morphology recovery (Fig. 4). In the CLP+N300 group had better preserved renal morphology. In the CLP+N300

group, vacuolar degeneration in tubular epithelium were rarely observed compared to the CLP+N100 group (Fig. 4). There was no significant difference between the Sham and treatment groups for all the histopathological parameters (P>0.05).

For the immunohistochemical examination of both liver and kidney tissue, normal levels of TNF- α , IL-6, caspase-3, and IL-1 β expression were observed in the Sham group. TNF- α , IL-6, caspase-3, and IL-1 β expression in both liver and

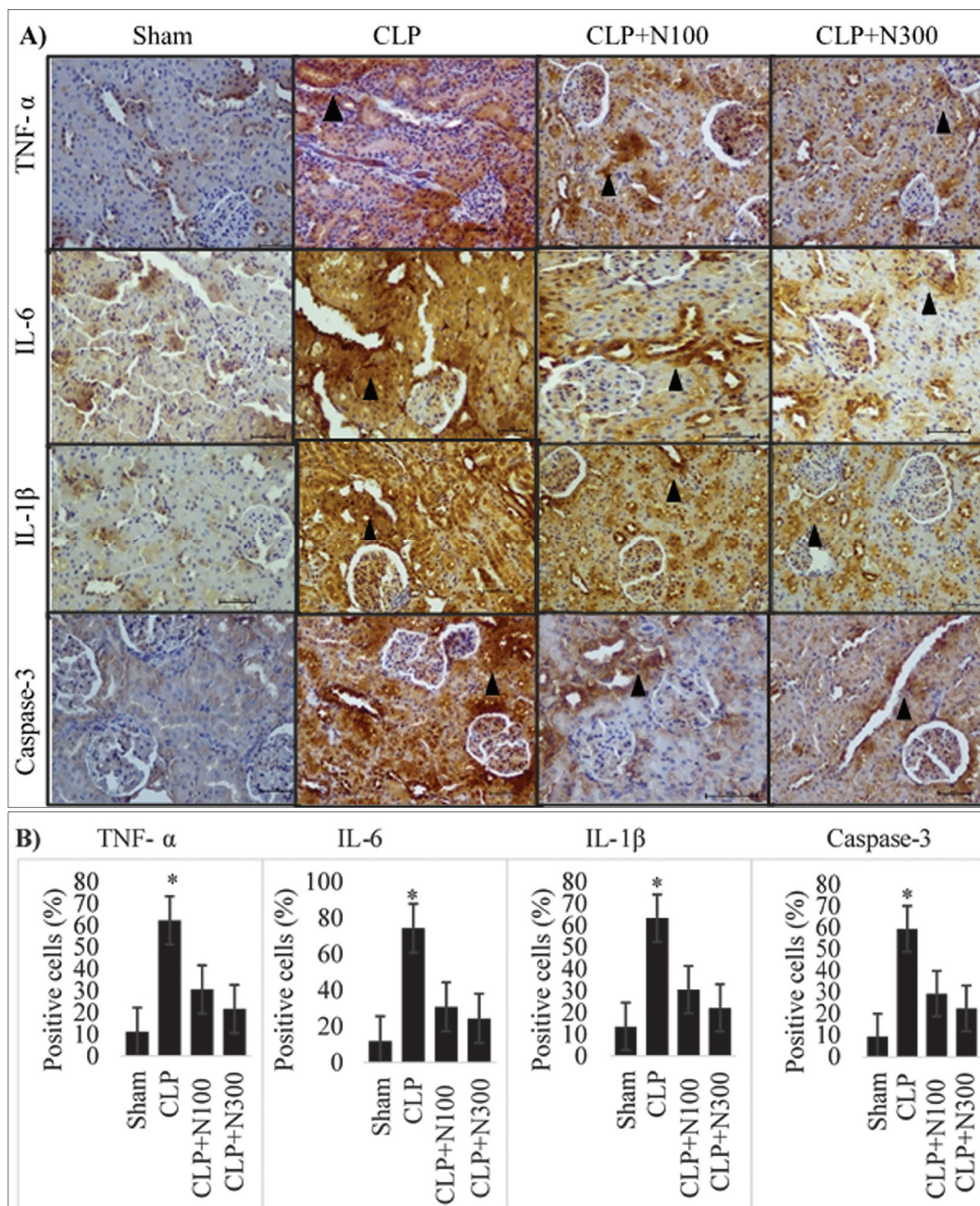


Fig 6. Kidney tissue. Sham group, TNF- α , IL-6, IL-1 β and caspase-3 normal percentage of positive cells and expression. In the CLP group increased TNF- α , IL-6, IL-1 β , and caspase-3 expression (A) (arrowhead) and percentage of positive cells (B), while these were reduced in the treated CLP+N100 and CLP+N300 sepsis groups. * $P < 0.001$ compared to the Sham, and treatment groups. IHC, 200X, 50 scale bar

kidney tissues in the CLP group was highly immunopositive compared to the Sham and treatment groups (Fig. 5-A,B, Fig. 6-A,B). The highest percentage of positive cells in the liver and kidney tissue was in the CLP group (Liver; TNF- α ; 55.71%, IL-6; 53.85%, caspase-3; 52.28%, and IL-1 β ; 59.85% and kidney: TNF- α ; 62.42%, IL-6; 74.42%, caspase-3; 59.42%, and IL-1 β ; 63.42%). The percentage of positive cells was found to be statistically significant ($P=0.000$ for all) (Fig. 5-B, Fig. 6-B). In addition, immunopositivity and the number of positive cells decreased significantly in the CLP+N300 group (Liver; TNF- α ; 20%, IL-6; 15.28%, caspase-3; 13.57%, and

IL-1 β ; 24% and Kidney: TNF- α ; 21.71%, IL-6; 24.57%, caspase-3; 22.42%, and IL-1 β ; 22.28%) compared to the CLP+N100 group (Liver; TNF- α ; 25.57%, IL-6; 25.14% caspase-3; 16.71%, and IL-1 β ; 32.14% and Kidney: TNF- α ; 30.71%, IL-6; 31%, caspase-3; 29.28%, and IL-1 β ; 30.57%), and this decrease was statistically significant ($P=0.000$) (Fig. 5-B, Fig. 6-B).

DISCUSSION

Sepsis is one of the leading causes of death in intensive care units worldwide. Multi-organ failure is the main feature of

sepsis and death is accompanied by medical complications such as multi-organ dysfunction. One of the main causes of multi-organ dysfunction is the development of oxidative stress [21]. ROS, which are released as a result of oxidative stress caused by sepsis, cause damage to structural proteins and DNA as well as phospholipids found in cellular membranes. Oxidative damage in cells and tissues causes increases in MDA and other oxidation products, and decreases in SOD, GSH levels and CAT activity. In the case of DNA damage, it causes widespread tissue damage by triggering apoptosis [22].

The current study results show that sepsis induced by CLP causes significant damage to the liver and kidneys, and this damage is significantly reduced by nicotinamide treatment. In our study, we saw that microscopic damage in liver and kidney samples in the group with untreated sepsis was associated with an increase in MDA levels, which is an oxidative stress biomarker, and a decrease in endogenous antioxidant GSH and CAT activity. However, in our study, the high degree of increase in the expression of TNF- α , IL-6 and IL-1 β cytokines induced by sepsis and involved in the inflammatory process is parallel to MDA levels and this result shows that oxidative damage in tissues triggers the inflammatory process. Specifically, our results showed that nicotinamide slows the increase in the release of CLP induced cytokines. In addition, the increase in caspase-3 expression in tissues showed that apoptosis was triggered by the formation of cellular damage in the tissue.

Sepsis increases the expression and release of pro-inflammatory cytokines such as TNF- α , IL-6 and IL-1 β in tissues. The inflammatory process progressing in sepsis becomes stronger with ROS and turns into a cytokine storm, also known as the cytokine cascade. For this reason, studies about the treatment of sepsis reported that, in addition to reducing cytokine release, preventing ROS formation also decreases tissue and organ damage caused by sepsis and decreases the mortality rate [8]. Inflammasome is essential for the innate immune response to infection and is also important in apoptosis due to sepsis. It was shown that TNF- α , IL-6, IL-1A and IL-1 β may be associated with sepsis susceptibility. IL-6 levels in septic rats were showed to increase mRNA expression and IL-6 plays important roles in heart, liver and kidney damage in septic rats [23].

In our study, in the immunohistochemical examination of both liver and kidney tissue, TNF- α , IL-6, caspase-3, and IL-1 β expression were at normal levels in the Sham group. However, TNF- α , IL-6, caspase-3, and IL-1 β expression increased in both liver and kidney tissues in the CLP group. It was observed that immunopositivity decreased in the treatment groups. These results indicate that sepsis stimulates intense inflammation pathways in these tissues and causes tissue damage. In our study, it was found that NAD⁺ also reduces and corrects the negative effects of sepsis in kidney and liver tissue.

Inflammatory pathogenesis and organ damage leading to death from sepsis, especially for vital organs such as the liver, are still not fully understood. Post-sepsis liver dysfunction was shown to be an independent risk factor for multiorgan dysfunction and death from sepsis. In sepsis, the liver-mediated immune response is responsible for the clearance of bacteria and toxins, but also causes inflammation, suppression of the immune system and organ damage. Mitigation of liver damage and restoration of liver function reduce morbidity and mortality rates in patients with sepsis [24]. Liu et al. [25] showed that there was significant cellular damage in liver tissue in the sepsis group and a significant increase in caspase-3 level in their studies investigating the mechanism of action of sepsis-induced liver damage in rats.

NAD⁺ is an essential coenzyme that plays important roles in a variety of metabolic pathways and was approved as a valuable strategy for increasing overall content and treating a wide variety of pathophysiological conditions [26,27]. Our results showing that nicotinamide suppresses pro-inflammatory cytokines are consistent with other studies. Traister et al. [28] reported that NAD⁺ reduced the expression of proinflammatory (IL-1 β , TNF- α TGF- β 2 and macrophage chemotactic protein-1) and pro-fibrotic cytokines in liver cells. Mukherjee et al. [29] reported that NAD⁺ increases liver regeneration, and NAD⁺ metabolism can be modulated to support recovery from liver damage. Hong et al. [30] used nicotinamide riboside (NR) application, which is a precursor of NAD, and reported increased NAD⁺ levels and decreased oxidative stress, inflammation and caspase-3 activity in lung and heart tissues. In another study, nicotinamide was shown to be protective against acetaminophen-induced liver toxicity, even when administered after injury [31].

In a study investigating the effects of experimental acute sepsis on kidney damage, mitochondrial dysfunction was reported in proximal tubule epithelial cells. In addition, a decrease in nicotinamide adenine dinucleotide and mitochondrial membrane potential was seen [32]. In our study, we found important results showing that NAD⁺ corrected the damage caused by sepsis in kidney tissue. In our study, interstitial hemorrhage, enlargement of the Bowman capsule, glomerular congestion and dense hemorrhage areas, and degeneration in the tubular epithelium were observed in the kidney tissues of the CLP group. In the treatment groups, this deterioration in tissue decreased and improvement was almost normal. The improvement in the CLP+N300 group was greater. These findings show that NAD⁺ may be a very important biological agent in preventing tissue damage in sepsis, especially in acute microbial sepsis. The pathogenesis of acute kidney injury in sepsis is associated with apoptosis. Ying et al. [33] reported that caspase 3 expression increased in the kidney tissue of septic mice.

Numerous studies showed that nicotinamide may have an important role in infection and sepsis by inhibiting

poly (ADP-ribose) polymerase (PARP) activation, pro-inflammatory mediators, and antioxidant damage by restoring mitochondrial function to restore adenosine triphosphate (ATP) levels. Thus, nicotinamide plays a role in the antioxidant system as well as energy metabolism^[34,35]. In recent years, the results of clinical and experimental studies also show NAD⁺ homeostasis as a determinant of the ability of kidney tissue to resist various stressors^[36]. Guan et al.^[37] applied the NAD precursor nicotinamide mononucleotide (NMN) to young and old rats, which they created acute kidney injury (AKI). As a result of the study, they reported that NAD levels increased in both age groups. In another study, it was reported that nicotinamide administration decreased the severity of AKI by increasing renal NAD⁺^[38].

As a result, increased oxidative stress due to sepsis induced by CLP, inflammation and apoptosis caused severe damage in tissues. Our findings show that the damage from sepsis is prevented by the antioxidant, anti-inflammatory and anti-apoptotic effects of nicotinamide adenine dinucleotide. It is clear that nicotinamide has great potential for multiple diseases, but the development of new therapeutic strategies needs to be elucidated with further investigations of new cellular pathways largely and closely directed by nicotinamide.

AVAILABILITY OF DATA AND MATERIALS

The authors declare that data supporting the findings of this study are available within the article.

FINANCIAL SUPPORT

This research did not receive any financial support from funding agencies in the public, commercial, or not-for-profit sectors.

CONFLICT OF INTEREST

We declare that there is no conflict of interest between the authors.

AUTHORS CONTRIBUTIONS

SD, planned this study design, conducted this experiment, statistics and biochemical analysis, and wrote this manuscript. OB conducted histopathological and immunohistochemical examination and evaluation, study design, contributed to literature searches, data acquisition. AS and NB contributed to write, biochemical analysis, literature searches.

REFERENCES

1. **Mayr FB, Yende S, Angus DC:** Epidemiology of severe sepsis. *Virulence*, 5 (1): 4-11, 2014. DOI: 10.4161/viru.27372
2. **Kempker JA, Martin GS:** The changing epidemiology and definitions of sepsis. *Clin Chest Med*, 37 (2): 165-179, 2016. DOI: 10.1016/j.ccm.2016.01.002

3. **Cohen J:** The immunopathogenesis of sepsis. *Nature*, 420 (6917): 885-891, 2002. DOI: 10.1038/nature01326
4. **Deng M, Scott MJ, Loughran P, Gibson G, Sodhi C, Watkins S, Hackam D, Billiar TR:** Lipopolysaccharide clearance, bacterial clearance, and systemic inflammatory responses are regulated by cell type-specific functions of TLR4 during sepsis. *J Immunol*, 190 (10): 5152-5160, 2013. doi: 10.4049/jimmunol.1300496
5. **Shimaoka M, Park EJ:** Advances in understanding sepsis. *Eur J Anaesthesiol Suppl*, 42: 146-153, 2008. DOI: 10.1017/S0265021507003389
6. **Cinel I, Opal SM:** Molecular biology of inflammation and sepsis: A primer. *Crit Care Med*, 37 (1): 291-304, 2009. DOI: 10.1097/CCM.0b013e31819267fb
7. **Bavunoglu I, Genc H, Konukoglu D, Cicekci H, Sozer V, Gelisgen R, Uzun H:** Oxidative stress parameters and inflammatory and immune mediators as markers of the severity of sepsis. *J Infect Dev Ctries*, 10 (10): 1045-1052, 2016. DOI: 10.3855/jidc.7585
8. **Petronilho F, Florentino D, Danielski LG, Vieira LC, Martins MM, Vieira A, Bonfante S, Goldim MP, Vuolo F:** Alpha-lipoic acid attenuates oxidative damage in organs after sepsis. *Inflammation*, 39 (1): 357-365, 2016. DOI: 10.1007/s10753-015-0256-4
9. **Perico L, Benigni A:** The iNADequacy of renal cell metabolism: modulating NAD⁺ biosynthetic pathways to forestall kidney diseases. *Kidney Int*, 96 (2): 264-267, 2019. DOI: 10.1016/j.kint.2019.03.012
10. **Lappas M, Permezel M:** The anti-inflammatory and antioxidative effects of nicotinamide, a vitamin B3 derivative, are elicited by FoxO3 in human gestational tissues: Implications for preterm birth. *J Nutr Biochem*, 22 (12): 1195-1201, 2011. DOI: 10.1016/j.jnutbio.2010.10.009
11. **Ungerstedt J, Blombäck M, Söderström T:** Nicotinamide is a potent inhibitor of proinflammatory cytokines. *Clin Exp Immunol*, 131 (1): 48-52, 2003. DOI: 10.1046/j.1365-2249.2003.02031.x
12. **Hosseini L, Vafae MS, Mahmoudi J, Badalzadeh R:** Nicotinamide adenine dinucleotide emerges as a therapeutic target in aging and ischemic conditions. *Biogerontology*, 20 (4): 381-395, 2019. DOI: 10.1007/s10522-019-09805-6
13. **Cadirci E, Altunkaynak BZ, Halici Z, Odabasoglu F, Uyanik MH, Gundogdu C, Suleyman H, Halici M, Albayrak M, Unal B:** α-lipoic acid as a potential target for the treatment of lung injury caused by cecal ligation and puncture-induced sepsis model in rats. *Shock*, 33 (5): 479-484, 2010. DOI: 10.1097/SHK.0b013e3181c3cf0e
14. **Waterborg JH, Matthews HR:** The Lowry method for protein quantitation. *Methods Mol Biol*, 32, 1-4, 1994. DOI: 10.1385/0-89603-268-x:1
15. **Beuge J, Aust SD:** Microsomal lipid peroxidation. *Methods Mol Biol*, 52: 302-310, 1978. DOI: 10.1016/s0076-6879(78)52032-6
16. **Agergaard N, Jensen PT:** Procedure for blood glutathione peroxidase determination in cattle and swine. *Acta Vet Scand*, 23 (4): 515-527, 1982. DOI: 10.1186/bf03546770
17. **Hadwan MH:** Simple spectrophotometric assay for measuring catalase activity in biological tissues. *BMC Biochem*, 19 (1): 7, 2018. DOI: 10.1186/s12858-018-0097-5
18. **Suzuki S, Toledo-Pereyra LH, Rodriguez FJ, Cejalvo D:** Neutrophil infiltration as an important factor in liver ischemia and reperfusion injury. Modulating effects of FK506 and cyclosporine. *Transplantation*, 55 (6): 1265-1272, 1993. DOI: 10.1097/00007890-199306000-00011
19. **Irmak MK, Koltuksuz U, Kutlu NO, Yağmurca M, Özyurt H, Karaman A, Akyol Ö:** The effect of caffeic acid phenethyl ester on ischemia-reperfusion injury in comparison with α-tocopherol in rat kidneys. *Urol Res*, 29 (3): 190-193, 2001. DOI: 10.1007/s002400100185
20. **Panzan MQ, Mattar R, Maganhin CC, dos Santos Simões R, Rossi AGZ, da Motta ELA, Baracat EC, Soares-Jr JM:** Evaluation of FAS and caspase-3 in the endometrial tissue of patients with idiopathic infertility and recurrent pregnancy loss. *Eur J Obstet Gynecol Reprod Biol*, 167 (1): 47-52, 2013. DOI: 10.1016/j.ejogrb.2012.10.021
21. **Wu Y, Yao YM, Lu ZQ:** Mitochondrial quality control mechanisms as potential therapeutic targets in sepsis-induced multiple organ failure. *J Mol Med*, 97 (4): 451-462, 2019. DOI: 10.1007/s00109-019-01756-2
22. **Chousterman BG, Swirski FK, Weber GF:** Cytokine storm and sepsis

disease pathogenesis. *Semin Immunopathol*, 39 (5): 517-528, 2017. DOI: 10.1007/s00281-017-0639-8

- 23. Zhang PP, Li ZJ, Wang DQ:** Effect of Liangge powder on expression of inflammatory mediators and hepatic and renal function in rats with sepsis. *Zhonghua Lao Dong Wei Sheng Zhi Za Zhi*, 35 (5): 369-372, 2017. DOI: 10.3760/cma.j.issn.1001-9391.2017.05.014
- 24. Yan J, Li S, Li S:** The role of the liver in sepsis. *Int Rev Immunol*, 33 (6): 498-510, 2014. DOI: 10.3109/08830185.2014.889129
- 25. Li XK, Yang SC, Bi L, Jia Z:** Effects of dexmedetomidine on sepsis-induced liver injury in rats. *Eur Rev Med Pharmacol Sci*, 23 (3 Suppl): 177-183, 2019. DOI: 10.26355/eurrev_201908_18645
- 26. Mehmel M, Jovanović N, Spitz U:** Nicotinamide riboside—the current state of research and therapeutic uses. *Nutrients*, 12 (6): 1616, 2020. DOI: 10.3390/nu12061616
- 27. Bogan KL, Brenner C:** Nicotinic acid, nicotinamide, and nicotinamide riboside: A molecular evaluation of NAD⁺ precursor vitamins in human nutrition. *Annu Rev Nutr*, 28: 115-130, 2008. DOI: 10.1146/annurev.nutr.28.061807.155443
- 28. Traister A, Breitman I, Bar-Lev E, Zvibel I, Harel A, Halpern Z, Oren R:** Nicotinamide induces apoptosis and reduces collagen I and pro-inflammatory cytokines expression in rat hepatic stellate cells. *Scand J Gastroenterol*, 40(10):1226-1234, 2005. DOI:10.1080/00365520510023341
- 29. Mukherjee S, Chellappa K, Moffitt A, Ndungu J, Dellinger RW, Davis JG, Agarwal B, Baur JA:** Nicotinamide adenine dinucleotide biosynthesis promotes liver regeneration. *Hepatology*, 65 (2): 616-630, 2017. DOI: 10.1002/hep.28912
- 30. Hong G, Zheng D, Zhang L, Ni R, Wang G, Fan GC, Lu Z, Peng T:** Administration of nicotinamide riboside prevents oxidative stress and organ injury in sepsis. *Free Radic Biol Med*, 123, 125-137, 2018. DOI: 10.1016/j.freeradbiomed.2018.05.073
- 31. Shi Y, Zhang L, Jiang R, Chen W, Zheng W, Chen L, Tang L, Li L, Li L, Tang W, Yu Y:** Protective effects of nicotinamide against acetaminophen-induced acute liver injury. *Int Immunopharmacol*, 14 (4): 530-537, 2012. DOI: 10.1016/j.intimp.2012.09.013
- 32. Arulkumaran N, Pollen S, Greco E, Courtneidge H, Hall AM, Duchon MR, Tam FWK, Unwin RJ, Singer M:** Renal tubular cell mitochondrial dysfunction occurs despite preserved renal oxygen delivery in experimental septic acute kidney injury. *Crit Care Med*, 46 (4): e318-e325, 2018. DOI: 10.1097/CCM.0000000000002937
- 33. Ying J, Wu J, Zhang Y, Han Y, Qian X, Yang Q, Chen Y, Chen Y, Zhu H:** Ligustrazine suppresses renal NMDAR1 and caspase-3 expressions in a mouse model of sepsis-associated acute kidney injury. *Mol Cell Biochem*, 464 (1): 73-81, 2020. DOI: 10.1007/s11010-019-03650-4
- 34. Cheng L, Chen T, Liu Y, Liu K, Liang H:** Progress of nicotinamide in preventing infection and sepsis. *Zhonghua Wei Zhong Bing Ji Jiu Yi Xue*, 32 (7): 877-879, 2020. DOI: 10.3760/cma.j.cn121430-20200319-00098
- 35. Ying W:** NAD⁺/NADH and NADP⁺/NADPH in cellular functions and cell death: regulation and biological consequences. *Antioxid Redox Signal*, 10 (2): 179-206, 2008. DOI: 10.1089/ars.2007.1672
- 36. Ralto KM, Rhee EP, Parikh SM:** NAD(+) homeostasis in renal health and disease. *Nat Rev Nephrol*, 16 (2): 99-111, 2020. DOI: 10.1038/s41581-019-0216-6
- 37. Guan Y, Wang SR, Huang XZ, Xie QH, Xu YY, Shang D, Hao CM:** Nicotinamide mononucleotide, an NAD(+) precursor, rescues age-associated susceptibility to AKI in a sirtuin 1-dependent manner. *J Am Soc Nephrol*, 28 (8): 2337-2352, 2017. DOI: 10.1681/asn.2016040385
- 38. Tran MT, Zsengeller ZK, Berg AH, Khankin EV, Bhasin MK, Kim W, Clish CB, Stillman IE, Karumanchi SA, Rhee EP, Parikh SM:** PGC1 α drives NAD biosynthesis linking oxidative metabolism to renal protection. *Nature*, 531 (7595): 528-532, 2016. DOI: 10.1038/nature17184